



Letter to the Editor

Korean J Anesthesiol 2021;74(2):178-180

<https://doi.org/10.4097/kja.20398>

pISSN 2005-6419 • eISSN 2005-7563

Received: July 18, 2020

Revised: August 5, 2020

Accepted: August 6, 2020

Corresponding author:

John J. Finneran IV, M.D.

Department of Anesthesiology, University of California, 200 West Arbor Drive MC 8770

San Diego, CA 92103, USA

Tel: +1-408-307-3004

Fax: +1-619-543-6162

Email: jfinneran@ucsd.edu

ORCID: <https://orcid.org/0000-0002-0955-155X>

Continuous erector spinae plane blocks with automated boluses for analgesia following percutaneous nephrolithotomy

John J. Finneran IV¹, Brenton Alexander¹, Seth K. Bechis², Roger L. Sur², Brian M. Ilfeld¹

Departments of ¹Anesthesiology, ²Urology, University of California San Diego, San Diego, CA, USA

Percutaneous nephrolithotomy (PCNL) is a minimally invasive surgical procedure providing an alternative to open surgery for removal of large stones from the kidney [1]. Despite its minimally invasive nature, the procedure can still be associated with significant postoperative pain and opioid requirements, either of which may prohibit same-day discharge. This is especially true in cases of multiple access tracts, larger tract size, or the use of a postoperative nephrostomy tube. The erector spinae plane (ESP) block was first described by Forero et al. [2] as an analgesic modality for thoracic neuropathic pain. This block has since been described for analgesia following PCNL and other retroperitoneal urologic surgeries [3]. However, these reports have focused on single injection nerve blocks, and the duration of pain following PCNL with nephrostomy tube placement is likely to exceed that of a single injection nerve block. Continuous peripheral nerve blocks offer a much longer duration of analgesia; however, it remains unknown whether a continuous technique may be applied to the ESP block, especially in the context of analgesia following PCNL. We report on five patients who had a continuous ESP block following PCNL. This series represents the first evidence that a continuous ESP block may provide postoperative analgesia and facilitate discharge in patients undergoing PCNL and suggests that automated boluses and an infusion delay timer may increase the spread and duration of the infusion.

The University of California San Diego Institutional Review Board waives review requirements for short case series. Written informed consent for the ESP block and publication of relevant, non-identifiable history and imaging in the form of a case report was obtained from all patients. Five patients, ranging in age from 34 to 75 years, underwent PCNL with nephrostomy tube placement and had a continuous ESP block for postoperative analgesia. In the preoperative area, patients were positioned prone with standard American Society of Anesthesiologists monitors and oxygen delivered via facemask. Using either a 5- to 2-MHz curvilinear probe (C60xi, Edge II[®], SonoSite, USA) or a 13- to 6-MHz high frequency linear probe (HFL38xi, Edge II[®], SonoSite, USA), the transverse process of the 10th thoracic vertebra was identified by counting up from the 12th rib. After sterilely prepping and draping the insertion site, the skin was anesthetized with 2 ml lidocaine 1%. A 17-gauge (G) Tuohy needle (FlexTip Plus[®], Teleflex Medical, USA) was then advanced under ultrasound guidance with an in-plane technique to a point just to the depth of the erector spinae muscle and superficial to the 10th transverse process ipsilateral to the surgical side (Fig. 1). The plane to the depth of the muscle was opened by injecting 30 ml ropivacaine 0.5% with 2.5 µg/ml epinephrine. The local anesthetic was visualized spreading in both cephalad and caudad directions to the depth of the erector

© The Korean Society of Anesthesiologists, 2021

© This is an open-access article distributed under the terms of the Creative Commons Attribution license (<http://creativecommons.org/licenses/by/4.0/>), which permits unrestricted use, distribution, and reproduction in any medium, provided the original work is properly cited.

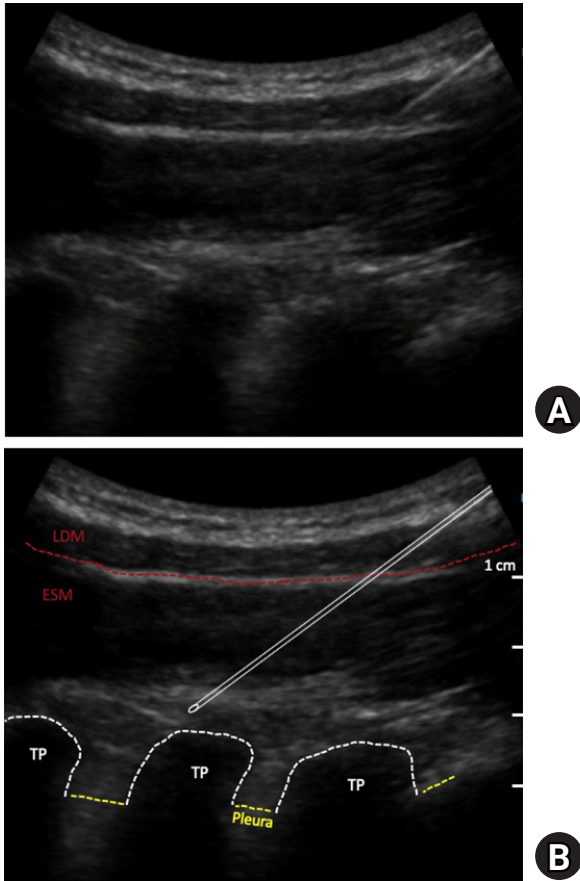


Fig. 1. (A) The 10th thoracic vertebral transverse process is identified to the depth of the erector spinae and latissimus dorsi muscles. A 17-gauge Tuohy needle is advanced toward this transverse process. (B) Schematic demonstrating the latissimus dorsi (LDM) and erector spinae (ESM) muscles, as well as the transverse processes (TP), pleura, and needle trajectory (white outline).

spinae muscle. A 19 G flexible, single-orifice perineural catheter (FlexTip Plus[®], Teleflex Medical, USA) was inserted under ultrasound guidance. Correct location of the catheter was confirmed by injection of an additional 1–2 ml ropivacaine 0.5% with visualization of spread on the plane to the depth of the erector spinae muscle. The catheter was then secured at the skin with clear, occlusive dressings and 2-octyl cyanoacrylate adhesive to prevent dislodgement of the catheter, leakage, and infection.

Patients received intermittent boluses of ropivacaine 0.2% (15 mL automatic bolus every 2 hours with 5 mL patient-controlled bolus available every 30 minutes) using an ambulatory electronic pump (Nimbus[™] II PainPRO[®], InfuTronix, USA) with a 500 mL reservoir of ropivacaine 0.2%. As the block was initially administered with a long-acting local anesthetic (typically 8–12 h duration), a 6-hour delay was set for the automated bolus doses to increase the total duration of the initial block combined with the postoperative local anesthetic administration. Prior to discharge,

detailed instructions on catheter care and removal were provided to the patients and a caregiver. They were instructed to assess the catheter site daily for evidence of infection or dislodgement and educated on the removal of the catheter. All patients were discharged on either the day of surgery or the first postoperative day and received daily telephone follow-up during which they reported excellent analgesia with minimal or no supplementation by oral opioid analgesics for the duration of the continuous ESP block. All catheters were successfully removed by the patients with the help of a caregiver on either the second or third postoperative day.

Historically, continuous peripheral nerve blocks have been administered primarily as a continuous infusion supplemented by patient-controlled boluses. However, there is evidence that larger, repeated bolus doses provide superior analgesia, possibly as a result of improved spread of the local anesthetic [4]. Evidence for the improved spread may be found in one study demonstrating automated boluses increasing the number of affected dermatomal levels compared to continuous infusions for continuous paravertebral blocks [5]. Since plane blocks, such as ESP, rely on the spread of local anesthetic on an interfacial plane, automated boluses may be particularly useful for this group of blocks. However, until recently, ambulatory pumps capable of providing automated boluses in addition to patient-controlled boluses were unavailable [4].

In the presented series, ESP perineural local anesthetic administered in automated boluses with patient-controlled dose supplementation provided outstanding analgesia with minimal opioid requirements in five outpatients following PCNL. Further investigation involving randomized, controlled trials is indicated to determine the clinical benefit of continuous ESP blocks for PCNL and other urologic surgeries, as well as the optimal dosing strategies for the block.

Funding Statement

InfuTronix (Natick, MA, USA) provided the ambulatory infusion pumps used for these cases.

Conflicts of Interest

John J. Finneran IV: Dr. Finneran's institution has received funding and/or product for his research from Myoscience, Epimed, InfuTronix, Ferrosan Medical Devices, and SPR Therapeutics.

Brenton Alexander: No potential conflict of interest relevant to this article was reported.

Seth K. Bechis: Dr. Bechis is a paid consultant for Boston Scien-

tific and Karl Storz.

Roger L. Sur: Dr. Sur is a paid consultant for Boston Scientific, Karl Storz, Cook Medical, Lumenis, and serves as Chief Medical Officer for CalyxoTM

Brian Ilfeld: Dr. Ilfeld's institution has received funding and/or product for his research from Myoscience, Epimed, InfuTronix, Ferrosan Medical, Heron Therapeutics, and SPR Therapeutics.

Author Contributions

John J. Finneran IV (Conceptualization; Data curation; Formal analysis; Funding acquisition; Investigation;

Methodology; Project administration; Resources; Writing – original draft; Writing – review & editing)

Brenton Alexander (Data curation; Formal analysis; Methodology; Writing – review & editing)

Seth K. Bechis (Conceptualization; Investigation; Methodology; Writing – review & editing)

Roger L. Sur (Conceptualization; Investigation; Methodology; Writing – review & editing)

Brian M. Ilfeld (Conceptualization; Data curation; Investigation; Methodology; Resources; Supervision; Writing – original draft; Writing – review & editing)

ORCID

John J. Finneran IV, <https://orcid.org/0000-0002-0955-155X>

Brenton Alexander, <https://orcid.org/0000-0001-9323-6538>

Seth K. Bechis, <https://orcid.org/0000-0002-2430-2893>

Roger L. Sur, <https://orcid.org/0000-0002-8183-882X>

Brian M. Ilfeld, <https://orcid.org/0000-0002-6144-3273>

References

1. Wickham JE, Kellet MJ. Percutaneous nephrolithotomy. *Br Med J (Clin Res Ed)* 1981; 283: 1571-2.
2. Forero M, Adhikary SD, Lopez H, Tsui C, Chin KJ. The erector spinae plane block: a novel analgesic technique in thoracic neuropathic pain. *Reg Anesth Pain Med* 2016; 41: 621-7.
3. Gultekin MH, Erdogan A, Akyol F. Evaluation of the efficacy of the erector spinae plane block for postoperative pain in patients undergoing percutaneous nephrolithotomy: a randomized controlled trial. *J Endourol* 2020; 34: 267-72.
4. Ilfeld BM, Gabriel RA. Basal infusion versus intermittent boluses for perineural catheters: should we take the 'continuous' out of 'continuous peripheral nerve blocks'? *Reg Anesth Pain Med* 2019; 44: 285-6.
5. Hida K, Murata H, Ichinomiya T, Inoue H, Sato S, Hara T. Effects of programmed intermittent thoracic paravertebral bolus of levobupivacaine on the spread of sensory block: a randomized, controlled, double-blind study. *Reg Anesth Pain Med* 2019; 44: 326-32.