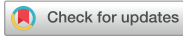

Original Article
Medical Imaging



Comparison of radiographic and computed tomographic acetabular index in small-breed dogs: a preliminary study using Maltese and Shih Tzu

Kanokporn Kanthavichit ¹, Auraiwan Klaengkaew ¹,
Chutimon Thanaboornipat ¹, Damri Darawiroj ²,
Kumpanart Soontornvipart ¹, Nan Choisunirachon ^{1,*}

¹Department of Veterinary Surgery, Faculty of Veterinary Science, Chulalongkorn University, Bangkok 10330, Thailand

²Department of Veterinary Anatomy, Faculty of Veterinary Science, Chulalongkorn University, Bangkok 10330, Thailand

 OPEN ACCESS

Received: Mar 3, 2021

Revised: May 24, 2021

Accepted: Jun 14, 2021

Published online: Jul 6, 2021

*Corresponding author:

Nan Choisunirachon

Department of Veterinary Surgery, Faculty of Veterinary Science, Chulalongkorn University, 39 Henri-Dunant Road, Wangmai, Pathumwan, Bangkok 10330, Thailand.
E-mail: nan.c@chula.ac.th

© 2021 The Korean Society of Veterinary Science

This is an Open Access article distributed under the terms of the Creative Commons Attribution Non-Commercial License (<https://creativecommons.org/licenses/by-nc/4.0>) which permits unrestricted non-commercial use, distribution, and reproduction in any medium, provided the original work is properly cited.


ORCID iDs

Kanokporn Kanthavichit 

<https://orcid.org/0000-0001-5227-508X>

Auraiwan Klaengkaew 

<https://orcid.org/0000-0003-1009-2386>

Chutimon Thanaboornipat 


<https://orcid.org/0000-0002-4548-549X>

Damri Darawiroj 

<https://orcid.org/0000-0001-5873-7951>

Kumpanart Soontornvipart 

<https://orcid.org/0000-0002-6226-9000>

Nan Choisunirachon 

<https://orcid.org/0000-0001-7169-6699>

ABSTRACT

Background: The morphometry of the acetabulum is one source of information that assists in the clinical diagnosis of the hip and influences the proper selection of a prosthesis, reducing post-operative complications such as those seen in total hip replacement (THR). However, acetabular parameters in small-breed dogs are rarely reported.

Objectives: To investigate acetabular parameters using radiography and computed tomography (CT) in small-breed dogs with Maltese and Shih Tzu dogs used as model breeds.

Methods: Standard calibrated, extended hip radiographs and CT images were obtained. Subsequently, acetabular width (AW) in various directions was measured using radiography and CT, whereas acetabular depth (AD) was obtained by CT. Acetabular index (AI) is a ratio calculated from AD and AW.

Results: The values of AW and AD were much higher in Shih Tzu than in Maltese dogs. Male Shih Tzus showed higher values of these parameters than females, while sex-based differences in most of the parameters could not be detected in Maltese. Body weight, but not age, influenced AWs and ADs. While AWs and ADs were influenced by several factors, AI was comparable among the assessed factors and between Maltese and Shih Tzu dogs ($p = 0.172$; 31.42 ± 1.35 and 32.60 ± 1.80 , respectively). Also, AI did not vary with breed, sex, or body size.

Conclusions: The obtained radiographic and CT acetabular parameters could be useful as guidelines for evaluating the acetabulum of small-breed dogs in clinical practice.

Keywords: Acetabulum; computed tomography; Maltese; radiograph; Shih Tzu

INTRODUCTION

The hip joint is an important joint in the caudal part of the body that supports movement and carries the body's weight. The joint is composed of the femoral head and the acetabulum. The acetabulum is characterized by a cup shape or socket on the lateral border of the pelvic bone and contacts the femoral head to form a joint [1]. In small-breed dogs, several diseases can alter hip-joint anatomy: for example, femoral head fracture, femoral luxation, Legg-Calve-

Funding

The scholarship from the Graduate School of Chulalongkorn University to Commemorate the 72nd Anniversary of His Majesty King Bhumibol Adulyadej and The 90th anniversary Chulalongkorn University Fund (Ratchadaphiseksomphot Endowment Fund) (Grant number GCUGR1125632150M,150).

Conflict of Interest

The authors declare no conflicts of interest.

Author Contributions

Conceptualization: Choisunirachon N, Soontornvipart K; Data curation: Choisunirachon N, Kanthavichit K, Thanaboonnipat C; Formal analysis: Choisunirachon N, Kanthavichit K; Funding acquisition: Choisunirachon N, Kanthavichit K; Investigation: Choisunirachon N, Kanthavichit K, Klaengkaew A; Methodology: Choisunirachon N, Soontornvipart K, Thanaboonnipat C; Supervision: Choisunirachon N, Soontornvipart K; Visualization: Choisunirachon N, Soontornvipart K, Darawiroj D; Writing - original draft: Kanthavichit K; Writing - review & editing: Choisunirachon N, Soontornvipart K.

Perthes disease, avascular necrosis (AVN) of the femoral head [2], epiphysiolysis, and canine hip dysplasia (CHD) [3]. These abnormalities can cause hindlimb lameness and subsequent hindlimb muscular atrophy, leading finally to the development of osteoarthritis (OA). To prevent the progressive development of OA and enhance the function of the hip joint, surgical correction, such as femoral head and neck ostectomy (FHNO), is frequently performed. However, FHNO can lead to muscular atrophy and a decreased range of motion of the affected limb [4]. Therefore, total hip replacement (THR) may be considered an alternative solution [5].

Although THR is increasingly being applied in companion animals, a major complication of THR is failure. THR failure can be due to ill-fitting prostheses [6]. It has been reported that accurately sizing the acetabular shell could reduce complications related to THR surgery [7]. Since canine pelvic anatomy varies among breeds, these differences can affect the reliability of acetabular parameters [7]. Availability of hip information from several dog breeds would assist the veterinary orthopedist in selecting the proper implantation device for THR. Radiography has been performed to obtain anatomical information on the acetabulum and to screen for bone alteration of the hip joint. However, radiography can provide low information accuracy due to variations in pelvis position and lack of anatomical reference values [8]. Computed tomography (CT) is currently used for musculoskeletal diagnosis because it can display bone alteration in several dimensions. Although previous studies have reported information on the normal parameters of the canine acetabulum, most data were obtained from large-breed dogs, such as Labrador Retrievers [7], Hounds [9], and Sivas Kangals [3]. Currently, there are no reports of acetabular parameters of small breeds, despite their being the most common breed type in many cities, with Shih Tzu being the most popular dog breed in Thailand. Among the small breeds, Maltese is a breed predisposed to Legg-Calve-Perthes disease or traumatic hip luxation, conditions that can be corrected by THR [2,10]. Therefore, it is very important to establish acetabular parameters for small-breed dogs. The purposes of this study were to obtain acetabular parameters from CT and radiography images of normal Maltese and Shih Tzu dogs and to identify significant differences between the breeds and imaging modalities. In addition, correlations of acetabular parameters with other clinical factors were investigated. The results of this study could present reference values for acetabular parameters of small-breed dogs that would be useful in clinical practice.

MATERIALS AND METHODS

Animals

This study was approved by The Institutional Animal Care and Use Committee of Chulalongkorn University (CU-IACUC) under approval number: 1931037. Maltese and Shih Tzu dogs presented at the Small Animal Hospital, Faculty of Veterinary Science, Chulalongkorn University during December 2017 to September 2019 were included in the study. The gonadectomized dogs included in this study must have undergone gonadectomy at the age of over 6 months to avoid hormonal interference with skeletal maturation. Dogs with histories of pelvic limb abnormalities, such as hip-joint laxity, subluxation or luxation, any fracture of pelvic limbs, and those with evidence of hip abnormalities based on physical and radiographic examination were excluded from the study. All included dogs were examined to confirm their healthy physical status; assessments included general appearance, mentation, hydration status, temperature, heart rate, heart rhythm, respiratory rate, mucous membrane color, capillary refill time, gait observation, neurological examination, and orthopedic examinations, including Ortolani and thumb tests.

Radiography

To ensure the normal anatomical appearance of the acetabulum and pelvic limbs of all assessed dogs, standard extended hip positions in both ventrodorsal (VD) and lateral (LAT) views were obtained using direct digital radiography (ETL, GE, China) with 65 kVp and 2.0 or 2.5 mA for VD and LAT radiographs, respectively. The pelvic radiograph field of view (FOV) was positioned to cover the area from the cranial border of the ilium to the distal end of the femoral condyle. A calibrated ball was placed at the same level of the hip joint during the radiographic examination.

CT

Mechanical restraint was applied to all dogs during CT. In brief, the dog was kept in a plastic carrying box (box size dependent on body size) in a sternal recumbency position supported by rolled towels to minimize dog movements. The CT images were acquired using a 64-slice, helical CT unit (Optima CT660, GE, Japan); the dogs' heads were directed into the CT gantry. The caudal body of the dog, especially the coxofemoral joint, was placed perpendicular to the isocenter of the CT scan. As soon as the proper position was achieved, the pre-scan phase was obtained at 120 kVp and 50 mA. Next, non-contrast-enhanced CT images were acquired at 120 kVp, with automated mA, effective slice thickness of 0.625 mm, collimator pitch of 0.935 mm, and matrix size of 512 × 512 (isotropic voxels). The FOV was placed to cover the whole area of the positioning device. A graduated student (KK) with 2 years of radiology experience uploaded and analyzed the CT images using the Digital Imaging and Communications in Medicine (DICOM) imaging viewer software (Osirix, Pixmeo, Switzerland) under the supervision of an experienced radiologist (NC).

Measurement of acetabular parameters

Acetabular width (AW) by radiography

On the VD radiograph of the pelvis, the calibrated AW in each dog was recorded. Radiographic AW was measured from the cranial to the caudal rim of the acetabulum (**Fig. 1A**).

Acetabular parameters by CT

Multiplanar reconstruction (MPR) and maximum intensity projection were applied to enhance the precision of acetabular measurements on two- and three-dimensional CT (2D-CT and 3D-CT, respectively) images. All measurements were made using a bone window at window width of 1500 Hounsfield units (HU) and a window level of 300 HU. A CT image was deemed acceptable if the characteristics of the acetabulum showed a well-defined margin of the acetabular sourcil and sharp points of the acetabulum. After the best positions of the 2D-CT and 3D-CT images of the hips were selected, AWs in two directions, *i.e.*, dorsolateral-ventrolateral (2D-CT AW; **Fig. 1B**) and craniocaudal (3D-CT AW; **Fig. 1C**), were recorded. In addition, the 2D-CT AD was measured by drawing a line from the medial edge of the acetabular sourcil to the AW line in the perpendicular direction on the 2D-CT image (**Fig. 1B**). Subsequently, the acetabular index (AI) was calculated as the ratio of 2D-CT AD to 2D-CT AW multiplied by 100.

Statistical analysis

All data are presented as descriptive data. Each acetabular parameter, such as radiographic AW, 2D-CT AW, 3D-CT AW, 2D-CT AD, and AI are presented as mean and standard deviation (SD) values, the 95% confidence interval, and the minimal and maximal values. All statistical analyses were analyzed using Prism7 (GraphPad, USA). Prior to performing statistical comparisons, the normality of each data set was screened by applying the Shapiro-Wilk

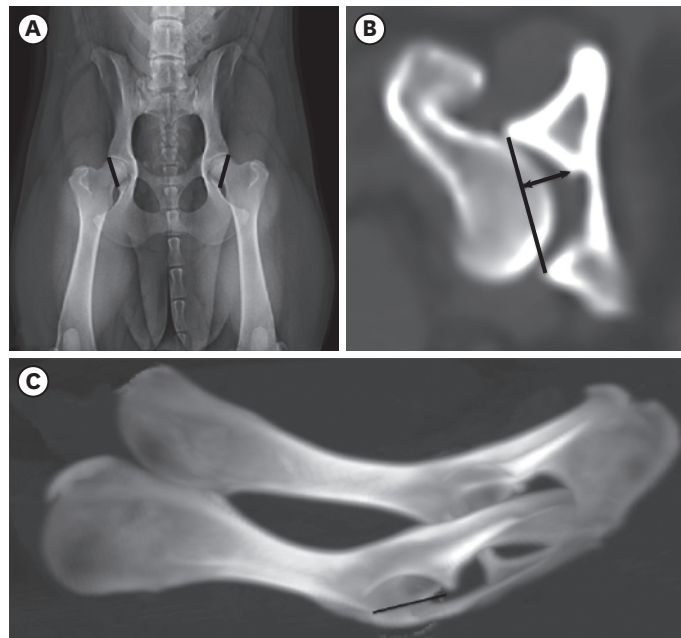


Fig. 1. Acetabular parameter measurement methods. Acetabular widths were measured in a craniocaudal direction on radiographs (A), in a craniolateral-ventrolateral direction on 2D-CT images (B), and in a craniocaudal direction on 3D-CT images (C). Acetabular depth (arrow) was measured on two-dimensional computed tomographic (CT) images (B) from the medial edge of the sourcil to the line between the lateral edge of the dorsal acetabular rim. D, dimensional; CT, computed tomography.

test. Acetabular parameters were compared between breeds, sexes, imaging modalities, and measurement planes using an unpaired T-test and one-way analysis of variance. The relationships and associations of acetabular parameters to gender, body weight, and measurement planes were assessed by examining Pearson's correlation coefficients and performing simple linear regressions. The statistical significance of a difference was significant if $p < 0.05$.

RESULTS

Clinical demographic data

A total of fourteen dogs, seven each of Maltese and Shih Tzu, were enrolled in the study. The clinical information of the enrolled dogs is summarized in **Table 1**. The Shih Tzu group had a significantly greater body weight than the Maltese group ($p = 0.0120$), and male dogs were heavier than the females, especially the Shih Tzus, although the difference was not significant (7.70 ± 1.60 and 5.60 ± 1.80 kg for male and female Shih Tzus, $p = 0.168$ and 4.05 ± 0.34 and 3.66 ± 0.41 kg for male and female Maltese, $p = 0.2165$).

Acetabular parameters

Acetabular parameters of the two dog breeds, including AW, AD and AI, for the right and left limbs and for gender, as obtained by radiography and CT, are shown in **Tables 2** and **3**, respectively. The AWs obtained by radiography, 2D-CT, and 3D-CT, and AD, were significantly greater in Shih Tzu than in Maltese ($p < 0.001$ for radiographic AW, $p < 0.001$ for 2D-CT AW, $p < 0.001$ for 3D-CT AW, and $p < 0.001$ for 2D-CT AD; **Fig. 2A**). However, AI values of the Maltese and Shih Tzu dogs were not significantly different ($p = 0.172$; $31.42 \pm$

1.35 [29.17 – 33.33] and 32.60 ± 1.80 [30.35 – 36.25], respectively) (**Fig. 2B**). Considering gender, male Shih Tzu had significantly higher values of all parameters than those for female Shih Tzus ($p = 0.009$ for radiographic AW, $p = 0.009$ for 2D-CT AW, $p = 0.022$ for 3D-CT AW

Table 1. Clinical demographic information of dogs included in this study

Clinical features	Value
Age (yr)	
All dogs	
Mean	5.07 ± 3.60
Median	4.00
Range	(2.00–13.00)
Maltese	
Mean	3.86 ± 1.68
Median	3.00
Range	(2.00–7.00)
Shih Tzu	
Mean	6.29 ± 4.68
Median	4.00
Range	(2.00–13.00)
Body weight (kg)	
All dogs	
Mean	5.31 ± 1.94
Median	4.00
Range	(3.20–9.00)
Maltese	
Mean	3.89 ± 0.40
Median	4.00
Range	(3.20–4.40)
Shih Tzu	
Mean	6.73 ± 1.81
Median	7.00
Range	(3.90–9.00)
Sex (number of dogs)	
All dogs	
Female	
Total	6
Intact	6
Neutered	0
Male	
Total	8
Intact	7
Neutered	1
Maltese	
Female	
Total	3
Intact	3
Neutered	0
Male	
Total	4
Intact	4
Neutered	0
Shih Tzu	
Female	
Total	3
Intact	3
Neutered	0
Male	
Total	4
Intact	3
Neutered	1

Acetabular index in Maltese and Shih Tzu

Table 2. Acetabular parameter values for Rt and Lt side acetabula in Maltese and Shih Tzu dogs

Acetabular parameter	Breed	Mean ± SD		Median		95% CI		Range		
		Rt	Lt	Rt	Lt	Rt	Lt	Rt	Lt	
AW (cm)	Radiograph	Maltese	1.01 ± 0.08	1.01 ± 0.10	1.01	1.03	0.94–1.09	0.91–1.09	0.88–1.13	0.90–1.18
		Shih Tzu	1.38 ± 0.23	1.38 ± 0.22	1.31	1.24	1.17–1.59	1.18–1.59	1.14–1.76	1.20–1.77
2D-CT	Maltese	1.16 ± 0.07	1.16 ± 0.07	1.17	1.18	1.10–1.23	1.09–1.23	1.08–1.25	1.07–1.28	
		Shih Tzu	1.44 ± 0.15	1.42 ± 0.12	1.41	1.39	1.31–1.58	1.31–1.53	1.25–1.68	1.28–1.58
3D-CT	Maltese	1.04 ± 0.07	1.05 ± 0.07	1.03	1.03	0.98–1.11	0.98–1.10	0.94–1.15	0.94–1.14	
		Shih Tzu	1.37 ± 0.17	1.36 ± 0.18	1.34	1.32	1.21–1.52	1.20–1.53	1.14–1.62	1.17–1.64
AD (cm)	Maltese	0.36 ± 0.02	0.36 ± 0.02	0.36	0.36	0.34–0.38	0.34–0.38	0.32–0.39	0.32–0.39	
		Shih Tzu	0.47 ± 0.06	0.47 ± 0.05	0.44	0.46	0.43–0.53	0.42–0.52	0.41–0.58	0.40–0.57
AI	Maltese	31.49 ± 1.54	31.35 ± 1.24	32.23	31.81	30.97–32.92	30.20–32.49	29.51–33.33	29.17–32.50	
		Shih Tzu	32.32 ± 0.72	32.88 ± 0.68	31.65	32.33	30.56–34.08	31.22–3	30.35–36.25	31.21–36.08

Rt, right; Lt, left; AW, acetabular width; AD, acetabular depth; AI, acetabular index.

Table 3. Acetabular parameter values for female and male Maltese and Shih Tzu dogs

Acetabular parameter	Breed	Mean ± SD		Median		95% CI		Range		
		Female	Male	Female	Male	Female	Male	Female	Male	
AW (cm)	Radiograph	Maltese	0.97 ± 0.02	1.04 ± 0.04	0.99	1.05	0.92–1.02	0.95–1.12	0.90–1.01	0.88–1.18
		Shih Tzu	1.22 ± 0.06	1.50 ± 0.21	1.22	1.51	1.16–1.28	1.32–1.68	1.14–1.31	1.21–1.77
2D-CT	Maltese	1.11 ± 0.02	1.20 ± 0.02	1.01	1.03	1.06–1.16	1.15–1.25	1.07–1.18	1.00–1.28	
		Shih Tzu	1.34 ± 0.06	1.50 ± 0.12	1.35	1.50	1.27–1.40	1.40–1.60	1.25–1.41	1.36–1.68
3D-CT	Maltese	1.02 ± 0.03	1.06 ± 0.02	1.01	1.05	0.94–1.10	1.01–1.11	0.94–1.12	0.99–1.15	
		Shih Tzu	1.25 ± 0.08	1.45 ± 0.17	1.28	1.48	1.17–1.34	1.31–1.59	1.14–1.34	1.21–1.64
AD (cm)	Maltese	0.35 ± 0.01	0.37 ± 0.01	0.36	0.36	0.32–0.38	0.35–0.38	0.32–0.38	0.35–0.39	
		Shih Tzu	0.43 ± 0.01	0.50 ± 0.02	0.43	0.49	0.41–0.44	0.46–0.54	0.40–0.44	0.44–0.58
AI	Maltese	32.21 ± 0.34	30.83 ± 0.49	32.34	30.59	31.33–33.09	29.67–31.99	30.84–33.33	29.17–32.50	
		Shih Tzu	31.81 ± 0.63	33.19 ± 2.19	32.36	32.01	31.15–32.47	31.37–35.02	31.21–32.80	30.35–36.25

CI, confidence interval; AW, acetabular width; AD, acetabular depth; AI, acetabular index.

and $p = 0.006$ for 2D-CT AD; **Fig. 3A**). However, most parameters were comparable between male and female Maltese ($p = 0.186$ for radiographic AW, $p = 0.275$ for 3D-CT AW, and $p = 0.230$ for 2D-CT AD), the exception being for 2D-CT AW ($p = 0.012$) (**Fig. 3B**). Furthermore,

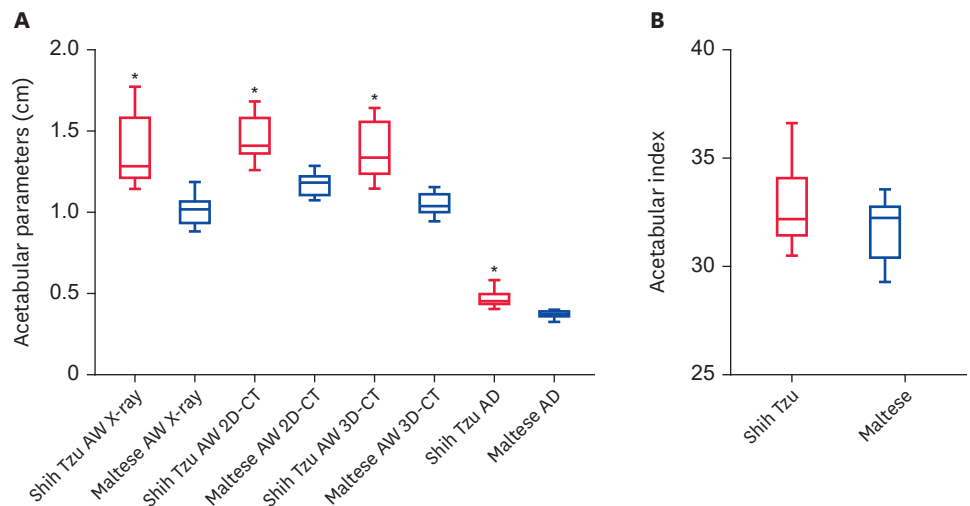


Fig. 2. Box and whisker plots of all acetabular parameters including radiographic AW X-ray (A), AW 2D-CT (A), AW 3D-CT (A), AD (A) and AI (B) of Shih Tzu and Maltese dogs. AW, acetabular width; D, dimensional; CT, computed tomography; AD, acetabular depth.

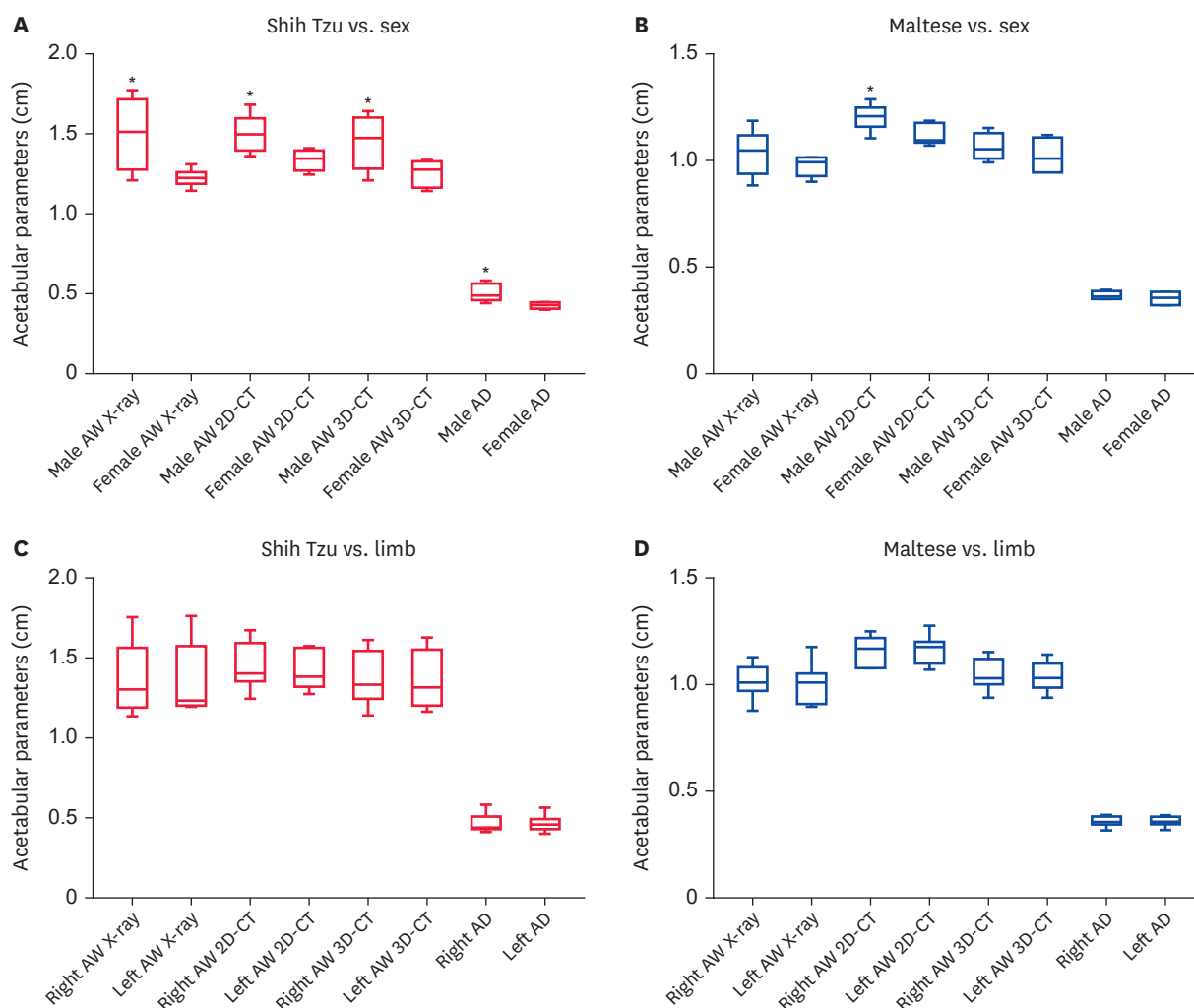


Fig. 3. Box and whisker plots of all acetabular parameters including radiographic AW X-ray, AW 2D-CT, AW 3D-CT, and AD for sex (A and B) and limb side (C and D) of Shih Tzu (A and C) and Maltese (B and C) dogs.

AW, acetabular width; D, dimensional; CT, computed tomography; AD, acetabular depth.

the parameters obtained for limbs from each side were not significantly different in either Maltese and Shih Tzu dogs ($p > 0.99$ for all parameters comparing the two sides on radiography and CT; **Fig. 3C and D**).

AWs of the two breeds obtained by radiography and 3D-CT were not significantly different ($p = 0.817$ for Maltese and $p = 0.985$ for Shih Tzu). However, both radiographic AW and 3D-CT AWs were significantly different from the 2D-CT AW in Maltese (radiographic AW vs. 2D-CT AW, $p = 0.004$ and 3D-CT AW vs. 2D-CT AW, $p = 0.024$) while those in Shih Tzu were comparable (radiographic AW vs. 2D-CT AW, $p = 0.862$ and 3D-CT AW vs. 2D-CT AW, $p = 0.775$).

Relationships between acetabular parameters and clinical information

The correlation coefficients between body weight and acetabular values in all dogs of both breeds are shown in **Fig. 4**. Body weight was strongly positively correlated with radiographic AW (**Fig. 4A**; $r = 0.860$, $p < 0.001$), 2D-CT AW (**Fig. 4C**; $r = 0.915$, $p < 0.001$), 3D-CT AW (**Fig. 4E**; $r = 0.904$, $p < 0.001$), and 2D-CT AD (**Fig. 4G**; $r = 0.883$, $p < 0.001$). In contrast, there were no significant correlations between age and acetabular parameters: radiographic AW (**Fig. 4B**; $r = 0.033$, $p =$

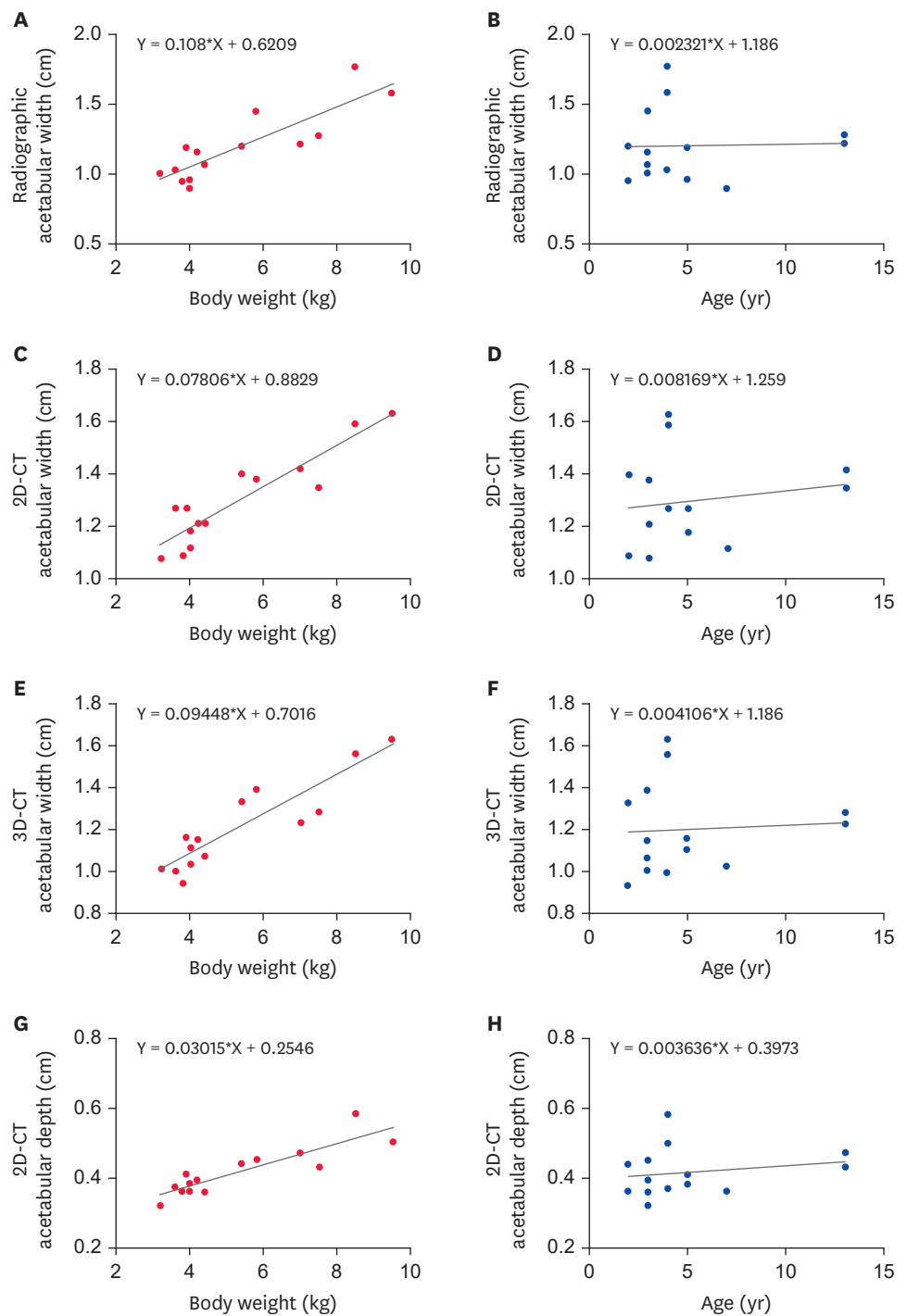


Fig. 4. Correlations of body weight and age in all Maltese and Shih Tzu dogs with acetabular parameters such as acetabular width on radiograph (A and B), 2D-CT images (C and D), 3D-CT images (E and F), and acetabular depth on 2D-CT images (G and H). AW, acetabular width; D, dimensional; CT, computed tomography; AD, acetabular depth.

0.911), 2D-CT AW (**Fig. 4D**; $r = 0.171$, $p = 0.558$), 3D-CT AW (**Fig. 4F**; $r = 0.070$, $p = 0.811$), and 2D-CT AD (**Fig. 4H**; $r = 0.191$, $p = 0.514$). Moreover, no significant correlations between AI and body weight or age were detected (**Fig. 5A**; $r = 0.373$, $p = 0.190$, **Fig. 5B**; $r = 0.140$, $p = 0.632$).

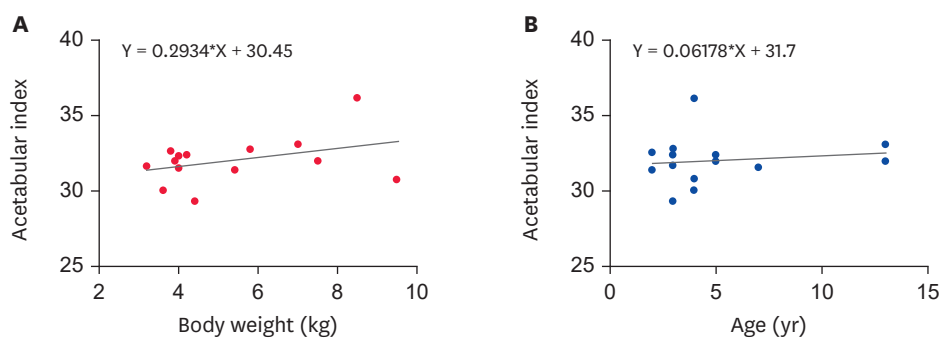


Fig. 5. Correlations between AI and body weight (A) or age (B). AI, acetabular index.

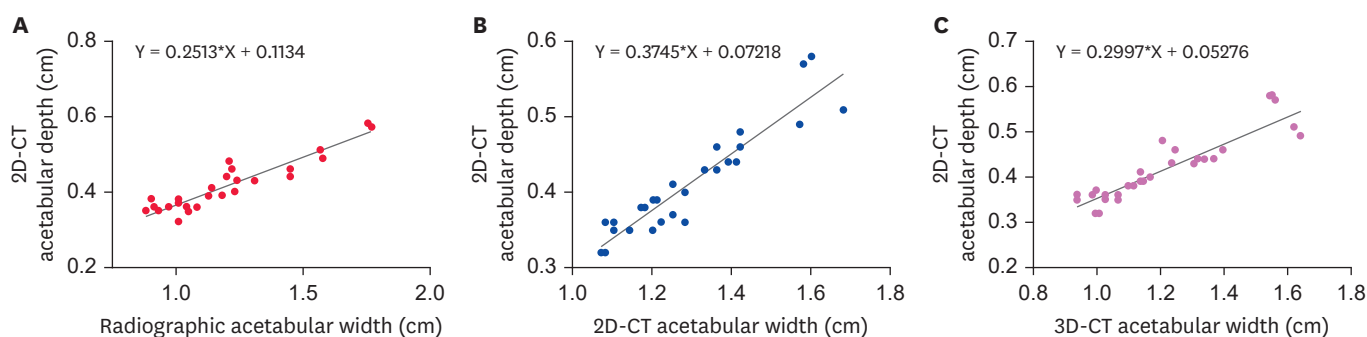


Fig. 6. Correlations between acetabular depth and acetabular width measured on radiographs (A), 2D-CT images (B), and 3D-CT images (C). D, dimensional; CT, computed tomography.

The correlation coefficients between AD and AW in all dogs are shown in **Fig. 6**. There were strong positive correlations between 2D-CT AD and radiographic AW (**Fig. 6A**; $r = 0.876$, $p < 0.001$), between 2D-CT AD and 2D-CT AW (**Fig. 6B**; $r = 0.930$, $p < 0.001$), and between 2D-CT AD and 3D-CT AW (**Fig. 6C**; $r = 0.922$, $P < 0.001$).

DISCUSSION

Diseases of the hip joint are one of the most common orthopedic problems in large-breed dogs. However, small-breed dogs and cats are also affected with conditions such as femoral head fracture, femoral luxation [10], Legg-Calve-Perthes disease [2], and CHD [11]. These problems can affect hip anatomy and interfere with the biomechanics of the hip joint [12]. Surgical correction, such as FHNO, is a predominant treatment choice, but it is associated with several complications [4,10]. THR is an alternative technique to correct hip abnormalities as it can provide good quality of life and improves hip-joint functions [5]. In humans, there is a narrow range for the selection of acetabular components in THR [12], and ethnicity, gender, and age can affect that selection [13]. THR failures have also occurred due to improper implantation or malposition of acetabular components. Recently, there is great interest in the design of prostheses that can reduce the risk of complications [7]. Acetabular parameters have been a main interest focus because of their important role when fitting acetabular components. To obtain accurate acetabular information, measurements from imaging modalities such as radiography, CT, and MRI are used. Radiography is commonly used to diagnose bone problems, but it has accuracy limitations [7]. CT and MRI are advanced imaging modalities routinely used in humans and are increasingly being used

in animals. CT is a good technique to achieve precise acetabular parameter measurements because it can be shown trigonometrically [7]. Therefore, CT can aid in surgical treatments [14] and can lead to successful outcomes. However, the assessment of acetabular parameters in small-breed dogs has not previously been described. Thus, this study is the first to present CT-based acetabular parameter results for small-breed dogs.

In this study, the results were obtained from two different small dog breeds: Maltese and Shih Tzu. Previous reports mostly used large-breed dogs, such as hounds [9], Labrador Retrievers [7], and Sivas Kangals [3]. In humans, it has been found that differences in hip morphometry can be detected in different human ethnic groups; for example, Mongoloids and Caucasoids have significantly different AD values [15]. A previous report on large-breed dogs described variations in acetabular anatomy among various breeds; St. Bernard and Bernese Mountain dogs had the largest acetabula, while Labrador Retrievers and Boxers had the shallowest and widest acetabula [16]. In our study, Shih Tzu had larger acetabulum depth and width than those of Maltese. Therefore, differences among races and breeds influence acetabular parameters. Thus, surgeons should use breed-specific acetabular values during surgical planning and when designing a THR.

Furthermore, gender and body weight have also been shown to be important factors affecting acetabular parameter measurements. Previous reports found that human males have higher acetabular parameter measurements than those of human females [1,12]. Likewise, the gender of the dogs in this study was a factor affecting acetabular parameter measurements, such as radiographic AW, 2D-CT AW, 3D-CT AW and 2D-CT AD, especially in Shih Tzus, and 2D-CT AW in Maltese. Similar relationships were observed between body weight and AW and AD but not with body weight and AI. Acetabulum size in various dimensions was dependent on body size and sex, especially in Shih Tzu. Surprisingly, breed, gender, and body weight did not show any significant effects on AI. Therefore, due to the similarity in AI values in the two dog breeds, it may be assumed that both dog breeds have similarly shaped acetabula. This assumption is corroborated by the correlation between AW and AD values.

Interestingly, the acetabular parameters of Maltese and Shih Tzu hip joints were not significantly different between the right and left sides, indicating an advantage of using images of the contralateral acetabulum if the ipsilateral acetabulum is abnormal. In such cases, the normal side can be used as a guide for assessing the acetabular parameters of the abnormal side [13]. Dog age had no significant effect on acetabular parameters in this study. However, several studies in humans and large-breed dogs revealed that age was an important factor when estimating acetabular parameters. This inconsistency might be due to the small sample number in the present study. Cay et al. [1] found that the AD of elder Serbians (mean age 58.41 years) was larger than that of Malay adults (21–25 years). In hounds, increased age was related to decreased AI [9]. Therefore, further studies investigating large numbers of small-breed dogs over a wide age range should be undertaken.

Generally, radiography is the basic modality of choice to estimate acetabular parameters. However, pelvic tilt and improper X-ray beam direction can interfere with the measurement of acetabular parameters on radiographs [7]. The acetabular measurements based on radiography in this study were collected by using well-controlled subject positioning and a calibrated ball. Therefore, the radiographic results from this study may show fewer measurement inaccuracies. In contrast, CT provides fewer limitations related to interfering factors due to the ability to construct 3D images and its better image acquisition qualities

[7,17]. The scanning procedure for each dog during the CT examination in this study differed from those in previous reports [7,14]. The current study used mechanical restraint instead of sedation, which eliminates the risk of anesthetic complications. Compared to other parts of the body, such as the head, neck, or thoracic cavity, motion artifacts for the caudal limbs were low in this study. In addition, even with mechanical restraint and no anesthesia, the results for AI by CT imaging can be reliable due to the volumetric data that can be reconstructed and evaluated in different planes. Radiographic measurements of AW were not significantly different from those derived by 3D-CT on the same plane. CT provides better image acquisition and allows 3D reconstruction, providing greater structural surface information than that obtained by radiography. Regardless, our results indicate that the radiographic measurement of AW can be used instead of those obtained by CT. In addition, by comparing AWs measured in the craniocaudal direction by radiography, those from 3D-CT, and those measured in the transverse plane by 2D-CT, it was observed that AW in the two CT planes were significantly different in Maltese but not in Shih Tzu dogs. Therefore, it can be assumed that the acetabulum of the Shih Tzu represents a true hemisphere, in contrast to that in the Maltese. This evidence concerning Maltese dogs is similar to that from a previous study, which concluded that the normal acetabulum in dogs is not hemispherical [18]. However, due to the discrepancy of results between breeds, further study on various small breeds could further elucidate this issue. Furthermore, the Maltese data contrasts that of the human acetabulum, which is hemispherical in appearance [19]. It is possible that the acetabular characteristics are specific to species and breeds. This should be borne in mind when using acetabular information obtained from different planes and breeds during diagnosis or when designing a prosthesis or planning a THR.

In humans, AD is an important parameter that can indicate hip dysplasia (HD) [1]. Human HD is considered present when AD is below 9 mm [15]. However, different values were reported in Serbian people, whose normal AD should be 22.01 and 26.47 mm in men and women, respectively [1]. Thus, AD can depend on ethnicity, age, gender, and individual. However, AD is less often mentioned in canine studies. Only one study into the relative depth of the acetabulum in various large-breed dogs has been reported in the last few decades [16]. To date, references to AD seem to be connected with the calculation of AI, which is the ratio of AD and AW from 2D-CT images. AI, if decreased, can encourage practitioners to predict OA in dogs and HD in human patients [9,14,17]. In hounds, AI is 31.22 ± 4.23 [9], similar to those in the current study; the average AI in the Maltese was 31.42 ± 1.35 , and in the Shih Tzu was 32.60 ± 1.80 .

The assessment of correlations between AD and other acetabular parameters demonstrated that 2D-CT AD had a statistically positive correlation with radiographic AW, 2D-CT AW, and 3D-CT AW, implying that AW, whether by radiography or CT, can be used to estimate AD. This is similar to results in a human study that compared acetabular diameter to depth and showed significant positive correlations between the factors in both males and females [1]. However, this is the first report of the association between AW and AD in small-breed dogs. This information could be advantageous when estimating the AD from radiographic AW in clinical practices in which CT is unavailable.

There were limitations in this study related to the small number of dogs, which resulted from limitations imposed by ethical regulations on the use of animals for research. Moreover, the small number of breeds in the study limited our assessment of inter-breed variations. Therefore, comparing the acetabular parameters among dogs of different breeds and pelvis

characteristics, including assessments of normal and OA-affected small-breed dogs, should provide further clinically useful information.

In conclusion, radiographic AW, 2D-CT AW, 3D-CT AW and 2D-CT AD measurements were influenced by breed, gender, and body weight, but not by age, in Maltese and Shih Tzu small-breed dog models. The different imaging tools and techniques provided differing acetabular values, especially in the Maltese dogs. In addition, AI was the only value that was not dependent on any of the tested factors. Thus, AI could be helpful in detecting hip abnormality or selecting surgical prosthesis such as that required for THR.

REFERENCES

1. Cay M, Senol D, Canbolat M, Yildirim IO, Kose E, Ozbag D. Comparison of diameter and depth morphometry in human acetabulum in terms of age and gender: a radiological study. *J Human Anat.* 2017;1(2):000109.
2. Jankovits DA, Liska WD, Kalis RH. Treatment of avascular necrosis of the femoral head in small dogs with micro total hip replacement. *Vet Surg.* 2012;41(1):143-147.
[PUBMED](#) | [CROSSREF](#)
3. Sarierler M, Tatli ZB, Akin I, Yaygingül R, Derincegöz OÖ. Radiographic examination of hip joint geometry in healthy Sivas Kangal dogs. *Turk J Vet Anim Sci.* 2017;41(1):85-92.
[CROSSREF](#)
4. Off W, Matis U. Excision arthroplasty of the hip joint in dogs and cats. Clinical, radiographic, and gait analysis findings from the Department of Surgery, Veterinary Faculty of the Ludwig-Maximilians-University of Munich, Germany. 1997. *Vet Comp Orthop Traumatol.* 2010;23(5):297-305.
[PUBMED](#)
5. Heo SY, Seol JW, Lee HB. Total hip replacement in two dogs with unsuccessful femoral head ostectomy. *J Vet Sci.* 2015;16(1):131-134.
[PUBMED](#) | [CROSSREF](#)
6. Torres BT, Budsberg SC. Revision of cemented total hip arthroplasty with cementless components in three dogs. *Vet Surg.* 2009;38(1):81-86.
[PUBMED](#) | [CROSSREF](#)
7. Wu CH, Lin CC, Lu TW, Yeh LS. Three-dimensional morphometry of native acetabulum in relation to design and implantation of canine total hip replacements. *Biomed Eng Appl Basis Commun.* 2012;24(6):549-555.
[CROSSREF](#)
8. Martins J, Colaço B, Alves-Pimenta S, Ferreira A, Ginja M. Effects of pelvis rotation on the projected radiographic position of the femoral head in relationship to the acetabulum. *Vet Med (Praha).* 2017;62(7):377-385.
[CROSSREF](#)
9. Andronesu AA, Kelly L, Kearney MT, Lopez MJ. Associations between early radiographic and computed tomographic measures and canine hip joint osteoarthritis at maturity. *Am J Vet Res.* 2015;76(1):19-27.
[PUBMED](#) | [CROSSREF](#)
10. Liska WD. Micro total hip replacement for dogs and cats: surgical technique and outcomes. *Vet Surg.* 2010;39(7):797-810.
[PUBMED](#) | [CROSSREF](#)
11. Arnbjerg J. Hip joint laxity in small dog breeds; a radiological study. *SOJ Vet Sci.* 2017;3(1):1-5.
[CROSSREF](#)
12. Arsić S, Ilić D, Mitković M, Tufegdžić M, Janković S, Trajanović M. The study of morphological parameters of human acetabulum significant for hip arthroplasty. *The 2nd International Conference, Mechanical Engineering in XXI century.* 2013, 115-120.
13. Zeng Y, Wang Y, Zhu Z, Tang T, Dai K, Qiu S. Differences in acetabular morphology related to side and sex in a Chinese population. *J Anat.* 2012;220(3):256-262.
[PUBMED](#) | [CROSSREF](#)
14. Lopez MJ, Lewis BP, Swaab ME, Markel MD. Relationships among measurements obtained by use of computed tomography and radiography and scores of cartilage microdamage in hip joints with moderate to severe joint laxity of adult dogs. *Am J Vet Res.* 2008;69(3):362-370.
[PUBMED](#) | [CROSSREF](#)

15. Saikia KC, Bhuyan SK, Rongphar R. Anthropometric study of the hip joint in northeastern region population with computed tomography scan. *Indian J Orthop.* 2008;42(3):260-266.
[PUBMED](#) | [CROSSREF](#)
16. Scartazzini R. A radiologic study of normal and dysplastic hip joints in six breeds of large dogs. *Acta Radiol Suppl.* 1972;319:183-185.
[PUBMED](#) | [CROSSREF](#)
17. Schachner ER, Lopez MJ. Diagnosis, prevention, and management of canine hip dysplasia: a review. *Vet Med (Auckl)* 2015;6:181-192.
[PUBMED](#)
18. Montgomery ML, Kim SE, Dyce J, Pozzi A. The effect of dorsal rim loss on the initial stability of the BioMedtrix cementless acetabular cup. *BMC Vet Res.* 2015;11(1):68.
[PUBMED](#) | [CROSSREF](#)
19. Dhindsa G. Acetabulum: a morphometric study. *J Evol Med Dental Sci.* 2013;2(7):657-665.
[CROSSREF](#)