



Total shoulder arthroplasty outcomes after noncorrective, concentric reaming of B2 glenoids

W. Jeffrey Grantham, MD ^a, Travis J. Dekker, MD ^a, Lucca Lacheta, MD ^{b,c},
Marilee P. Horan, MPH ^b, Brandon T. Goldenberg, MD ^b, Bryant P. Elrick, MSc ^b,
Peter J. Millett, MD, MSc ^{a,*}

^a The Steadman Clinic, Vail, CO, USA

^b Steadman Philippon Research Institute, Vail, CO, USA

^c Center for Musculoskeletal Surgery, Charité Universitaetsmedizin Berlin, Berlin, Germany

ARTICLE INFO

Keywords:

Total shoulder arthroplasty
biconcave glenoids (B2) glenoids
outcomes
survivorship

Level of Evidence: Level IV; Case Series;
Treatment Study

Background: Total shoulder arthroplasty (TSA) is an effective procedure for the treatment of glenohumeral osteoarthritis (GHOA) delivering reliable pain relief and improved shoulder function. Abnormal glenoid morphologies are common, and biconcave glenoids are enigmas that have been associated with poor clinical outcomes and implant survivorship.

Purpose: To assess the clinical outcome scores of patients who underwent noncorrective, concentric reaming for TSA with biconcave glenoids (B2). We hypothesized that patients with B2 glenoids who underwent TSA with glenoid implantation using noncorrective, concentric reaming would have significant improvements in clinical outcome scores and high implant survivorship.

Methods: All patients who underwent anatomic TSA for GHOA with B2 glenoids, performed by a single surgeon, between July 2006 and December 2015 with minimum 2-year follow-up were reviewed. Walch classification was obtained from preoperative imaging (magnetic resonance imaging or computed tomography). Clinical outcome scores were prospectively collected and included American Shoulder and Elbow Surgeons Standardized Shoulder Assessment Form (ASES) score, Single Assessment Numerical Evaluation (SANE) score, Quick Disabilities of the Arm, Shoulder, and Hand (QuickDASH) score, 12-Item Short Form Health Survey physical component summary (PCS), and patient satisfaction. Clinical failures (revision TSA surgery or conversion to reverse TSA) and complications were reported. Paired *t* test and bivariate correlations level of significance was set at $P = .05$. Survivorship analysis with implant failure as an endpoint was done using Kaplan-Meier survival curves.

Results: 51 TSA in 49 patients (9 females, 40 males) with primary GHOA with B2 glenoids were performed with a mean age of 64 (range 36–81 years) at the time of surgery. The mean retroversion was 19.1° (range 5.4° – 38°), and posterior decentring was 42.0% (range 19.4%–78.5%). At final evaluation, 45/51 anatomic TSAs (88% follow-up) with a mean follow-up of 4.9 years (range 2.0–10.4 years) were assessed. All clinical outcome scores improved significantly pre- to postoperatively: ASES, 52.5 to 79.6 ($P < .001$); SANE, 52.4 to 74.7 ($P < .001$); QuickDASH, 39.2 to 19.1 ($P = .001$); and PCS, 40.9 to 48.9 ($P = .001$). Median postoperative satisfaction was 9 (range 1–10). There were 2 failures and 4 that required another surgery —subscapularis repair, lysis of adhesions, irrigation and débridement, and one to explore the status of the subscapularis for persistent pain. The implant survivorship rate was 95% at a mean follow-up of 4.9 years.

Conclusion: Anatomic total shoulder replacement with minimally noncorrective, concentric reaming in patients with B2 glenoids had significant improvement in clinical outcome scores, high patient satisfaction, and high survivorship in this cohort.

© 2020 The Author(s). Published by Elsevier Inc. on behalf of American Shoulder and Elbow Surgeons. This is an open access article under the CC BY-NC-ND license (<http://creativecommons.org/licenses/by-nc-nd/4.0/>).

Disclaimer: This work was supported directly by outside funding from Arthrex, Inc. W. Jeffrey Grantham, Travis J. Dekker, Marilee P. Horan, Brandon T. Goldenberg, and Bryant P. Elrick received research support from the Steadman Philippon Research Institute, which is a 501(c)(3) nonprofit institution supported financially by private donations and corporate support from the following entities: Smith & Nephew, Inc., Arthrex, Inc., Siemens, and Ossur Americas, Inc.

Lucca Lacheta had his research position at the Steadman Philippon Research Institute funded by Arthrex, Inc.

Peter J. Millett receives royalties and consultant payments from Arthrex, Inc., Medbridge, and Springer Publishing, which is not related to the subject of this work; he has stock in VuMedi.

This research project was deemed to be exempt from IRB requirements by Vail Health Hospital Institutional Review Board (no. 2019-55).

* Corresponding author: Peter J. Millett, MD, MSc, The Steadman Clinic, 181 West Meadow Drive, Vail, CO 81657, USA.

E-mail address: drmillett@thesteadmanclinic.com (P.J. Millett).

<https://doi.org/10.1016/j.jseint.2020.04.006>

2666-6383/© 2020 The Author(s). Published by Elsevier Inc. on behalf of American Shoulder and Elbow Surgeons. This is an open access article under the CC BY-NC-ND license (<http://creativecommons.org/licenses/by-nc-nd/4.0/>).

Total shoulder arthroplasty (TSA) is a common and reliable procedure to improve pain and function for patients with glenohumeral osteoarthritis (GHOA). However, several factors have been associated with less than optimal results, including posterior humeral head decentering, excessive glenoid retroversion, and posterior glenoid bone loss.¹⁰ The biconcave glenoid, Walch classification B2,²⁶ may encompass all 3 of these factors and thus presents a challenge for surgeons, with mixed outcomes reported.¹⁴ Currently, there are several options to help address glenoid deformity, but there is still a lot of debate about the best method to maximize the longevity of the implant and patient outcomes.

Presently, surgical options include hemiarthroplasty, corrective glenoid reaming, posterior implant augmentation, bone grafting, and reverse shoulder arthroplasty. Each of these procedures has different benefits and risks. One of the proposed methods is non-corrective, concentric reaming of the glenoid (eccentrically reaming more anterior bone) to produce a smooth surface that is concentric with the new glenoid implant. This technique allows for standard glenoid component implantation technique and avoids corrective reaming, which sometimes necessitates going into the softer subchondral bone. The purpose of this study is to analyze the midterm outcomes of TSA with minimal noncorrective, concentric reaming of B2 glenoids.

Materials and methods

After receiving approval from the institutional review board, all consecutive patients who underwent anatomic TSA by the senior surgeon (PJM) between July 2006 and December 2015 were identified. Patients with Walch B2 glenoids were identified for inclusion by preoperative radiographs and advanced imaging modalities (computed tomography [CT] or magnetic resonance imaging). Inclusion criteria consisted of patients who received anatomic TSA with minimal noncorrective, concentric reaming without bone grafting or posterior augmentation for GHOA with B2 glenoids and a minimum of 2-year follow-up.

Preoperative advanced imaging (CT or magnetic resonance imaging) was used to measure glenoid retroversion, glenoid inclination, and humeral head decentering (Figs. 1 and 2).^{4,5,11} Prospectively collected clinical outcome scores were retrospectively reviewed including American Shoulder and Elbow Surgeons Standardized Shoulder Assessment Form score,²⁰ Single Assessment Numerical Evaluation score,³⁰ Quick Disabilities of the Arm, Shoulder and Hand score,⁹ 12-Item Short Form Health Survey physical component summary,²⁸ and patient satisfaction (rated 0–10, with 0 being very unsatisfied and 10 being very satisfied). Clinical failures (revision TSA surgery or reverse TSA) and complications were reported.

Surgical technique

All surgeries used a standard anatomic TSA implant (Apex or Uniers 2; Arthrex, Inc., Naples, FL, USA or Aequalis; Tornier, Inc., Edina, MN, USA or Anatomical Shoulder; Zimmer Biomet, Warsaw, IN, USA) with an all-polyethylene, pegged, cemented glenoid implant. Surgery was performed with a combination of a peripheral nerve block and general anesthesia in the beach chair position using a pneumatic arm holder. Following a standard deltopectoral approach, the subscapularis tendon was reflected via a lesser tuberosity osteotomy. The humeral head was then exposed, osteophytes were removed, the capsule was released from both the humeral and glenoid sides, and the head was osteotomized to mimic native version.

The glenoid was then prepared with noncorrective, concentric reaming, creating a glenoid face concentric with the reamer and eliminating the B2 lip with minimal correction of the glenoid retroversion, ensuring preservation of bone stock. Care was taken to preserve the subchondral bone to optimize glenoid fixation. When a hard rim of bone remained, a small burr was used to contour the glenoid. The peg holes were then prepared. Excellent (at least 80%)¹² backside coverage of the implant was important, and the trial had to be completely stable to manual assessment prior to cementation. Excellent fit of the glenoid was confirmed to minimize risk of the rocking horse effect. The largest-size glenoid implant that would fit without overhang was chosen. If there was overhang of the component, the glenoid implant was downsized to a smaller size. The native glenoid was then irrigated with pulsatile lavage and dried. Cement was pressurized in the peg holes with a Toomey syringe (Bard Medical, Covington, GA, USA) and mechanical pressurizing instrument. Cement was also placed on the backside of the glenoid component around the pegs. The implant was impacted into place, and excess cement was removed (Fig. 3).

Afterward, the humerus was reamed to the appropriate size, and the stemmed humeral implant was inserted. Finally, the anatomic humeral head component was sized and inserted. At this point, the shoulder was reduced and tested for translation. The subscapularis and lesser tuberosity were repaired using 3 no. 5 nonabsorbable sutures passed through the lesser tuberosity bone fragment and through the humeral shaft before final seating of the humeral implant.¹⁹ The rotator interval was closed laterally with no. 2 nonabsorbable suture with the arm in 30° external rotation. The wound was then thoroughly irrigated and closed in standard layered fashion.

Postoperative rehabilitation included immediate full passive range of motion, with external rotation limited to 30° for the first 3 weeks postoperatively. A protective sling was used for 3 weeks. At 3 weeks, full active and passive ranges of motion were permitted, and the sling was discontinued. Strengthening was allowed 5–6 weeks postoperatively. After full range of motion and strength were obtained, typically 3.5–4 months postoperatively, full activities were

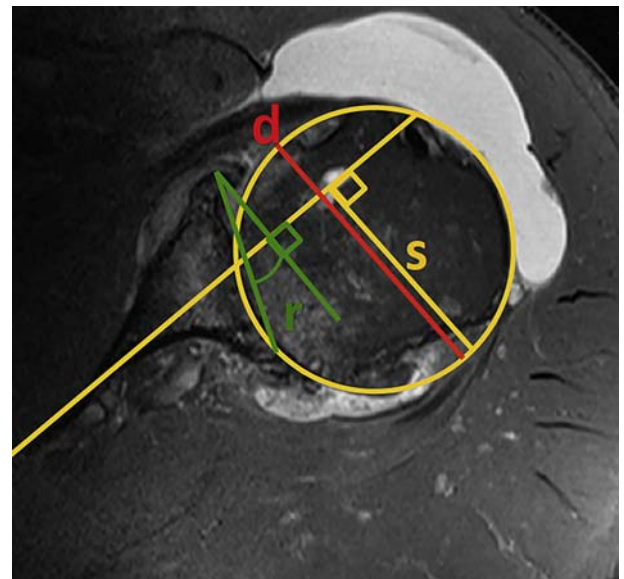


Figure 1 Axial magnetic resonance image of a preoperative B2 glenoid. The retroversion (r) was measured from a line perpendicular to the plane of the scapula (Friedman line).^{4,5} Posterior decentering compared the diameter of the humeral head to a line along the scapula axis to give a percentage of decentering ($s/d \times 100\%$).¹¹

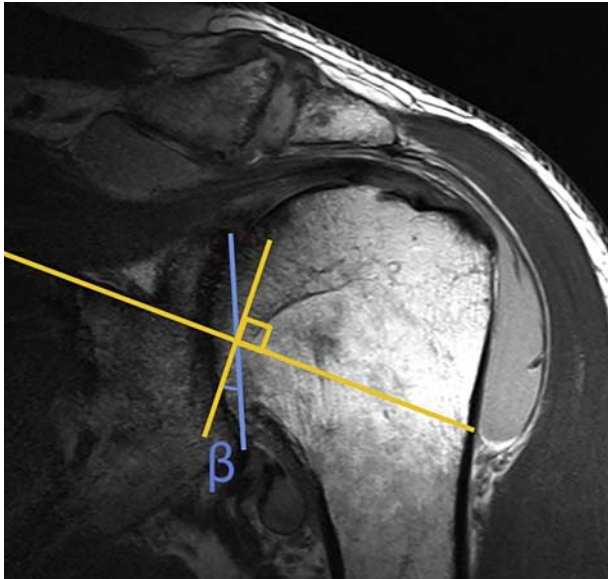


Figure 2 Coronal magnetic resonance image of a preoperative B2 glenoid. Glenoid inclination (β) was measured as the angle between a line perpendicular to the sclerotic line of the supraspinatus fossa and the glenoid fossa line.^{3,15}

permitted. No restrictions were placed on patients' recreational, work, or sporting activities after 4–6 months.¹⁶

Statistical analysis

Paired *t* test and bivariate correlations level of significance was set at *P* value equal to .05. Survivorship analysis with failure of the components requiring revision was the endpoint used for Kaplan-Meier survival curves.

Results

Fifty-one shoulders in 49 patients received a TSA with noncorrective, concentric reaming for GHOA with B2 glenoid deformity during the study period. Despite our best effort, 6 shoulders were lost to follow-up, leaving a final study population with 45 shoulders (88.2%) having follow-up greater than 2 years. The follow-up mean was 4.9 years (range 2–10.4 years). There were 35 men and 8 women (1 man and 1 woman underwent bilateral TSA for GHOA with B2 glenoids). The mean age at the time of surgery was 64.6 ± 6.9 years. Previous surgery was reported on 28 of the 45 shoulders (62.2%). The mean retroversion and inclination measured on CT or magnetic resonance imaging was $19.1^\circ \pm 7.6^\circ$ (range 5.4° – 38°) and $14.1^\circ \pm 8.2^\circ$ (range 0° – 33.3°), respectively. Posterior decentering was $42.0\% \pm 17.3\%$ (range 19.4%–78.5%).

Postoperative outcomes showed statistically significant improvement over all patient-reported outcome measures collected (Table 1). Single Assessment Numerical Evaluation scores improved from 52.4 ± 20.5 to 74.7 ± 25.6 . The 12-Item Short Form Health Survey physical component summary was 48.9 ± 9.8 postoperatively, increased from 40.9 ± 8.0 preoperatively. The Quick Disabilities of the Arm, Shoulder, and Hand likewise showed less disability following surgery (19.1 ± 16.9 vs. 39.2 ± 17.9). The American Shoulder and Elbow Surgeons Standardized Shoulder Assessment Form score improved from 52.5 ± 18.5 preoperatively to 79.6 ± 18.3 postoperatively with improvement shown in both pain and function sections (28.9 ± 12.2 to 41.2 ± 12.4 and 24.3 ± 9.8 to 39.2 ± 11.3 , respectively). When patients were asked at follow-up if they were satisfied with the surgical outcome of the shoulder, the

median score was 9 of 10. Thirty-two of 43 (74.4%) patients reported at least 7 of 10 satisfaction. On regression analysis, the degree of preoperative retroversion and percentage of decentering did not correlate with outcome scores.

Two patients (3.9%) had loose glenoids, one patient at 1 year and the other at 3 years postoperatively, and both patients required revision TSA with reimplantation of the glenoid component. Kaplan-Meier analysis showed 97.8% implant survivorship at 1 year and 94.6% at 5 years (Fig. 4). Two patients (3.9%) had postoperative instability secondary to subscapularis insufficiency and subsequently underwent revision subscapularis repair. One postoperative infection (2.0%) occurred with *Cutibacterium acnes* that necessitated surgical débridement and long-term antibiotics. One patient had adhesive capsulitis (2.0%) resistant to aggressive physical therapy, requiring arthroscopic lysis of adhesions. In total, there were 6 reoperations (11.8%).

Discussion

The most important finding of this study was that patients had significant improvements in all reported shoulder function and pain scores at mean 4.9 years' follow-up after noncorrective, concentric, and bone-preserving reaming of B2 glenoids in anatomic TSA. The change in outcome scores more importantly indicates significant clinical improvement as previously described.^{23,25,29} Although previous studies have indicated a high complication rate and less than optimal results, this study found that noncorrective, concentric reaming of a biconcave B2 glenoid to a smooth surface with bone preservation and without complete retroversion correction allowed for good clinical outcome scores and few complications. The data from this study support the hypothesis that noncorrective, concentric reaming is a reliable option for the management of B2 glenoids in patients with GHOA at midterm follow-up.

Clinical and laboratory studies have shown a relatively high risk of glenoid implant failure in patients with B2 deformities.^{2,7,22,27} The biconcavity and retroversion of the glenoid risk increased contact forces and a rocking horse phenomenon leading to early failure. When considering complete correction of a glenoid deformity of greater than 15° of retroversion cortical integrity may be compromised with significant medialization of the implant.^{2,7} In fact, glenoid reaming to restore axial plane version to less than 10° of retroversion may not actually restore the glenoid to the native glenoid version and, furthermore, may result in the new implant being seated in softer subchondral bone. However, partial correction of retroversion by Gerber et al showed good short-term clinical results with retroversion correction from 18° to 9° measured on CT.⁶ The threshold effect for retroversion may not be fully determined, and biomechanical laboratory studies may not adequately model the clinical situation where there are adaptive changes that occur in the bone and soft tissue.

Walch et al²⁷ in a study of patients who underwent TSA with B2 glenoids described a 16.3% revision rate at a mean 77 months, 6.5% for glenoid loosening and 5.5% for posterior instability. Our study had 2 revision operations for glenoid implant loosening (3.9%). Chin et al¹ had 1 revision for glenoid loosening in 37 TSAs (1.1%) done for B1 and B2 glenoids at 5 years postoperation. Furthermore, Orvets et al did not have any revisions for glenoid loosening in 59 shoulders at a mean follow-up of 50 months. They also showed low rates of radiolucency at the glenoid implant at short-term follow-up.¹⁸

There are additional concerns with the other options of TSA for patients with B2 glenoids. Bone grafting originally showed good results in 16 of 19 patients at 52.5 months, with all patients demonstrating graft healing.¹⁷ Subsequent reports, however, have shown similar results, but with increased concern for graft healing.

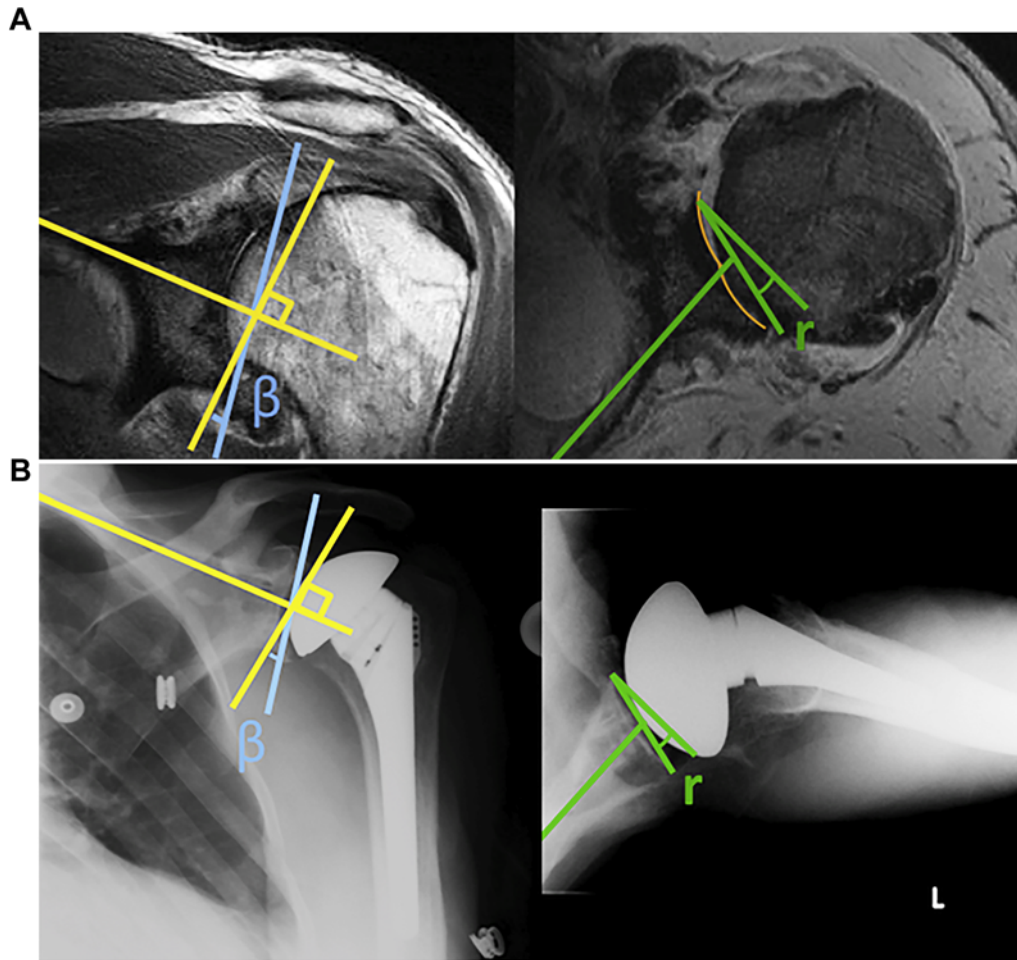


Figure 3 (A) Preoperative magnetic resonance image and (B) postoperative radiographs demonstrating the minimal noncorrective reaming technique. The anteroposterior view shows persistent glenoid inclination (β) and the axillary view demonstrates remaining retroversion (r).

Table I
Patient-reported outcome scores pre- and postoperatively

Measure	Preoperative			Postoperative			P value
	n	Mean	Standard deviation	n	Mean	Standard deviation	
SANE	31	52.4	20.5	41	74.7	25.6	<.001
SF-12 PCS	37	40.9	8.0	44	48.9	9.8	.001
ASES Total	33	52.5	18.5	42	79.6	18.3	<.001
ASES Pain	39	28.9	12.2	42	41.2	12.4	<.001
ASES Function	33	24.3	9.8	40	39.2	11.3	<.001
QuickDASH	31	39.2	17.9	44	19.1	16.9	.001
Satisfaction				45	Median 9		

SANE, Single Assessment Numerical Evaluation; SF-12 PCS, 12-Item Short Form Health Survey physical component summary; ASES, American Shoulder and Elbow Surgeons Standardized Shoulder Assessment Form; QuickDASH, Quick Disabilities of the Arm, Shoulder, and Hand.

Steinmann and Cofield²⁴ had 3 loose glenoids (10.7%) despite good results in 82% of patients at 63 months. Minor graft resorption (16.7%) and 2 with broken screws (16.7%) were noted by Sabesan et al²¹ despite 10 of 12 patients with complete graft incorporation without resorption. Klika et al¹³ found that 6 of 25 glenoid components shifted, and resorption of the bone graft occurred in 6 shoulders.

When addressing the posterior bone loss with an augmented implant, mixed outcomes have been reported. The original metal-backed implants have shown a 31% survivorship at 10 years, but more recently satisfactory results have been shown in 71 shoulders by Ho et al⁸ at 2.4 years with no revisions.

This large case series critically evaluated patient-reported outcomes following minimally corrective, concentric reaming of the glenoid for B2 glenoids. With mean retroversion of 19.1° and a maximum of 38°, these patients represent glenoids with moderate deformities. A strength of this study is that all TSAs were performed with similar surgical technique with the same implant by the senior surgeon to limit confounding variables. This study is limited by its retrospective review of prospectively collected data. Furthermore, there are no comparison groups that would best delineate the optimal surgical technique in patients with B2 glenoid deformity. Additionally, although the mean follow-up was 4.9 years, long-term follow-up is needed to determine the true longevity of the TSA

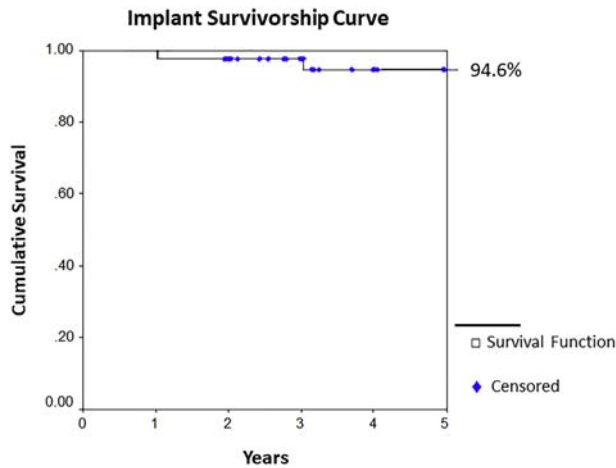


Figure 4 Kaplan-Meier implant survivorship curve.

components. We did not obtain postoperative 3D imaging so the degree of correction cannot be quantified. Finally, this study did not look at radiographic lucency as a measure of survivorship, as the primary outcome of concern was patient function and satisfaction and not the appearance of the implant. Other studies have reported rates of radiographic lucency with this surgical technique without establishing its impact at this time of follow-up.^{1,18} The primary goal of this study was to identify any clinical improvement in patients with B2 glenoids who underwent minimal corrective reaming at a mean of 4.9 years.

Conclusion

Anatomic TSA with noncorrective, concentric reaming of B2 glenoid deformity offers good clinical results, high patient satisfaction, and high survivorship at a mean 4.9-year follow-up.

References

- Chin PC, Hachadorian ME, Pulido PA, Munro ML, Meric G, Hoenecke HR Jr. Outcomes of anatomic shoulder arthroplasty in primary osteoarthritis in type B glenoids. *J Shoulder Elbow Surg* 2015;24:1888–93. <https://doi.org/10.1016/j.jse.2015.05.052>.
- Clavert P, Millett PJ, Warner JJ. Glenoid resurfacing: what are the limits to asymmetric reaming for posterior erosion? *J Shoulder Elbow Surg* 2007;16:843–8. <https://doi.org/10.1016/j.jse.2007.03.015>.
- Daggett M, Werner B, Gauci MO, Chauji J, Walch G. Comparison of glenoid inclination angle using different clinical imaging modalities. *J Shoulder Elbow Surg* 2016;25:180–5. <https://doi.org/10.1016/j.jse.2015.07.001>.
- Denard PJ, Walch G. Current concepts in the surgical management of primary glenohumeral arthritis with a biconcave glenoid. *J Shoulder Elbow Surg* 2013;22:1589–98. <https://doi.org/10.1016/j.jse.2013.06.017>.
- Friedman RJ, Hawthorne KB, Genz BM. The use of computerized tomography in the measurement of glenoid version. *J Bone Joint Surg Am* 1992;74:1032–7.
- Gerber C, Costouros JG, Sukthankar A, Fucentese SF. Static posterior humeral head subluxation and total shoulder arthroplasty. *J Shoulder Elbow Surg* 2009;18:505–10. <https://doi.org/10.1016/j.jse.2009.03.003>.
- Gillespie R, Lyons R, Lazarus M. Eccentric reaming in total shoulder arthroplasty: a cadaveric study. *Orthopedics* 2009;32:21. <https://doi.org/10.3928/01477447-20090101-07>.
- Ho JC, Amini MH, Entezari V, Jun BJ, Alolabi B, Ricchetti ET, et al. Clinical and radiographic outcomes of a posteriorly augmented glenoid component in anatomic total shoulder arthroplasty for primary osteoarthritis with posterior glenoid bone loss. *J Bone Joint Surg Am* 2018;100:1934–48. <https://doi.org/10.2106/JBJS.17.01282>.
- Hudak PL, Amadio PC, Bombardier C. Development of an upper extremity outcome measure: the DASH (Disabilities of the Arm, Shoulder and Hand) [corrected]. The Upper Extremity Collaborative Group (UECG). *Am J Ind Med* 1996;29:602–8.
- Iannotti JP, Norris TR. Influence of preoperative factors on outcome of shoulder arthroplasty for glenohumeral osteoarthritis. *J Bone Joint Surg Am* 2003;85:251–8. <https://doi.org/10.2106/00004623-200302000-00011>.
- Kidder JF, Rouleau DM, Pons-Villanueva J, Dynamidis S, DeFranco M, Walch G. Humeral head posterior subluxation on CT scan: validation and comparison of 2 methods of measurement. *Tech Shoulder Elb Surg* 2010;11:72–6. <https://doi.org/10.1097/BTE.0b013e3181e5d742>.
- Klein SM, Dunning P, Mulieri P, Pupello D, Downes K, Frankle MA. Effects of acquired glenoid bone defects on surgical technique and clinical outcomes in reverse shoulder arthroplasty. *J Bone Joint Surg Am* 2010;92:1144–54. <https://doi.org/10.2106/JBJS.I.00778>.
- Klika BJ, Wooten CW, Sperling JW, Steinmann SP, Schleck CD, Harmsen WS, et al. Structural bone grafting for glenoid deficiency in primary total shoulder arthroplasty. *J Shoulder Elbow Surg* 2014;23:1066–72. <https://doi.org/10.1016/j.jse.2013.09.017>.
- Luedke C, Kissenberth MJ, Tolan SJ, Hawkins RJ, Tokish JM. Outcomes of anatomic total shoulder arthroplasty with B2 glenoids: a systematic review. *JBJS Rev* 2018;6:e7. <https://doi.org/10.2106/JBJS.RVW.17.00112>.
- Maurer A, Fucentese SF, Pfirrmann CW, Wirth SH, Djahangiri A, Jost B, et al. Assessment of glenoid inclination on routine clinical radiographs and computed tomography examinations of the shoulder. *J Shoulder Elbow Surg* 2012;21:1096–103. <https://doi.org/10.1016/j.jse.2011.07.010>.
- Millett PJ, Gobeze R, Boykin RE. Shoulder osteoarthritis: diagnosis and management. *Am Fam Physician* 2008;78:605–11.
- Neer CS 2nd, Morrison DS. Glenoid bone-grafting in total shoulder arthroplasty. *J Bone Joint Surg Am* 1988;70:1154–62.
- Orvets ND, Chamberlain AM, Patterson BM, Chalmers PN, Gosselin M, Salazar D, et al. Total shoulder arthroplasty in patients with a B2 glenoid addressed with corrective reaming. *J Shoulder Elbow Surg* 2018;27:558–64. <https://doi.org/10.1016/j.jse.2018.01.003>.
- Ponce BA, Ahluwalia RS, Mazzocca AD, Gobeze RG, Warner JJ, Millett PJ. Biomechanical and clinical evaluation of a novel lesser tuberosity repair technique in total shoulder arthroplasty. *J Bone Joint Surg Am* 2005;87(Suppl 2):1–8. <https://doi.org/10.2106/JBJS.E.00441>.
- Richards RR, An KN, Bigliani LU, Friedman RJ, Gartsman GM, Gristina AG, et al. A standardized method for the assessment of shoulder function. *J Shoulder Elbow Surg* 1994;3:347–52.
- Sabesan V, Callanan M, Ho J, Iannotti JP. Clinical and radiographic outcomes of total shoulder arthroplasty with bone graft for osteoarthritis with severe glenoid bone loss. *J Bone Joint Surg Am* 2013;95:1290–6. <https://doi.org/10.2106/JBJS.L.00097>.
- Shapiro TA, McGarry MH, Gupta R, Lee YS, Lee TQ. Biomechanical effects of glenoid retroversion in total shoulder arthroplasty. *J Shoulder Elbow Surg* 2007;16:S90–5. <https://doi.org/10.1016/j.jse.2006.07.010>.
- Simovitch R, Flurin PH, Wright T, Zuckerman JD, Roche CP. Quantifying success after total shoulder arthroplasty: the minimal clinically important difference. *J Shoulder Elbow Surg* 2018;27:298–305. <https://doi.org/10.1016/j.jse.2017.09.013>.
- Steinmann SP, Cofield RH. Bone grafting for glenoid deficiency in total shoulder replacement. *J Shoulder Elbow Surg* 2000;9:361–7.
- Tashjian RZ, Hung M, Keener JD, Bowen RC, McAllister J, Chen W, et al. Determining the minimal clinically important difference for the American Shoulder and Elbow Surgeons score, Simple Shoulder Test, and visual analog scale (VAS) measuring pain after shoulder arthroplasty. *J Shoulder Elbow Surg* 2017;26:144–8. <https://doi.org/10.1016/j.jse.2016.06.007>.
- Walch G, Badet R, Boulahia A, Khoury A. Morphologic study of the glenoid in primary glenohumeral osteoarthritis. *J Arthroplasty* 1999;14:756–60.
- Walch G, Moraga C, Young A, Castellanos-Rosas J. Results of anatomic non-constrained prosthesis in primary osteoarthritis with biconcave glenoid. *J Shoulder Elbow Surg* 2012;21:1526–33. <https://doi.org/10.1016/j.jse.2011.11.030>.
- Ware J Jr, Kosinski M, Keller SD. A 12-Item Short-Form Health Survey: construction of scales and preliminary tests of reliability and validity. *Med Care* 1996;34:220–33.
- Werner BC, Chang B, Nguyen JT, Dines DM, Gulotta LV. What change in American Shoulder and Elbow Surgeons score represents a clinically important change after shoulder arthroplasty? *Clin Orthop Relat Res* 2016;474:2672–81. <https://doi.org/10.1007/s11999-016-4968-z>.
- Williams GN, Gangel TJ, Arciero RA, Uhorchak JM, Taylor DC. Comparison of the Single Assessment Numeric Evaluation method and two shoulder rating scales. Outcomes measures after shoulder surgery. *Am J Sports Med* 1999;27:214–21.