

# Long-term results of extensive aortoiliac occlusive disease (EAIOD) treated by endovascular therapy and risk factors for loss of primary patency

Xiao-Lang Jiang, Yun Shi, Bin Chen, Jun-Hao Jiang, Tao Ma, Chang-Po Lin, Da-Qiao Guo, Xin Xu, Zhi-Hui Dong, Wei-Guo Fu

Institute of Vascular Surgery, Department of Vascular Surgery, Zhongshan Hospital, Fudan University; Center for Vascular Surgery and Wound Care, Jinshan Hospital, Fudan University, Shanghai 201508, China.

## Abstract

**Background:** Although endovascular therapy has been widely used for focal aortoiliac occlusive disease (AIOD), its performance for extensive AIOD (EAIOD) is not fully evaluated. We aimed to demonstrate the long-term results of EAIOD treated by endovascular therapy and to identify the potential risk factors for the loss of primary patency.

**Methods:** Between January 2008 and June 2018, patients with a clinical diagnosis of the 2007 TransAtlantic Inter-Society Consensus II (TASC II) C and D AIOD lesions who underwent endovascular treatment in our institution were enrolled. Demographic, diagnosis, procedure characteristics, and follow-up information were reviewed. Univariate analysis was used to identify the correlation between the variables and the primary patency. A multivariate logistic regression model was used to identify the independent risk factors associated with primary patency. Five- and 10-year primary and secondary patency, as well as survival rates, were calculated by Kaplan-Meier analysis.

**Results:** A total of 148 patients underwent endovascular treatment in our center. Of these, 39.2% were classified as having TASC II C lesions and 60.8% as having TASC II D lesions. The technical success rate was 88.5%. The mean follow-up time was  $79.2 \pm 29.2$  months. Primary and secondary patency was 82.1% and 89.4% at 5 years, and 74.8% and 83.1% at 10 years, respectively. The 5-year survival rate was 84.2%. Compared with patients without loss of primary patency, patients with this condition showed significant differences in age, TASC II classification, infrainguinal lesions, critical limb ischemia (CLI), and smoking. Multivariate logistic regression analysis showed age <61 years (adjusted odds ratio [aOR]: 6.47; 95% CI: 1.47–28.36;  $P = 0.01$ ), CLI (aOR: 7.81; 95% CI: 1.92–31.89;  $P = 0.04$ ), and smoking (aOR: 10.15; 95% CI: 2.79–36.90;  $P < 0.01$ ) were independent risk factors for the loss of primary patency.

**Conclusions:** Endovascular therapy was an effective treatment for EAIOD with encouraging patency and survival rate. Age <61 years, CLI, and smoking were independent risk factors for the loss of primary patency.

**Keywords:** Critical limb ischemia; Endovascular therapy; Extensive aortoiliac occlusive disease; Mortality; Primary patency; Risk factors

## Introduction

Aortoiliac occlusive disease (AIOD) has historically been treated by aortobifemoral (ABF) bypass because of its satisfactory primary patency rates at 5 and 10 years, ranging between 85–90% and 75–85%, respectively.<sup>[1–3]</sup> However, perioperative mortality and morbidity is substantial, up to 17–32% and 12.2–32.0%, respectively.<sup>[4–7]</sup> With the improvement of devices and increased experience of vascular surgeons, endovascular techniques have been developed as a minimal invasive alternative treatment for AIOD with reduced mortality and morbidity compared with ABF bypass. Although endovascular

therapy currently has been firmly established as the first-line treatment for focal AIOD, its performance for extensive and complex AIOD, TransAtlantic Inter-Society Consensus II (TASC II) C and D lesions, remains controversial.<sup>[8]</sup> Although there are many articles describing the outcomes of endovascular treatment for AIOD, the majority are confined to a small sample size, and risk factors associated with loss of primary patency after stenting have not been fully evaluated. This retrospective cohort study aimed to investigate the long-term outcomes of extensive aortoiliac occlusive disease (EAIOD), defined as TASC II C and D lesions, treated by endovascular therapy and to explore the potential independent risk factors for the loss of primary patency.

## Access this article online

Quick Response Code:



Website:  
www.cmj.org

DOI:  
10.1097/CM9.0000000000001229

**Correspondence to:** Zhi-Hui Dong, Institute of Vascular Surgery, Department of Vascular Surgery, Zhongshan Hospital, Fudan University; Center for Vascular Surgery and Wound Care, Jinshan Hospital, Fudan University, Shanghai 201508, China  
E-Mail: dzh926@126.com

Copyright © 2021 The Chinese Medical Association, produced by Wolters Kluwer, Inc. under the CC-BY-NC-ND license. This is an open access article distributed under the terms of the Creative Commons Attribution-Non Commercial-No Derivatives License 4.0 (CCBY-NC-ND), where it is permissible to download and share the work provided it is properly cited. The work cannot be changed in any way or used commercially without permission from the journal.

Chinese Medical Journal 2021;134(8)

Received: 04-04-2020 Edited by: Jing Ni and Li-Shao Guo

## Methods

### Ethical approval

The study was approved by the Ethics Committee of Zhongshan Hospital, Fudan University and the study complied with the *Declaration of Helsinki* guidelines (No. Y2019-099). Given the retrospective nature of the study, the requirement of written informed consent was waived.

### Patients and data collation

Between January 2008 and June 2018, patients who underwent endovascular treatment for AIOD classified as TASC II C and D lesions in our center were reviewed. All eligible patients and their medical records were reviewed for demographic, diagnosis, procedure characteristics and follow-up information. Preoperative diagnosis and TASC II classifications were mainly based on preoperative imaging modalities and intraoperative angiography. Segment, length, and characteristics of the lesions were evaluated by duplex ultrasound, computed tomography angiography (CTA), magnetic resonance angiography (MRA), and angiography. Local anesthesia of the inguinal region was performed in most patients. The transfemoral approach was the most commonly used. The transbrachial approach could be used to perform flush abdominal aortography to reveal the condition of the occluded segment without touching the lesions, and it is easy to engage both iliac arteries via this route. If the wire failed to pass through the lesion or could not reenter the true lumen owing to substantial dissection, retrograde transfemoral access was performed. The antegrade-retrograde kissing technique for reconstruction of the segment lesion was preferred in most cases. If the common femoral artery (CFA) was completely occluded, the hybrid procedure, including femoral endarterectomy (FEA) with possible thrombectomy, would be performed.

The kissing technique was performed in settings with: (1) short or no stump at the common iliac artery (CIA), leaving no reliable proximal landing zone; (2) an abdominal aortic bifurcation being involved. Self-expanding bare stents were preferred for long lesions, and balloon-expandable bare stents for focal, ostial, and severely calcified lesions. Covered stents were selected for lesions with a high probability of rupture or residual thrombus. Catheter-directed thrombolysis (CDT) was reserved only for patients complicated with acute limb ischemia or lesions close to the renal artery so as to create a proximal landing zone and leave the stent as distant from the renal artery as possible.

The femoral-femoral crossover reconstruction was employed if the iliac artery was patent or endovascularly reconstructed on one side and the contralateral side failed to be recanalized. Most patients with EAIOD had concurrent infrainguinal lesions. The majority did not need to be treated at one stage except for the presence of large ulcers or tissue loss. Stent placement was preferred for the treatment of infrainguinal lesions, and if the patient was not suitable for stenting then a femoral-popliteal bypass was performed. This study excluded patients with iliac stenoses undergoing balloon angioplasty or stenting. Patients with iliac dissection, an associated abdominal artery aneurysm (AAA), or iliac therapy during AAA

endograft placement were also excluded. Dual antiplatelet therapy (aspirin 100 mg/d and clopidogrel 75 mg/d) was administered for 6 months, and only aspirin thereafter for life-long use.

### Variables and definitions

Variables included gender, age (<61 years, 61–70 years, >70 years), ongoing smoking (defined as active smoking before surgery and continued smoking after surgery), CLI (defined in accordance with TASC II guidelines<sup>[8]</sup>), TASC II types (defined in accordance with TASC II guidelines<sup>[8]</sup>), hypertension (defined as systolic pressure >140 mmHg and/or diastolic pressure >90 mmHg), diabetes mellitus, chronic obstructive pulmonary disease (COPD; defined as presence of symptoms or history diagnosed as COPD before), chronic kidney disease (CKD; defined as elevated serum creatinine concentration >1.5 mg/dL and dialysis-dependent status), coronary artery disease (CAD; defined as the presence of symptoms or history of being diagnosed with CAD or having coronary artery balloon angioplasty or stenting), kissing technique, infrainguinal lesions, subintimal access (defined as the guide wire passing the lesion from under the intima), occluded level (lesion involving renal artery or not), and CDT.

Technical success was defined as the residual stenosis <30% determined by intraoperative angiography. Ankle-brachial index (ABI) and Doppler ultrasound or CTA were performed at 3, 6, 9, and 12 months, and yearly afterwards. Significant restenosis was defined as >2.4 peak systolic velocity ratio on duplex,<sup>[9]</sup> >50% stenosis on angiography or CTA or a 0.2 decrease from the resting ABI.<sup>[10]</sup> The loss of primary patency was defined as an ABI decrease associated with evidence of significant restenosis/occlusion, requiring reintervention for the target vessel to maintain arterial patency, or thrombosis of the treated lesions.

### Statistical analysis

Data were collected using Microsoft Excel (Microsoft, Redmond, WA, USA) and analyzed by SPSS version 20.0 for Windows (IBM Co., Armonk, NY, USA). Continuous variables were presented as mean  $\pm$  standard deviation (SD) with range values or as the medians with the interquartile ranges (IQRs), and categorical variables were presented as frequencies and percentages. Univariate analysis and multivariate logistic analysis were used to identify potential independent risk factors for the loss of primary patency. For univariate analysis, the Student's *t* test and Pearson  $\chi^2$  test were applied to test the differences between two groups (with and without loss of primary patency) for continuous variables and categorical variables, respectively. For categorical variables, if the cell with an expected value <5 exceeded 20%, Fisher exact test was used. In the multivariate logistic model, the variables included all variables that exhibited significant difference at the level of *P* value <0.05 in the univariate analysis. The adjusted odds ratio (aOR) and 95% confidence interval (CI) were presented for each independent risk factor for the loss of primary patency at the level of *P* value <0.05. Primary and secondary patency at 5 and 10 years, as well as survival rates, were calculated by Kaplan-Meier

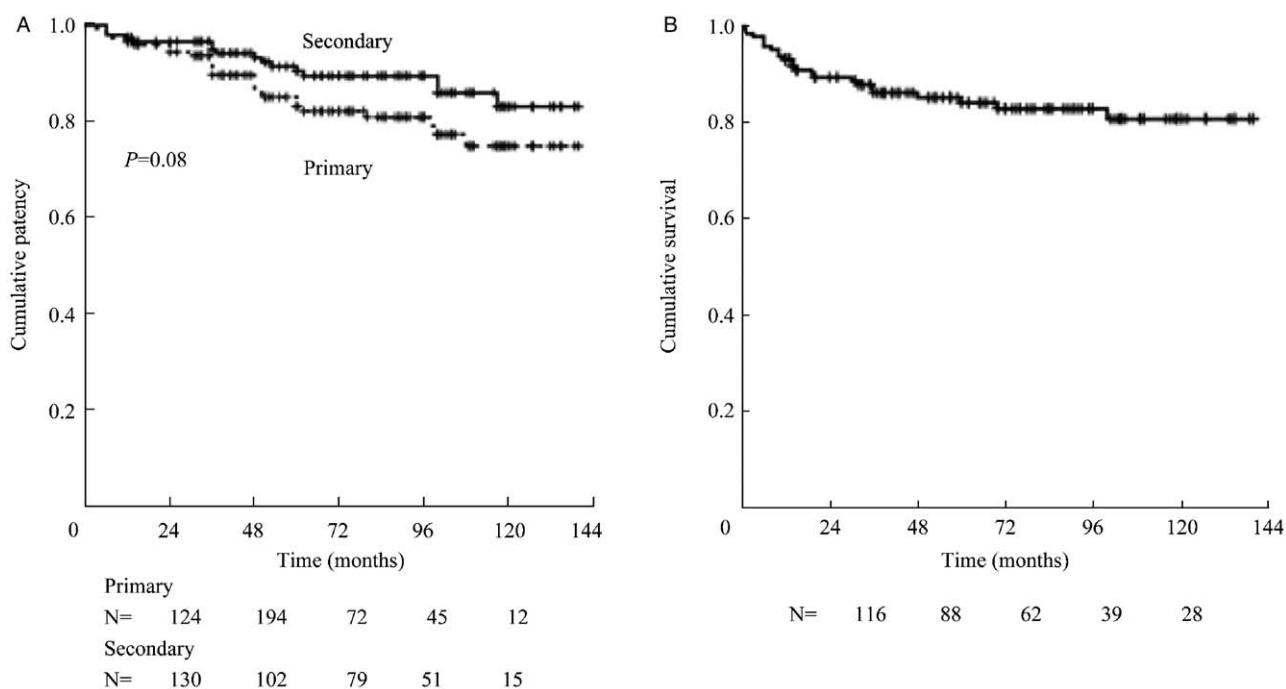
analysis. All *P* values were two-tailed, and a *P* value < 0.05 was defined as statistically significant.

**Results**

From January 2008 to June 2018, a total of 148 patients with 173 limbs were diagnosed with AIOD and treated by endovascular surgery in our center. The technical success rate was 88.5%. The mean age of the patients was 68.6 ± 10.8 years (range, 27–90 years). The ratio of women to men was 1 to 11. Seventy-nine (53.4%) patients presented buttocks, hip, or thigh pain, while 58 (39.2%) presented claudication, 56 (37.8%) presented rest pain, and 34 (23.0%) had tissue loss (ulceration or gangrene). All the patients' conditions were diagnosed by at least one imaging modality. CTA was the most commonly used modality in 135 (91.2%) patients, while duplex ultrasound was performed in 55 (37.2%) patients and MRA in 31 (20.9%) patients. TASC II classifications were mainly based on intraoperative angiography. Fifty-eight (39.2%) and 90 (60.8%) patients were classified as TASC II C and D lesions, respectively. Transfemoral access was most commonly used. The transbrachial approach was performed in 38 (25.7%) patients, and 34 (89.5%) of them were TASC II D lesions. All of these patients were punctured at the left brachial artery, except one who had an arteriovenous fistula on the left arm. Local anesthesia was employed in 128 (86.5%) patients. Among 90 (60.8%) patients with concurrent infrainguinal lesions, FEA was performed in 20 (13.5%) patients, superficial femoral artery (SFA) stenting in 17 (11.5%) patients, femoral-popliteal bypass in 5 (3.4%) patients, and femoral-femoral crossover reconstruction in 17 (11.5%) patients. The median established blood loss (EBL) was

15.0 mL (IQR: 10.0–20.0 mL), and the median hospital stay was 8.0 days (IQR: 6.0–14.8 days). Eight (5.4%) patients died within 1 month after surgery. The causes of death were acute myocardial infarction in 2 (1.4%), acute aortic saddle embolism in 1 (0.7%), stroke in 1 (0.7%), respiratory failure in 1 (0.7%) and unrelated causes in 3 (2.0%) patients.

The mean follow-up time was 79.2 ± 29.2 months (range, 12–140 months). Perioperative complications occurred in 23 (15.8%) patients. The majority of the complications could be treated percutaneously or conservatively. Arterial dissection was the most common complication, which occurred in 8 (5.4%) patients, and all of them were treated by covered stent. Femoral pseudoaneurysm developed in 4 (3.0%) patients and was treated with surgical repair within 1 month of the endovascular procedure. Perforation of the iliac artery occurred in 2 (1.4%) patients, and one of them developed retroperitoneal hematoma. Both of them underwent covered stents placement. Stent graft infection occurred in 2 (1.4%) patients. One of them underwent removal of the endograft and femoral-femoral crossover reconstruction. The other died of multiple organ dysfunction syndrome (MODS). Two (1.4%) patients had distal embolism, and both recovered within 1 week after anticoagulation and vasodilation therapy. Postoperative kidney failure and myocardial infarction occurred in 4 (3.0%) and 5 (3.4%) patients, respectively. Access site hematoma occurred in 4 (3.0%) patients, and access site infection was the rarest complication and occurred in 1 (0.7%) patient. The primary and secondary patency rates at 5 years were 82.1% and 89.4%, respectively, and those at 10 years were 74.8% and 83.1%, respectively [Figure 1A]. The differences between primary and second patency were



**Figure 1 :** (A) Kaplan-Meier plot of stent patency. Primary and secondary patency were 82.1% and 89.4% at 5 years, and 74.8% and 83.1% at 10 years, respectively, with a confidence interval of 95%. (B) Kaplan-Meier plot of long-term survival during the 144-month follow-up.

not significant ( $P = 0.08$ ). Thirty-day mortality was 5.4%, and the 5-year survival rate was 84.2% [Figure 1B].

Compared with patients with patent stent, patients losing primary patency demonstrated statistically significant differences in age ( $P = 0.046$ ), TASC II classification ( $P = 0.046$ ), infrainguinal lesions ( $P = 0.049$ ), CLI ( $P = 0.001$ ), and smoking ( $P = 0.001$ ) [Table 1]. The multivariate logistic analysis showed that age  $< 61$  years (aOR: 6.47; 95% CI: 1.47–28.36;  $P = 0.01$ ), CLI (aOR: 7.81; 95% CI: 1.92–31.89;  $P = 0.04$ ), and smoking (aOR: 10.15; 95% CI: 2.79–36.90;  $P < 0.01$ ) were independent risk factors for the loss of primary patency [Table 2]. The Hosmer-Lemeshow test revealed a good fit ( $\chi^2 = 3.52$ ,  $P = 0.90$ ).

## Discussion

Current guidelines recommend endovascular therapy for less complex lesions and ABF bypass for patients with TASC II C and D lesions. Unfortunately, these guidelines do not take patients' comorbidities and perioperative risks into account, but only the morphology of the lesion.<sup>[11]</sup> Graft infection, acute graft thrombosis, and aortoenteric fistula could be potentially fatal complications.<sup>[12]</sup> Other disadvantages include alternation of the normal anatomy, loss of collateral circulation, and loss of sexual function in males owing to pelvic autonomic nerve damage during surgery. All these have encouraged physicians to extend endovascular treatment to more EAIOD. Jongkind *et al*<sup>[13]</sup> performed a systematic review including 1711 patients and found that more than 1000 patients diagnosed with EAIOD had been successfully treated by endovascular therapy, whereas according to TASC II guidelines, surgical revascularization should have been the preferred treatment. The present study, based on our experience in endovascular treatment for TASC II C and D lesions during the past decade, also demonstrated satisfactory mid- to long-term outcomes.

Evans *et al*<sup>[14]</sup> determined that the atherosclerotic process in patients under 50 years old did not appear more virulent than that in patients over 50 years old. The majority of studies found arterial occlusive disease was preserved as a rare disease in young adults with a poor prognosis because of multiple vascular bed involvement and the accelerated nature of the disease progress.<sup>[15]</sup> Atherosclerosis in most elderly patients is often characterized by a slow progress and a relatively benign course.<sup>[16]</sup> In contrast, premature atherosclerosis has been described as "virulent" with severe symptoms and an aggressive course, producing early disability and death. Valentine *et al*<sup>[17]</sup> also noted that patients aged 40 years and younger required secondary procedures to relieve recurrent symptoms caused by rapid progression of the disease and recommended an aggressive interventional approach in the evaluation and treatment of young patients, and they also concluded that these patients were at significant risk of developing premature coronary occlusive disease and should be monitored closely. The SFA was most commonly affected in older patients with peripheral arterial disease (PAD); nevertheless, the aortoiliac artery was the most common location in young patients.<sup>[14,17,18]</sup> Previous studies have found that the systematic evaluation of patients with early-onset PAD

revealed a high prevalence of other arterial beds in 50% to 71%, especially in the coronary and cerebral arteries.<sup>[19–21]</sup> Jensen *et al*<sup>[22]</sup> noted that young patients exhibited an early manifestation of arteriosclerosis that eventually progressed. Patients younger than 61 years accounted for 24.3% in this study. In the multivariate analysis model, we validated that an age  $< 61$  years was an independent risk factor for the loss of primary patency, which was consistent with others.<sup>[6]</sup> And 30.6% (11/36) of patients aged under 61 years needed further interventions to maintain long-term patency after stenting, which was significantly higher than that in the older patients ( $P = 0.046$ ). Reed *et al*<sup>[6]</sup> also demonstrated that young patients accounted for 41.7% of all emergency admissions, which was significantly higher than that of older patients. Therefore, it could be inferred that atherosclerosis in young patients progressed more virulently and needed to be dealt with more aggressively.

Smoking has been proven to impact all phrases of atherosclerosis from endothelial dysfunction to acute clinical events by affecting vasomotor dysfunction, inflammation and the modification of lipids.<sup>[23,24]</sup> Evans *et al*<sup>[14]</sup> demonstrated that smoking was the most significant risk factor in patients under 50 years with atherosclerotic peripheral vascular disease. Studies have also noted that smoking was the most prevalent risk factor of PAD.<sup>[18,25,26]</sup> In the current study, smoking was also identified as one of the independent risk factors for the loss of primary patency. Nearly half (48.9%) of the cohort were ongoing smokers before surgery. Furthermore, despite repeated notifications of vascular damage caused by smoking, none of the patients succeeded in quitting smoking after surgery. Among the patients losing the primary patency, 20 (76.9%) patients were active smokers, which was significantly higher than among the patients without loss of primary patency ( $P = 0.001$ ).

Previous studies have shown that symptoms in patients with AIOD are not directly related to the severity of the disease due to the development of collateral arterial flow.<sup>[27]</sup> The majority of patients may be asymptomatic for a long time, and the most common clinical manifestations are intermittent claudication and CLI.<sup>[8]</sup> In this study, TASC II classifications were not significantly associated with the patients' clinical presentations (Rutherford classifications;  $P = 0.663$ ). Meanwhile, 60.8% of the patients presented CLI, defined as rest pain and tissue loss (ulceration and gangrene). On the other hand, as a known marker of poorer results, CLI accounted for 60.8% among all patients in the present study and was identified as one of the independent risk factors for the loss of primary patency, implicating a more severe atherosclerosis burden in patients with CLI.<sup>[8,28]</sup> The proportion of concomitant infrainguinal arterial lesions among CLI patients was higher than that among claudicants (67.8% *vs.* 53.4%), even though the difference was not statistically significant ( $P = 0.057$ ). Moreover, most CLI patients had poorer collateral circulation or outflow and needed simultaneous distal revascularization, such as bypass, FEA or thrombectomy, indicating a more virulent and extensive atherosclerotic process. In this study, 20 (76.9%) of the patients with loss of primary patency presented coexisting infrainguinal lesions, which was significantly

**Table 1:: Univariate analysis of the risk factors for patients with decreasing primary patency.**

Variables	Total	Loss of primary patency		Statistic value	P
		No	Yes		
Gender				NA	0.443*
Male	136 (91.9)	113 (83.1)	23 (16.9)		
Female	12 (8.1)	9 (9/12)	3 (3/12)		
Age				6.153	0.046†
<61 years	36 (24.3)	25 (69.4)	11 (30.6)		
61–70 years	49 (33.1)	44 (89.8)	5 (10.2)		
>70 years	63 (42.6)	53 (84.1)	10 (15.9)		
Cigarette smoking				NA	0.001*
Yes	71 (48.0)	51 (71.8)	20 (28.2)		
No	77 (52.0)	71 (92.2)	6 (7.8)		
TASC II classification				NA	0.046*
C	58 (39.2)	43 (74.1)	15 (25.9)		
D	90 (60.8)	79 (87.8)	11 (12.2)		
CAD				NA	0.595*
Yes	29 (19.6)	23 (79.3)	6 (20.7)		
No	119 (80.4)	99 (83.2)	20 (16.8)		
DM				NA	0.485*
Yes	43 (29.1)	34 (79.1)	9 (20.9)		
No	105 (70.9)	88 (83.8)	17 (16.2)		
CKD				NA	0.591*
Yes	6 (4.1)	6 (6/6)	0 (0)		
No	142 (95.9)	116 (81.7)	26 (18.3)		
Hypertension				NA	0.604*
Yes	115 (77.7)	96 (83.5)	19 (16.5)		
No	33 (22.3)	26 (78.8)	7 (21.2)		
Stroke				NA	0.131*
Yes	23 (15.5)	16 (69.6)	7 (30.4)		
No	125 (84.5)	106 (84.8)	19 (15.2)		
COPD				NA	0.607*
Yes	7 (4.9)	5 (5/7)	2 (2/7)		
No	141 (95.3)	117 (83.0)	24 (17.0)		
CDT				NA	0.370*
Yes	23 (15.5)	21 (91.3)	2 (8.7)		
No	125 (84.5)	101 (80.8)	24 (19.2)		
Renal artery involved				NA	0.361*
Yes	9 (6.1)	9 (9/9)	0 (0)		
No	139 (93.9)	113 (81.3)	26 (18.7)		
Subintimal access				NA	0.160*
Yes	16 (10.8)	11 (11/16)	5 (5/16)		
No	132 (89.2)	111 (84.2)	21 (15.9)		
Infrainguinal lesion				NA	0.049*
Yes	90 (60.8)	70 (77.8)	20 (22.2)		
No	58 (39.2)	52 (89.7)	6 (10.3)		
Kissing technique				NA	0.808*
Yes	40 (27.0)	34 (85.0)	6 (15.0)		
No	108 (73.0)	88 (81.5)	20 (18.5)		
CLI				NA	0.001*
Yes	90 (60.8)	67 (74.4)	23 (25.6)		
No	58 (39.2)	55 (94.8)	3 (5.2)		
Number of stents implanted	1.6 ± 0.5	1.6 ± 0.6	1.7 ± 0.5	0.354	0.321‡
Length of the lesions (cm)	9.7 ± 5.3	9.5 ± 5.1	10.5 ± 4.3	0.452	0.342‡

The data are presented as *n* (%) or mean ± standard deviation. \* Pearson  $\chi^2$  test. † Fisher exact test. ‡ Student's *t* test. TASC: TransAtlantic Inter-Society Consensus; CAD: Coronary artery disease; DM: Diabetes mellitus; CKD: Chronic kidney disease; COPD: Chronic obstructive pulmonary disease; CDT: Catheter directed thrombolysis; CLI: Critical limb ischemia

more than patients without loss of primary patency ( $P = 0.049$ ). This indicated that infrainguinal diseases negatively affected the stent patency, which was compara-

ble with other studies.<sup>[29]</sup> However, in the multivariate analysis, infrainguinal disease was not the independent risk factor for loss of primary patency.

**Table 2: Multivariate analysis of the risk factors for loss of primary patency.**

Variables	Exp (B)	95% CI	P
CLI	7.81	1.92–31.89	0.04
TASC II classification	0.55	0.19–1.63	0.28
Infrainguinal lesion	3.34	0.87–12.76	0.78
Age <61 years (reference: >70)	6.47	1.47–28.36	0.01
Cigarette	10.15	2.79–36.90	0

CI: Confidence interval; CLI: Critical limb ischemia; TASC: TransAtlantic Inter-Society Consensus.

Upchurch *et al*<sup>[30]</sup> showed that between 1996 and 2000, stenting and angioplasty for AIOD increased by 8.5-fold and there was a concurrent 16% decrease in the incidence of open surgery to treat AIOD. According to the current study, the endovascular procedure could be the first-line therapy for EAIOD, with a satisfactory technical success rate and long-term outcomes. Its primary and secondary patency rates were 82.1% and 89.4% at 5 years, respectively, and 74.8% and 83.1% at 10 years, respectively, comparable to the conventional ABF procedure.<sup>[13,31-33]</sup> On the other hand, its overall perioperative morbidity rate (15.8%) was lower than that reported after open surgery.<sup>[6]</sup> Moreover, it was determined that patients might still be suitable for referral for conventional surgical therapy without much negative impact, even if the endovascular therapy failed. Danczyk *et al*<sup>[34]</sup> determined that patients who underwent open surgery after failed endovascular therapy for AIOD did not require amputation and failed endovascular therapy did not lead to worse outcomes after surgical conversion. Even for patients with TASC II D lesions in this series, endovascular therapy was also regarded as the first choice with transbrachial access. Even if only one side of the iliac lesion was passed successfully, the femoral-femoral cross-over reconstruction worked effectively as the alternative for contralateral reconstruction. Such a strategy succeeded in 17 (11.5%) patients, and only 1 (5.9%) patient suffered from postoperative renal failure.

There are several limitations in this study. First, this is a retrospective, nonrandomized study that complies with its own nature. Second, the evaluation of restenosis was not performed by angiography, but by ultrasound, CTA and ABI. Third, endovascular therapy was performed by several different surgeons during one decade, which may lead to selection bias concerning decision-making. However, this study does provide practical and useful information for the management of EAIOD.

In conclusion, endovascular therapy for EAIOD showed satisfactory early and late results. Age <61 years, CLI, and smoking were independent risk factors for the loss of primary patency.

### Funding

This work was supported by grants from the National Nature Science Funds (No. 81970407); the Training Program for Outstanding Academic Leaders of the Shanghai Health and Family Planning System [Hundred Talent Program, No. 2018BR40]; the Project of Outstand-

ing Academic Leaders of Shanghai Science and Technology Commission [No. 19XD1401200]; the Training Project for “Future Star” Doctor of Fudan University (2019).

### Conflicts of interest

None.

### References

- Chiu KW, Davies RS, Nightingale PG, Bradbury AW, Adam DJ. Review of direct anatomical open surgical management of atherosclerotic aorto-iliac occlusive disease. *Eur J Vasc Endovasc Surg* 2010;39:460–471. doi: 10.1016/j.ejvs.2009.12.014.
- Szilagyi DE, Elliott JP Jr, Smith RF, Reddy DJ, McPharlin M. A thirty-year survey of the reconstructive surgical treatment of aortoiliac occlusive disease. *J Vasc Surg* 1986;3:421–436. doi: 10.1067/mva.1986.avs0030421.
- Nevelsteen A, Wouters L, Suy R. Aortofemoral dacron reconstruction for aorto-iliac occlusive disease: a 25-year survey. *Eur J Vasc Surg* 1991;5:179–186. doi: 10.1016/s0950-821x(05)80685-1.
- Back MR, Johnson BL, Shames ML, Bandyk DF. Evolving complexity of open aortofemoral reconstruction done for occlusive disease in the endovascular era. *Ann Vasc Surg* 2003;17:596–603. doi: 10.1007/s10016-003-0063-5.
- Bredahl K, Jensen LP, Schroeder TV, Sillesen H, Nielsen H, Eiberg JP. Mortality and complications after aortic bifurcated bypass procedures for chronic aortoiliac occlusive disease. *J Vasc Surg* 2015;62:75–82. doi: 10.1016/j.jvs.2015.02.025.
- Reed AB, Conte MS, Donaldson MC, Mannick JA, Whittemore AD, Belkin M. The impact of patient age and aortic size on the results of aortobifemoral bypass grafting. *J Vasc Surg* 2003;37:1219–1225. doi: 10.1016/s0741-5214(02)75179-3.
- de Vries SO, Hunink MG. Results of aortic bifurcation grafts for aortoiliac occlusive disease: a meta-analysis. *J Vasc Surg* 1997;26:558–569. doi: 10.1016/s0741-5214(97)70053-3.
- Norgren L, Hiatt WR, Dormandy JA, Nehler MR, Harris KA, Fowkes FG, *et al*. Inter-society consensus for the management of peripheral arterial disease (TASC II). *J Vasc Surg* 2007;45 (Suppl S): S5–S67. doi: 10.1016/j.ejvs.2006.09.024.
- Ranke C, Creutzig A, Alexander K. Duplex scanning of the peripheral arteries: correlation of the peak velocity ratio with angiographic diameter reduction. *Ultrasound Med Biol* 1992;18:433–440. doi: 10.1016/0301-5629(92)90082-1.
- Lida O, Soga Y, Takahara M, Kawasaki D, Yamauchi Y, Suzuki K, *et al*. Efficacy of the S.M.A.R.T. Control vs. other stents for aortoiliac occlusive disease in contemporary clinical practice. *J Endovasc Ther* 2013;20:431–439. doi: 10.1583/12-4156MR.1.
- Pooshpas P, Lehman E, Aziz F. Factors Associated with increased risk of unplanned hospital readmission after endovascular aortoiliac interventions. *Cureus* 2018;10:e3558. doi: 10.7759/cureus.3558.
- Theriot JM, Feldman ZM, Korayem AH, Chander RK, Finlay DJ. Minimally invasive aortobifemoral endarterectomy for aortoiliac occlusive disease is a compelling alternative to bypass. *Vasc Endovascular Surg* 2019;53:97–103. doi: 10.1177/1538574418807104.
- Jongkind V, Akkersdijk GJ, Yeung KK, Wisselink W. A systematic review of endovascular treatment of extensive aortoiliac occlusive disease. *J Vasc Surg* 2010;52:1376–1383. doi: 10.1016/j.jvs.2010.04.080.
- Evans WE, Hayes JP, Vermillion BD. Atherosclerosis in the younger patient. Results of surgical management. *Am J Surg* 1987;154:225–229. doi: 10.1016/0002-9610(87)90186-3.
- Nunn DB. Symptomatic peripheral arteriosclerosis of patients under age 40. *Am Surg* 1973;39:224–228.
- Ma X, Kong Q, Wang C, Rajah G, Ding YC, Zhang YR, *et al*. Predicting asymptomatic coronary artery stenosis by aortic arch plaque in acute ischemic cerebrovascular disease: beyond the cervicocephalic atherosclerosis? *Chin Med J* 2019;132:905–913. doi:10.1097/CM9.0000000000000174.
- Valentine RJ, MacGillivray DC, DeNobile JW, Snyder DA, Rich NM. Intermittent claudication caused by atherosclerosis in patients aged forty years and younger. *Surgery* 1990;107:560–565.
- Haimovici H. Patterns of arteriosclerotic lesions of the lower extremity. *Arch Surg* 1967;95:918–933. doi: 0.1001/archsurg.1967.01330180066012.

19. Barretto S, Ballman KV, Rooke TW, Kullo IJ. Early-onset peripheral arterial occlusive disease: clinical features and determinants of disease severity and location. *Vasc Med* 2003;8:95–100. doi: 10.1191/1358863x03vm475oa.
20. Valentine RJ, Grayburn PA, Eichhorn EJ, Myers SI, Clagett GP. Coronary artery disease is highly prevalent among patients with premature peripheral vascular disease. *J Vasc Surg* 1994;19:668–674. doi: 10.1016/s0741-5214(94)70040-0.
21. Liu MY, Yang Y, Zhang LJ, Pu LH, He DF, Liu JY, *et al.* Potential predictors for mental stress-induced myocardial ischemia in patients with coronary artery disease. *Chin Med J* 2019;132:1390–1399. doi: 10.1097/CM9.0000000000000260.
22. Jensen BV, Egeblad K. Aorto-iliac arteriosclerotic disease in young human adults. *Eur J Vasc Surg* 1990;4:583–586. doi: 10.1016/s0950-821x(05)80811-4.
23. Zhou Y, Zhang NR, Zheng ZN, Yang Y, Lyu BF, Wang HL, *et al.* Regular transient limb ischemia prevents atherosclerosis progression in hypercholesterolemic rabbits. *Chin Med J* 2019;132:1079–1086. doi: 10.1097/CM9.0000000000000204.
24. Ambrose JA, Barua RS. The pathophysiology of cigarette smoking and cardiovascular disease: an update. *J Am Coll Cardiol* 2004;43:1731–1737. doi: 10.1016/j.jacc.2003.12.047.
25. Waters D, Lespérance J, Gladstone P, Bocuzzi SJ, Cook T, Hudgin R, *et al.* Effects of cigarette smoking on the angiographic evolution of coronary atherosclerosis. A Canadian Coronary Atherosclerosis Intervention Trial (CCAIT) Substudy. CCAIT Study Group. *Circulation* 1996;94:614–621. doi: 10.1161/01.cir.94.4.614.
26. Taylor RA, Siddiq F, Suri MF, Martin CO, Hayakawa M, Chaloupka JC. Risk factors for in-stent restenosis after vertebral ostium stenting. *J Endovasc Ther* 2008;15:203–212. doi: 10.1583/07-2175.1.
27. Pena CS, McCauley TR, Price TB, Sumpio B, Gusberg RJ, Gore JC. Quantitative blood flow measurements with cine phase-contrast MR imaging of subjects at rest and after exercise to assess peripheral vascular disease. *AJR Am J Roentgenol* 1996;167:153–157. doi: 10.2214/ajr.167.1.8659362.
28. Dorigo W, Piffaretti G, Benedetto F, Tarallo A, Castelli P, Spinelli F, *et al.* A comparison between aortobifemoral bypass and aortoiliac kissing stents in patients with complex aortoiliac obstructive disease. *J Vasc Surg* 2017;65:99–107. doi: 10.1016/j.jvs.2016.06.107.
29. Kashyap VS, Pavkov ML, Bena JF, Sarac TP, O'Hara PJ, Lyden SP, *et al.* The management of severe aortoiliac occlusive disease: endovascular therapy rivals open reconstruction. *J Vasc Surg* 2008;48:1451–1457. doi: 10.1016/j.jvs.2008.07.004.
30. Upchurch GR, Dimick JB, Wainess RM, Eliason JL, Henke PK, Cowan JA, *et al.* Diffusion of new technology in health care: the case of aorto-iliac occlusive disease. *Surgery* 2004;136:812–818. doi: 10.1016/j.surg.2004.06.019.
31. Clair DG, Beach JM. Strategies for managing aortoiliac occlusions: access, treatment and outcomes. *Expert Rev Cardiovasc Ther* 2015;13:551–563. doi: 10.1586/14779072.2015.1036741.
32. Indes JE, Pfaff MJ, Farrokhyar F, Brown H, Hashim P, Cheung K, *et al.* Clinical outcomes of 5358 patients undergoing direct open bypass or endovascular treatment for aortoiliac occlusive disease: a systematic review and meta-analysis. *J Endovasc Ther* 2013;20:443–455. doi: 10.1583/13-4242.1.
33. Shen CY, Liu YF, Li QL, Zhang YB, Jiao Y, Krokidis ME, *et al.* Open and endovascular treatment of Trans-Atlantic Inter-Society Consensus II D aortoiliac occlusive lesions: what determines the rate of restenosis? *Chin Med J* 2015;128:3035–3042. doi: 10.4103/0366-6999.169053.
34. Danczyk RC, Mitchell EL, Petersen BD, Edwards J, Liem TK, Landry GJ, *et al.* Outcomes of open operation for aortoiliac occlusive disease after failed endovascular therapy. *Arch Surg* 2012;147:841–845. doi: 10.1001/archsurg.2012.1649.

---

**How to cite this article:** Jiang XL, Shi Y, Chen B, Jiang JH, Ma T, Lin CP, Guo DQ, Xu X, Dong ZH, Fu WG. Long-term results of extensive aortoiliac occlusive disease (EAIOD) treated by endovascular therapy and risk factors for loss of primary patency. *Chin Med J* 2021;134:913–919. doi: 10.1097/CM9.0000000000001229