

# Artificial intelligence and cardiovascular imaging: A win-win combination

 Luigi P. Badano,  Daria M. Keller<sup>1</sup>,  Denisa Muraru,  Camilla Torlasco<sup>2</sup>,  Gianfranco Parati

Department of Medicine and Surgery, University of Milano-Bicocca; Milan-Italy

<sup>1</sup>Department of Cardiology, Poznan University of Medical Sciences; Poznan-Poland

<sup>2</sup>Cardiovascular Imaging Unit, Department of Cardiovascular, Neural and Metabolic Sciences, Istituto Auxologico Italiano, IRCCS; Milan-Italy

## ABSTRACT

Rapid development of artificial intelligence (AI) is gaining grounds in medicine. Its huge impact and inevitable necessity are also reflected in cardiovascular imaging. Although AI would probably never replace doctors, it can significantly support and improve their productivity and diagnostic performance. Many algorithms have already proven useful at all stages of the cardiac imaging chain. Their crucial practical applications include classification, automatic quantification, notification, diagnosis, and risk prediction. Consequently, more reproducible and repeatable studies are obtained, and personalized reports may be available to any patient. Utilization of AI also increases patient safety and decreases healthcare costs. Furthermore, AI is particularly useful for beginners in the field of cardiac imaging as it provides anatomic guidance and interpretation of complex imaging results. In contrast, lack of interpretability and explainability in AI carries a risk of harmful recommendations. This review was aimed at summarizing AI principles, essential execution requirements, and challenges as well as its recent applications in cardiovascular imaging. (*Anatol J Cardiol* 2020; 24: 214-23)

**Keywords:** artificial intelligence, machine learning, deep learning, echocardiography, cardiac magnetic resonance, cardiac computed tomography, nuclear cardiac imaging

## Introduction

### Artificial intelligence

Artificial intelligence (AI) is the branch of computer science that refers to the ability of computers and robots to perform skills that are typical of intelligent beings such as “reasoning,” discover meanings, generalize, or learn from past experiences (Fig. 1). Well-known examples of AI applications in everyday life are self-driving automobiles, speech-recognition, and autocorrect text software packages.

Machine learning (ML) (a subset of AI) applies statistical techniques to big data to learn from them to make predictions when new data come and improve its own knowledge to better react the next time it is presented with similar data (Fig. 1). In cardiovascular imaging, data are identified by image features (such as their individual measurable characteristics) (Fig. 2).

Three types of ML are used: supervised, unsupervised, and reinforcement learning. Supervised learning relies on the

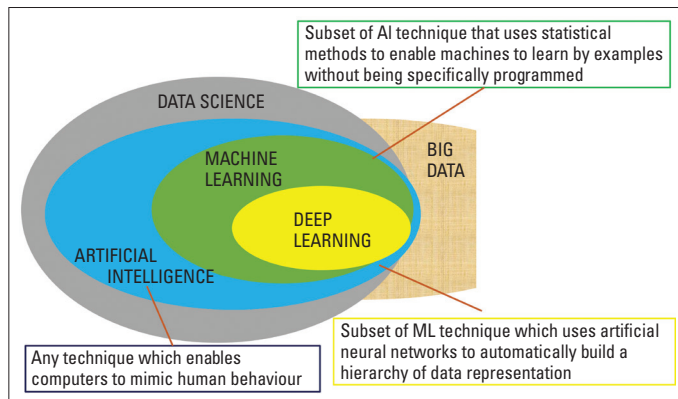
relationship between the input and already known output of a given dataset (Fig. 3). It is used for classification (sorting items into categories) or regression (identifying real values). In contrast, unsupervised learning allows us to tackle problems with little or no idea about the output (Fig. 4). Data can be grouped based on the relationship existing among the variables (1). Unsupervised learning is suited for clustering (identifying similarities in groups) and anomaly detection (identifying abnormalities in data). Finally, with reinforcement learning, the agent decides what to do to perform a given task by finding the best possible way to maximize the reward. Reinforcement learning is suited to develop decision-making processes and reward systems and to set reactions to the environment. Deep learning (DL) is based on artificial neural networks (ANN)-computing systems that are not programmed with task-specific rules, similarly to biological neural networks (Fig. 5). DL utilizes feature (representation) learning, which is a set of techniques enabling a system to perform automated feature engineering and classification through raw data.

**Address for correspondence:** Luigi P. Badano, MD, PhD, Department of Medicine and Surgery, University of Milano-Bicocca; Milan-Italy  
Phone: +39 3756119209 E-mail: luigi.badano@unimib.it

**Accepted Date:** 03.09.2020 **Available Online Date:** 28.09.2020

©Copyright 2020 by Turkish Society of Cardiology - Available online at [www.anatoljcardiol.com](http://www.anatoljcardiol.com)  
DOI:10.14744/AnatolJCardiol.2020.94491





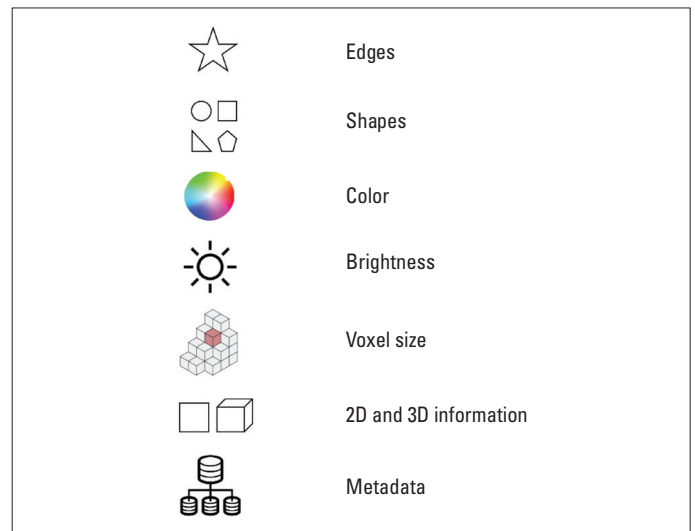
**Figure 1.** Schematic representation of the hierarchy among artificial intelligence, machine learning, and deep learning. All three are branches of the data science. Machine learning and deep learning are subfields within artificial intelligence and need big data to “learn.”

According to a U.S. Food and Drug Administration statement, AI-based technologies have the potential to transform healthcare by deriving new and important insights from the vast amount of data generated in daily healthcare practice. Accordingly, the fundamental prerequisite is the availability of big data.

**Big data**

Big data refers to very large sets of data that can only be stored, understood, and used with the support of special tools and methods. In medicine, they can be derived from clinical records (such as electronic health records), laboratory results, molecular data (such as OMICS data, genomics, transcriptomics, proteomics), imaging (radiomics and PACS-derived data from different modalities), and their integration (2).

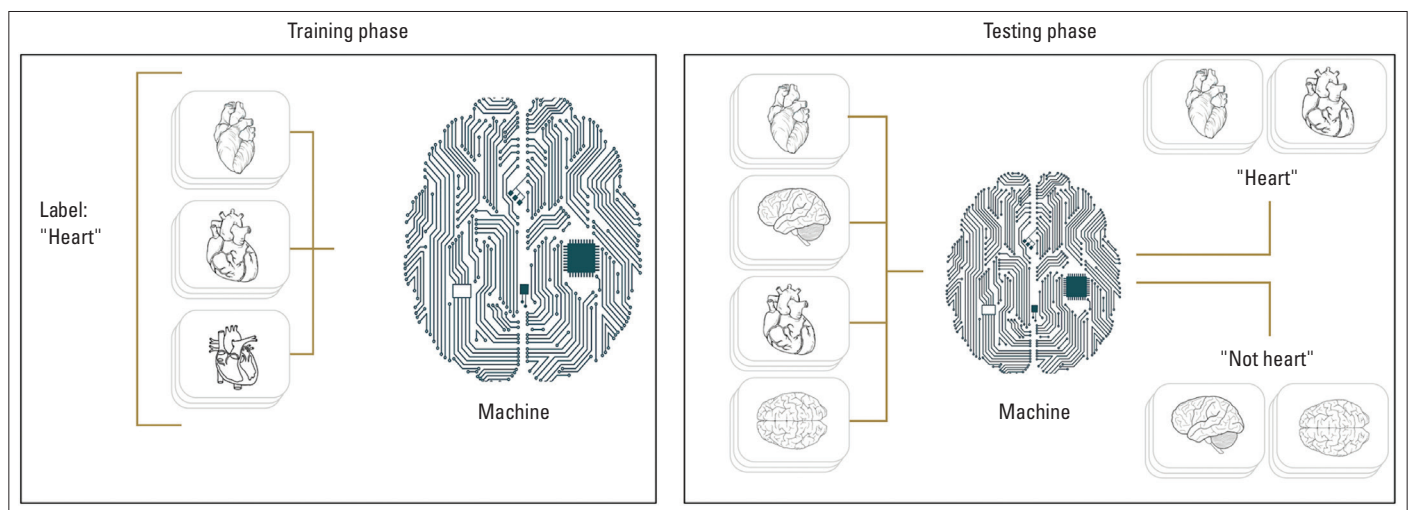
There are five big data characteristics referred to as the “V’s” from ML algorithms. The datasets should be sizable (volume), be



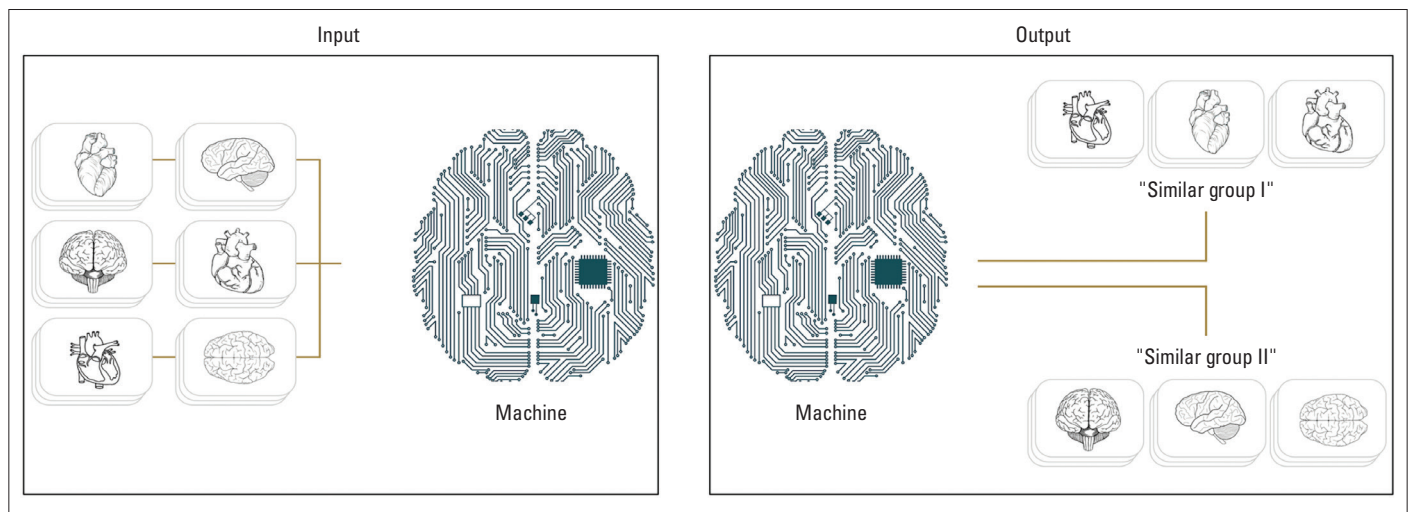
**Figure 2.** Main features of the cardiovascular images that can be extracted with radiomics techniques and used to build big data to train and test artificial intelligence applications [adapted from Artificial Intelligence in Cardiovascular Imaging, Dey et al. (4)]

created and processed quickly (velocity), originate from different sources (variety), be reliable (veracity), and provide answers to crucial questions (value).

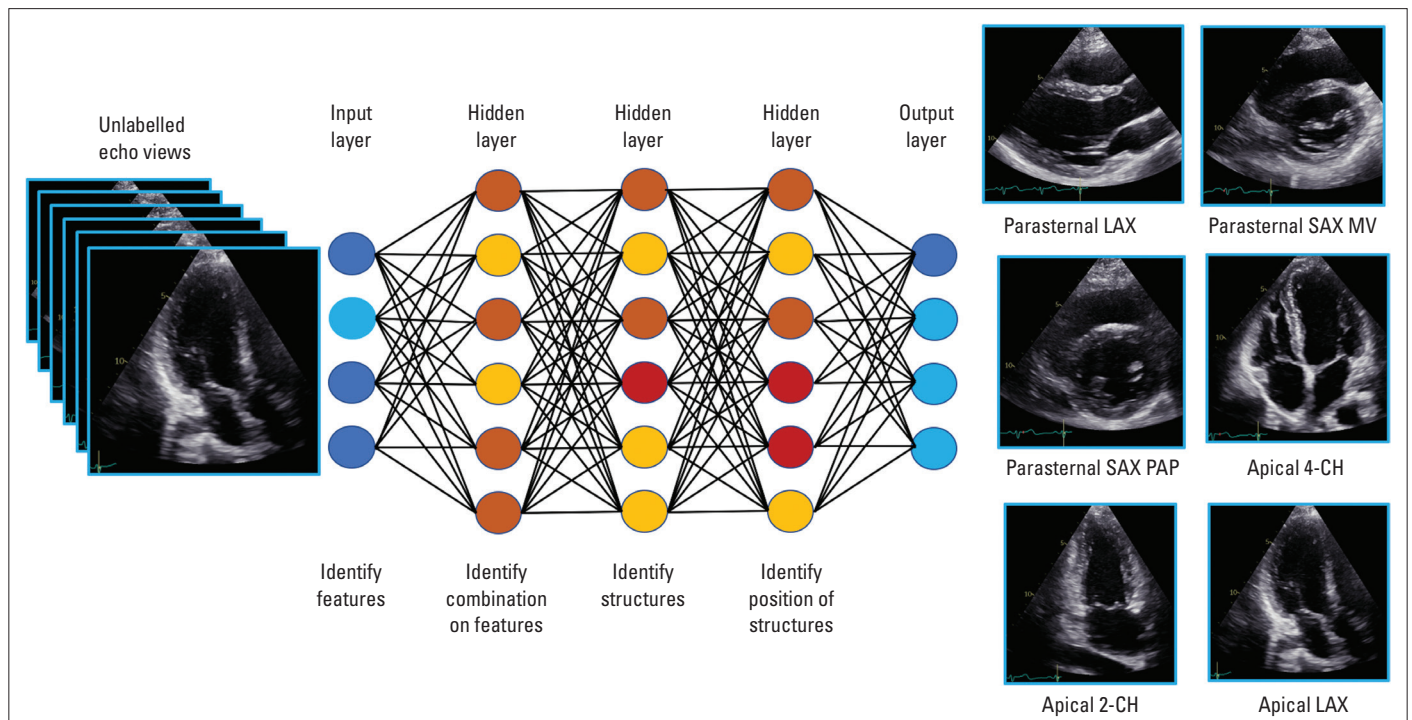
The added value is the ability of AI applications to identify patterns by scrutinizing and analyzing massive amounts of data. Usually, these patterns may remain unrecognized by human reasoning and classical statistical analysis because they involve variables that were not previously linked to the studied phenomenon, and not usually considered in clinical reasoning or in statistical planning. Although humans have abstract-thinking ability, they are not able to find and identify patterns embedded into large quantities of multidimensional and apparently unrelated data.



**Figure 3.** Supervised learning. During the training step (left panel), the algorithm is given a large number of labeled inputs (known diagnosis, anatomical structure) along with desired outputs to teach it. During the testing step (right panel), the algorithm is given new order to check if it is able to label them correctly. If not, the algorithm needs improvement. This technique enables the algorithm to classify or predict views, cardiac strictures, or diagnosis on the basis of the labeled data entered into the machine



**Figure 4.** Unsupervised learning is a technique that feeds the algorithm with unlabeled data sets to detect previously unknown patterns (Left panel). It is the machine that identifies the patterns needed to classify objects (Right panel), cluster patients in homogeneous groups



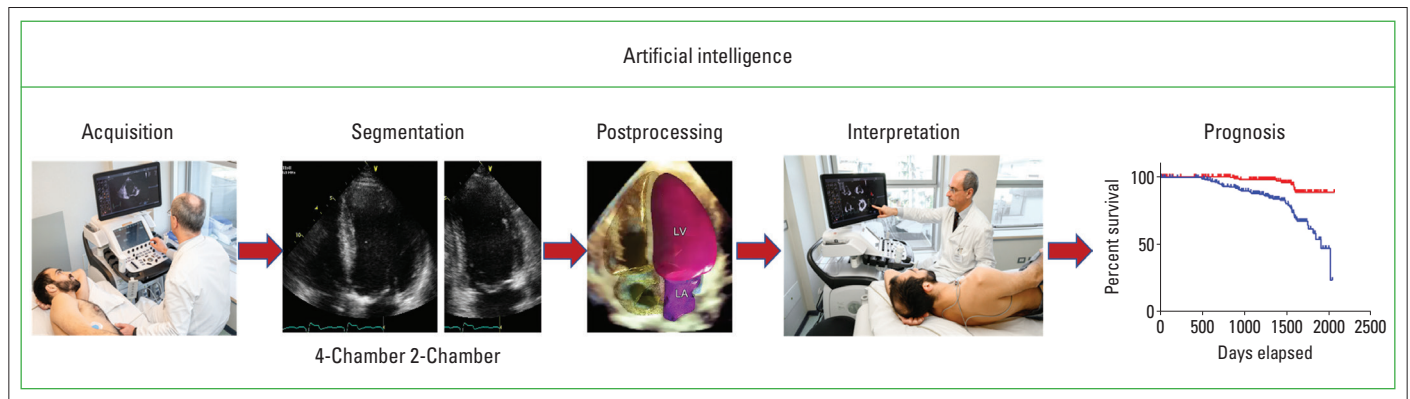
**Figure 5.** Schematic representation of how an artificial neural network works. In the case of a Convolutional Neural Network, the input is an image (a matrix of pixels). The input is processed through a chain (called a graph) of neural layers. At the end of the chain, an output of any desired result can be returned. Although five layers are shown, in reality hundreds or thousands of layers are used

**Artificial intelligence and cardiovascular imaging**

AI is gaining interest in cardiovascular imaging, addressing problems of inconsistency, inter- and intra-observer variability during image acquisition and interpretation. These are particularly sensitive topics in echocardiography compared to other imaging techniques such as cardiac magnetic resonance (CMR) and cardiac computed tomography (CCT), which is more affected by interobserver variability, and is strongly dependent on the expertise of operators (3). Cardiovascular imaging and echocardiography, in particular, are in increasing demand and are becoming more

complex. Therefore, to maintain high quality despite the cost, it is imperative to find ways to decrease variability, acquisition, and postprocessing time while improving efficiency. These are areas where AI could be extremely advantageous for the benefit of the patients, cardiologists, and healthcare system (Fig. 6).

Historically, AI algorithms have been utilized to evaluate static images in radiology. The dynamic nature of cardiac imaging modalities represents a particular challenge for AI. Current problems with timing, acquisition, and diagnostic accuracy may occur at all steps of the imaging chain (Fig. 6). The application of the new



**Figure 6.** Artificial intelligence impact in the various steps of the cardiac imaging chain

computational methods and tools enhances image segmentation, thus enabling automated measurements, and eventually, automated diagnosis. AI also reduces the cost of examinations and increases their value. Furthermore, radiomics—a method that extracts a large amount of quantitative features (Fig. 2), such as signal intensity, texture or shape from images using data-characterization algorithms—enables the creation of large datasets so that any abnormality can be characterized by hundreds of parameters. These data combined with digitized clinical information improves the diagnostic process and lead to personalized treatments and prognostic stratification (4-6). AI-based software packages allowing fully automated quantitative assessment of images are now commercially available for echocardiography, CMR, CCT, and nuclear cardiac imaging. Future software packages will likely enable to triage unread studies by the likelihood of having abnormal findings and prioritize their reporting. The ability of AI algorithms to detect specific heart diseases (such as hypertrophic cardiomyopathy, and amyloidosis) when the images meet specific criteria, seems to be promising (7). AI can also improve the image acquisition process itself. New software packages integrate real-time assessment of image quality with anatomic guidance to help beginners in acquiring standard echocardiographic views (8). Another application of AI is in the comparison of real-time images with previous examinations (3). The public availability of AI libraries (Tensorflow or PyTorch) made research and use of AI algorithms possible, not only for professional data scientists, but also for clinical researchers (9).

### Essentials to apply AI to cardiovascular imaging

The essential requirements for ML performance are pertinent and comprehensive data, appropriate, validated, and useful techniques in clinical practice. Data are indispensable for creating the model (training), and to verify if the algorithm provides the similar outputs, when given new inputs (testing). It is important to avoid using same data for both training and testing, except for “*x-fold cross-validation*” method, where the dataset is split and the testing is repeatedly performed on nontraining data.

AI algorithms need large datasets of high quality. The quality of the source data is crucial: the old “garbage in, garbage out”

concept is still valid. Patient records, medical registries, and cardiovascular images are not always collected in accurate and complete datasets, with data quality far from optimal. Accordingly, to get the most from the application of AI to cardiovascular imaging, images must be collected, adequately organized, consistently labeled, and linked to clinical and laboratory data. Finally, all data must be accessible in big repositories.

A good example is a potent resource for AI development created by Slomka et al. (10). The REFINE SPECT—the Registry of Fast Myocardial Perfusion Imaging with Next generation SPECT may serve as a template for other imaging modalities. Another example is the CMR image database created for the 2016 Kaggle Data Science Bowl Competition, in which >1000 CMR datasets were shared by the National Institutes of Health (4). Conversely, homogenous and small datasets carry the risk of overfitting, where the model benefits only a specific output.

Implementation of AI in imaging involves three steps—data and image features, computational techniques, and imaging applications. Supervised and unsupervised learning are the most widely used ML methods. The crucial practical applications of ML in imaging are quantification, notification, diagnosis, and prediction. Quantification includes automated measures, image quality and sorting, whereas “*red flag*” images and workflow prioritization are the most important notification tools.

### Challenges of AI application in cardiovascular imaging

The serious downsides or “*black boxes*” of AI are the lack of both interpretability and explainability. It seems not to be a major issue when AI is applied to identify views, and the image segmentation is not properly done. Physicians that see the images can always correct it. Conversely, if the AI tool makes harmful recommendations (such as incorrect diagnosis or risk prediction), the consequences are more serious. Removing the “*black boxes*” in AI is currently an area of extensive research to minimize the uncertainty of the decision-making process.

The human brainpower is still much more complex than current AI algorithms, and it will take many years before we can entirely depend on new technologies to interpret cardiac images. Furthermore, we have the issue of personal medical data

being used to improve healthcare. According to an online survey among over 2000 adults from the United Kingdom, most respondents were uncomfortable with that resolution (6).

### **Practical applications of AI in cardiovascular imaging Echocardiography**

Echocardiography is by far the most frequently used cardiovascular imaging modality worldwide. However, this technique is affected by a significant inter- and intra-observer variability in manual quantification of the echocardiographic parameters, and an inconsistent interpretation of studies due to varying image quality, arduous boundary detection, and professional experience (11). The AI algorithms reduce these discrepancies and improve the accuracy of the technique (12-18).

Early applications of AI in echocardiography focused on 2D images. Nowadays, AI-based computer programs can identify cardiac views and measure different parameters such as cardiac chamber dimensions and volumes, ejection fraction, spectral Doppler-derived indexes from digital imaging and communications in medicine format images in less than a minute (19). As recently demonstrated, a DL model (EchoNet) based on convolutional neural networks (CNN), has proven to be very effective in areas such as image recognition and classification. They are able to identify cardiac structures, evaluate their function, as well as predict systemic phenotypes (20). EchoNet accurately recognized the presence of pacemaker leads [area under the curve (AUC)=0.89], enlarged left atrium (AUC=0.86), left ventricular (LV) hypertrophy (AUC=0.75), LV end systolic and diastolic volumes ( $R^2=0.74$  and  $0.70$ , respectively), and ejection fraction ( $R^2=0.50$ ). It also predicted systemic phenotypes of age, weight and height ( $R^2=0.46$ ,  $0.56$ , and  $0.33$ , respectively), and sex (AUC=0.88). The model was trained on a dataset of over 2.6 million images from 2850 patients. The ML pipeline involved sample images from echocardiogram videos, classifying them by view, cropping to eliminate information outside the scanning sector, model training and outcome prediction (20). Zhang et al. (7) used 14,035 echocardiograms to train CNN models for multiple tasks including automated identification of 23 viewpoints and cardiac chambers segmentation across five standard views, quantify chamber volumes, LV mass, and ejection fraction. Automated measurements were comparable (or even superior) to manual ones. Finally, we developed models to detect hypertrophic cardiomyopathy, cardiac amyloidosis, and pulmonary arterial hypertension with C-statistics of 0.93, 0.87, and 0.85, respectively [7].

The application of AI in 3D echocardiography is promising, given that 3D is one of the main advancements in echocardiography and measurements obtained from 3D data sets correlate with CMR measurements better than 2D (21). Although the American Society of Echocardiography and the European Association of Cardiovascular Imaging recommend the use of 3D echocardiography to quantify ventricular cavity volumes, it requires high proficiency level, limiting its application in everyday clinical practice (22). Automatic chamber measurements of 3D

echocardiograms, allow even less experienced sonographers to fully exploit the potential of 3D, making it to become the standard of examination (14).

Furthermore, AI-based algorithms can also automatically evaluate the severity of valvular diseases and is helpful in the preoperative assessment of patients. Moghaddasi et al. (23) used the Support Vector Machine (SVM which is a supervised ML model) classifier to determine the severity of mitral regurgitation. Among 139 patients, an accuracy of 99.52% was recorded for the detection of normal mitral valve, and 99.38%, 99.31%, and 99.59%, respectively, for the identification of mild, moderate, and severe mitral regurgitation (overall sensitivity=99.38% and specificity=99.63%) using SVM classifier. A proof-of-concept study of 530,871 echocardiograms by Playford et al. (24) revealed that their AI algorithm correctly identified 95.3% of patients with high-gradient aortic stenosis versus 73.9% for the continuity equation. The severity of aortic stenosis was obtained by the entire phenotype evaluation, without reference to LV outflow track velocity or dimension. The algorithm performed equally well in low-flow and low-gradient severe aortic stenosis, regardless of systolic LV function. In another study with 47 patients who underwent transcatheter aortic valve implantation, periprocedural aortic annulus measurements by AI echocardiographic software correlated with measurements obtained from CCT more closely than 2D echocardiography (25). It's likely that the use of AI will persuade the medical community to change the paradigm of aortic stenosis treatment soon. A study by Strange et al. in 241,303 patients demonstrated a surprisingly marked increased risk of death evidently from a mean aortic valve gradient >20 mm Hg (26).

Moreover, fully automated, rapid, and reproducible assessment of 2D LV global longitudinal strain (GLS) is already feasible. It will take less than 8 seconds to be evaluated (12). Salte et al. (27) compared fully automated GLS measurements based on DL to the conventional ones on 100 transthoracic echocardiograms of patients with acute myocardial infarction or de novo heart failure, regardless of the image quality. GLS was  $-11.6\% \pm 4.5\%$  for DL method and  $-12.8\% \pm 5\%$  for the conventional method. Feasibility of GLS measurements was 93% and 99%, respectively. This novel DL technique succeeded to automatically identify and classify the standard views, perform myocardium tracing and motion estimation, and evaluate GLS, easing its use in important clinical decisions (27).

### **Cardiac magnetic resonance**

AI in CMR is a rapidly developing field, and it experienced a turning point in 2017. Robert Balaban (National Institutes of Health) gave a visionary keynote lecture at the Society for Cardiovascular Magnetic Resonance Annual Scientific Session "What's Next To come in CMR" with the crucial conception—"Drawing circles. This has to stop." By this, the Arterys company received the Food and Drug Administration approval for the AI-based CMR interpretation (6, 28).

Over recent years, ML, and specifically DL, has been used successfully to address main issues limiting CMR diffusion. This includes cost-effectiveness (long duration of images acquisition and reconstruction, time-consuming image analysis), and the complexity of acquisition of images both due to technical reasons (coping with cardiac and respiratory-induced motion of the heart), and to the high demands on patients (in terms of compliance to breath holding and scan duration).

ML can be applied in all steps of the cardiovascular imaging chain (image acquisition, reconstruction, and segmentation, myocardial tissue characterization, diagnosis, and prognosis). The image acquisition workflow may be optimized by automated localization of the heart, planning of image acquisition planes, optimal frequency adjustment, and scan control framework detecting artifacts (29, 30). Such features are now available, or under development and implementation by many vendors. Furthermore, DL approach has been proposed to speed up the acquisition and the reconstruction of the images. For example, techniques implementing DL to compressed sensing (which exploits spatiotemporal redundancies to reconstruct magnetic resonance images from undersampled k-space data), proved to be superior to the standard techniques in terms of speed and image quality (31). Another promising application for DL is in its high-dimensional imaging (3D, 4D), including late gadolinium enhancement, hemodynamic flow, and perfusion, which all require acceleration techniques (29).

Another field in which AI shows great potential is in image segmentation. At present, manual endo- and epicardial border contouring is needed to calculate mass and volumes, though very time-consuming. Many automated segmentation algorithms have published up-to-date, achieving Dice similarity coefficients of 0.95, or better, when compared to manual tracing (32). However, manual correction is still needed in LV outflow tract, apical slices, right ventricle, and the presence of trabeculae and thrombi (29, 33-35). After identifying heart muscle and cavity, DL partitioning algorithms can also calculate functional parameters, such as ejection fraction. DL frameworks adapted for general image segmentation can use pixel-based classification or regression.

DL-based automated segmentation can be used in myocardial tissue characterization. Examples include automated late gadolinium enhancement quantification (both for ischemic and nonischemic scars), detection of diffuse interstitial fibrosis, myocardial edema or lipid deposition (29, 35, 36). Recently, automated online quantitative myocardial perfusion has been developed, validated, and deployed (37). It is a dual sequence technique characterized by the simultaneous acquisition of a low-resolution arterial input function and a high-resolution myocardial perfusion acquisition. The AI tool exploits a CNN-based solution to accurately detect the LV blood pool from its arterial input function image series (38) and perform automatic segmentation of the left ventricle cavity and myocardium (excluding myocardial fat and papillary muscles). A perfusion map

is obtained, with each pixel of myocardium corresponding to a number represented by a color scale. The global myocardial blood flow (MBF) is then calculated automatically as the mean of all pixels and global myocardial perfusion reserve as the ratio of the stress to rest MBF.

In addition, the first applications of radiomics and texture analysis (TA) in CMR show a promising potential. TA is accurate in differentiating between acute and chronic myocardial infarction, (39) enabling enhanced visualization of damaged myocardium and obtaining information about the surrounding tissue. Furthermore, recent studies suggest that TA can differentiate among various causes of myocardial hypertrophy (40). Finally, TA applied on CMR  $T_1$  and  $T_2$  mapping proves to be an efficient tool in diagnosing myocarditis (41).

Finally, ML is suited for unbiased identification of prognostically important variables. A reduction in myocardial blood flow and myocardial perfusion reserve (measured by automated online quantification stress MBF and myocardial perfusion reserve) were independently associated with both death and major adverse cardiac events regardless of other clinical risk markers in a 1049-patient study (42). Moreover, a 5004-patient study revealed that CMR-derived indices of LV sphericity are strong predictors of heart failure, CAD, and atrial fibrillation (43). Finally, the scar texture features and the patterns of right ventricular motions may be used to predict the occurrence of arrhythmia after myocardial infarction, and the outcome in patients with pulmonary hypertension (44, 45).

### Cardiac computed tomography

With the advancement of innovative algorithms, computing power, and storage capabilities and the use of AI in CCT is gaining grounds in the last decade. In accordance with the ALARA (“as low as reasonably achievable”) principle, lowering the radiation dose while maintaining the image quality is one of the main goals in modern CCT. This can be obtained by optimizing both image acquisition and generation. Furthermore, the ML algorithms in CCT can be used for objective detection and segmentation of structures, diagnostic classification, and outcome prediction (9).

Image enhancement by AI seems to be promising. The reduction of the number of acquisitions, as well as the radiation and contrast doses can be obtained using DL algorithms which are able to convert noncontrast CCT scans to the contrast ones (46). Furthermore, contrast CCT scans can be transformed into noncontrast CCT ones and be utilized for detection of coronary artery calcification (CAC). Another DL use is to generate more precise DECT (dual-energy CT) scans from SECT (single-energy CT) scans (47).

Current methods usually combine object detection with partitioning. Segmentation in CCT can be described as a pixel-based labeling process. The algorithms evaluate each pixel in the scan if it belongs to the target object. As a result, a binary mask of the image is obtained. Afterwards, the segmented objects can be

analyzed separately. This method allows for removal of the background, which is especially helpful in the assessment of CAC. Wolterink et al. (48) revealed that CAC can be accurately identified and quantified in CCT angiography by AI. Their method using ConvPairs (pairs of CNN) reached a sensitivity of 72%. Contemporarily, the most popular CNN architecture for semantic image segmentation is U-net (49).

CCT angiography has become a first-line examination in diagnosing coronary artery disease (CAD). It has shown excellent sensitivity and negative predictive value for coronary artery stenosis. Therefore, its application with AI is of particular importance. The goal of van Hamersvelt et al. (50) was to automatically detect functionally significant coronary artery stenosis causing stress-induced ischemia and subsequent perfusion disorders. They used multiple AI techniques to detect the effects of ischemia that are undetected by human eyes. Firstly, LV myocardium (LVM) was segmented using CNN. Afterwards, a convolutional auto-encoder collected the most important features of LVM. In the third stage, SVM classified the LVM regions as either stenosis or not. Finally, DL and visual assessment of the degree of stenosis were combined. A sensitivity and specificity of 85% and 48% was attained, respectively. AUC was 0.76 compared to invasive fractional flow reserve (AUC=0.68) (50). In addition, ML-based CCT fractional flow reserve analysis is already feasible. However, it is highly influenced by CT reconstruction algorithms so far, potentially affecting patient management (51).

The study predicting all-cause mortality by Motwani et al. (52) and risk of cardiovascular events by van Rosendael et al. (53) in patients suspected of CAD used a relatively large dataset of the CONFIRM (COronary CT Angiography Evaluation For Clinical Outcomes: An International Multicenter) registry. They included 10,030 and 8844 patients, respectively. Both researchers used CCT angiography features such as segment stenosis score, segment involvement score, modified Duke Index, number of segments with plaques, and their composition. Clinical markers such as age, sex, standard cardiovascular risk factors, were further included in the input by Motwani et al. (52). The highest-ranking features for predicting adverse events were selected and used for further training of the algorithm. AUCs were 0.77 (52) and 0.79 (53), respectively. They were more accurate than prediction based on well-known Framingham risk score (AUC=0.69) and current CCTA integrated risk scores (52, 53).

### **Nuclear cardiac imaging**

Myocardial perfusion imaging (MPI) by SPECT (single-photon emission computed tomography) and positron emission tomography (PET) plays a crucial role in the diagnosis and management of CAD. Although PET has an advantage of lower radiation exposure and shorter acquisition time, SPECT is more used worldwide. Interestingly, nuclear cardiac imaging has already used AI in its elementary form for many years. Regular utilization of endocardial border tracking software in SPECT is just one of its applications.

Quantitative perfusion assessment is the primary information derived from the MPI. It may be fully automated, as well as other imaging variables such as ejection fraction, systolic and diastolic volumes, motion thickening, transient ischemic dilation, myocardial mass and blood flow, and dyssynchrony parameters. Overall, several hundred variables can be obtained automatically from a complete (rest/stress) MPI dataset. Although the dataset is typically quantitative, a physician subjectively enters the parameters in the final MPI diagnosis, which opens up a whole spectrum of possibilities for ML (54). The REFINE SPECT is the largest ongoing registry of patients who underwent stress MPI utilizing the latest generation SPECT cameras. It currently includes scans of 20,418 patients from five centers, and diagnostic data of 2079 patients from nine centers. Approximately 300 imaging variables are extracted automatically from each image dataset and integrated with clinical parameters into a comprehensive database. The registry will aid in developing new AI tools for automated diagnosis, patient management, and prognosis (10).

Several recent studies in nuclear cardiology demonstrated the use of ML to improve diagnostic accuracy, identify perfusion defects and their location, predict early revascularization, and the risk of cardiovascular events. Nakajima et al. (55) revealed that their ANN might help in CAD diagnosis. The ANN was trained to classify abnormal areas based on the expert interpretations of 1001 rest/stress SPECT images from 12 centers. The ANN identified stress defects better than nuclear cardiology experts (AUC=0.92 vs. 0.82, respectively). Arsanjani et al. (56) have shown that computational integration of quantitative and functional variables using the SVM approach outperformed visual assessment based on receiver operating characteristic curve analysis and improved the diagnostic accuracy of MPI using SPECT for CAD. The study included 623 CAD patients confirmed by coronary angiography, and 334 patients with a low likelihood of CAD. The total perfusion deficit was computed automatically, with ischemic and ejection fraction changes between stress and rest examinations derived by quantitative software. The SVM was trained using five groups of 25 persons (with low likelihood of CAD, and with 0-, 1-, 2-, and 3-vessel CAD). The remaining 832 patients were categorized using probability. CAD was defined as probability estimate  $\geq 0.5$ . The diagnostic accuracy of CAD was compared with visual scoring by two experts in the field. The sensitivity of SVM, ischemic and ejection fraction changes was 84%, 75%, and 31%, respectively. Moreover, the specificity of SVM, total perfusion deficit, and ejection fraction changes were 88%, 78%, and 77%, respectively. Furthermore, the diagnostic accuracy of SVM (86%) was significantly better than total perfusion deficit (81%), ischemic changes (81%) or ejection fraction changes (46%), and comparable to the overall accuracy of the experts (84%). AUC for SVM was 0.92, whereas for total perfusion deficit, ischemic and ejection fraction changes 0.9, 0.87, 0.64, respectively. For both visual readers AUC was 0.87 and 0.88 (56). Another study of Arsanjani et al. (57) investigated if early revascularization in

patients with suspected CAD can be successfully predicted by ML architecture. We then included 713 rest/stress SPECT studies with corresponding coronary angiographies in the study. From MPS, 372 patients had revascularization events within 90 days (275 underwent percutaneous coronary intervention, 97 coronary artery bypass surgery). Clinical and quantitative data were selected using an automated feature selection algorithm. The results of boosted ensemble ML algorithm (Logit-Boost) were compared to standard measures of perfusion and visual analysis of two experts. The sensitivity of ML for prediction of revascularization ( $73.6\% \pm 4.3\%$ ) was similar to one of the experts and standalone measures of perfusion ( $73.9\% \pm 4.6\%$  and  $75.5\% \pm 4.5\%$ , respectively). Whereas, the specificity of ML ( $74.7\% \pm 4.2\%$ ) was significantly better than both readers ( $67.2\% \pm 4.9\%$  and  $66.0\% \pm 5.0\%$ ) and TPD ( $68.3\% \pm 4.9\%$ ). AUC for ML ( $0.81 \pm 0.02$ ) was the same as one of the experts ( $0.81 \pm 0.02$ ), but superior to the second reader ( $0.72 \pm 0.02$ ), and standalone measures of perfusion ( $0.77 \pm 0.02$ ). The ML approach turned out to be comparable or better than experts in the field and independent measures of perfusion derived from scintigraphy (57). Betancur et al. (58) used 1638 images from the REFINE SPECT registry to train and validate a DL algorithm for automatic detection of significant coronary artery stenosis. They utilized automatically derived compact 2D polar map displays as a CNN input. DL network was trained by obstructive stenosis correlations by invasive coronary angiography to generate a probability of obstructive CAD in each vascular territory. Patterns of perfusion defects were identified by feature extraction into a DL process combining the location, shape, and density. AUC for disease prediction by DL was significantly higher than for TPD (0.80 vs. 0.78 per person and 0.76 vs. 0.73 per vessel). The time needed for the evaluation of a new patient with the pretrained model was  $<1$  s (58).

## Conclusion

AI has become a need in cardiac imaging with crucial practical applications such as automatic quantification, notification, diagnosis, and risk prediction. The AI technology should not be seen as a replacement for cardiac imaging specialists, but as an aid in improving workflow, interpretation skills, and delivering more accurate and personalized reports. Radiomics—a method to extract a large amount of quantitative features from images seems to be especially useful to apply AI to cardiovascular imaging. Moreover, the AI algorithms have an ability to detect a specific disease, when the images meet specific criteria. In a near future, the unread examinations will be triaged by the probability of having abnormal findings (“red flags”) and potentially anomalous studies will be prioritized. Thus, AI may not only refine the workflow, but also decrease healthcare costs by reducing unnecessary testing and improving patient outcomes in the long run.

**Acknowledgments:** We would like to thank Anita Puda for graphic design, and Mateusz Bednarski from Poznan University of Technology for critical evaluation of the text.

**Conflict of interest:** None declared.

**Peer-review:** Internally peer-reviewed.

**Authorship contributions:** Concept – L.P.B., D.M.K., D.M.; Design – None; Supervision – L.P.B., D.M.K., D.M., C.T., G.P.; Funding – L.P.B.; Materials – None; Data collection and/or processing – None; Analysis and/or interpretation – L.P.B., D.M.K., D.M., C.T., G.P.; Literature search – L.P.B., D.M.K., D.M., C.T., G.P.; Writing – L.P.B., D.M.K., D.M.; Critical review – L.P.B., D.M.K., D.M., C.T., G.P.

## References

1. Oikonomou EK, Siddique M, Antoniadou C. Artificial intelligence in medical imaging: A radiomic guide to precision phenotyping of cardiovascular disease. *Cardiovasc Res* 2020; cvaa021. Epub ahead of print
2. Baro E, Degoul S, Beuscart R, Chazard E. Toward a Literature-Driven Definition of Big Data in Healthcare. *Biomed Res Int* 2015; 2015: 639021.
3. Davis A, Billick K, Horton K, Jankowski M, Knoll P, Marshall JE, et al. Artificial Intelligence and Echocardiography: A Primer for Cardiac Sonographers. *J Am Soc Echocardiogr* 2020; 33: 1061-6.
4. Dey D, Slomka PJ, Leeson P, Comaniciu D, Shrestha S, Sengupta PP, et al. Artificial Intelligence in Cardiovascular Imaging: JACC State-of-the-Art Review. *J Am Coll Cardiol* 2019; 73: 1317-35.
5. Kolossváry M, Kellermayer M, Merkely B, Maurovich-Horvat P. Cardiac Computed Tomography Radiomics: A Comprehensive Review on Radiomic Techniques. *J Thorac Imaging* 2018; 33: 26-34.
6. Petersen SE, Abdulkareem M, Leiner T. Artificial Intelligence Will Transform Cardiac Imaging—Opportunities and Challenges. *Front Cardiovasc Med* 2019; 6: 133.
7. Zhang J, Gajjala S, Agrawal P, Tison GH, Hallock LA, Beussink-Nelson L, et al. Fully Automated Echocardiogram Interpretation in Clinical Practice. *Circulation* 2018; 138: 1623-35.
8. Narang A, Bae R, Hong H, Thomas Y, Surette S, Cadieu C, et al. Acquisition of diagnostic echocardiographic images by novices using a deep learning based image guided algorithm. *J Am Coll Cardiol* 2020; 75 (11 Supplement 1): 1564.
9. van den Oever LB, Vonder M, van Assen M, van Ooijen PMA, de Bock GH, Xie XQ, et al. Application of artificial intelligence in cardiac CT: From basics to clinical practice. *Eur J Radiol* 2020; 128: 108969.
10. Slomka PJ, Betancur J, Liang JX, Otaki Y, Hu LH, Sharir T, et al. Rationale and design of the REgistry of Fast Myocardial Perfusion Imaging with NExt generation SPECT (REFINE SPECT). *J Nucl Cardiol* 2020; 27: 1010-21.
11. Nagata Y, Kado Y, Onoue T, Otani K, Nakazono A, Otsuji Y, et al. Impact of image quality on reliability of the measurements of left ventricular systolic function and global longitudinal strain in 2D echocardiography. *Echo Res Pract* 2018; 5: 27-39.
12. Knackstedt C, Bekkers SC, Schummers G, Schreckenber M, Muraru D, Badano LP, et al. Fully Automated Versus Standard Tracking of Left Ventricular Ejection Fraction and Longitudinal Strain: The FAST-EFs Multicenter Study. *J Am Coll Cardiol* 2015; 66: 1456-66.



13. Volpato V, Mor-Avi V, Narang A, Prater D, Gonçalves A, Tamborini G, et al. Automated, machine learning-based, 3D echocardiographic quantification of left ventricular mass. *Echocardiography* 2019; 36: 312-9.
14. Narang A, Mor-Avi V, Prado A, Volpato V, Prater D, Tamborini G, et al. Machine learning based automated dynamic quantification of left heart chamber volumes. *Eur Heart J Cardiovasc Imaging* 2019; 20: 541-9.
15. Tamborini G, Piazzese C, Lang RM, Muratori M, Chiorino E, Mapelli M, et al. Feasibility and Accuracy of Automated Software for Transthoracic Three-Dimensional Left Ventricular Volume and Function Analysis: Comparisons with Two-Dimensional Echocardiography, Three-Dimensional Transthoracic Manual Method, and Cardiac Magnetic Resonance Imaging. *J Am Soc Echocardiogr* 2017; 30: 1049-58.
16. Tsang W, Salgo IS, Medvedofsky D, Takeuchi M, Prater D, Weintert L, et al. Transthoracic 3D Echocardiographic Left Heart Chamber Quantification Using an Automated Adaptive Analytics Algorithm. *JACC Cardiovasc Imaging* 2016; 9: 769-82.
17. Asch FM, Poilvert N, Abraham T, Jankowski M, Cleve J, Adams M, et al. Automated Echocardiographic Quantification of Left Ventricular Ejection Fraction Without Volume Measurements Using a Machine Learning Algorithm Mimicking a Human Expert. *Circ Cardiovasc Imaging* 2019; 12: e009303.
18. Muraru D, Spadotto V, Cecchetto A, Romeo G, Aruta P, Ermacora D, et al. New speckle-tracking algorithm for right ventricular volume analysis from three-dimensional echocardiographic data sets: validation with cardiac magnetic resonance and comparison with the previous analysis tool. *Eur Heart J Cardiovasc Imaging* 2016; 17: 1279-89.
19. Gandhi S, Mosleh W, Shen J, Chow CM. Automation, machine learning, and artificial intelligence in echocardiography: A brave new world. *Echocardiography* 2018; 35: 1402-18.
20. Ghorbani A, Ouyang D, Abid A, He B, Chen JH, Harrington RA, et al. Deep learning interpretation of echocardiograms. *NPJ Digit Med* 2020; 3: 10.
21. Lang RM, Addetia K, Narang A, Mor-Avi V. 3-Dimensional Echocardiography: Latest Developments and Future Directions. *JACC Cardiovasc Imaging* 2018; 11: 1854-78.
22. Lang RM, Badano LP, Mor-Avi V, Afilalo J, Armstrong A, Ernande L, et al. Recommendations for cardiac chamber quantification by echocardiography in adults: an update from the American Society of Echocardiography and the European Association of Cardiovascular Imaging. *J Am Soc Echocardiogr* 2015; 28: 1-39.
23. Moghaddasi H, Nourian S. Automatic assessment of mitral regurgitation severity based on extensive textural features on 2D echocardiography videos. *Comput Biol Med* 2016; 73: 47-55.
24. Playford D, Bordin E, Mohamad R, Stewart S, Strange G. Enhanced Diagnosis of Severe Aortic Stenosis Using Artificial Intelligence: A Proof-of-Concept Study of 530,871 Echocardiograms. *JACC Cardiovasc Imaging* 2020; 13: 1087-90.
25. Thalappillil R, Datta P, Datta S, Zhan Y, Wells S, Mahmood F, et al. Artificial Intelligence for the Measurement of the Aortic Valve Annulus. *J Cardiothorac Vasc Anesth* 2020; 34: 65-71.
26. Strange G, Stewart S, Celermajer D, Prior D, Scalia GM, Marwick T, et al.; National Echocardiography Database of Australia contributing sites. Poor Long-Term Survival in Patients With Moderate Aortic Stenosis. *J Am Coll Cardiol* 2019; 74: 1851-63.
27. Salte IM, Oestvik A, Smistad E, Melichova D, Nguyen TM, Brunvand H, et al. 545 Deep learning/artificial intelligence for automatic measurement of global longitudinal strain by echocardiography. *Eur Heart J Cardiovasc Imaging* 2020; 21 (Suppl 1): jez319.279.
28. Topol EJ. High-performance medicine: the convergence of human and artificial intelligence. *Nat Med* 2019; 25: 44-56.
29. Leiner T, Rueckert D, Suinesiaputra A, Baessler B, Nezafat R, Išgum I, et al. Machine learning in cardiovascular magnetic resonance: basic concepts and applications. *J Cardiovasc Magn Reson* 2019; 21: 61.
30. Frick M, Paetsch I, den Harder C, Kouwenhoven M, Heese H, Dries S, et al. Fully automatic geometry planning for cardiac MR imaging and reproducibility of functional cardiac parameters. *J Magn Reson Imaging* 2011; 34: 457-67.
31. Qin C, Schlemper J, Caballero J, Price AN, Hajnal JV, Rueckert D. Convolutional Recurrent Neural Networks for Dynamic MR Image Reconstruction. *IEEE Trans Med Imaging* 2019; 38: 280-90.
32. Bernard O, Lalande A, Zotti C, Cervenansky F, Yang X, Heng PA, et al. Deep Learning Techniques for Automatic MRI Cardiac Multi-Structures Segmentation and Diagnosis: Is the Problem Solved? *IEEE Trans Med Imaging* 2018; 37: 2514-25.
33. Lin X, Cowan BR, Young AA. Automated detection of left ventricle in 4D MR images: experience from a large study. *Med Image Comput Assist Interv* 2006; 9 (Pt 1): 728-35.
34. Tsadok Y, Petrank Y, Sarvari S, Edvardsen T, Adam D. Automatic segmentation of cardiac MRI cines validated for long axis views. *Comput Med Imaging Graph* 2013; 37: 500-11.
35. Fahmy AS, El-Rewaify H, Nezafat M, Nakamori S, Nezafat R. Automated analysis of cardiovascular magnetic resonance myocardial native T1 mapping images using fully convolutional neural networks. *J Cardiovasc Magn Reson* 2019; 21: 7.
36. Fahmy AS, Rausch J, Neisius U, Chan RH, Maron MS, Appelbaum E, et al. Automated Cardiac MR Scar Quantification in Hypertrophic Cardiomyopathy Using Deep Convolutional Neural Networks. *JACC: Cardiovascular Imaging* 2018; 11: 1917-8.
37. Kellman P, Hansen MS, NIELLES-Vallespin S, Nickander J, Themudo R, Ugander M, et al. Myocardial perfusion cardiovascular magnetic resonance: optimized dual sequence and reconstruction for quantification. *J Cardiovasc Magn Reson* 2017; 19: 43.
38. Xue H, Tseng E, Knott KD, Kotecha T, Brown L, Plein S, et al. Automated detection of left ventricle in arterial input function images for inline perfusion mapping using deep learning: A study of 15,000 patients. *Magn Reson Med* 2020; 84: 2788-800.
39. Beliveau P, Cheriet F, Anderson SA, Taylor JL, Arai AE, Hsu LY. Quantitative assessment of myocardial fibrosis in an age-related rat model by ex vivo late gadolinium enhancement magnetic resonance imaging with histopathological correlation. *Comput Biol Med* 2015; 65: 103-13.
40. Schofield R, Ganeshan B, Kozor R, Nasis A, Endozo R, Groves A, et al. CMR myocardial texture analysis tracks different etiologies of left ventricular hypertrophy. *J Cardiovasc Magn Reson* 2016; 18 (Suppl 1): O82.
41. Baessler B, Luecke C, Lurz J, Klingel K, Das A, von Roeder M, et al. Cardiac MRI and Texture Analysis of Myocardial T1 and T2 Maps in Myocarditis with Acute versus Chronic Symptoms of Heart Failure. *Radiology* 2019; 292: 608-17.
42. Knott KD, Seraphim A, Augusto JB, Xue H, Chacko L, Aung N, et al. The Prognostic Significance of Quantitative Myocardial Perfusion: An Artificial Intelligence Based Approach Using Perfusion Mapping. *Circulation* 2020; 141: 1282-91.
43. Ambale-Venkatesh B, Yang X, Wu CO, Liu K, Hundley WG, McClelland R, et al. Cardiovascular Event Prediction by Machine Learn-

- ing: The Multi-Ethnic Study of Atherosclerosis. *Circ Res* 2017; 121: 1092-101.
44. Kotu LP, Engan K, Borhani R, Katsaggelos AK, Ørn S, Woie L, et al. Cardiac magnetic resonance image-based classification of the risk of arrhythmias in post-myocardial infarction patients. *Artif Intell Med* 2015; 64: 205-15.
  45. Bello GA, Dawes TJW, Duan J, Biffi C, de Marvao A, Howard LSGE, et al. Deep-learning cardiac motion analysis for human survival prediction. *Nat Mach Intell* 2019; 1: 95-104.
  46. Santini G, Zumbo LM, Martini N, Valvano G, Leo A, Ripoli A, et al. Synthetic contrast enhancement in cardiac CT with Deep Learning. *ArXiv cs.CV* 2018; 1807.01779.
  47. Zhao W, Lv T, Lee R, Chen Y, Xing L. Obtaining dual-energy computed tomography (CT) information from a single-energy CT image for quantitative imaging analysis of living subjects by using deep learning. *Pac Symp Biocomput* 2020; 25: 139-48.
  48. Wolterink JM, Leiner T, de Vos BD, van Hamersvelt RW, Viergever MA, Išgum I. Automatic coronary artery calcium scoring in cardiac CT angiography using paired convolutional neural networks. *Med Image Anal* 2016; 34: 123-36.
  49. Ronneberger O, Fischer P, Brox T. U-Net: Convolutional Networks for Biomedical Image Segmentation. In: Navab N, Hornegger J, Wells WM, Frangi AF, editors. *Medical Image Computing and Computer-Assisted Intervention – MICCAI 2015*, vol. 9351, Cham: Springer International Publishing; 2015, p.234-41.
  50. van Hamersvelt RW, Zreik M, Voskuil M, Viergever MA, Išgum I, Leiner T. Deep learning analysis of left ventricular myocardium in CT angiographic intermediate-degree coronary stenosis improves the diagnostic accuracy for identification of functionally significant stenosis. *Eur Radiol* 2019; 29: 2350-9.
  51. Mastrodicasa D, Albrecht MH, Schoepf UJ, Varga-Szemes A, Jacobs BE, Gassenmaier S, et al. Artificial intelligence machine learning-based coronary CT fractional flow reserve (CT-FFRML): Impact of iterative and filtered back projection reconstruction techniques. *J Cardiovasc Comp Tomogr* 2019; 13: 331-5.
  52. Motwani M, Dey D, Berman DS, Germano G, Achenbach S, Al-Mallah MH, et al. Machine learning for prediction of all-cause mortality in patients with suspected coronary artery disease: a 5-year multicentre prospective registry analysis. *Eur Heart J* 2017; 38: 500-7.
  53. van Rosendaal AR, Maliakal G, Kolli KK, Beecy A, Al'Aref SJ, Dwivedi A, et al. Maximization of the usage of coronary CTA derived plaque information using a machine learning based algorithm to improve risk stratification; insights from the CONFIRM registry. *J Cardiovasc Comput Tomogr* 2018; 12: 204-9.
  54. Slomka PJ, Dey D, Sitek A, Motwani M, Berman DS, Germano G. Cardiac imaging: working towards fully-automated machine analysis & interpretation. *Expert Rev Med Devices* 2017; 14: 197-212.
  55. Nakajima K, Kudo T, Nakata T, Kiso K, Kasai T, Taniguchi Y, et al. Diagnostic accuracy of an artificial neural network compared with statistical quantitation of myocardial perfusion images: a Japanese multicenter study. *Eur J Nucl Med Mol Imaging* 2017; 44: 2280-9.
  56. Arsanjani R, Xu Y, Dey D, Fish M, Dorbala S, Hayes S, et al. Improved accuracy of myocardial perfusion SPECT for the detection of coronary artery disease using a support vector machine algorithm. *J Nucl Med* 2013; 54: 549-55.
  57. Arsanjani R, Dey D, Khachatryan T, Shalev A, Hayes SW, Fish M, et al. Prediction of revascularization after myocardial perfusion SPECT by machine learning in a large population. *J Nucl Cardiol* 2015; 22: 877-84.
  58. Betancur J, Commandeur F, Motlagh M, Sharir T, Einstein AJ, Bokhari S, et al. Deep Learning for Prediction of Obstructive Disease From Fast Myocardial Perfusion SPECT. *JACC: Cardiovascular Imaging* 2018; 11: 1654-63.