

Retrospective magnetic resonance imaging evaluation of fatty filum terminale in Kuwaiti population

Parag Suresh Mahajan,
Nazeer Ahamad,
Anuradha Parag Mahajan¹,
Nawal M. Al Moosawi²

Clinical Imaging Department, Hamad Medical Corporation, Doha, Qatar, ¹Mahajan Clinic, Charkop Market, Kandivali (West), Mumbai, Maharashtra, India, ²Department of Radiodiagnosis, Armed Forces Hospital, Kuwait

Address for correspondence:

Dr. Parag Suresh Mahajan, Clinical Imaging Department, Hamad Medical Corporation,
Post Box 3050, Doha, Qatar.
E-mail: mdfrcr@gmail.com

Abstract

Objective: Thickened fatty filum terminale (FFT) can cause tethered cord syndrome (TCS) and can be easily diagnosed on magnetic resonance (MR) imaging. We aimed to assess a) the incidence, distribution and clinical significance of the incidentally detected FFT in Kuwaiti population and b) the relationship between degenerative disk disease (DDD) and thickness of the FFT. **Materials and Methods:** A retrospective study was planned at Jaber Al Ahmad Armed Forces Hospital, Kuwait involving 1111 patients. A 1.5T GE machine was used for MR imaging to acquire multiplanar MR sequences. MR images of lumbar spine in 1111 subjects were reviewed and location, size, tightness of FFT, the DDD and clinical details were evaluated. **Results:** FFT was observed in 43 out of 1111 (3.9%) subjects based on MRI, out of which 11 were females and 32 were males. The mean distance between the tip of conus medullaris and the FFT was 41 mm. The mean diameter of the FFT was 1.74 mm. 40 of 43 patients had DDD of varying severity on MR images and no significant or appreciable slackness of FFT was observed in these cases. There were no clinical symptoms related to FFT associated with degenerated disks. **Conclusion:** FFT is frequently observed in Kuwaiti male population. No significant slackness of FFT was observed in cases with varying severity of DDD. There were no clinical symptoms related to FFT with or without degenerated disks.

Key words: Degenerative disk disease, fatty filum terminale, lumbar spine, magnetic resonance, tethered cord syndrome

INTRODUCTION

Tethered spinal cord with tight filum terminale may cause neurogenic disturbances of the urinary bladder and lower extremities in childhood.^[1-5] Hence, it is commonly diagnosed and managed by pediatric neuro-surgeons and urologists.^[4] However some authors have reported the adult onset tethered cord syndrome (TCS) with urinary disturbances in the presence of cord tethering with FFT.^[4-6]

FFT is disregarded if the neurological dysfunctions are not observed in childhood.^[4] The FFT is incidentally found in 0.24-1.0% of lumbar MRI examinations and its clinical significance remains unclear.^[1,4] We aimed to assess a) the incidence, distribution and clinical significance of the incidentally detected FFT in Kuwaiti population and b) the relationship between degenerative disk disease (DDD) and tightness of the FFT. We hypothesized that in older patients the filum may appear slack due to the loss of disk height secondary to disk degeneration. FFT may thus less influence on tethering if degenerative disk disease (DDD) exists.

MATERIALS AND METHODS

Following ethical approval, lumbosacral magnetic resonance images of 1111 patients, who were imaged between July 2008 and February 2010 at the MRI

Access this article online

Quick Response Code:



Website:
www.jnsbm.org

DOI:
10.4103/0976-9668.149097

department of the Jaber Al Ahmad Armed Forces Hospital, Kuwait, were reviewed. Patients were evaluated by a General Electric (GE) Signa Excite 1.5T MR machine in supine position. Sagittal, axial and coronal images of the lumbosacral spine were obtained. Each image was analyzed by three radiologists (authors). FFT was found in 43 subjects on MR imaging. The clinical details of the 43 patients were reviewed. The location of conus medullaris, the diameter, location and tightness of the FFT were evaluated on MR imaging. The DDD was also evaluated and graded in these 43 patients, according to Pfirrmann grading system. Pfirrmann, *et al.* examined and characterized intervertebral disk pathology using MR imaging.^[7] The severity of disk degeneration was graded from I to V. Grade I disks are bright, and homogenous on T2 sequences. Grade II disks are bright, but somewhat inhomogenous with banding. Grade III disks are gray with unclear distinction between the nucleus and annulus. Grade IV disks are inhomogenous and dark without distinction between the nucleus and annulus. Finally, grade V disks demonstrate a collapsed disk space.^[7]

FFT was diagnosed based on the presence of a hyperintense cord like structure on sagittal T1-weighted images and small hyperintense circular structures on the corresponding axial T1-weighted images [Figures 1-6]. Disk degeneration is seen on T2-weighted images [Figures 7 and 8]. Slackness or tightness of the FFT was subjectively evaluated and the final opinion was determined based on the consensus opinion of all 3 radiologists. Similar opinion of 2 or more authors in each case was considered as a final. All statistical analyses were performed using statistical package PASW Statistics (version 19.0, SPSS Inc., Chicago, United States of America).

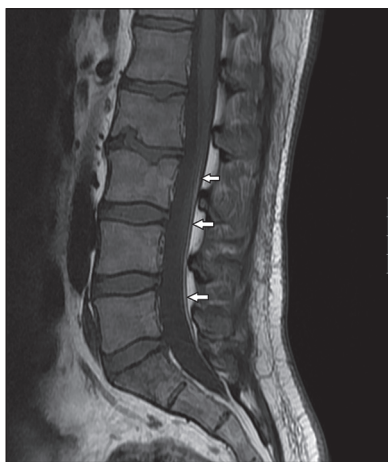


Figure 1: Sagittal T1 weighted MRI image demonstrating FFT as a long slack cord like hyperintense intrathecal structure isointense to the subcutaneous fat in patient 1

RESULTS

This study included 1111 patients. 523 patients were females and 588 were males. FFT was found in 43 of 1111 (3.9%) patients on MRI. Out of the 43 patients with FFT, eleven were females and 32 were males. The mean age of the 43 patients with FFT was 47 years. The age range was 26-65 years. There were 3 patients less than 30 years of age; 10 were in the 31 to 40-year age group and 30 were older than 41 years [Table 1]. All the FFT were incidentally detected on lumbar MRI. The diagnosis or symptoms of the patients varied from low backache, lumbar disk prolapse, compression fractures of lumbar spine, degenerative scoliosis of lumbar spine and spinal trauma. The conus medullaris was observed to terminate between T12 and L2 vertebral levels. No apparent low conus medullaris was observed on MRI in the 43 patients. The mean distance between the tip of the conus and the fatty filum was 41 mm (range of 5-115 mm). The mean diameter of the fatty filum was 1.74 mm (1.1-3.8 mm). Thickened FFT (diameter or thickness more than 2 mm) was found in 10 patients. The mean length of the FFT was 44 mm (range of 14-186 mm). Degenerative disk disease was observed in 40 patients. Out of the 40 patients of FFT with DDD, 4 had Pfirrmann grade II disease, 16 had grade III disease, 15 had grade IV disease and 5 had grade V disease [Table 2]. Clinical signs and symptoms of these patients were unrelated to the FFT but were related to the clinical diagnosis/DDD. Relationship of location, distance and the diameter of the FFT to the clinical symptoms was not observed.

DISCUSSION

Tethered Cord Syndrome (TCS) is due to fixation of the filum terminale in the thecal sac and is seen in pediatric

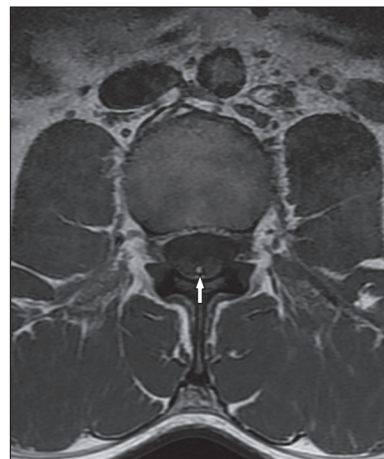

Figure 2: Axial T1 weighted MRI image demonstrating FFT as a hyperintense intrathecal dot like structure in patient 1

patients commonly associated with diastematomyelia and myelomeningocele.^[6] Some authors have reported the adult onset TCS due to injury to conus medullaris

secondary to inelastic and fatty filum terminale.^[4-6] Thickened (more than 2 mm) FFT or lipoma in

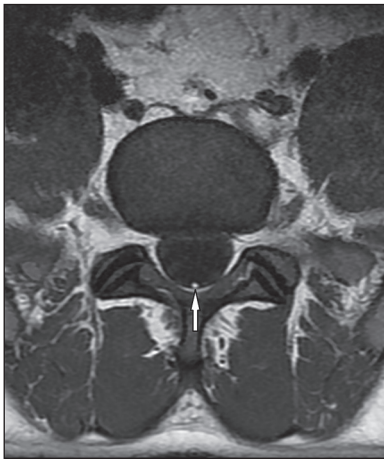


Figure 3: Axial T1 weighted MRI image demonstrating FFT as a hyperintense intrathecal dot like structure in patient 1

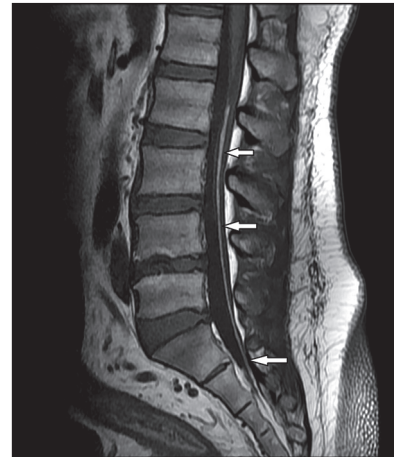


Figure 4: Sagittal T1 weighted MRI image demonstrating FFT as a long cord like hyperintense intrathecal structure isointense to the subcutaneous fat in patient 2. No significant slackness of the FFT is noted despite reduced disk height

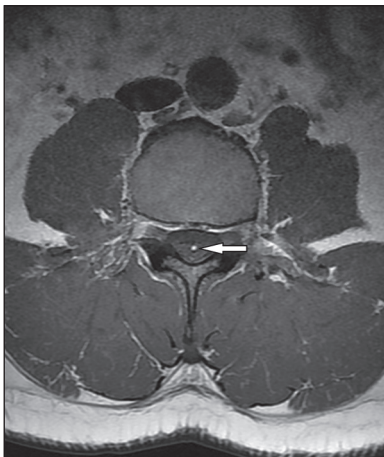


Figure 5: Axial T1 weighted MRI image demonstrating FFT as a hyperintense intrathecal dot like structure in patient 2

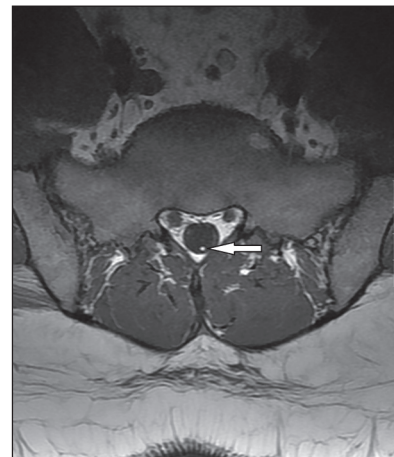

Figure 6: Axial T1 weighted MRI image demonstrating FFT as a hyperintense intrathecal dot like structure in patient 2

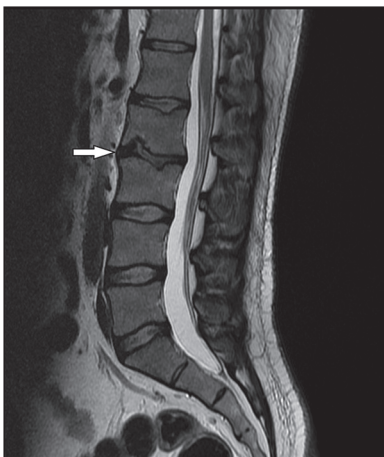


Figure 7: Sagittal T2 weighted MRI image demonstrating degenerated L2-3 disk in patient 1

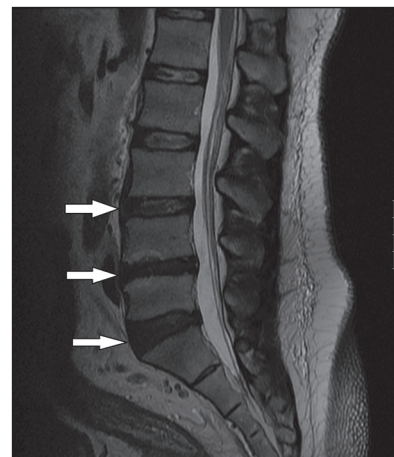


Figure 8: Sagittal T2 weighted MRI image demonstrating degenerated L3-4 through L5-S1 disks in patient 2

Table 1: Age group and gender related distribution of incidentally detected fatty filum terminale (FFT)

Age	Males (n)	Males (%)	Females (n)	Females (%)
<30 (n=3)	3	100	0	0
30-40 (n=10)	9	90	1	10
>40 (n=30)	20	66.6	10	33.3
Total (n=43)	32	74.4	11	25.6

Table 2: Distribution of Pfirrmann grades of degenerative disk disease (DDD) amongst cases with fatty filum terminale (FFT) on magnetic resonance imaging

Pfirrmann grade	Number of patients of FFT with DDD (n = 40)	Percentage of patients of FFT with DDD (%)
Grade I	0	0
Grade II	4	10
Grade III	16	40
Grade IV	15	37.5
Grade V	5	12.5

thecal sac is demonstrated on MRI in more than 90% diagnosed cases of TCS.^[4] On the other hand, FFT was found in 0.24-1.0% of MRI examinations of lumbar spine.^[1,4] Thus the thickened FFT is considered as one of the causes of tethering.^[1,4] In our study, FFT was observed in 43 of 1111 or 3.9% of MR examinations, indicating that the FFT incidence is high in Kuwaiti population compared to other regions wherein 0.24-1% incidence rate is reported. We observed significant gender difference in the distribution of FFT in Kuwaiti population, with higher incidence among males, which is in contrast to other international studies.

TCS with normal level of conus medullaris with or without thickened FFT are reported.^[1,4,6] Fat in the filum may represent mesodermal cells that did not migrate properly to their normal position in the process of canalization.^[1] The presence of fatty tissue may alter the developmental properties of the filum and may predispose patients to cord tethering.^[1,3,4] Fat in the filum terminale within 13 mm of the conus medullaris is most predictive of neurological deficits and TCS in adults is caused by anoxia due to over-stretching of the conus medullaris.^[1,4,8] Momentary stretching of the conus, narrowing of the spinal canal and direct blow to the back may aggravate the neurological dysfunction in the presence of the tethering.^[4,5] FFT may cause TCS even in older patients, hence attention should be paid to the location and the diameter of the FFT, if it is demonstrated on MRI.^[4] FFT that is found incidentally in patients with DDD may not cause TCS as there is loss of disk height in these patients that causes slackening of the terminale. In a 2006 study, slack FFT was demonstrated

on MRI in cases with disk degeneration.^[4] FFT may lead to TCS when it lies near to the conus medullaris and is associated with loss of its elasticity.^[4] Hence, it was suggested that attention should be paid not only to the location in relation to the conus medullaris and the diameter of the FFT if it is demonstrated on MRI, but also to the DDD and the tightness (tension) of the terminale itself.^[4] The neurological disturbances may be caused by the tethering with FFT, but the filum that is found incidentally in older patients may not influence the function of the cauda equina and nerve roots because there is loss of disk height in older patients with disk degenerations.^[4] In our study, however, MRI did not reveal any significant or appreciable slackness of the FFT. This was a retrospective study and the results of a prospective study would be more reliable. Sample size was relatively small in our study. A larger study with significantly more number of cases may be needed to further evaluate the hypothesis. To the best of our knowledge, there is only one previous research article studying the relationship between the DDD and the tightness of the FFT. Also, this is the largest study about FFT in Kuwait and possibly the Middle East. In conclusion, FFT is commoner in Kuwaiti population than in other parts of the world. Also it is commoner in males than females in Kuwaiti population. No significant or appreciable slackness of FFT was observed in our study in cases with varying severity of DDD and there were no clinical symptoms related to FFT with or without degenerated disks.

REFERENCES

- Bursara KR, Zomorodi AR, Enterline DS, George TM. The value of magnetic resonance imaging in the evaluation of fatty filum terminale. *Neurosurgery* 2004;54:375-9.
- Rinaldi F, Cioffi FA, Columbano L, Krasagakis G, Bernini FP. Tethered Cord Syndrome. *J Neurosurg Sci* 2005;49:131-5.
- Selcuki M, Coskun K. Management of Tight Filum Terminale Syndrome with special emphasis on normal level conus medullaris. *Surg Neurol* 1998;50:318-22.
- Iizuka T. Fatty Filum Terminale on MRI. *The Internet Journal of Spine Surgery* 2006;3:1.
- Zimmer PE. Tethered cord syndrome in adult. A rare presentation. *J Urol (Paris)* 1994;100:93-6.
- Matsuoka T, Ueyama H, Ando Y, Kumamoto T, Araki S. A case of adult-onset tethered cord syndrome accompanied with slowly progressive muscular atrophy in the lower limbs. *Rhinsho Shinkeigaku* 1991;31:778-80.
- Pfirrmann CW, Metzendorf A, Zanetti M, Hodler J, Boos N. Magnetic resonance classification of lumbar intervertebral disc degeneration. *Spine (Phila Pa 1976)* 2001;26:1873-8.
- Yamada S, Knerium DS, Mandybur GM, Schultz RL, Yamada BS. Pathophysiology of tethered cord syndrome and other complex factors. *Neurol Res* 2004;26:722-6.

How to cite this article: Mahajan PS, Ahamad N, Mahajan AP, Al Moosawi NM. Retrospective magnetic resonance imaging evaluation of fatty filum terminale in Kuwaiti population. *J Nat Sc Biol Med* 2015;6:85-8.

Source of Support: Nil. **Conflict of Interest:** None declared.