

# Parosmia and Dysgeusia after Intravenous Propofol-Based General Anesthesia: A Case Report

Nayab Farzana, Prabhat Tewari, Sanjoy Sureka<sup>1</sup>, Aanchal Dixit<sup>2</sup>

Departments of Anaesthesiology, <sup>1</sup>Urology, SGPGIMS, <sup>2</sup>Department of Cardiac Anaesthesia, Medanta Hospital, Lucknow, Uttar Pradesh, India

## ABSTRACT

Various drugs, including anesthetic agents, can cause parosmia in the perioperative period. There are reported cases of patients with alterations of smell and taste due to local anesthetics, nerve damage, or as a side effect of general anesthesia. We present a case of a 58-year-old male who developed parosmia and dysgeusia in the postoperative period after radical nephrectomy and inferior vena cava thrombectomy. The anesthetics used were fentanyl and propofol for general anesthesia and ropivacaine for epidural analgesia. Clinical examination did not reveal any pathology.

**Keywords:** Dysgeusia, effects of propofol, parosmia, postoperative olfactory disorder

**Address for correspondence:** Dr. Nayab Farzana, 9/308, Vikas Nagar, Lucknow - 226 022, Uttar Pradesh, India.

E-mail: farzanasgpgi@gmail.com

**Submitted:** 13-Jul-2021 **Revised:** 12-Sep-2021 **Accepted:** 12-Sep-2021 **Published:** 21-Jan-2022

## CASE REPORT

We present a case of a 58-year-old, well-built, non-smoker male patient who underwent elective radical nephrectomy and inferior vena cava (IVC) thrombectomy for renal tumor with level 2 IVC tumor growth [Figure 1] in October of the year 2018.

The patient was a known hypertensive and was on amlodipine 5 mg for 2 months, advised rosuvastatin (20 mg OD) for a week before surgery, and was also on immunotherapy- pazopanib (tyrosine kinase inhibitor, 400 mg BD) for 2 weeks which was stopped a week before surgery. His laboratory investigations were within normal limits.

On the day of the surgery in the operation room, general anesthesia was induced and maintained with propofol (2%; (260 mg total amount infused during surgery) and fentanyl 850 µg (total intravenous anesthesia [TIVA] was

given without inhalational agent). The epidural catheter was placed at L2-L3 level, and a mixture of ropivacaine (0.1%) and fentanyl (1 µg/mL), at 6 mL per hour, was used for continuous epidural analgesia (to minimize intraoperative use of intravenous opioids). After muscle relaxation with pancuronium (8 mg), the trachea was intubated, and the patient was mechanically ventilated with a low tidal volume strategy (6–7 mL per kg). The surgery included opening up of the abdomen, identification and separation of the kidney with the mass, and identification of IVC where tumor entered it, clearing up of tissue around IVC up to below the diaphragm, pringle applied, IVC clamped just below the diaphragm, and opened and cleared of mass, IVC closed hemostasis checked and clamps removed. There was a blood loss of approximately 2500 mL during surgery, and six units of packed red cells and eight units of fresh frozen plasma were given. The surgery lasted for 6 hours. The patient was electively ventilated because of hypothermia and was extubated the next day in the

This is an open access journal, and articles are distributed under the terms of the Creative Commons Attribution-NonCommercial-ShareAlike 4.0 License, which allows others to remix, tweak, and build upon the work non-commercially, as long as appropriate credit is given and the new creations are licensed under the identical terms.

**For reprints contact:** WKHLRPMedknow\_reprints@wolterskluwer.com

**How to cite this article:** Farzana N, Tewari P, Sureka S, Dixit A. Parosmia and dysgeusia after intravenous propofol-based general anesthesia: A case report. *Ann Card Anaesth* 2022;25:112-5.

Access this article online	
Quick Response Code:	Website: www.annals.in
	DOI: 10.4103/aca.ACA_93_21

morning, and he did well in the postoperative period. There was no change in manufacturer company of any of the drugs used intraoperatively or postoperatively.

On postoperative day 3, the patient complained of parosmia (distorted smell perception) and dysgeusia (altered taste) after extubation. However, he had a normal smell and taste perception before the surgery. The parosmia got worsened the next day. He complained of an unpleasant exaggerated sense of smell from food and drinks, thus was irregular with his diet. He had also secluded himself from others due to an inflated sense of perception of body odors. The patient had a low mood level due to a continuous exaggerated sense of perception of any olfactory stimulus. There were two episodes of agitated behavior due to parosmia, which had subsided after removing the trigger. The parosmia gradually declined over 1 week from the onset without any intervention, and the patient had absolutely no complaints on postoperative day 15.

There was no medical history of conditions leading to olfactory dysfunction such as head trauma, neurodegenerative disorders, or acute or chronic upper respiratory tract infections. There was no family history of parosmia as well.

The patient was on antibiotic injections (cefoperazone and sulbactam, 1.5 gm BD), injection ondansetron (8 mg BD), injection ranitidine (150 mg BD), and injection paracetamol (1 gm TDS) in the postoperative period. The epidural catheter was removed on postoperative day 4 after ascertaining normal coagulation parameters.

**DISCUSSION**

It is well-known that surgeries involving the brain, head, and neck can cause olfactory impairment. However, various

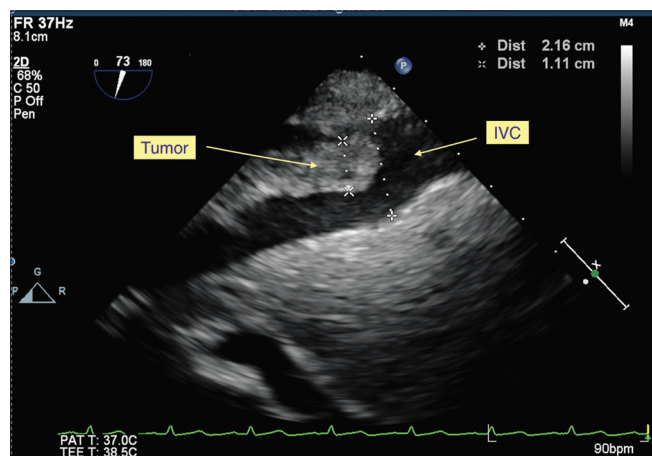
animal studies have shown that drugs used for general anesthesia may also affect olfaction. Therefore, it is difficult to determine whether surgery, anesthesia, or both have caused olfactory impairment in these cases. However, in the presented case report of olfactory dysfunction, it is a thoracoabdominal procedure under general anesthesia. To our knowledge, there are only a few clinical case reports of parosmia in the postoperative period, especially as a consequence of general anesthesia.

The list of drugs affecting olfaction is exhaustive [Table 1]. The mechanism of olfaction dysfunction remains unclear for most drugs, despite their well-documented effect on olfaction.

Regarding anesthetic agents, there are reports and experimental studies on topical anesthetics affecting olfaction.<sup>[1,2]</sup> Salvinelli *et al.*<sup>[1]</sup> reported permanent olfactory dysfunction after endonasal local anesthesia with lidocaine 4%. Welge-Lussen *et al.*<sup>[2]</sup> demonstrated a temporary reduction in olfaction (decrease in discrimination ability) caused by local anesthesia applied in the middle meatus.

In our case, olfactory dysfunction was of acute onset following general anesthesia, with the surgery being unrelated to the anatomical location of the olfactory system. The parosmia was transient and short-lived. However, olfactory dysfunction following general anesthesia had also been described [Table 2], and it had been shown that it could also be a long-standing disorder, as mentioned in previous reports.

Du *et al.*<sup>[3]</sup> reported a case of a 32-year-old female with no comorbidities who underwent uterine curettage with propofol as sole anesthetic had developed post-procedure anosmia and hypogeusia. Computed tomography and magnetic resonance imaging (MRI) had revealed no abnormality. This case had highly suggested that propofol could induce smell and taste disorders.



**Figure 1:** Transesophageal echocardiography showing tumor extending in the inferior vena cava but keeping well below IVC right atrial junction. IVC, inferior vena cava

**Table 1: Drugs affecting olfaction**

Class	Drugs
Antibiotics	Ampicillin, azithromycin, ciprofloxacin, ofloxacin, clarithromycin, tetracycline
Anticonvulsants	Carbamazepine, phenytoin
Anti-histaminic	Chlorpheniramine, pseudoephedrine
Antihypertensives	Nifedipine, amlodipine, captopril, enalapril
Lipid-lowering	Atorvastatin, rosuvastatin, fluvastatin
Anti-neoplastic	Cisplatin, doxorubicin, methotrexate
Anti-depressants	Amitriptyline, desipramine, imipramine

Our patient was on the underlined drugs prior to surgery. As there was no history of parosmia prior to surgery and due to acute onset in the postoperative period, it is unlikely that these drugs may have caused parosmia

**Table 2: Cases of parosmia reported after general anesthesia**

Surgery	General anesthetic agent	Duration of parosmia	Reference
Uterine curettage	Propofol	3 months	Du <i>et al.</i> , 2018 <sup>[3]</sup>
Laparoscopic cholecystectomy	Propofol and sevoflurane	6 months	Dhanani and Jiandg, 2012 <sup>[4]</sup>
Urological procedure (procedure not mentioned)	Sevoflurane and propofol	3 months	Konstantinidis <i>et al.</i> , 2009 <sup>[5]</sup>
Inguinal hernia repair	Propofol	2 years	Jason <i>et al.</i> , 2017 <sup>[6]</sup>

Dhanani and Jiandg<sup>[4]</sup> reported a similar case of a 57-year-old female, who underwent elective laparoscopic cholecystectomy under general anesthesia using propofol and sevoflurane, who had developed the decreased sensation of both tastes and smell 2 weeks after the surgery which had recovered entirely after 6 months.

Konstantinidis *et al.*<sup>[5]</sup> reported a case of a 60-year-old female who had developed parosmia after general anesthesia with sevoflurane and propofol for a urological operation.

Jason *et al.*<sup>[6]</sup> reported a case of a 69-year-old male who underwent inguinal hernia repair with TIVA with propofol, who had developed postoperative anosmia and anosmia, suggesting anesthetic drugs as a causative agent.

Salmi *et al.*<sup>[7]</sup> demonstrated propofol could affect subcortical and cortical gamma-aminobutyric acid (GABA) receptor–ligand binding. GABA is the primary inhibitory neurotransmitter, including many areas of the olfactory system, such as cingulate gyri and olfactory bulbs. Levy and Henkin<sup>[8]</sup>, in experimental studies, found significantly decreased levels of GABA in patients with PHANTOMOSMIA. Thus, any drug that affects the GABA-dependent pathways could potentially jeopardize the olfaction. There is a high probability that anesthetic agents could affect the olfactory system.<sup>[7,8]</sup> In experimental animal studies, propofol disrupted the olfactory and gustatory memories<sup>[9]</sup> and the postoperative ability to recognize odors administered during the anesthesia.<sup>[10]</sup> The inhibitory effect of propofol on the olfactory system was greater than that of fentanyl, demonstrated in experimental studies in rats following infusion of these drugs.<sup>[11]</sup>

As symptoms were acute, diagnoses of cerebral microangiopathy and cortical atrophy were ruled out. An infarct in the olfactory or gustatory pathway is more likely to cause anosmia and ageusia rather than parosmia and dysgeusia.

The patient had no history of upper respiratory tract infection, ruling it out as a causative factor. The patient was on amlodipine and rosuvastatin as well, both of which can distort smell and taste. Still, no previous preoperative

symptoms, acute onset only in the postoperative period, and complete recovery in 2 weeks do not support these drugs as a causative factor.

As the symptoms in our case were short-lived and transient, there was no other associated focal neurological deficit, and there was complete recovery without any medical intervention; imaging was not done. Though functional scan (MRI) done in some previous case reports have demonstrated no evidence of lesion or decreased function.<sup>[3,5,6]</sup>

In this case, we reported a case of parosmia developing after a surgery not involving areas of the potential risk of olfactory disturbance, occurring in the postoperative period, raising suspicion of general anesthetics as a causative factor. As few cases have reported distortion or decreased sensation of smell and taste following general anesthesia, with propofol being the common drug or sole anesthetic, well-designed controlled studies are warranted to establish the complicated relationship between general anesthesia, especially propofol and the olfactory system. As it is quite distressing for the patient, the controlled studies may further guide us to preventive or therapeutic measures in these cases. It would improve the recovery from anesthesia and the quality of patient care.

#### Declaration of patient consent

The authors certify that they have obtained all appropriate patient consent forms. In the form the patient(s) has/have given his/her/their consent for his/her/their images and other clinical information to be reported in the journal. The patients understand that their names and initials will not be published and due efforts will be made to conceal their identity, but anonymity cannot be guaranteed.

#### Financial support and sponsorship

Nil.

#### Conflicts of interest

There are no conflicts of interest.

#### REFERENCES

1. Salvinelli F, Casale M, Hardy JF, D'Ascanio L, Agro F. Permanent anosmia after topical nasal anaesthesia with lidocaine 4%. *Br J Anaesth* 2005;95:838-9.

2. Welge-Lussen A, Wille C, Renner B, Kobal G. Anaesthesia effects on olfaction and chemosensory event related potentials. *Clin Neurophysiol* 2005;115:1394-1.
3. Du W, Xu Z, Wang W, Liu Z. A case of anosmia and hypogeusia as a complication of Propofol. *J Anesth* 2018;32:293-6.
4. Dhanani NM, Jiandg Y. Anosmia and hypogeusia as a complication of general anaesthesia. *J Clin Anaesth* 2012;24:231-3.
5. Konstandinidis I, Tsakiropoulou E, Iakovou I, Douvantzi A, Metaxas S. Anosmia after general anaesthesia: A case report. *Anesthesia* 2009;64:1367-70.
6. Jason JB, Stina O, Jacob R. Loss of Smell and Taste After General Anesthesia: A Case Report, A & A Case Reports: 2017;9:p 346-8. doi: 10.1213/XAA.0000000000000612.
7. Salmi E, Kaisti K, Metsahonkala L, Oikonen V, Aalto S, Nägren K, *et al.* Sevoflurane and Propofol increase 11C-flumazenil binding to gamma-aminobutyric acid A receptors in humans. *Anesth Analg* 2004;99:1420-6.
8. Levy LM, Henkin RI. Brain gamma-aminobutyric acid levels are decreased in patients with phantageusia and phantosmia demonstrated by magnetic resonance spectroscopy. *J Comput Assist Tomogr* 2004;28:721-7.
9. Ishitobi S, Miyamoto T, Oi K, Toda K. Subhypnotic doses of Propofol accelerate the extinction of conditioned taste aversion. *Behav Brain Res* 2003;141:223-8.
10. Jia LJ, Tang P, Brandon NR, Luo Y, XU Y. Effects of propofol general anaesthesia on olfactory relearning. *Sci Rep* 2016;6:33538.
11. Jugovac I, Imas O, Hudetz AG. Supraspinal anaesthesia: Behavioural and electroencephalographic effects of intracerebroventricularly infused pentobarbital, Propofol, fentanyl, and midazolam. *Anesthesiology* 2006;105:764-7.