

Bilateral bullectomy through uniportal video-assisted thoroscopic surgery combined with contralateral access to the anterior mediastinum^{*,**}

Bulectomia bilateral por cirurgia torácica vídeo-assistida uniportal combinada com acesso contralateral ao mediastino anterior

Nan Song, Gening Jiang, Dong Xie, Peng Zhang, Ming Liu, Wenxin He

Abstract

Objective: Video-assisted thoroscopic surgery (VATS) has been a surgical intervention of choice for the treatment of spontaneous pneumothorax (SP) with lung bulla. Our objective was to introduce a uniportal VATS approach for simultaneous bilateral bullectomy and to evaluate its therapeutic efficacy. **Methods:** Between May of 2011 and January of 2012, five patients underwent bilateral bullectomy conducted using this approach. All of the patients presented with bilateral SP. Preoperative HRCT revealed that all of the patients had bilateral apical bullae. We reviewed the surgical indications, surgical procedures, and outcomes. **Results:** All of the patients were successfully submitted to this approach for bilateral bullectomy, and there were no intraoperative complications. The median time to chest tube removal was 4.2 days, and the median length of the postoperative hospital stay was 5.2 days. The median postoperative follow-up period was 11.2 months. One patient experienced recurrence of left SP three weeks after the surgery and underwent pleural abrasion. **Conclusions:** Bilateral bullectomy through uniportal VATS combined with contralateral access to the anterior mediastinum is technically reliable and provides favorable surgical outcomes for patients with bilateral SP who develop bilateral apical bullae. However, among other requirements, this surgical procedure demands that surgeons be experienced in VATS and that the appropriate thoroscopic instruments are available.

Keywords: Pneumothorax; Thoracic surgery, video-assisted; Pleural cavity; Mediastinum.

Resumo

Objetivo: A cirurgia torácica vídeo-assistida (CTVA) tem sido uma intervenção de escolha para o tratamento de pneumotórax espontâneo (PS) com bolha pulmonar. Nosso objetivo foi apresentar uma abordagem de CTVA uniportal unilateral para bulectomia bilateral e avaliar sua eficácia terapêutica. **Métodos:** Entre maio de 2011 e janeiro de 2012, cinco pacientes foram submetidos a bulectomia bilateral por essa abordagem. Todos apresentavam PS bilateral. A TCAR pré-operatória mostrou que todos os pacientes tinham bolhas bilaterais no pulmão apical. As indicações cirúrgicas, os procedimentos de operação e os desfechos foram revisados. **Resultados:** Todos os pacientes foram submetidos com sucesso a essa abordagem para bulectomia bilateral, sem complicações intraoperatórias. A mediana de tempo para a retirada do dreno torácico foi de 4,2 dias, e a mediana do tempo de hospitalização no pós-operatório foi de 5,2 dias. A mediana de seguimento pós-operatório foi de 11,2 meses. Um paciente teve recidiva de PE do lado esquerdo três semanas após a cirurgia e foi submetido a abrasão pleural. **Conclusões:** A bulectomia bilateral utilizando CTVA uniportal combinada com acesso contralateral ao mediastino anterior é tecnicamente confiável e promove desfechos favoráveis para pacientes com PS que desenvolvem bolhas bilaterais no pulmão apical. Entretanto, para a realização desse procedimento cirúrgico, são necessários cirurgiões com experiência em CTVA, instrumentos toracoscópicos longos, entre outras exigências.

Descritores: Pneumotórax; Cirurgia torácica vídeo-assistida; Cavidade pleural; Mediastino.

* Study carried out in the Department of Thoracic Surgery, Shanghai Pulmonary Hospital, Tongji University School of Medicine, Shanghai, China.

Correspondence to: Gening Jiang. Department of Thoracic Surgery, Shanghai Pulmonary Hospital, Tongji University School of Medicine, 507, Zheng Min Rd, Yangpu District, Shanghai, People's Republic of China.

Tel. 86 21 65115006-2080. E-mail: Insongnan@163.com or jgnwp@ymail.com

Financial support: None.

Submitted: 20 June 2012. Accepted, after review: 30 November 2012.

**A versão completa em português deste artigo está disponível em www.jornaldepneumologia.com.br

Introduction

Spontaneous pneumothorax (SP) mostly affects young, thin males.⁽¹⁾ If not managed surgically, SP still has a high recurrence rate (10-80%).⁽²⁾ Recurrence of SP is mainly caused by lung bulla.⁽¹⁾ Therefore, bullectomy is the preferred therapy for recurrent SP. Video-assisted thoracoscopic surgery (VATS) is the only acceptable strategy for the treatment of SP.^(3,4) Currently, most surgeons prefer VATS because it is a minimally invasive method for the resection of lung bullae.^(5,6) However, when the SP and lung bullae are bilateral, either one-stage bilateral bullectomy needs to be performed or a second VATS procedure has to be performed on the other side.⁽⁴⁾ In the present study, we describe a procedure of bilateral bullectomy using uniportal VATS combined with a contralateral access approach to the anterior mediastinum in patients with bilateral SP.

Methods

Between May of 2011 and January of 2012, five patients with bilateral SP underwent bilateral bullectomy through uniportal VATS combined with contralateral access to the anterior mediastinum at Shanghai Pulmonary Hospital, Tongji University School of Medicine, in Shanghai, China. Patient ages ranged from 16 to 19 years. In three patients, the bilateral SP had developed first on just one side, whereas it had developed on both sides simultaneously in two other patients. In one patient, two 24F chest tubes had to be inserted (one on each side), because of massive bilateral lung collapse. The characteristics of the five patients are displayed in Table 1. Chest X-rays showed bilateral SP in two patients (Figure 1A). All of the patients underwent preoperative multidetector HRCT, which revealed bilateral apical bullae in all of the patients (Figure 1B). The data, including

Table 1 - Characteristics of the five patients with bilateral spontaneous pneumothorax.

Patient	Gender	Age, years	Development of bilateral spontaneous pneumothorax	AD	Clinical status at admission	Classification of symptoms	Preoperative treatment
1	Male	19	Simultaneous	None	Chest tenderness/shortness of breath	Severe	Bilateral closed thoracic drainage
2	Male	17	Simultaneous	None	Chest tenderness and pain	Mild	Symptomatic
3	Male	16	Alternate	None	Chest tenderness and cough	Mild	Symptomatic
4	Male	19	Alternate	None	Chest tenderness	Mild	Symptomatic
5	Male	18	Alternate	None	Chest tenderness	Mild	Symptomatic

AD: associated (pulmonary or systemic) disease(s).

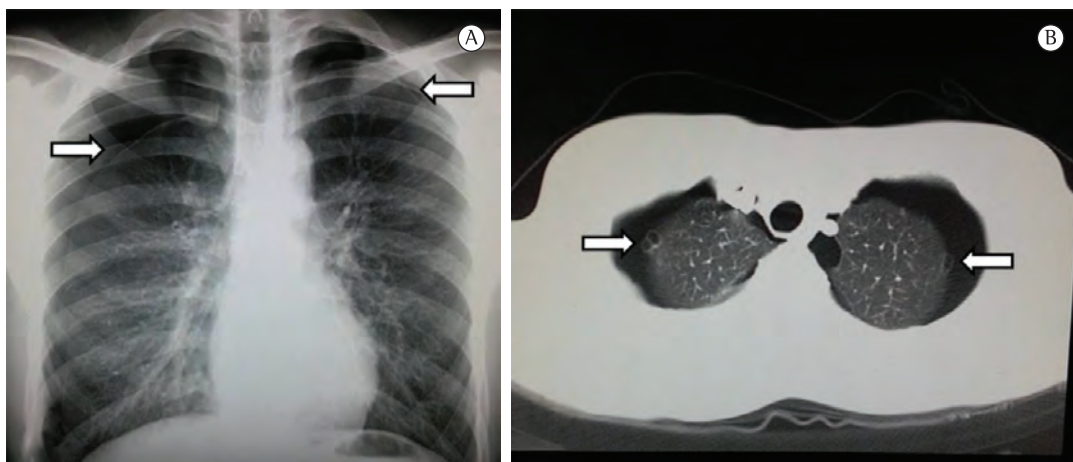


Figure 1 - In A, chest X-ray showing simultaneous bilateral pneumothorax (arrows). In B, CT scan of the chest showing bilateral pneumothorax and bullae (arrows) in the apex of the lung.

surgical time, time to chest tube removal, length of hospital stay, postoperative complications, and recurrences, were retrospectively reviewed. All of the patients and their guardians were informed of the benefits and risks of this new VATS approach prior to the procedure.

The patients were placed in the supine position (30° angle)—four and one being placed left side down and right side down, respectively (Figure 2), so that left-sided or right-sided VATS was performed. After anesthesia, a double-lumen endotracheal tube was inserted for selective lung ventilation.

First, a 10-mm incision was made in the seventh intercostal space at the midaxillary line of the selected side for the placement of a 30° thoracoscope. Two 15-mm incisions were made: one in the third intercostal space at the anterior axillary line and one in the fourth or fifth intercostal space at the anterior axillary line. With the control of contralateral lung inflation, the entire thoracic cavity on the operation side was examined carefully, and the lung bullae found were resected using an endostapler (Echelon 60 Endopath stapler; Ethicon Endosurgery Corp., Cincinnati, OH, USA). The mediastinal pleura was then opened between the sternum and the pericardium with an electric separating hook, and an 8-to-10-cm incision was made into the pleura under the sternum (Figure 3A). Selective deflation of the contralateral lung and appropriate inflation of the lung on the side of the operation were carried out without complication. The 30° thoracoscope and long grasping forceps were inserted into the contralateral thoracic cavity from the mediastinal pleura incision (Figure 3B).

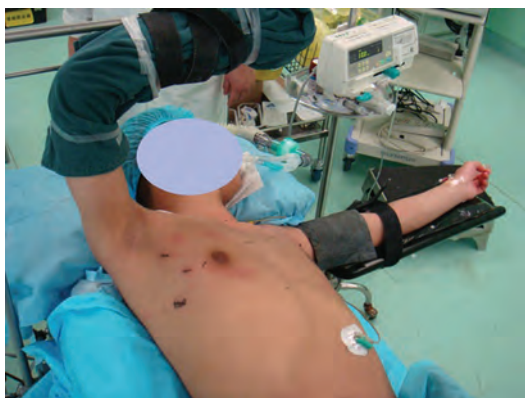

Figure 2 - Intraoperative patient position.

The contralateral thoracic cavity and lung were examined (especially the apex of the contralateral lung), and the apical bullae identified on the HRCT scans were then localized (Figure 3C). The contralateral apical lung bullae were held with a long grasping forceps and resected with the endostapler through the incision in the mediastinal pleura (Figure 3D). In this step, the procedures were carried out gently in order to avoid exerting pressure on the heart when the thoracoscope, the long grasping forceps, and the endostapler device were inserted into the contralateral thoracic cavity above the pericardium.

After bullectomy of the contralateral lung had been performed, the pleural cavity on both sides was carefully examined to ensure that all of the bullae were removed. Pleural abrasion was then performed on the ipsilateral side because it was impossible to do so on the contralateral side through the mediastinal access used in this uniportal VATS procedure. At the end of the procedure, a 24F chest tube was inserted into the contralateral thoracic cavity via the mediastinal incision, and the other end of that tube exited one of the working incisions. A 28F tube was inserted into the thoracic cavity on the ipsilateral side via the camera incision (Figure 4). After confirmation had been made that there was no active bleeding, the surgical incision was closed.

Results

Through the procedure described, bilateral bullectomy was successfully performed in all five of the patients. The median surgical time was 80 min (range, 65–90 min). The median intraoperative blood loss was 50 mL. There were no intraoperative complications, and postoperative recovery was uneventful. The chest tube was removed after a median of 4.2 days (range, 3–7 days), and the median length of postoperative hospital stay was 5.2 days (range, 4–8 days). The median follow-up period was 11.2 months (range, 8–17 months). One patient experienced recurrence of contralateral SP three weeks after the surgery and required VATS on the contralateral side. During that procedure, no bullae were identified and only pleural abrasion was performed. At this writing, that patient had shown no signs of recurrence.

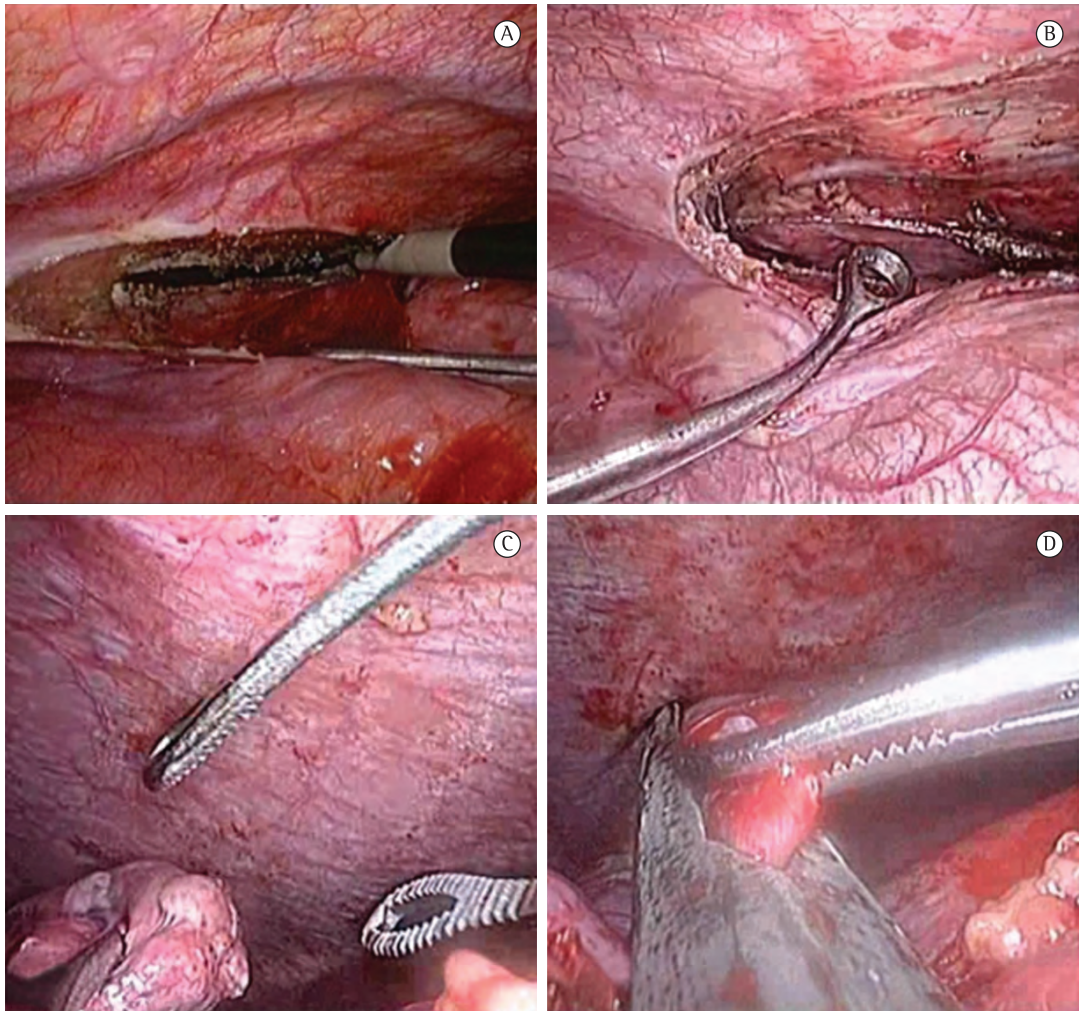


Figure 3 - Photographs taken during the procedure. In A, the incision is being made in the mediastinal pleura between the sternum and the pericardium with a hook electrode. In B, a 30° thoracoscope and a long grasping forceps are inserted into the contralateral thoracic cavity from the mediastinal pleura incision. In C, the apical bulla of the contralateral lung is located. In D, the contralateral lung bulla is resected with an endostapler device through the mediastinal incision.

Discussion

Generally, SP is found in young adults who are tall and thin.⁽¹⁾ There are various conservative strategies for the treatment of SP, such as closed drainage of the pleural cavity and intrathoracic injection of an adhesion agent (such as hypertonic glucose solution). However, if the HRCT scans reveal obvious lung bullae, those conservative treatments will be useless and there is a high risk of recurrence.⁽⁷⁾ Therefore, surgical resection of the lung bullae is the most effective treatment for recurrent SP, and most surgeons employ minimally invasive VATS in order to excise the

lung bullae.^(5,6) According to the literature, most lung bullae are bilateral, resulting in bilateral pneumothorax.⁽⁸⁾ Therefore, it is worth discussing how to perform one-stage bullectomy for the treatment of bilateral SP. One-stage sequential bilateral VATS bullectomy has been considered the best choice. However, that procedure causes patients to suffer from more chronic incisional pain and poor cosmetic outcomes, because of multiple bilateral incisional wounds.⁽⁸⁻¹⁰⁾ Although it has been reported that one-stage sequential bilateral VATS bullectomy is safe and feasible for the treatment of bilateral SP, bilateral bullectomy using the VATS approach requires

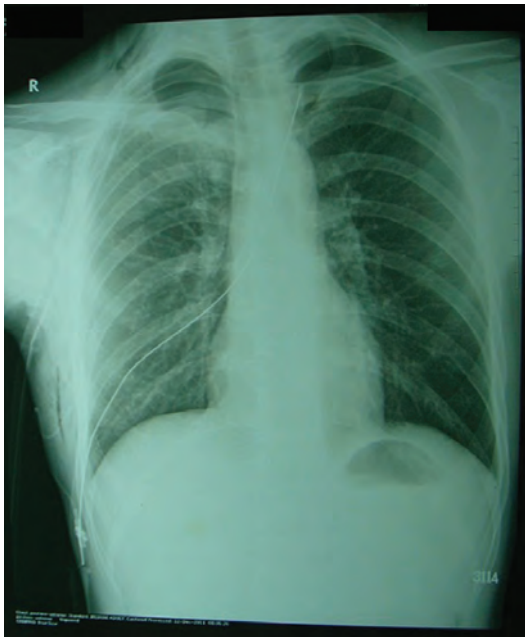

Figure 4 – Postoperative chest X-ray showing the chest tube inserted through the mediastinal incision to the contralateral thoracic cavity.

a longer surgical time,^(4,10) which can increase the risk of intraoperative complications.

Various studies have reported that unilateral thoracotomy using transmediastinal access to the contralateral lung, which is a minimally invasive approach, is effective for the management of bilateral lung lesions.^(11,12) Wu et al.⁽¹³⁾ were the first to report the successful use of bilateral bullectomy through unilateral VATS, in four patients. More recently, Cho et al.⁽¹⁴⁾ introduced a method of apicoposterior transmediastinal access (between the esophagus and vertebrae) to perform simultaneous bilateral VATS bullectomy. In the present study, the procedures for bilateral bullectomy were almost the same as those described by Wu et al.,⁽¹³⁾ although the incision in the anterior mediastinal pleura was smaller, and a longer, longitudinal incision was made in the mediastinum, under the sternum. That incision was 8- to 10-cm in length, which is long enough to allow exploration of the lung on the contralateral side. It is of note that the incision under the sternum is appropriate for resecting apical lung bullae and offers a better operative field at the contralateral pleural cavity than does

an incision made between the esophagus and the vertebrae.

As reported by Wu et al. and Cho et al.,^(13,14) patients undergoing bullectomy by means of unilateral VATS approach experience less chronic pain because there are fewer incisional wounds. In addition, given that there is no incision in the contralateral chest wall, those patients will achieve better cosmetic outcomes, surgical times will be shorter, and there will be less intraoperative blood loss. Our median surgical time (80 min) was shorter than that reported in previous studies.^(4,10) Inserting two drainage tubes into only one side of the thoracic cavity facilitates postoperative ambulatory activities, shortens the time to chest tube removal, and shortens the postoperative hospital stay. Shorter surgical times and shorter postoperative hospital stays also help reduce hospital costs.

In our opinion, this surgical procedure has some prerequisites. First, candidates for this procedure must be carefully selected. The ideal candidate is a tall, thin, young male. Since there is little fat in the anterior mediastinum of such patients, the mediastinal pleura can be readily opened. Preoperative HRCT scans should show that the contralateral bulla are located at the apex of the upper lobe, so that they can be easily reached with the grasping forceps and the endostapler device, through the transmediastinal incision. An experienced anesthetist is needed, because a double-lumen endotracheal tube needs to be inserted and re-inserted for selective lung ventilation throughout the procedure. In addition, long-handled, fine endoscopic instruments and a 30° thoracoscope are needed for collecting the contralateral lung bulla. Most importantly, this surgical procedure should be performed only by surgeons experienced in VATS.

By performing bullectomy through this unilateral VATS procedure, we have accumulated experience. The transmediastinal incision should be made closer to the sternum, where the mediastinal pleura is much thinner and can be easily opened. This surgical procedure can be performed more conveniently if the thoracoscopic approach is carried out on the right side rather than on the left side. Of the five patients who underwent this surgery, only one was submitted to the left side approach. The beating heart always covers the surgical field when the endoscopic instruments are inserted from the left thoracic

cavity to the right. However, exerting pressure on the heart with these instruments can cause cardiac complications, such as arrhythmia. Therefore, bullectomy through this unilateral VATS procedure is more suitably performed on the right side.

This procedure has some contraindications, such as a history of sternotomy and intolerance to one-lung ventilation because of accessibility. If such contraindications are present, one-stage bilateral VATS bullectomy should be performed.

Our results demonstrate that bilateral bullectomy using uniportal VATS combined with contralateral access to the anterior mediastinum is technically reliable and provides favorable surgical outcomes for patients with bilateral SP who develop bilateral bullae in the apical lung. However, among other requirements, the successful execution of this surgical procedure requires that surgeons be experienced in VATS and that the appropriate thoracoscopic instruments be available.

References

1. Roman M, Weinstein A, Macaluso S. Primary spontaneous pneumothorax. *Medsurg Nurs*. 2003;12(3):161-9. PMID:12861753.
2. Cho S, Ryu KM, Jheon S, Sung SW, Kim BH, Huh DM. Additional mechanical pleurodesis after thoracoscopic wedge resection and covering procedure for primary spontaneous pneumothorax. *Surg Endosc*. 2009;23(5):986-90. PMID:18802734. <http://dx.doi.org/10.1007/s00464-008-0083-x>
3. Berger R. Pleurodesis for spontaneous pneumothorax. Will the procedure of choice please stand up? *Chest*. 1994;106(4):992-4. PMID:7523038. <http://dx.doi.org/10.1378/chest.106.4.992>
4. Lang-Lazdunski L, de Kerangal X, Pons F, Jancovici R. Primary spontaneous pneumothorax: one-stage treatment by bilateral videothoracoscopy. *Ann Thorac Surg*. 2000;70(2):412-7. [http://dx.doi.org/10.1016/S0003-4975\(00\)01552-6](http://dx.doi.org/10.1016/S0003-4975(00)01552-6)
5. Treasure T. Minimally invasive surgery for pneumothorax: the evidence, changing practice and current opinion. *J R Soc Med*. 2007;100(9):419-22. PMID:17766914 PMID:1963389. <http://dx.doi.org/10.1258/jrsm.100.9.419>
6. Ng CS, Lee TW, Wan S, Yim AP. Video assisted thoracic surgery in the management of spontaneous pneumothorax: the current status. *Postgrad Med J*. 2006;82(965):179-85. PMID:16517799 PMID:2563704. <http://dx.doi.org/10.1136/pgmj.2005.038398>
7. Haynes D, Baumann MH. Management of pneumothorax. *Semin Respir Crit Care Med*. 2010;31(6):769-80. PMID:21213209. <http://dx.doi.org/10.1055/s-0030-1269837>
8. Chen YJ, Luh SP, Hsu KY, Chen CR, Tsao TC, Chen JY. Video-assisted thoracoscopic surgery (VATS) for bilateral primary spontaneous pneumothorax. *J Zhejiang Univ Sci B*. 2008;9(4):335-40. PMID:18381810 PMID:2276678. <http://dx.doi.org/10.1631/jzus.B0720235>
9. Graf-Deuel E, Knoblauch A. Simultaneous bilateral spontaneous pneumothorax. *Chest*. 1994;105(4):1142-6. <http://dx.doi.org/10.1378/chest.105.4.1142>
10. Ayed AK. Bilateral video-assisted thoracoscopic surgery for bilateral spontaneous pneumothorax. *Chest*. 2002;122(6):2234-7. PMID:12475869. <http://dx.doi.org/10.1378/chest.122.6.2234>
11. Yavuzer S, Enon S, Kumbasar U. Anterior transmediastinal contralateral access. *Interact Cardiovasc Thorac Surg*. 2004;3(2):331-2. PMID:17670252. <http://dx.doi.org/10.1016/j.icvts.2004.01.012>
12. Kodama K, Higashiyama M, Yokouchi H, Takami K, Doki Y, Kabuto T. Transmediastinal approach to exploring the lung contralateral to the thoracotomy site. *Jpn J Thorac Cardiovasc Surg*. 2001;49(5):267-72. PMID:11431943. <http://dx.doi.org/10.1007/BF02913131>
13. Wu YC, Chu Y, Liu YH, Yeh CH, Chen TP, Liu HP. Thoracoscopic ipsilateral approach to contralateral bullous lesion in patients with bilateral spontaneous pneumothorax. *Ann Thorac Surg*. 2003;76(5):1665-7; discussion 1667.
14. Cho DG, Cho KD, Kang CU, Jo MS, Kim YH. Thoracoscopic simultaneous bilateral bullectomy through apicoposterior transmediastinal access for bilateral spontaneous pneumothorax: a challenging approach. *World J Surg*. 2011;35(9):2016-21. PMID:21607818. <http://dx.doi.org/10.1007/s00268-011-1157-9>

About the authors

Nan Song

Physician. Department of Thoracic Surgery, Shanghai Pulmonary Hospital, Tongji University School of Medicine, Shanghai, China.

Gening Jiang

Physician. Department of Thoracic Surgery, Shanghai Pulmonary Hospital, Tongji University School of Medicine, Shanghai, China.

Dong Xie

Physician. Department of Thoracic Surgery, Shanghai Pulmonary Hospital, Tongji University School of Medicine, Shanghai, China.

Peng Zhang

Physician. Department of Thoracic Surgery, Shanghai Pulmonary Hospital, Tongji University School of Medicine, Shanghai, China.

Ming Liu

Physician. Department of Thoracic Surgery, Shanghai Pulmonary Hospital, Tongji University School of Medicine, Shanghai, China.

Wenxin He

Physician. Department of Thoracic Surgery, Shanghai Pulmonary Hospital, Tongji University School of Medicine, Shanghai, China.