



CASE REPORT

**REVISED** Case Report: Perioperative management of a pregnant poly trauma patient for spine fixation surgery [v2; ref status: indexed, <http://f1000r.es/5oo>]

Rashmi Vandse, Meghan Cook, Sergio Bergese

Department of Anesthesiology, Wexner Medical Center, Ohio State University, Columbus, Ohio, 43210, USA

**v2** First published: 29 Jun 2015, 4:171 (doi: [10.12688/f1000research.6659.1](https://doi.org/10.12688/f1000research.6659.1))  
 Latest published: 24 Jul 2015, 4:171 (doi: [10.12688/f1000research.6659.2](https://doi.org/10.12688/f1000research.6659.2))

**Abstract**

Trauma is estimated to complicate approximately one in twelve pregnancies, and is currently a leading non-obstetric cause of maternal death. Pregnant trauma patients requiring non-obstetric surgery pose a number of challenges for anesthesiologists. Here we present the successful perioperative management of a pregnant trauma patient with multiple injuries including occult pneumothorax who underwent T9 to L1 fusion in prone position, and address the pertinent perioperative anesthetic considerations and management.

**Open Peer Review**

Referee Status:

|   | Invited Referees |            |
|---|------------------|------------|
|   | 1                | 2          |
| <b>REVISED</b><br>version 2<br>published<br>24 Jul 2015 | <br>report       | <br>report |
|   | ↑                | ↑          |
| version 1<br>published<br>29 Jun 2015                   | <br>report       | <br>report |

- 1 **Michael Paech**, University of Western Australia Australia
- 2 **Bernard Wittels**, Saint Francis Hospital USA

**Discuss this article**

Comments (0)

**Corresponding author:** Rashmi Vandse ([rashmi.vandse@osumc.edu](mailto:rashmi.vandse@osumc.edu))

**How to cite this article:** Vandse R, Cook M and Bergese S. **Case Report: Perioperative management of a pregnant poly trauma patient for spine fixation surgery [v2; ref status: indexed, <http://f1000r.es/5oo>]** *F1000Research* 2015, 4:171 (doi: [10.12688/f1000research.6659.2](https://doi.org/10.12688/f1000research.6659.2))

**Copyright:** © 2015 Vandse R *et al.* This is an open access article distributed under the terms of the [Creative Commons Attribution Licence](https://creativecommons.org/licenses/by/4.0/), which permits unrestricted use, distribution, and reproduction in any medium, provided the original work is properly cited.

**Grant information:** The author(s) declared that no grants were involved in supporting this work.

**Competing interests:** No competing interests were disclosed.

**First published:** 29 Jun 2015, 4:171 (doi: [10.12688/f1000research.6659.1](https://doi.org/10.12688/f1000research.6659.1))

**First indexed:** 30 Jul 2015, 4:171 (doi: [10.12688/f1000research.6659.2](https://doi.org/10.12688/f1000research.6659.2))

**REVISED** Amendments from Version 1

In response to the reviewer's comments, we have modified our case report:

- We have shortened the obstetric concern paragraph.
- Explained the need for alternative surgical approaches in case of a viable fetus.
- We have also performed some grammar changes.

See referee reports

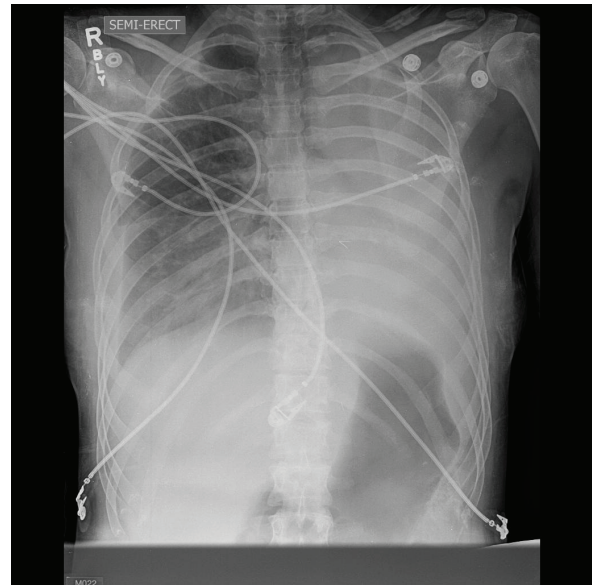
## Introduction

Perioperative management of a pregnant patients requiring non-obstetric surgery is always challenging for an anesthesiologist. The literature documenting anesthetic, surgical and obstetric management of pregnant poly trauma victims undergoing spine surgery in prone positioning is limited. We present a case of a pregnant polytrauma victim with multiple injuries who subsequently underwent spine fixation surgery in prone position and discuss pertinent anesthetic issues and management.

## Case presentation

This is a case of a previously healthy 32 year old female, who presented while 17 weeks pregnant as a level 2 trauma following a motor vehicle collision. She had sustained multiple injuries including Grade II liver laceration, pelvic fracture, bilateral clavicle fractures, C1 transverse process fracture, T11 vertebral body burst fracture, R rib 1–10 fractures, L 1st and 2nd rib fractures, bilateral small pneumothoraces and right pulmonary contusion. She was moderately built and nourished, was 66 inches tall and weighed 136 pounds. Her vital signs on admission showed: heart rate of 96 beats/minute, respiratory rate of 14–18 breaths/minute, blood pressure of 108/56 mmHg, and O<sub>2</sub> saturation of 98% on 2–3 liters of oxygen through nasal cannula. She remained hemodynamically stable throughout and did not show any signs of respiratory distress, although she did have some trouble with coughing and clearing respiratory secretions. A preoperative chest X-ray demonstrated complete collapse of the left lung (Figure 1). The small pneumothorax that was discovered in a computed tomography (CT) of the chest, however, was not apparent in the chest X-ray. After a multidisciplinary discussion, because of the unstable spine fracture, it was decided to perform a posterior T9-L1 fusion under general anesthesia. Her lab values were otherwise normal except for hemoglobin of 9.5 and hematocrit of 27.4.

General anesthesia was induced with propofol, lidocaine, fentanyl and succinylcholine. Following intubation, bronchoscopy was performed and the airway was suctioned given her preoperative chest X-ray. The radial artery was cannulated for hemodynamic monitoring. She was then carefully positioned prone on an open frame Jackson table. Special care was taken to avoid any pressure on the abdomen and all the other pressure points were checked and padded. Anesthesia was maintained with propofol (50 mcg/kg/min) and remifentanyl (0.05–0.12 mcg/kg/min) infusions along with 1.0% sevoflurane in 50% oxygen. Phenylephrine was used to support her blood pressure as needed. She remained hemodynamically stable



**Figure 1.** A preoperative chest X-ray showing complete collapse of the left lung.

throughout the procedure. She was ventilated with a small tidal volume (300–350 ml) and her peak pressure was closely monitored, which stayed less than 20 cm of H<sub>2</sub>O throughout. CT-based image guidance was mostly used by the surgeons to limit the intraoperative fluoroscopy. She received 1300 ml of crystalloids and 500 ml of albumin. She produced 400 ml of urine and lost approximately 200 ml of blood. Total duration of anesthesia was approximately 4 hours. She was successfully extubated at the end of the procedure. She remained stable post operatively. However, she did require 22 days of inpatient care due to multiple injuries sustained during the trauma. She was successively discharged home. She later came back at term and delivered a healthy baby by elective Caesarean section under general anesthesia.

## Discussion

Trauma is estimated to complicate approximately one in twelve pregnancies, and is currently a leading non-obstetric cause of maternal death; moreover, maternal death remains the most common cause of fetal demise<sup>1–4</sup>. Extensive multidisciplinary planning between the surgeons, intensivists, anesthesiologists and obstetricians is essential to ensure fetal and maternal well-being throughout the perioperative period. The anesthetic considerations of this case were many. We had a pregnant patient requiring spine fixation surgery in prone position. Her management was further convoluted by the associated injuries, most importantly b/l rib fractures and small pneumothoraces.

## Obstetric concerns

Optimum management requires a thorough understanding of normal maternal-fetal physiology, maternal physiologic adaptation to pregnancy and altered drug pharmacodynamics and pharmacokinetics. The increased oxygen requirements, decreased functional residual lung capacity and increased risk for aspiration associated with pregnancy complicates perioperative management by decreasing the time available and the margin of safety. These changes are

extensively reviewed in many textbooks and review articles<sup>5-7</sup>. The gestational age and maturity of the fetus as well as the acute maternal injuries were taken into account when formulating the operative plan. As the patient was in her second trimester, delivery of the fetus was not a feasible option. The fetal heart tones (FHT) were monitored pre and post operatively, which remained stable.

The deleterious effects of anesthesia on the human fetus have been considered for many years. As such, any drug has the potential to negatively affect the developing human fetus depending on the dose and the time of exposure and there is no “ideal anesthetic agent”<sup>5-8</sup>.

It is therefore most prudent to postpone elective surgical procedures until after pregnancy or, if possible, to avoid during the first trimester<sup>5,6</sup>. There is no convincing evidence that any particular anesthetic drug at clinically used doses is clearly dangerous to the human fetus<sup>5,6</sup>. Anesthetic goals are to prevent fetal asphyxia by maintaining maternal oxygenation, ventilation and hemodynamic stability and avoid factors that might cause reduction in the uteroplacental perfusion or compromise fetal gas exchange<sup>5-7</sup>. Large survey studies on women who underwent surgery during pregnancy suggest no increase in congenital anomalies among their offspring but rather an increase in the risk for abortions, growth restriction for reasons mostly attributed to the requirement for surgery but not anesthetic administration<sup>5,6</sup>. In our patient, we used a combination of intravenous (IV) anesthetics (propofol and remifentanyl) with 1% sevoflurane in order to permit Somatosensory Evoked Potential (SSEP) and electromyogram (EMG) monitoring and allowed for rapid awakening at the end of the procedure. In clinical practice both propofol and remifentanyl have been used safely in pregnant patients<sup>10-13</sup>. Caution must be exercised while using propofol infusion for long procedures (>10 hours). Two cases of prolonged IV anesthesia with propofol during pregnancy (14–18 h) resulted in mild metabolic acidosis<sup>14</sup>. Maintenance of normal maternal blood pressure is imperative because of the relative passive dependence of the uteroplacental circulation and also to avoid spinal cord ischemia. As such a reduction in maternal arterial pressure causes reduced uteroplacental blood flow and fetal ischaemia. We used phenylephrine infusion to maintain MAP above 70 mmHg based on the earlier studies supporting better maternal cardiovascular stability and improved neonatal acid–base status when phenylephrine was used to treat maternal hypotension<sup>5,6</sup>.

### Surgical positioning

Some of the case reports and small case series have described good fetal outcome among gestational women who had spinal surgery during their pregnancy<sup>15-19</sup>. Caution must be exercised while positioning the patient to avoid any compression on the gravid uterus. Aortocaval compression must be avoided as this can lead to significant reductions in maternal cardiac output, systemic blood pressure, and uterine blood flow. This can also cause epidural venous engorgement and increased surgical bleeding. The study by Nakai *et al.*<sup>20</sup> showed that when pregnant patients were positioned prone by letting the abdomen hang free, there was actually better relief of compression on the large maternal vessels by the gravid uterus when compared to sitting or lateral positions. We used a Jackson frame, which helped to avoid any direct compression of the fetus and the great vessels. One of the drawbacks of prone positioning is inability to easily monitor fetal status or perform emergent

cesarean section for fetal distress in a viable fetus. Spinal surgeries have been performed successfully under epidural anesthesia and lateral positioning has also been utilized safely during the late second and third trimester of pregnancy<sup>15</sup>. These alternative surgical approaches must be discussed with the surgeon whenever feasible in patients with a viable fetus.

### Rib fractures and pneumothorax

The presence of multiple b/l rib fractures and b/l occult (small) pneumothorax impacted our decision making because of the increased risk for expanding the pneumothorax with positive pressure ventilation. The management of an occult or clinically insignificant pneumothorax in acute trauma patients is controversial. The development of tension pneumothorax intraoperatively requiring emergency chest tube insertion has been reported<sup>21</sup>. In a prospective randomized study by Anderson *et al.*, 8 out of 21 patients in the observation group demonstrated progression of the occult pneumothorax and 3 of them developed a tension pneumothorax<sup>22</sup>. They suggested that mechanically ventilated patients with an occult pneumothorax should be managed with a thoracostomy tube. On the contrary, there appears to be a growing recognition that vast majority of cases with an occult pneumothorax can be safely treated without placing a thoracostomy tube in non-ventilated or even mechanically ventilated patients<sup>23-26</sup>. Hence in the absence of clear-cut evidence one must consider the risk versus benefit while making the clinical decision. Thoracostomy is also associated with major complications and has been reported to increase the overall mortality rate<sup>25,26</sup>. As such, in this case, special attention was paid to the peak airway pressures and plethysmography. Additionally, the general surgery team was made aware of the patient, and a chest tube kit was kept in the room, although it was not needed during this case. Our patient also had decreased aeration on the L side of her lung in the preoperative chest X-ray which was thought to be due to an inability to clear the secretions as a result of splinting. Flexible bronchoscopy and aspiration of secretion was performed after intubation. Postoperatively, meticulous attention was paid to adequate pain control and incentive spirometry, which allowed further improvement in the lung aeration. She was also placed on intermittent BiPAP as needed. Thus, we were able to avoid prolonged intubation as well as chest tube insertion.

### Radiation exposure

Additional consideration was also given to radiation exposure. Radiographic studies have shown that radiation exposure poses the greatest teratogenic risk in early pregnancy when organogenesis occurs (2–7 weeks)<sup>5,9</sup>. Exposure after organogenesis may cause growth restriction, microcephaly, and childhood cancer<sup>5,9,27</sup>. Fetal risk of malformations is considered to be low with total radiation exposures of less than 50 to 100 mGy (5 to 10 rads)<sup>27</sup>. In contrast to the negligible risk of teratogenicity, observational studies suggest that there is a slightly higher risk of childhood cancer at radiation doses greater than or equal to 10 mGy<sup>28</sup>. Therefore, exposure to radiation should be minimized whenever possible. Computed tomography produces higher levels of radiation exposure than plain radiographs, but even abdominal and pelvic CT scanning usually produces estimated fetal exposures below those typically associated with adverse fetal/neonatal outcomes<sup>5,28</sup>. In our case, CT-base image guidance was mostly used by the surgeons to limit the intraoperative fluoroscopy.

## Conclusion

Successful surgical intervention was accomplished without any major morbidity or mortality due to thorough systematic assessment of individual issues and stratification of management priorities. The ultimate objective is to provide safe anesthesia to the mother while concurrently minimizing the risk of preterm labor or fetal demise. In our case, the patient was successively discharged home and delivered a healthy baby at term without any complications.

## Consent

Written informed consent for publication of their clinical details and/or clinical images was obtained from the patient.

## Author contributions

RV and MC were involved in preparing the first draft of the manuscript. RV and SB did further literature review and modifications. All authors were involved in the revision of the draft manuscript and have agreed to the final content.

## Competing interests

No competing interests were disclosed.

## Grant information

The author(s) declared that no grants were involved in supporting this work.

## References

- Mirza FG, Devine PC, Gaddipati S: **Trauma in pregnancy: a systematic approach.** *Am J Perinatol.* 2010; **27**(7): 579–586.  
[PubMed Abstract](#) | [Publisher Full Text](#)
- El Kady D: **Perinatal outcomes of traumatic injuries during pregnancy.** *Clin Obstet Gynecol.* 2007; **50**(3): 582–591.  
[PubMed Abstract](#) | [Publisher Full Text](#)
- Mendez-Figueroa H, Dahlke JD, Vrees RA, *et al.*: **Trauma in pregnancy: an updated systematic review.** *Am J Obstet Gynecol.* 2013; **209**(1): 1–10.  
[PubMed Abstract](#) | [Publisher Full Text](#)
- Daponte A, Khan N, Smith MD, *et al.*: **Trauma in pregnancy.** *S Afr J Surg.* 2003; **41**(2): 51–54; discussion 55.  
[PubMed Abstract](#)
- Naughton NN, Cohen SE: **Nonobstetric surgery during pregnancy.** Chestnut DH ed., *Obstetric Anesthesia: principles and practice.* Philadelphia: Elsevier Mosby, 2004; 255–72.
- Reitman E, Flood P: **Anesthetic considerations for non-obstetric surgery during pregnancy.** *Br J Anaesth.* 2011; **107**(Suppl 1): i72–i78.  
[PubMed Abstract](#) | [Publisher Full Text](#)
- Reisner LS, Kuczkowski KM: **Anesthetic considerations for complicated pregnancies.** In: Creasy, Resnik, Iams (eds). *Maternal-fetal medicine.* Elsevier Philadelphia. 2003; 1243–1260.
- Cohen-Kerem R, Railton C, Oren D, *et al.*: **Pregnancy outcome following non-obstetric surgical intervention.** *Am J Surg.* 2005; **190**(3): 467–473.  
[PubMed Abstract](#) | [Publisher Full Text](#)
- Wang LP, Paech MJ: **Neuroanesthesia for the pregnant woman.** *Anesth Analg.* 2008; **107**(1): 193–200.  
[PubMed Abstract](#) | [Publisher Full Text](#)
- Gregory MA, Gin T, Yau G, *et al.*: **Propofol infusion anaesthesia for caesarean section.** *Can J Anaesth.* 1990; **37**(5): 514–20.  
[PubMed Abstract](#) | [Publisher Full Text](#)
- Heesen M, Klöhr S, Hofmann T, *et al.*: **Maternal and foetal effects of remifentanyl for general anaesthesia in parturients undergoing caesarean section: a systematic review and meta-analysis.** *Acta Anaesthesiol Scand.* 2013; **57**(1): 29–36.  
[PubMed Abstract](#) | [Publisher Full Text](#)
- Van de Velde M, Teunkens A, Kuypers M, *et al.*: **General anaesthesia with target controlled infusion of propofol for planned caesarean section: maternal and neonatal effects of a remifentanyl-based technique.** *Int J Obstet Anesth.* 2004; **13**(3): 153–8.  
[PubMed Abstract](#) | [Publisher Full Text](#)
- Mertens E, Saldien V, Coppejans H, *et al.*: **Target controlled infusion of remifentanyl and propofol for cesarean section in a patient with multivalvular disease and severe pulmonary hypertension.** *Acta Anaesthesiol Belg.* 2001; **52**(2): 207–9.  
[PubMed Abstract](#)
- Hilton G, Andrzejowski JC: **Prolonged propofol infusions in pregnant neurosurgical patients.** *J Neurosurg Anesthesiol.* 2007; **19**(1): 67–8.  
[PubMed Abstract](#) | [Publisher Full Text](#)
- Han IH, Kuh SU, Kim JH, *et al.*: **Clinical approach and surgical strategy for spinal diseases in pregnant women: a report of ten cases.** *Spine (Phila Pa 1976).* 2008; **33**(17): E614–619.  
[PubMed Abstract](#) | [Publisher Full Text](#)
- Brown MD, Levi AD: **Surgery for lumbar disc herniation during pregnancy.** *Spine (Phila Pa 1976).* 2001; **26**(4): 440–43.  
[PubMed Abstract](#) | [Publisher Full Text](#)
- Kim HS, Kim SW, Lee SM, *et al.*: **Endoscopic discectomy for the cauda equina syndrome during third trimester of pregnancy.** *J Korean Neurosurg Soc.* 2007; **42**(5): 419–20.  
[PubMed Abstract](#) | [Publisher Full Text](#) | [Free Full Text](#)
- Jea A, Moza K, Levi AD, *et al.*: **Spontaneous spinal epidural hematoma during pregnancy: case report and literature review.** *Neurosurgery.* 2005; **56**(5): E1156; discussion E1156.  
[PubMed Abstract](#)
- Edgcombe H, Carter K, Yarrow S: **Anaesthesia in the prone position.** *Br J Anaesth.* 2008; **100**(2): 165–83.  
[PubMed Abstract](#) | [Publisher Full Text](#)
- Nakai Y, Mine M, Nishio J, *et al.*: **Effects of maternal prone position on the umbilical arterial flow.** *Acta Obstet Gynecol Scand.* 1998; **77**(10): 967–69.  
[PubMed Abstract](#) | [Publisher Full Text](#)
- Rankin D, Mathew P, Kurnutala L, *et al.*: **Tension Pneumothorax during surgery for Thoracic Spine Stabilization in Prone Position: A Case Report and Review of Literature.** *J Investig Med High Impact Case Rep.* 2014; **2**(2).  
[Publisher Full Text](#)
- Enderson BL, Abdalla R, Frame SB, *et al.*: **Tube thoracostomy for occult pneumothorax: a prospective randomized study of its use.** *J Trauma.* 1993; **35**(5): 726–29; discussion 729–30.  
[PubMed Abstract](#)
- Brasel KJ, Stafford RE, Weigelt JA, *et al.*: **Treatment of occult pneumothoraces from blunt trauma.** *J Trauma.* 1999; **46**(6): 987–990; discussion 990–1.  
[PubMed Abstract](#)
- Wilson H, Ellsmere J, Tallon J, *et al.*: **Occult pneumothorax in the blunt trauma patient: tube thoracostomy or observation?** *Injury.* 2009; **40**(9): 928–931.  
[PubMed Abstract](#) | [Publisher Full Text](#)
- Ouellet JF, Trottier V, Kmet L, *et al.*: **The OPTICC trial: a multi-institutional study of occult pneumothoraces in critical care.** *Am J Surg.* 2009; **197**(5): 581–86.  
[PubMed Abstract](#) | [Publisher Full Text](#)
- Ball CG, Kirkpatrick AW, Feliciano DV: **The occult pneumothorax: what have we learned?** *Can J Surg.* 2009; **52**(5): E173–9.  
[PubMed Abstract](#) | [Free Full Text](#)
- McCullough CH, Schueler BA, Atwell TD, *et al.*: **Radiation exposure and pregnancy: when should we be concerned?** *Radiographics.* 2007; **27**(4): 909–917; discussion 917–8.  
[PubMed Abstract](#) | [Publisher Full Text](#)
- Valentin J: **Pregnancy and medical radiation, ICRP Publication 84: Approved by the Commission in November 1999.** *Ann ICRP.* 2000; **30**(1): 1–43.  
[Publisher Full Text](#)

# Open Peer Review

Current Referee Status:



---

## Version 2

Referee Report 30 July 2015

doi:[10.5256/f1000research.7368.r9715](https://doi.org/10.5256/f1000research.7368.r9715)



**Michael Paech**

School of Medicine and Pharmacology, University of Western Australia, Perth, WA, Australia

I am happy to approve the revision of the case report without further comment.

**I have read this submission. I believe that I have an appropriate level of expertise to confirm that it is of an acceptable scientific standard.**

**Competing Interests:** No competing interests were disclosed.

Referee Report 28 July 2015

doi:[10.5256/f1000research.7368.r9647](https://doi.org/10.5256/f1000research.7368.r9647)



**Bernard Wittels**

Continental Anesthesia LLC, Saint Francis Hospital, Evanston, IL, USA

The authors have revised their manuscript in a manner that addresses the concerns of this reviewer, including the mention of alternative surgical approaches and the discussion of the relative benefits of their choice of anesthetic care. Further work in this area of neurosurgery during pregnancy may lead to more rigorous analysis and safer practices.

**I have read this submission. I believe that I have an appropriate level of expertise to confirm that it is of an acceptable scientific standard.**

**Competing Interests:** No competing interests were disclosed.

---

## Version 1

Referee Report 14 July 2015

doi:[10.5256/f1000research.7153.r9227](https://doi.org/10.5256/f1000research.7153.r9227)



**Bernard Wittels**

Continental Anesthesia LLC, Saint Francis Hospital, Evanston, IL, USA

This is a report of an exceptionally unusual presentation of a parturient with multiple trauma needing urgent neurosurgery. The authors do a thorough review of important aspects of parturient physiology, as well as the medical and surgical considerations involved. Still, the authors seem to have followed the typical care of any neurosurgical patient for this procedure and were just serendipitous in having a Jackson-type operating table with an open suspended sling that prevented any untoward pressure on the fetus or fetal circulation while in the prone position. If a more unique approach to neurosurgery or neuroanesthesia in the parturient was introduced and proven successful, this report would have much greater value to its readers.

The main scientific point is that the positioning and monitoring of a non-pregnant patient for neurosurgery serves well for the polytrauma pregnant patient for many reasons as well described, though not directly. Also missing is the inability to easily monitor the fetal status intraoperatively, and the inability to perform emergent cesarean delivery in this position if fetal distress occurs in a viable fetus. Are there modifications in the anesthetic or surgical approach that could accommodate these factors?

**I have read this submission. I believe that I have an appropriate level of expertise to confirm that it is of an acceptable scientific standard, however I have significant reservations, as outlined above.**

**Competing Interests:** No competing interests were disclosed.

Author Response 18 Jul 2015

**Rashmi Vandse**, Wexner medical center at ohio state university, USA

We thank our reviewer for their input. We have modified the case report as suggested.

As the patient was in her early pregnancy, we did not have significant challenge in positioning her prone. Also since the fetus was non viable we didn't encounter any need to modify her positioning. As suggested in the literature, surgery in prone position has been carried out safely during the first and early second trimester. As pointed out by the reviewer, one of the drawbacks of prone positioning is inability to monitor fetal status or perform emergent cesarean section for fetal distress in a viable fetus. Spinal surgeries have been performed successfully under epidural anesthesia and lateral positioning has also been utilized safely during the late second and third trimester of pregnancy<sup>15</sup>. These alternative surgical approaches must be discussed with the surgeon whenever feasible.

**Competing Interests:** No competing interests

Referee Report 10 July 2015

doi:10.5256/f1000research.7153.r9420



**Michael Paech**

School of Medicine and Pharmacology, University of Western Australia, Perth, WA, Australia

This is a case report with an extended discussion of perioperative management in this setting. Although the patient was pregnant, she was in the early second trimester, when the relevance of some physiological changes of pregnancy and the absence of a distended abdomen or a viable fetus mean that the management is mainly specific to trauma issues - pregnancy issues are not well illustrated. Consequently the educational value of this report is diminished.

My main suggestions are:

1. Delete the sentence in the case presentation "On examination....."
2. Add a sentence as to whether an attempt made to confirm fetal viability before and after surgery, and by what method.
3. The Discussion section on "obstetric concerns" is too long, a regurgitation of standard teaching and is not specific to this patient. This should be shortened. Likewise much of the first half on "surgical positioning" is not relevant to this patient.
4. Please check for quality of language. Examples of poor use include "of a pregnant patients" ; "the obstetric team was consulted who..." ; "multiple b/l rib....."; "3 of which..."

**I have read this submission. I believe that I have an appropriate level of expertise to confirm that it is of an acceptable scientific standard, however I have significant reservations, as outlined above.**

**Competing Interests:** No competing interests were disclosed.

Author Response 18 Jul 2015

**Rashmi Vandse**, Wexner medical center at ohio state university, USA

We would like to thank our reviewer for reviewing our case report. We have modified it as per the suggestion. As pointed out by the reviewer, our patient was in her early 2 nd trimester hence lacked the viable fetus or the distended abdomen. Physiologic changes of pregnancy are less pronounced. However as suggested in the literature, surgery during the early pregnancy carry increased risk for miscarriage and it is important to take all precautions to maintain adequate maternal oxygenation and hemodynamic stability which was complicated in our patient due to her polytrauma status.

1. *Delete the sentence in the case presentation "On examination....."- modified*
2. *Add a sentence as to whether an attempt made to confirm fetal viability before and after surgery, and by what method.- FHT were monitored both pre and post operatively which was reassuring.*
3. *The Discussion section on "obstetric concerns" is too long, a regurgitation of standard teaching and is not specific to this patient. This should be shortened. Likewise much of the first half on "surgical positioning" is not relevant to this patient.- Has been shortened. However some of the important obstetric issues have been retained for educational purposes. Surgical positioning – Has been shortened.*
4. *Quality of language has been checked and corrections have been made.*

***Competing Interests:*** No competing interests

---