

Incidental detection of microfilariae in a lymph node aspirate: A case report

Donatus Sabageh, Adetunji S. Oguntola¹, Adebanke M. Oguntola², Olanrewaju O. Bajowa³

Departments of Morbid Anatomy and Histopathology, ¹Surgery, ²Medical Microbiology and Parasitology, and ³Obstetrics and Gynaecology, Lautech Teaching Hospital, Ogbomosho, Oyo State, Nigeria

ABSTRACT

Lymphatic filariasis is a global health problem endemic in Nigeria. Peripheral blood smears are frequently negative for microfilariae in a significant number of infected patients in whom conventional diagnostic methods may also fail to identify the disease. In such cases, fine needle aspiration cytology may play an important role in disease identification. A 49-year-old South-western male Nigerian farmer, presented with a one-year history of a right groin swelling, which became painful 2 weeks before coming to the hospital. A clinical assessment of lymphogranuloma venereum was made to rule out a non-Hodgkin lymphoma. Initial laboratory investigations only showed mild eosinophilia and haematuria. However, fine needle aspiration cytology performed on the swelling showed microfilariae of *Wuchereria bancrofti* for which appropriate treatment was instituted with excellent outcome. This case demonstrates that lymphatic filariasis should be considered in the differential diagnosis of lymph node swellings in the groin and that aspiration cytology may play an important role in its diagnosis, especially in an endemic resource poor country.

Key words: Aspirate, incidental, lymph node, microfilariae

Address for correspondence:

Dr. Adetunji S. Oguntola,
Department of Surgery,
Ladoke Akintola University of
Technology, Ogbomosho,
Oyo State, Nigeria.
E-mail: asoguntola@gmail.com

INTRODUCTION

Lymphatic filariasis is a disabling parasitic disease endemic in over 80 countries including Nigeria with an estimated 120 million infected individuals and 1.2 billion at risk of acquiring the infection.^{1,2} Nigeria is the third most endemic country in the world.²

While mortality from lymphatic filariasis is low, the disease may produce acute or chronic clinical manifestations.³ In fact, lymphatic filariasis has been identified by the World Health Organisation as a leading cause of permanent and long-term disability in the world.⁴

A large majority of infected individuals have asymptomatic microfilaraemia, although peripheral blood smears are frequently negative for microfilariae in a significant number of other patients in whom conventional diagnostic methods may fail to identify the organism.⁵

The demonstration of microfilaria in fine needle aspiration cytology (FNAC) smears and body fluids is not a very common finding.^{6,7} Indeed, only few reports of microfilariae found in smears and aspirates from various body locations have been documented.⁸

Here, we report the incidental finding of microfilaria in a fine needle aspirate from a patient presenting with a groin swelling suspected to be a lymphoma and demonstrate the role of FNAC in the diagnosis of filariasis in a resource-poor setting.

CASE REPORT

A 49-year-old male farmer, domiciled in one of the South-western states of Nigeria, presented at the accident and emergency unit of our hospital with a one-year history of a right groin swelling, which suddenly became painful about 2 weeks before presentation.

The swelling had quadrupled in size over the course of the year. The patient also reported a positive history of progressive weight loss, generalised body itching and associated nocturia with a feeling of incomplete bladder emptying. There were no associated skin changes, fever, visual impairment or gastrointestinal symptoms.

Physical examination showed a middle-aged man, who was afebrile, not pale, anicteric and without pedal

Access this article online	
Quick Response Code:	Website: www.nigeriamedj.com
	DOI: 10.4103/0300-1652.140392

oedema. His vital signs were essentially normal. There was no significant peripheral lymphadenopathy. There was, however, a firm and tender right groin mass, which measured 16 cm × 10 cm and extended from the right anterior superior iliac spine to the root of the penis. The mass was irreducible, immobile and was firmly attached to the overlying skin which appeared normal.

An assessment of inguinal adenitis, possibly due to lymphogranuloma venereum was made to rule out a non-Hodgkin lymphoma.

The patient was commenced on oral doxycycline, intramuscular gentamicin as well as pain relievers pending the results of the laboratory investigations [Table 1].

The abdomino-pelvic ultrasound showed multiple heterogeneous matted superficial groups of lymph nodes. An ultrasound-guided FNAC was therefore performed with the smears showing many microfilariae of *Wucherera bancrofti* in a background of numerous eosinophils, neutrophils and lymphocytes [Figures 1 and 2]. Based on this, a peripheral blood film was prepared from blood sample taken from the patient. This also showed similar microfilariae.

The patient was treated with oral diethylcarbamazine with an appreciable outcome, with almost complete disappearance of the swelling 2 months after discharge from the hospital.

DISCUSSION

The chronic stage of lymphatic filariasis may present as a hydrocoele, lymphadenopathy, lymphoedema or elephantiasis. Unexplained chronic lymphadenopathy is, however, a well- recognised manifestation in children unlike adults in whom lymphoedema is characteristically encountered.¹ Our patient presented

with an uncharacteristic chronic lymphadenopathy. The diagnosis, even in endemic areas, thus depends of a high index of suspicion as a significant number of infected individuals may remain asymptomatic or present to the hospital with vague clinical signs and symptoms that cause a great deal of diagnostic dilemma.⁹ Our index patient is a classical example of the diagnostic confusion that may be encountered even in endemic areas such as South-western Nigeria. The low index of suspicion in this patient may actually be due to the fact that the patient presented to the hospital located in a semi-urban area even though he was domiciled in a rural community, where the disease is known to be more prevalent.

The laboratory diagnosis of filariasis is usually made by finding microfilariae in peripheral blood, chylous

Table 1: Results of laboratory investigations

Test	Patient's result (%)	Reference range (%)
Haemoglobin	11.7 g/dL	14-17.4 g/dL
Total leukocyte count	6,000 /mm ³	4,000- 11,000/mm ³
Differential leucocyte count		
Neutrophil	56	54-62
Lymphocytes	39	24-44
Eosinophils	10	2-6
Electrolytes & Urea		
Na ⁺	139 mEq/L	135-147 mEq/L
K ⁺	4.7 mEq/L	3.5-5.2 mEq/L
HCO ₃ ⁻	24 mg/dL	18-26 mg/dL
Urea	18 mg/dL	7-22 mg/dL
Creatinine	1.2 mg/dL	0.8-1.4 mg/dL
Random blood sugar	110 mg/dL	<120 mg/dL
Urinalysis		
Proteinuria	Negative	Negative
Haematuria	++	Negative
Urine microscopy, culture & sensitivity	Negative	Negative

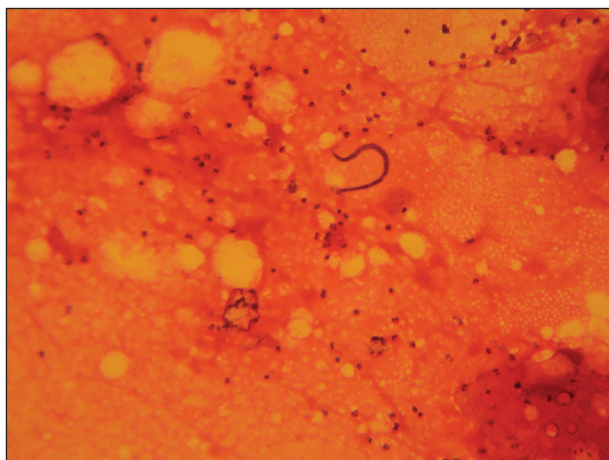


Figure 1: Low power view of microfilaria surrounded by numerous inflammatory cells (x40)

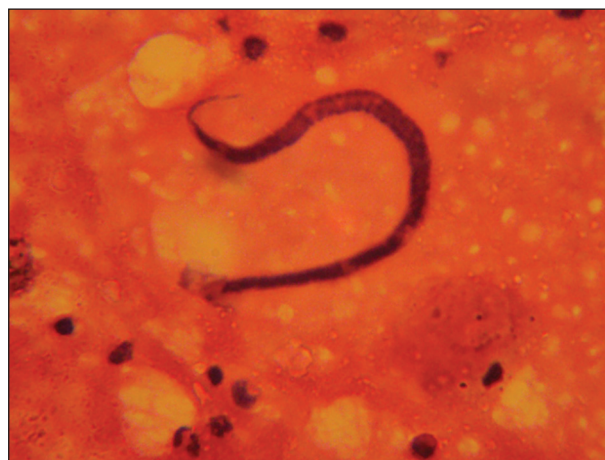

Figure 2: Medium power view showing microfilaria of *Wucherera bancrofti* with clear space free of nuclei at the caudal end. A polymorphic inflammatory infiltrate (including eosinophils) is seen in the background (x100)

urine, hydrocoele fluid and the skin or by detecting the filarial antigen and/or antibody.¹ This notwithstanding, microfilariae may not be seen in the peripheral blood of infected individuals even after a diethylcarbamazine provocation test.¹ This may also be a source of diagnostic difficulty even when the patient presents with classical clinical features or there is a high index of suspicion. In the present case, except for the mild eosinophilia and haematuria, all other laboratory investigations were within normal limits. Microfilariae were detected in peripheral blood only after the diagnosis had been made using FNAC.

Although a review of literature reveals that microfilariae have been detected in smears from virtually every body part, these cases remain at best incidental findings. This is because FNAC is rarely requested for the evaluation of patients for filariasis, especially where the peripheral blood films are negative for microfilariae.¹ Nevertheless, FNAC is known to play an important role in the diagnosis of filariasis in patients who present with mass lesions, which may or may not be clinically suspected to be associated with filarial infection.¹² Such diagnosis depends on the identification of microfilariae and/or fragments of adult worms or their ova within the smears.^{5,10} Fine needle aspiration cytology is thought to be a simple, more convenient, effective and cheap diagnostic method, which may prove invaluable in resource-poor countries where more sophisticated serological diagnostic methods are not readily available. This becomes imperative since many infected patients may have transient microfilaraemia or none at all.

Since, there is at present no radical cure or chemoprophylaxis for the chronic stage of filariasis, early diagnosis and treatment are the best options for infected individuals and FNAC may be an effective tool in this regard especially in clinically unusual cases.

REFERENCES

1. Awolola TS, Manafa OU, Idowu ET, Adedoyin JA, Adeneye AK. Epidemiological mapping of lymphatic filariasis in Southern Nigeria. Preliminary survey of Akinyele local government area. *Afr J Clin Exp Microbiol* 2004;5:231-4.
2. Okon OE, Iboh CI, Opara KN. Bancroftian filariasis among the mbembe people of cross river state, Nigeria. *J Vector Borne Dis* 2010;47:91-6.
3. Akhtar S, Gumashta R, Pande S, Maimoon S, Mahore S. Cytodiagnosis of filarial infection on a non healing ulcer: An unusual presentation and review of literature. *Prog Health Sci* 2012;2:195-9.
4. Michael E, Bundy DA, Grenfell BT. Re-assessing the global prevalence and distribution of lymphatic filariasis. *Parasitology* 1996;112:409-28.
5. Jha A, Shrestha R, Aryal G, Pant AD, Adhikari RC, Sayami G. Cytological diagnosis of bancroftian filariasis in lesions clinically anticipated as neoplastic. *Nepal Med Coll J* 2008;10:108-14.
6. Basu A, Gon S, Bera S, Chakravati S. Breast filariasis: A rare cytomorphological diagnosis. *J Pak Med Stud* 2013;3:103-5.
7. Chauhan K, Agarwal S. Incidental detection of microfilaria in lymph node aspirate — A case report. *Int J Sci Res* 2013;2:424-5.
8. Menon B, Garg A, Karla H, Sharma R. Microfilarial pleura effusion in a case of tropical pulmonary eosinophilia. *Indian J Chest Dis Allied Sci* 2008;50:241-3.
9. Mahesh KU, Potekar RM, Nodule over arm during pregnancy: An unusual presentation of filariasis. *J Interdiscipl Histopathol* 2013;1:230-3.
10. Madhuri SK, Preeti J, Dhar R. Incidental detection of microfilaria on fine needle aspiration cytology (FNAC) of a breast lump — A case report. *Southeast Asian J Case Rep Rev* 2013;2:369-73.
11. Rupinder K, Kandathil JP, Kanwal M, Rajeev K, Cecil J. Filariasis of the breast mimicking inflammatory carcinoma. *Labmedicine* 2009;40:683-5.
12. Kaya B, Namiki T, Tauchi P. Cytological diagnosis of bancroftian filariasis: Clinical implications. *Acta Cytol* 1995;39:1042.

How to cite this article: Sabageh D, Oguntola AS, Oguntola AM, Bajowa OO. Incidental detection of microfilariae in a lymph node aspirate: A case report. *Niger Med J* 2014;55:438-40.

Source of Support: Nil, **Conflict of Interest:** None declared.

Staying in touch with the journal

1) Table of Contents (TOC) email alert

Receive an email alert containing the TOC when a new complete issue of the journal is made available online. To register for TOC alerts go to www.nigeriamedj.com/signup.asp.

2) RSS feeds

Really Simple Syndication (RSS) helps you to get alerts on new publication right on your desktop without going to the journal's website. You need a software (e.g. RSSReader, Feed Demon, FeedReader, My Yahoo!, NewsGator and NewzCrawler) to get advantage of this tool. RSS feeds can also be read through FireFox or Microsoft Outlook 2007. Once any of these small (and mostly free) software is installed, add www.nigeriamedj.com/rssfeed.asp as one of the feeds.