

# An 8-Month-Old Girl With Vesicular Rash

Global Pediatric Health  
Volume 6: 1–4  
© The Author(s) 2019  
Article reuse guidelines:  
sagepub.com/journals-permissions  
DOI: 10.1177/2333794X19838526  
journals.sagepub.com/home/gph



Ali Ozcan, MD<sup>1</sup> , Kristin Kahale, MD<sup>1</sup>,  
and Dan Nguyen, MD<sup>1</sup>

## Abstract

This is a case report of an 8-month-old girl who presented to the pediatric emergency department with vesicular rash and fever. She was diagnosed with eczema herpeticum (EH). EH is an acute, rapidly progressive rare dermatologic disease, and if it is not treated promptly, it can cause life-threatening complications. It often occurs in a patient with an underlying skin disorder, such as atopic dermatitis or other erosive dermatoses. Diagnosis is mainly made by clinical examination usually presented as many very similar shaped and sized eroded vesicles. It is important for clinicians to recognize the sign and symptoms of EH and have a high suspicion for patients with atopic dermatitis who present with rapidly disseminating blisters. Treatment is with oral or intravenous acyclovir. If the patient has widespread eruptions or systemic symptoms such as fever, malaise, and poor oral intake, the patient should be admitted for intravenous acyclovir.

## Keywords

eczema herpeticum, vesicular rash, pediatric rash

Received May 25, 2018. Received revised December 7, 2018. Accepted for publication February 13, 2019.

## Case Report

An 8-month-old Asian Indian female infant presented to the emergency department with worsening rash, fever with a temperature of 38.7°C, and malaise. The patient had a known history of atopic dermatitis (AD; eczema). Her fever originally started 4 days ago followed the next day by an acute rash on her neck. When the rash first erupted, she was evaluated at a nearby children's hospital. She was started on oral cephalexin, clotrimazole cream, and triamcinolone cream due to concern for bacterial and fungal infection. As the rash rapidly progressed on to her face and truncal area, her parents brought her in for reevaluation. Parents denied history of cough, runny nose, and vomiting. They also denied eye redness and eye discharge. The patient was up to date on her vaccinations. Parents denied any recent sick contacts.

On evaluation, she was found to have a rectal temperature to 38.7°C. Her blood pressure was 112/72 mm Hg, pulse 178 beats per minute, and respiratory rate 38 breaths per minute. She was irritable and crying during the physical examination. She had diffuse crusted papules over a previously affected area of AD to her anterior neck, upper anterior trunk, and face (Figure 1). Some areas of newly developed lesions appeared clustered and

had a vesicular appearance. The severe cutaneous eruption coalesced into confluent areas of denudation revealing pink dermis involving approximately 10% of her body surface area.

## Hospital Course

As regions of her rash had a vesicular appearance, swabs from an unroofed vesicular lesion was sent for polymerase chain reaction (PCR) analysis for herpes simplex virus (HSV). Complete blood cell count with differential was within normal limits and comprehensive metabolic panel was significant for aspartate aminotransferase 47 U/L (range = 10-37 U/L) and alanine aminotransferase 31 U/L (range = 3-30 U/L). She was started on intravenous acyclovir prophylactically due to concerns for eczema herpeticum (EH). She was also given intravenous vancomycin for possible concomitant bacterial

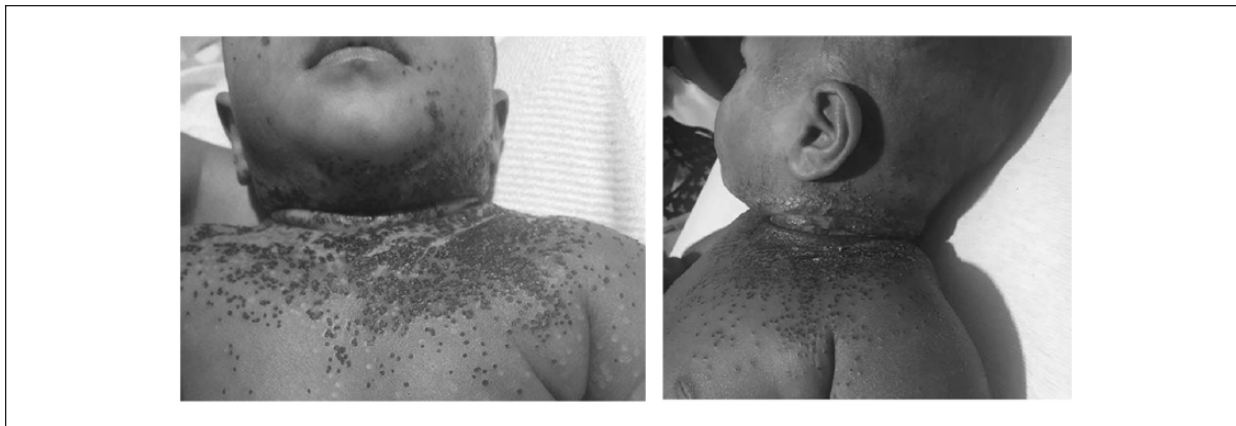<sup>1</sup>Beaumont Health, Royal Oak, MI, USA

### Corresponding Author:

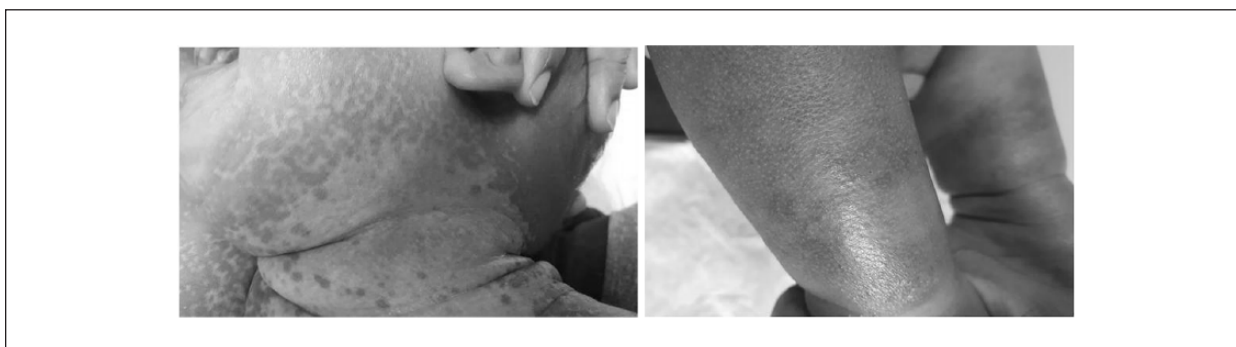Ali Ozcan, Beaumont Health, 3601 W 13 Mile Road, Royal Oak, MI 48073, USA.

Email: thealikemal@yahoo.com





**Figure 1.** A child with atopic dermatitis complicated by eczema herpeticum on the anterior chest, neck, and face. Characteristic monomorphic punched-out lesions coalescing into areas of denudation.



**Figure 2.** Dramatically cleared eczema herpeticum with denuded skin on arms and neck after initial 7 days of intravenous acyclovir followed by 10 days of daily prophylactic oral acyclovir. Characteristic healing pink and hypopigmented macules have replaced previous erosions.

infection. She was admitted to the pediatric unit due to severity of symptoms and malaise.

The next day she was evaluated by multiple consultants including pediatric infectious disease, dermatology, and ophthalmology, since she had vesicles on the face in close proximity to the eyes. No evidence was found for herpetic keratitis. PCR for HSV-1/HSV-2 was found to be positive for HSV-1. Bacterial culture demonstrated rare *Staphylococcus aureus* (sensitive to amoxicillin/clavulanic acid) and rare *Enterococcus faecalis* with no polymorphonuclear cells. As per discussion with infectious disease and dermatology, wound culture interpreted as contaminant from skin flora. Vancomycin was discontinued and no other antibiotics was ordered. The infant was hospitalized for 7 days due to relapsing fever and poor feeding. The patient was eventually transitioned to oral acyclovir. She was discharged home with plans to complete a 14-day course of oral acyclovir in addition to 7 days of topical acyclovir.

She was followed-up by infectious disease specialist in the outpatient clinic 10 days after discharge. At follow-up, the patient was found to have significant improvement of rash, and oral acyclovir was discontinued. Parents were advised to continue topical acyclovir 5% ointment, but instructed to apply twice daily only to the denuded skin areas and continue topical triamcinolone ointment on arms and legs twice daily. (Figure 2).

### Ethical Approval and Informed Consent

This study was approved by the Beaumont Health Research Institute Ethics Committee (Approval No.: 2019-018). Patient consent was not required by an institutional review board for the case report because HIPAA (Health Insurance Portability and Accountability Act) compliance has been confirmed by the Institutional Privacy Office.

## Final Diagnosis

A case of eczema herpeticum with concurrent superinfection.

## Discussion

Eczema herpeticum, traditionally known as Kaposi varicelliform eruption, is an acute, rapidly progressive skin infection due to a virus. EH often occurs in a patient with underlying skin disorder, such as AD or other erosive dermatoses.<sup>1</sup> This inflammatory state creates an impaired skin barrier that increases risk for bacterial and viral infection. EH is an easily missed entity and may lead to multiple organ system compromise if not treated promptly.<sup>2</sup> With increased use of antimicrobial therapy, mortality rates are low.<sup>3,4</sup>

Both sexes are affected equally and there is no seasonal variation in presentation. Transmission is usually by direct contact with infected secretions. Higher risk patients include those identified with early onset of AD, extensive skin involvement, eczematous lesions located on the head and neck, and high immunoglobulin E levels.<sup>5</sup> Children who are young (1 year or younger) or have systemic illness (ie, fever) are more likely to require hospitalization.<sup>6,7</sup> AD approximately affects 17% of children and EH occurs in less than 3% of AD patients.<sup>8</sup> HSVs are the main causative agents.<sup>1</sup> Overall, it is estimated that 90% of the population have at least one of the viruses, HSV-1 and HSV-2, the most prevalent virus being HSV-1. In early childhood, HSV-1 is thought to be acquired from close contact with family.<sup>9</sup> The prevalence of HSV-1 minimally increases after childhood,<sup>9</sup> suggesting majority of transmission in early age.

Herpes simplex virus (HSV-1 or HSV-2) is considered the main causative agent but other viruses such as Coxsackie A16, vaccinia, varicella zoster, and smallpox may rarely cause EH.<sup>1</sup> Since HSV is the usual cause of EH, acyclovir should be started if there is any clinical suspicion as it is hard to differentiate among the other viral causes. Although pathogenesis is not clearly explained, there are multiple theories. Epidermal barrier breakdown of the stratum corneum may create an environment for HSV to grow.<sup>2</sup> Impairment in both cell-mediated and humoral immunity in addition to increased Th-2 cytokine levels may predispose to EH.<sup>1,2</sup> AD patients are often colonized with pathogenic *Staphylococcus*. This leads to high bacterial superinfection rates with EH. HSV and *Staphylococcus* can penetrate the skin rapidly due to skin breakdown in AD patients, which can lead to viremia and bacteremia. Ninety percent of pediatric cases are secondarily infected with *Staphylococcus*

*aureus* or group A *Streptococcus*.<sup>2,10</sup> Fortunately, overall mortality rates are extremely low.

Diagnosis of EH can be difficult to establish, and clinicians should have a high index of suspicion. Diagnosis is made primarily on clinical findings. Typical skin findings are widespread clusters of monomorphic umbilicated vesicles and pustules. These skin findings can evolve to hemorrhagic vesicles and punched-out erosions, which may coalesce if not treated. Initially, the rash will start in regions of preexisting eczema, but then can spread to involve normal skin. Skin changes are most frequently seen on the trunk, neck, and head. Lesions can also affect the eye and cause keratoconjunctivitis. Sometimes, skin lesions may not appear with the characteristic findings of grouped vesicles on an erythematous base.<sup>1,2,11</sup> Some patients may develop systemic symptoms including fever, malaise, and lymphadenopathy. Differential diagnosis may include impetigo, arthropod bites, scabies, papular urticaria, varicella, and bacterial superinfection.

A previous study identified the clinical features of patients with EH, which included generalized eruption 76%, appearance of bacterial infection 66%, fever 56%, and systemic symptoms 37%.<sup>7</sup> Dissemination of HSV may also involve multiple organ involvement, DIC (disseminated intravascular coagulation), and meningitis/encephalitis.

Tzanck smear can be done by scraping the floor of an open vesicle. Multinucleated giant cells will be seen on Wright-Giemsa stain but the sensitivity depends on the operator and does not differentiate between HSV-1 and HSV-2 or varicella zoster virus. Direct fluorescent antibody staining, viral culture, PCR for HSV-1 and HSV-2, or Western blot assay are the other tests that can help diagnose HSV.<sup>1,2,10,12</sup>

Acyclovir is the traditional therapy. If the patient has widespread eruptions or systemic symptoms such as fever, malaise, lymphadenopathy, and poor oral intake, the patient should be admitted for parental antiviral medication immediately.<sup>6</sup> Oral acyclovir has low bioavailability, so it should only be used for mild cases. A previous study compared delayed acyclovir and the outcomes of children hospitalized with EH and found that each additional day delay in acyclovir initiation was associated with greater percent increase in length of hospital stay (LOS).<sup>13</sup> It is highly important to recognize EH promptly and start treatment early in the clinical course. In patients with recurrent EH, chronic suppressive therapy of oral acyclovir should be considered.<sup>2</sup>

Empiric antibiotics for all children have not been shown to improve outcomes.<sup>4</sup> However, appropriate anti-*Staphylococcus* and anti-streptococcal intravenous antibiotic should be added especially if significant

serous crusting is present until the results of bacterial skin swab and blood cultures resulted.<sup>1,2,10</sup>

For topical steroid use, there is currently no consensus. Topical steroids could reduce the immune response to the virus and increase the spread of HSV infection, but at the same time, they might help restore the integrity of the skin in AD. A previous study compared the effect of topical corticosteroids on LOS in children with EH. In this multicenter observational study, they did not find an association between topical corticosteroid use on the first day of hospitalization and decreased LOS in children with EH. In contrast, systemic corticosteroid therapy was associated with a longer LOS.<sup>3</sup> It may be prudent to wait until acyclovir treatment has been initiated before starting topical steroids.<sup>13</sup> For patients already taking topical steroids, some experts advise advocating stopping topical steroid for the first 48 hours and reassess and restarting topical steroid if there is clinical improvement.<sup>3,6</sup>

Complications of EH include delayed healing, widespread erosions, denuded skin, keratoconjunctivitis, secondary bacterial infection, and multiple organs may be involved, including brain, lung, and liver, if not treated. Fulminant herpes hepatitis and disseminated intravascular coagulation have been reported before the use of antivirals.<sup>2</sup> Reactivation of EH may occur in 15% to 50% within 6 to 12 months.<sup>14</sup>

There are several case reports regarding EH in the literature.<sup>2,6</sup> Our goal is to increase awareness of a frequently misdiagnosed rash that has high morbidity if not treated appropriately. We aim for this case to be offered as learning experience for readers to work through the case.

## Conclusion

Eczema herpeticum is an easily missed and frequently misdiagnosed disease. Diagnosis is mainly made by clinical examination and usually present as a rash with numerous similar shaped and sized eroded lesions. Systemic symptoms such as fever, malaise, and headache with widespread vesicular eruption should increase the suspicion for EH. When there is a suspicion for EH, acyclovir should be started promptly and prophylactic antibiotics are also recommended to cover *Staphylococcus aureus*.

## Author Contributions

All authors were actively involved in the writing of the article.


## Declaration of Conflicting Interests

The author(s) declared no potential conflicts of interest with respect to the research, authorship, and/or publication of this article.

## Funding

The author(s) received no financial support for the research, authorship, and/or publication of this article.

## ORCID iD

Ali Ozcan  <https://orcid.org/0000-0002-8465-7901>

## References

1. Karray M, Souissi A. Kaposi varicelliform eruption. In: *StatPearls*. Treasure Island, FL: StatPearls; 2018.
2. Blanter M, Vickers J, Russo M, Safai B. Eczema herpeticum: would you know it if you saw it? *Pediatr Emerg Care*. 2015;31:586-588.
3. Aronson PL, Shah SS, Mohamad Z, Yan AC. Topical corticosteroids and hospital length of stay in children with eczema herpeticum. *Pediatr Dermatol*. 2013;30:215-221.
4. Aronson PL, Yan AC, Mohamad Z, Mittal MK, Shah SS. Empiric antibiotics and outcomes of children hospitalized with eczema herpeticum. *Pediatr Dermatol*. 2013;30:207-214.
5. Wollenberg A, Zoch C, Wetzel S, Plewig G, Przybilla B. Predisposing factors and clinical features of eczema herpeticum: a retrospective analysis of 100 cases. *J Am Acad Dermatol*. 2003;49:198-205.
6. Khan A, Shaw L, Bernatoniene J. Fifteen-minute consultation: eczema herpeticum in a child. *Arch Dis Child Educ Pract Ed*. 2015;100:64-68.
7. Luca NJ, Lara-Corrales I, Pope E. Eczema herpeticum in children: clinical features and factors predictive of hospitalization. *J Pediatr*. 2012;161:671-675.
8. Leung DY. Why is eczema herpeticum unexpectedly rare? *Antiviral Res*. 2013;98:153-157.
9. Wald A, Corey L. Persistence in the population: epidemiology, transmission. In: Arvin A, Campadelli-Fiume G, Mocarski E, et al, eds. *Human Herpesviruses: Biology, Therapy, and Immunoprophylaxis*. Cambridge, England: Cambridge University Press; 2007:656-674.
10. Kress DW. Pediatric dermatology emergencies. *Curr Opin Pediatr*. 2011;23:403-406.
11. National Institute for Health and Clinical Excellence. Atopic eczema in children under 12s: diagnosis and management (NICE Clinical Guideline 57). <https://www.nice.org.uk/guidance/cg57>. Accessed March 11, 2019.
12. Frisch S, Siegfried EC. The clinical spectrum and therapeutic challenge of eczema herpeticum. *Pediatr Dermatol*. 2011;28:46-52.
13. Aronson PL, Yan AC, Mittal MK, Mohamad Z, Shah SS. Delayed acyclovir and outcomes of children hospitalized with eczema herpeticum. *Pediatrics*. 2011;128:1161-1167.
14. Yan AC. Papulosquamous eruptions. In: Shaw KN, Bachur RG, eds. *Fleisher and Ludwig's Textbook of Pediatric Emergency Medicine*. 7th ed. Philadelphia, PA: Lippincott Williams & Wilkins; 2015: 441-449.