

# Evaluation of linear accelerator (LINAC)-based stereotactic radiosurgery (SRS) for cerebral cavernous malformations: a 15-year single-center experience

Omer Sager,<sup>a</sup> Murat Beyzadeoglu,<sup>a</sup> Ferrat Dincoglan,<sup>a</sup> Bora Uysal,<sup>a</sup> Hakan Gamsiz,<sup>a</sup> Selcuk Demiral,<sup>a</sup> Kaan Oysul,<sup>a</sup> Bahar Dirican,<sup>a</sup> Sait Sirin<sup>b</sup>

From the <sup>a</sup>Department of Radiation Oncology, <sup>b</sup>Department of Neurosurgery, Gulhane Military Medical Academy and Medical Faculty, Ankara, Turkey

Correspondence: Dr. Omer Sager · Department of Radiation Oncology, Gulhane Military Medical Academy and Medical Faculty, Ankara 06018, Turkey T: +903123044683 F: +903123044680 · omersager@gmail.com

Ann Saudi Med 2014; 34(1): 54-58

DOI: 10.5144/0256-4947.2014.54

**BACKGROUND AND OBJECTIVES:** Surgery is the principal treatment for safely accessible hemorrhagic and symptomatic cavernous malformations. Nevertheless, the role of linear accelerator (LINAC)-based stereotactic radiosurgery (SRS) in the management of high-risk, symptomatic cavernoma lesions warrants further refinement. In this study, we evaluate the use of LINAC-based SRS for cerebral cavernous malformations (CMs) and report our 15-year single-center experience.

**DESIGN AND SETTINGS:** A retrospective study from the Department of Radiation Oncology and the Department of Neurosurgery at Gulhane Military Medical Academy and Medical Faculty, Ankara from April 1998 to June 2013.

**PATIENTS AND METHODS:** Fifty-two patients (22 females and 30 males) with cerebral CM referred to our department underwent high-precision single-dose SRS using a LINAC with 6-MV photons. All patients had at least 1 bleeding episode prior to radiosurgery along with related symptoms. Median dose prescribed to the 85% to 95% isodose line encompassing the target volume was 15 Gy (range, 10-20).

**RESULTS:** Out of the total 52 patients, follow-up data were available for 47 patients (90.4%). Median age was 35 years (range, 19-63). Median follow-up time was 5.17 years (range, 0.08-9.5) after SRS. Three hemorrhages were identified in the post-SRS period. Statistically significant decrease was observed in the annual hemorrhage rate after radiosurgical treatment (pre-SRS 39% vs post-SRS 1.21,  $P < .0001$ ). Overall, there were no radiosurgery-related complications resulting in mortality.

**CONCLUSION:** LINAC-based SRS may be considered as a treatment option for high-risk, symptomatic cerebral CM of selected patients with prior bleeding from lesions located at surgically inaccessible or eloquent brain areas.

Cavernous malformations (CM), also named as “cavernomas,” “cavernous angiomas,” or “cavernous hemangiomas” are low-flow vascular lesions deemed to be in relation with developmental venous anomalies and capillary telangiectasias.<sup>1</sup> CM have a well-established tendency to bleed. Although intracranial hemorrhages are usually mild in severity, severe hemorrhages may lead to significant disability or death.

The rationale for using stereotactic radiosurgery (SRS) in the management of CM is preventing any

subsequent hemorrhages likewise its utilization in arteriovenous malformations (AVMs). Reduction in hemorrhage risk with SRS has been reported in several studies.<sup>2-7</sup> The mechanism of action in SRS is through progressive hyalinization of vessels surrounded by endothelium leading to luminal closure, thus decreasing the hemorrhage risk. Unlike AVM, however, verifying complete obliteration is problematic after CM radiosurgery because angiography may fail to display these angiographically occult lesions. Thus, a close follow-up

of the patients' clinical course is warranted to evaluate the effect of radiosurgical management in CM. In this study, we evaluate the use of linear accelerator (LINAC)-based SRS for cerebral CM and report our 15-year single-center experience.

## PATIENTS AND METHODS

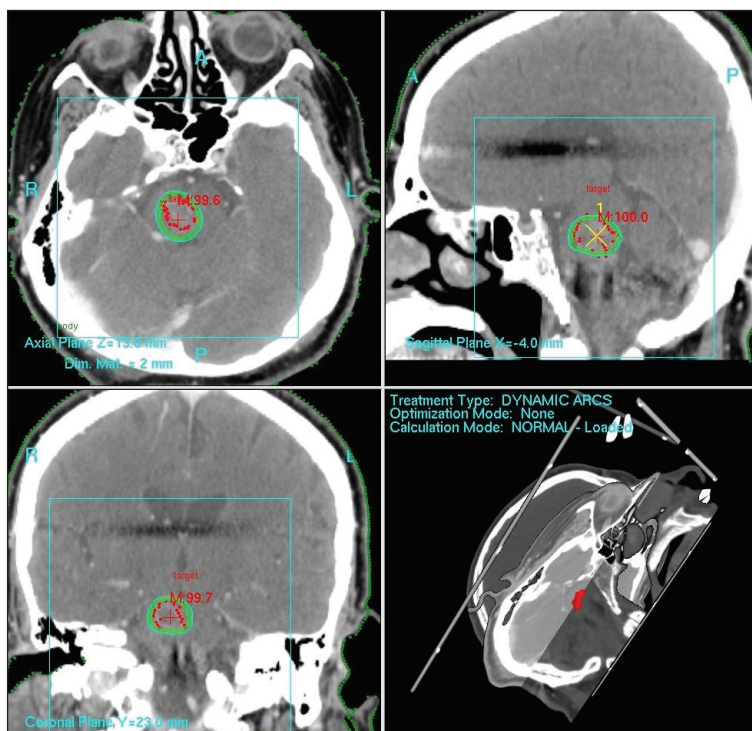
Between April 1998 and June 2013, 52 patients (22 females, 30 males) with CM were treated using LINAC-based single-dose SRS. All these 52 patients referred to our department for CM radiosurgery either had deep-seated lesions, had comorbidities precluding surgery, or refused surgical management. Patients were assessed thoroughly by a multidisciplinary team before deciding on SRS considering the mode of presentation, lesion location, symptomatology, comorbidities, and patient preference. All patients undergoing SRS had at least 1 bleeding episode prior to radiosurgery along with related symptoms. Informed consents of all patients were obtained before SRS. The details of the radiosurgical procedure were previously described.<sup>8</sup> Briefly, the stereotactic head frame was secured with 4 pins to the patients' skull under local anesthesia. Following robust immobilization with the stereotactic frame, contrast-enhanced planning computed tomography (CT) images were acquired. Magnetic resonance imaging (MRI) of all patients obtained 1 day before SRS were fused with the planning CT images to improve contouring accuracy. Target volume was defined as the region of mixed signal change surrounded by the hemosiderin ring. **Figure 1** shows the treatment planning images of a patient with brainstem CM in axial, coronal, sagittal, and three-dimensional planes in the ERGO (CMS, Elekta, UK) planning system.

All patients underwent high-precision single-dose SRS using a LINAC with 6-MV photons. Median treatment volume was 1.4 cc (range, 0.1-5.2). Median dose was 15 Gy (range, 10-20) prescribed to the 85% to 95% isodose line encompassing the target volume (minimum dose [Dmin]: 10.53 Gy, maximum dose [Dmax]: 21.05 Gy). After the completion of radiosurgical treatment, follow-up visits were scheduled for every patient routinely at 3-month intervals for the first year, at 6-month intervals for the second year, and annually afterward consisting of clinical examination, neurologic assessment, and neuroimaging with contrast-enhanced MRI. Patients were instructed to inform the treating physician of any unexpected neurological deterioration regardless of the follow-up schedule.

The appearance of new bleeding in the CM or adjacent brain parenchyma on CT or MRI accompanied by neurologic devastation was defined as post-SRS

bleeding. Pre-SRS and post-SRS annual hemorrhage rates were determined using the equation: hemorrhage rate = total hemorrhages observed / total patient-years observed. Statistical analyses were carried out by SPSS, version 17.0 (SPSS Inc., Chicago, IL, USA) computer program with the level of significance set at  $P < .05$ . Results

Out of the total 52 patients, follow-up data were available for 47 patients (90.4%). Median age was 35 years (range, 19-63). Of the 47 patients with available follow-up, 36 patients (76.6%) experienced 1 hemorrhage, and 11 patients (23.4%) had 2 hemorrhages before SRS ( $58/47 = 1.23$  hemorrhage per patient). Pre-SRS observation period defined as time from symptomatic, neuroimaging-verified hemorrhage to SRS was 28.2 patient-years for these 47 patients. Fifty-eight hemorrhage episodes were identified prior to SRS revealing an annual pre-SRS hemorrhage rate of 39% calculated by excluding the first bleeding episodes of the patients ( $11/28.2 = 39\%$ ). Median follow-up time was 5.17 years (range, 0.08-9.5) after SRS. During the post-SRS period, 3 hemorrhages were identified revealing an annual post-SRS hemorrhage rate of 1.2% in 246.75 observation-years ( $3/246.75 = 1.2\%$ ). Statistically sig-



**Figure 1.** Treatment planning images of a patient with brainstem CM in axial, coronal, sagittal, and 3D planes in ERGO planning system. CM: Cavernous malformation, 3D: three-dimensional.

nificant decrease was observed in the annual hemorrhage rate after radiosurgical treatment (pre-SRS 39% vs post-SRS 1.2%,  $P < .0001$ ).

Symptoms of the patients included headache in 25 patients (53.2%), seizures in 22 patients (46.8%), visual disturbance in 6 patients (12.8%), mild hemiparesis in 4 patients (8.5%), vertigo in 3 patients (6.4%), limb ataxia in 3 patients (6.4%), and diplopia in 2 patients (4.3%). CM were located in the hemispheric area in 32 patients (68.1%), in cerebellum in 7 patients (14.9%), in the brainstem in 5 patients (10.6%), and in the basal ganglia/thalamus in 3 patients (6.4%). Vast majority of the 32 CM lesions in the hemispheres were localized in eloquent brain areas including 14 CM lesions located in the parietal lobe (precentral region, central gyrus, postcentral region, and gyrus angularis), 11 CM lesions located in the occipital lobe, and the remaining 7 CM lesions located in temporal/insular/other regions. No patients had a prior surgery due to either lesion location, comorbidities, or patient refusal. Patient characteristics are shown in **Table 1**.

During the post-SRS follow-up period, 16 of the 25 patients (64%) with headache and 12 of the 22 patients (54.5%) with seizures had a symptomatic improvement after SRS. Three patients (6.4%) had asymptomatic post-LINAC edema with apparent edematous changes detected by MRI. Three patients (6.4%) had deterioration in headache, 2 patients (4.3%) had deterioration in visual disturbance, 1 patient (2.1%) had deterioration in hemiparesis, 1 patient had deterioration in diplopia (2.1%), and 1 patient (2.1%) had deterioration in limb ataxia. Post-SRS bleeding locations in the 3 CM patients included the brainstem, precentral gyrus, and the occipital lobe with the hemorrhages detected at 6, 11, and 14 months after radiosurgery, respectively. Diplopia of the patient with brainstem CM, visual disturbance of the patient with occipital lobe CM, and mild hemiparesis of the patient with precentral gyrus CM deteriorated after the post-SRS hemorrhage as aforementioned. These patients received conservative treatment including steroids, analgesics, and anticonvulsant drugs. There were no procedure-related complications resulting in mortality.

## DISCUSSION

While surgery remains the mainstay of treatment for surgically accessible hemorrhagic and symptomatic CM, the role of SRS in the management of high-risk, symptomatic cavernoma lesions is debated. The main controversy stems from the lack of prospective, randomized controlled trials showing the benefit of SRS over surveillance particularly in the management of

**Table 1.** Patient characteristics.

Variables	N (%)
<b>Gender</b>	
Male	30 (57.7)
Female	22 (42.3)
Median age	35 y (range, 19-63)
<b>Lesion location</b>	
Hemispheric area	32 (68.1)
Cerebellum	7 (14.9)
Brainstem	5 (10.6)
Basal ganglia/Thalamus	3 (6.4)
<b>Symptoms</b>	
Headache	25 (53.2)
Seizures	22 (46.8)
Visual disturbance	6 (12.8)
Mild hemiparesis	4 (8.5)
Vertigo	3 (6.4)
Limb ataxia	3 (6.4)
Diplopia	2 (4.3)
Median treatment volume	1.4 cc (range: 0.1-5.2)
Median dose	15 Gy (range: 10-20)
Pre-SRS annual hemorrhage rate	39.0% in 28.2 observation years
Post-SRS annual hemorrhage rate	1.21% in 246.75 observation years

N: Number, SRS: stereotactic radiosurgery, cc: cubic centimeters, Gy: Gray.

high-risk patients not amenable to surgery. Conducting such a study including an observation group with the identical risks of the treated population would not be that practical, either. Consequently, most of the existing published studies on the utilization of SRS for CM consists primarily of retrospective series with inherent limitations.

Some important reports emphasized the need for vigilance when considering SRS for CM.<sup>9-12</sup> The major points of criticism in these studies included the high risk of radiation-related complications following radiosurgical treatment. CM radiosurgery was reported to have a greater potential than AVM radiosurgery to induce complications with similar doses.<sup>10-13</sup> Another potential drawback of SRS is the absence of immediate bleeding risk elimination during the expected latency period for complete vascular obliteration. Moreover, the evaluation of treatment success is mainly dictated by a close follow-up of the patients' clinical course in CM radiosurgery because there are no strict neuroimaging criteria to gauge complete obliteration of these angiographically occult vascular malformations.

Despite all these caveats, SRS offers the only viable alternative to surgical resection for the management of

selected high-risk patients with CM located at surgically inaccessible or eloquent brain areas to protect them from the future risk of hemorrhages. We observed a statistically significant reduction in the annual hemorrhage rate after radiosurgical management in our study, consistent with other studies.<sup>2-7</sup> Because we did not have an untreated control group in our study to represent the natural history of CM, this finding should be interpreted with caution. Nevertheless, rather than awaiting the deleterious consequences of no intervention during the natural history of CM, earlier implementation of SRS has been suggested in some recent reports.<sup>5,14</sup> This recommended more active strategy may have important implications particularly for the management of high-risk, surgically inaccessible cavernoma lesions considering that the morbidity risk of repeated bleedings may surpass the risk of radiosurgical morbidity. It is also worth mentioning at this point that the radiosurgical technique has shown substantial progress in recent years thanks to the introduction of image-guided technology allowing exact target localization and improved normal tissue sparing, which translates into a decrease in radiosurgery-related complications.

Besides decreasing the subsequent risk of hemorrhages, SRS may also decrease the seizure frequency in patients with CM.<sup>4,15-18</sup> In our study, 12 of the 22 patients (54.5%) with seizures had symptomatic improvement after SRS, consistent with these studies. However, the improvement achieved in seizures and headache in our study may have also been contributed by the use of anticonvulsant drugs and steroid medication in addition to radiosurgical treatment, and the probability of spontaneous symptomatic improvement should not be disregarded.

Despite the dramatic advances in the field of SRS including improved neuroimaging capabilities and radiation treatment planning software, radiosurgery is not devoid of complications. Along with the 3 hemorrhages in the post-SRS period, our patients had deterioration in headache (3 patients, 6.4%), visual disturbance (2 patients, 4.3%), hemiparesis (1 patient, 2.1%), diplopia (1 patient, 2.1%), and limb ataxia (1 patient, 2.1%). This is not surprising, because it is known that the radiation-related complications of CM radiosurgery may be sig-

nificantly higher than that of AVM radiosurgery.<sup>10-13</sup> Permanent complication rates up to 41% have been reported in studies of CM radiosurgery.<sup>2,3,9-12,19</sup>

Given the high rate of complications associated with SRS of CM, the importance of proper patient selection for SRS becomes more pronounced. Before deciding on management, natural history of CM and age of the patient, genetic features, mode of presentation, lesion location and risk of surgical removal should all be considered. Factors associated with clinically significant hemorrhage include family history and presence of a prior hemorrhage.<sup>7,20-22</sup> In the setting of a prior hemorrhage history, Kondziolka et al<sup>21</sup> found a modest increase in hemorrhage risk (0.6% vs 4.5% per annum) in a study with 122 patients whereas Aiba et al<sup>22</sup> noted a dramatic increase (0.4%-23% per annum). In our study, a multidisciplinary team evaluated all patients individually before deciding on SRS. Mode of presentation, lesion location, symptomatology, comorbidities, and patient preferences were taken into account in decision making. All patients either had deep-seated lesions at surgically inaccessible or eloquent brain areas, had comorbidities precluding surgery, or refused surgical management and had at least 1 bleeding episode prior to SRS along with related symptoms. Neuroimaging with MRI was performed in all patients to optimize SRS planning. Consequently, outcomes of radiosurgical treatment in our series appears to be consistent with the related published studies.

Given the rarity of studies using LINACs for CM radiosurgery, our study adds to the current published studies regarding the utilization of this technology to treat patients with CM. The compilation of such data on the use of SRS in CM management merits utmost attention considering that the primary therapeutic approach, namely surgery, may be deemed hazardous in certain circumstances and leaving high-risk patients untreated may pose a significant risk of subsequent bleeding with relevant debilitating complications.

In conclusion, LINAC-based SRS may be considered as a treatment option for high-risk, symptomatic cerebral CM of selected patients with prior bleeding from lesions located at surgically inaccessible or eloquent brain areas.

## REFERENCES

1. Abla A, Wait SD, Uschold T, Lekovic GP, Spetzler RF. Developmental venous anomaly, cavernous malformation, and capillary telangiectasia: spectrum of a single disease. *Acta Neurochir (Wien)*. 2008;150:487-9.
2. Kondziolka D, Lunsford LD, Flickinger JC, Kestle JR. Reduction of hemorrhage risk after stereotactic radiosurgery for cavernous malformations. *J Neurosurg*. 1995;83:825-31.
3. Hasegawa T, McLnerney J, Kondziolka D, Lee JY, Flickinger JC, Lunsford LD. Long-term results after stereotactic radiosurgery for patients with cavernous malformations. *Neurosurgery*. 2002;50:1190-8.
4. Liu KD, Chung WY, Wu HM, Shiau CY, Wang LW, Guo WY, et al. Gamma knife surgery for cavernous hemangiomas: an analysis of 125 patients. *J Neurosurg*. 2005;102:81-6.
5. Nagy G, Razak A, Rowe JG, Hodgson TJ, Coley SC, Radatz MV, et al. Stereotactic radiosurgery for deep-seated cavernous malformations: a move toward more active, early intervention. *Clinical article*. *J Neurosurg*. 2010;113:691-9.
6. Monaco EA, Khan AA, Niranjana A, Kano H, Grandhi R, Kondziolka D, et al. Stereotactic radiosurgery for the treatment of symptomatic brainstem cavernous malformations. *Neurosurg Focus*. 2010;29: E11.
7. Lunsford LD, Khan AA, Niranjana A, Kano H, Flickinger JC, Kondziolka D. Stereotactic radiosurgery for symptomatic solitary cerebral cavernous malformations considered high risk for resection. *J Neurosurg*. 2010;113:23-9.
8. Dincoglan F, Sager O, Gamsiz H, Demiral S, Uysal B, Surenkoc S, et al. Management of arteriovenous malformations by stereotactic radiosurgery: a single center experience. *UHOD – Uluslararası Hematoloji-Onkoloji Dergisi*. 2012;22:107-12.
9. Amin-Hanjani S, Ogilvy CS, Candia GJ, Lyons S, Chapman PH. Stereotactic radiosurgery for cavernous malformations: Kjellberg's experience with proton beam therapy in 98 cases at the Harvard Cyclotron. *Neurosurgery*. 1998;42:1229-38.
10. Karlsson B, Kihlström L, Lindquist C, Ericson K, Steiner L. Radiosurgery for cavernous malformations. *J Neurosurg*. 1998;88:293-7.
11. Pollock BE, Garces YI, Stafford SL, Foote RL, Schomberg PJ, Link MJ. Stereotactic radiosurgery for cavernous malformations. *J Neurosurg*. 2000;93:987-91.
12. Pollock BE. Radiosurgery for cavernous malformations: theory and practice. *Clin Neurosurg*. 2008;55:97-100.
13. Fuetsch M, El Majdoub F, Hoevels M, Müller RP, Sturm V, Maarouf M. Stereotactic LINAC radiosurgery for the treatment of brainstem cavernomas. *Strahlenther Onkol*. 2012;188:311-6.
14. Nagy G, Kemeny AA. Stereotactic radiosurgery of intracranial cavernous malformations. *Neurosurg Clin N Am*. 2013;24:575-89.
15. Bartolomei F, Régis J, Kida Y, Kobayashi T, Vladoyca V, Liscák R, et al. Gamma Knife radiosurgery for epilepsy associated with cavernous hemangiomas: a retrospective study of 49 cases. *Stereotact Funct Neurosurg*. 1999;72:22-8.
16. Kim MS, Pyo SY, Jeong YG, Lee SI, Jung YT, Sim JH. Gamma knife surgery for intracranial cavernous hemangioma. *J Neurosurg*. 2005;102:102-6.
17. Wang P, Zhang F, Zhang H, Zhao H. Gamma knife radiosurgery for intracranial cavernous malformations. *Clin Neurol Neurosurg*. 2010;112:474-7.
18. Lévêque M, Carron R, Bartolomei F, Régis J. Radiosurgical treatment for epilepsy associated with cavernomas. *Prog Neurol Surg*. 2013;27:157-65.
19. Huang YC, Tseng CK, Chang CN, Wei KC, Liao CC, Hsu PW. LINAC radiosurgery for intracranial cavernous malformation: 10-year experience. *Clin Neurol Neurosurg*. 2006;108:750-6.
20. Flemming KD, Link MJ, Christianson TJ, Brown RD Jr. Prospective hemorrhage risk of intracerebral cavernous malformations. *Neurology*. 2012;78:632-6.
21. Kondziolka D, Lunsford LD, Kestle JR. The natural history of cerebral cavernous malformations. *J Neurosurg*. 1995;83:820-4.
22. Aiba T, Tanaka R, Koike T, Kameyama S, Takeda N, Komata T. Natural history of intracranial cavernous malformations. *J Neurosurg*. 1995;83:56-9.