

OPEN

A Systematic Review of Systemic Cobaltism After Wear or Corrosion of Chrome-Cobalt Hip Implants

Bradford D. Gessner, MD, MPH,* Thomas Steck, BS,† Erik Woelber, MSc,‡ and Stephen S. Tower, MD,‡

Objectives: We sought to synthesize data on systemic arthroprosthetic cobaltism, a recently described syndrome that results from wear or corrosion of chrome-cobalt hip components.

Methods: We conducted a systematic literature review to identify all reported cases of systemic arthroprosthetic cobaltism. To assess the epidemiologic link between blood cobalt levels (B[Co]), we developed a symptom scoring tool that evaluated 9 different symptom categories and a category of medical utilization.

Results: We identified 25 patients reported between 2001 and 2014 with a substantial increase in case reports over the past 3 years. Symptoms were diverse and involved the hip (84%), cardiovascular system (60%), audiovestibular system (52%), peripheral motor-sensory system (48%), thyroid (48%), psychological functioning (32%), visual system (32%), and the hematological, oncological, or immune system (20%). The mean latency from implantation to presentation or revision was 41 months (range, 9–99 months). The mean B[Co] was 324 µg/L and 4 patients had levels less than 20 µg/L. The B[Co] but not blood chromium level was highly associated with a quantitative measure of overall symptom severity (r^2 , 0.81; $P < 0.001$). Mean B[Co] and symptom scores were substantially higher in patients with revisions of failed ceramic-on-ceramic prostheses than those with primary metal-on-metal prostheses.

Conclusions: Systemic arthroprosthetic cobaltism is an increasingly recognized complication of wear or corrosion of chrome-cobalt hip implants, may involve a large number of organ systems, and may occur with relatively low B[Co]. There is an urgent need to better define the overall scope of the problem and to develop screening and management strategies.

Key Words: arthroplasty, cobalt, cobaltism, hip, hip replacement

(*J Patient Saf* 2019;15: 97–104)

The ill effects of ingestion or inhalation of cobalt on the peripheral and central nervous system, heart, and thyroid were extensively catalogued in 1981.¹ Historically, iatrogenic cobaltism resulted from oral cobalt chloride treatment of anemia, vocational cobaltism from exposure to cobalt power, and “beer drinkers” cardiomyopathy from a cobalt foam-stabilizing additive. This formerly esoteric malady is important because millions of hips

implanted over the past decade use chrome-cobalt components. It was thought that metal-on-metal articular surfaces would be protected from contact and wear by fluid film lubrication.² Analysis of explanted metal-on-metal hips suggests that this protective mechanism rarely occurs in vivo.³ Rather, metal-on-metal hips can wear or corrode, resulting in periprosthetic metallosis and hypercobaltemia (blood cobalt level, B[Co], >1 µg/L). Metal-on-metal hips comprising a third of American hips implanted over the past decade use chrome-cobalt femoral and acetabular articular surfaces and may have a particularly high risk for generating chrome-cobalt metallosis.^{4,5} A recent survey of 498 patients implanted with metal-on-metal hips found that one-third had B[Co] of more than 4 µg/L, with periprosthetic complications that increased as B[Co] increased.⁶

Subjects without abnormal cobalt exposure have a mean B[Co] of 0.3 µg/L, and 95% have a value of less than 0.6 µg/L.^{7,8} The biologic exposure threshold for B[Co] is 1 µg/L, and an end-of-work-week value of 1 or greater indicates potentially unsafe vocational exposure.⁹ Patients with well-functioning metal-on-metal hip resurfacings have a mean B[Co] of 2 µg/L, and a level greater than 3 µg/L in a patient with a unilateral metal-on-metal hip indicates a degree of periprosthetic chrome-cobalt metallosis that is likely to incite a periprosthetic adverse reaction to metallic debris.^{10,11}

Neurocobaltism and cardiac cobaltism occur when cobalt impairs mitochondrial metabolism resulting in cellular dysfunction or death.^{1,12,13} Studies in rabbits have found that the neurons in the cochlea and retina have the greatest susceptibility to oxidative stress and the greatest likelihood of dying after experimentally induced cobaltism.¹³ Different mechanisms may explain the effects of cobalt or chromium on mood and cognition. Acute cobalt exposure increases neural activity and can result in seizures.^{1,14} Because cobalt may deposit preferentially in the myocardium and pericardial fluid, cobaltism may have predominant or only cardiac symptoms.^{15–18} Because hip replacement often occurs among elderly patients, age-associated decreases in renal cobalt clearance may contribute to increased cobalt levels in some patients.¹⁹

The published peer-reviewed literature contains an increasing number of case reports of systemic cobaltism after hip arthroplasty. We present a review of all cases resulting from metal-on-metal primary arthroplasties or revised arthroplasties with chrome-cobalt femoral heads to define symptom presentation, identify basic characteristics of affected patients, and determine if symptom severity correlates with cobalt level or measures of cobalt exposure.

METHODS

Search Strategy

We conducted a systematic search of PubMed for manuscripts published at any point in the past through June 2014 with no language or geographic restrictions and no specified start date using the following terms: (“cobalt” OR “cobaltemia” OR “cobaltic” OR “cobaltism”) AND (“hip” OR “acetabulum” OR “total hip arthroplasty” OR “case report” OR “cohort”).

From the *Epidemiology and Vaccinology Consulting, Anchorage, AK; †University of Washington School of Medicine, Seattle, WA; and ‡Alaska Arthroplasty Initiative, Anchorage, AK.

Correspondence: Bradford D. Gessner, MD, Epidemiology and Vaccinology Consulting, 11100 Stony Brook Dr, Anchorage, AK, USA (e-mail: bdgessne@yahoo.com).

Conflicts of interest and funding sources: The study was funded by the Alaska Arthroplasty Initiative, which in turn was funded entirely by a grant from Providence Alaska Medical Center. SST was the originator and is the chairperson of the board of AAI and was a full participant in the current project. None of the authors report any conflicts of interest in conducting the evaluation or writing the manuscript. The corresponding author had full access to all study data and had final responsibility for the decision to submit for publication.

Copyright © 2015 The Author(s). Published by Wolters Kluwer Health, Inc. This is an open-access article distributed under the terms of the Creative Commons Attribution-NonCommercial-NoDerivatives License 4.0 (CCBY-NC-ND), where it is permissible to download and share the work provided it is properly cited. The work cannot be changed in any way or used commercially without permission from the journal.

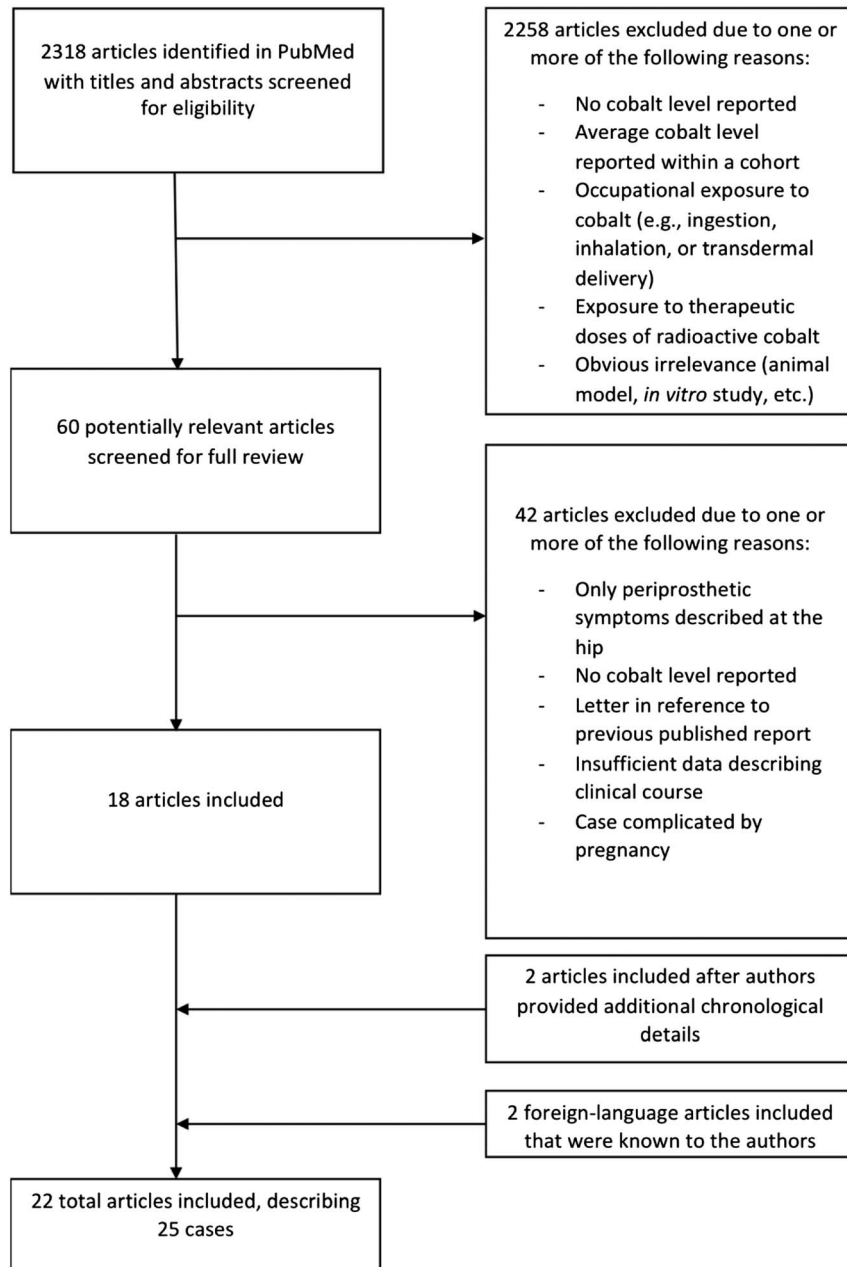


FIGURE 1. Flow chart for a systematic review of systemic cobaltism after wear or corrosion of chrome-cobalt hip implants.

This search yielded 2318 manuscripts whose titles and abstracts were screened for potential inclusion (Fig. 1). We also screened references of retrieved full-text manuscripts. As a last informal check on our search strategy, we conducted a nonsystematic review of EBSCOhost and Google Scholar using the terms “hip replacement” OR “hip arthroplasty” OR “total hip arthroplasty” OR “cobaltism” OR “cobalt” OR “case report” OR “arthroprosthetic cobaltism.” The goal of this search was to determine if any manuscripts were identified that obviously should be included. Neither of these 2 additional search strategies yielded additional manuscripts.

Inclusion criteria included human studies with reported systemic illness, a surgical history of hip arthroplasty with at least one chrome-cobalt component at the bearing surface, and a

reported blood or serum cobalt level greater than 7 $\mu\text{g/L}$. The selected blood cobalt level cutoff was that used by the United Kingdom Medicines and Healthcare Products Regulatory Agency as indicative of a bearing whose wear may induce periprosthetic tissue damage.²⁰ In addition, we only included cases with at least 2 of 3 details of the patient's clinical course: latency to illness, latency to revision, or latency to hip symptoms. Patients who had isolated periprosthetic pseudotumors, neuropathies associated with local inflammation or masses (e.g., femoral or sciatic neuropathy from pseudotumor), and elevated C-reactive protein or erythrocyte sedimentation rate in isolation were not considered to have systemic illness, and their case reports were not included.

Exclusion criteria included occupational exposure to cobalt (e.g., ingestion, inhalation, or transdermal delivery), exposure to

therapeutic doses of radioactive cobalt, and multipatient studies for which measured cobalt levels could not be associated with a specific patient's clinical symptoms. In addition, cases were excluded if the patient had had a diagnosis of a clear underlying disorder that explained all of their systemic symptoms (e.g., Hashimoto disease in a case of thyroid dysregulation). Although we did not limit our search to English language manuscripts, we did not include one manuscript for which we could not obtain a suitable translation.²¹ We also excluded one report of periprosthetic cobaltism during pregnancy to avoid confounding by the numerous symptoms that can complicate pregnancy.²²

We independently reviewed all 60 potentially relevant manuscripts. Where disagreement on inclusion occurred, the reviewers met and developed a consensus opinion on inclusion. This process led to inclusion of 18 manuscripts. Two manuscripts that were initially excluded^{23,24} were included after the authors were contacted, and they provided previously missing chronological details. We included 2 additional manuscripts known previously to one of the authors,^{15,25} which may not have been identified in our search because of their publication in Dutch and Italian, respectively. Although the manuscript by Megaterio et al¹⁵ did not include blood cobalt levels, we elected to include it because it was the first case report of arthroprosthetic cobaltism and the patient reportedly had significant increases in blood and urine cobalt levels. In total, we included 22 manuscripts,^{14–16,23–41} one of which reported 3 patients,³⁷ three of which reported 2 patients,^{32,38,39} and 2 occasions where descriptions of the same patient were reported twice.^{29,34,40,41} This led to results for 25 unique patients.

Data Abstraction and Synthesis

We independently abstracted data using a standard data abstraction form for all 22 relevant manuscripts (Fig. 1). In the 2 instances where a case was described in more than one publication, we used all sources to create the most complete clinical history. One of the current study authors authored 2 case reports included in the current review^{39,40}; clinical histories of patients described in these reports were supplemented by additional data not published in the original manuscripts.

All 25 cases were scored using a cobaltism scoring rubric developed by the authors (Table 1). This rubric was not designed for clinical management purposes but rather for the epidemiological purpose of determining if blood cobalt concentrations correlated with clinical severity. Within organ systems, medical specialists reviewed the scoring tool (for example, a cardiologist for the cardiovascular symptoms, a psychiatrist for psychiatric symptoms, etc). We independently scored each patient. Where discrepancies occurred, these were resolved through consensus. To arrive at a final summary cobaltism score, we added together the scores for each symptom category.

Elevations of blood cobalt are likely not constant throughout the period of hip implantation. Poorly positioned metal-on-metal hips are prone to edge loading resulting in accelerating rates of wear as articular incongruity increases.³ Because of this issue, ideally, cobalt exposure would be based on frequent monitoring of B[Co] for the duration of the prosthetic placement. Practically speaking, most patients had a single prediagnosis or peridiagnosis cobalt level available from the time of diagnosis. Consequently, we assessed 3 measures of exposure: highest B[Co], latency from prosthetic placement to revision, and the product of these 2 variables. As a control analysis, we also assessed blood chromium levels as an exposure variable.

In addition to descriptive analyses, we conducted linear regression analysis to determine the relationship between exposure measures and clinical outcomes. Evaluated clinical outcomes

included overall symptom score and scores within symptom categories. An adjusted model included patients' age and sex. All analyses were conducted with SPSS (IBM, SPSS Statistics, version 19, 2010).

RESULTS

We identified 25 patients with reported systemic arthroprosthetic cobaltism after wear or corrosion of chrome-cobalt hip implants. Sixteen patients (64%) were men, and mean age was 56 years (median, 54 years; range, 39–75 years). Seven of the patients resided in the United States (5 from Alaska), 5 in Australia, 4 in Germany, 3 each in Italy and The Netherlands, and 1 each in Canada, the Czech Republic, and Japan. The number of reported cases increased over time, with 1 case reported during 2001, 1 during 2006, 2 cases during 2009, 3 during 2010, 2 during 2011, 6 each during 2012 and 2013, and 4 through the first half of 2014.

Hip symptoms were identified in 21 patients (84%). Because we only included cases with systemic manifestations, all patients also had symptoms from one of the categories in Table 1 other than hip and medical utilization, most commonly constitutional and cardiovascular symptoms (Table 2). The mean number of systemic symptom categories involved was 3.6 (median, 4; range, 1–7).

All but one included patient (18) had at least one recorded B[Co] with the mean peak level equal to 324 $\mu\text{g/L}$ (range, 10–1085 $\mu\text{g/L}$). Of the 24 patients with available peak B[Co], 4 (17%) had a level of less than 20 $\mu\text{g/L}$ and 11 (46%) had a level of less than 100 $\mu\text{g/L}$. Of 21 persons with blood chromium levels (B[Cr]) available, the mean was 57 $\mu\text{g/L}$ (range, 4.1–249 $\mu\text{g/L}$). Five patients (24%) had a B[Cr] level of less than 20 $\mu\text{g/L}$, and 20 (91%) had a B[Cr] level of less than 100 $\mu\text{g/L}$. Twenty-two patients had information on the latency from the original insertion of a chrome-cobalt component to revision (if this was documented) or presentation (if revision latency was not documented), with a mean of 41 months (range, 9–99 months). One patient had a latency of less than 1 year, 6 (27%) from 1 to less than 2 years, 2 (9%) from 2 to less than 3 years, 5 (23%) from 3 to less than 4 years, and 8 (36%) for 4 years or greater.

Twenty patients (80%) had documentation of hip explantation. Reporting of postexplantation symptoms was nonsystematic and incomplete, making analysis impossible. However, for 19 of the patients, the authors noted that at least some of the symptoms improved; the 20th patient died of cobalt cardiomyopathy 2 months after hip resection,²⁹ the only death reported among the cases we identified. Despite improvement, for all patients where this was noted, at least some symptoms attributable to cobaltism persisted after explantation of the cobalt-containing prosthesis.

During linear regression analysis, the peak B[Co] was associated with the total symptom score on unadjusted and adjusted analyses (Fig. 2 and Table 3). The symptom category most strongly associated with B[Co] was thyroid abnormality. Latency from implantation to explantation or presentation was less strongly associated with total symptom score than peak B[Co]. However, for the individual categories of hip, audiovestibular, and peripheral motor sensory, latency predicted severity better than B[Co]. B[Cr] was not associated with total symptom score and infrequently associated with individual symptom categories.

Sixteen of the 25 patients had a metal-on-metal primary arthroplasty, whereas 9 had a chrome-cobalt revision femoral head after fracture of a primary ceramic-on-ceramic arthroplasty. The mean B[Co] among the 9 patients with revision surgery was 613 $\mu\text{g/L}$ (range, 398–1085 $\mu\text{g/L}$) compared with 104 $\mu\text{g/L}$

TABLE 1. Scoring Tool Developed to Determine Symptom Severity of Arthroprosthetic Cobaltism

Symptom Category	Score	Description
Psychosocial	0	No mood or cognitive problems noted
	1	Minor mood variations or lapses in memory with no more than slight impairment in social or occupational functioning
	2	Disordered mood or cognitive dysfunction that results in treatment or impairs social or occupational functioning
	3	Major mood or thought disorder with related partial social or occupational disability
	6	Major mood or thought disorder resulting in hospitalization or in periods of complete social or occupational disability
	12	Major mood or thought disorder resulting in involuntary hospitalization
Hip (APRMD)	0	No symptoms related to prosthetic hip noted, surveillance limited to venipuncture and radiographs
	1	APRMD with activity related hip pain or small mass (≤ 3 -cm maximal dimension)
	2	APRMD with rest hip pain or mass (>3 -cm maximal dimension) without compromise of periprosthetic tissues
	3	Hip revision indicated for APRMD; or hip revision performed and metallosis with tissue reaction noted at revision surgery
	6	APRMD with loss of major hip tendon or hip dislocation; or hip revision for APRMD with complications necessitating multiple anesthetics
	12	Major neurovascular compromise from APRMD; or resection arthroplasty performed; or revision contraindicated because patient ill from cobaltism
Medical utilization related to cobaltism	0	No monitoring or monitoring for cobaltism limited to venipuncture
	1	Testing beyond venipuncture performed to assess systemic problems consistent with cobaltism (e.g., audiogram, echo)
	2	Invasive outpatient procedures to assess for manifestations consistent with cobaltism; or oral chelation treatment performed
	3	Medical hospital admission required for assessment or treatment of cobaltism manifestations; or parenteral chelation performed
	6	Hip revision indicated to treat patient hospitalized for cobaltism manifestations
	12	Patient admitted to ICU to treat cobaltism manifestations
Constitutional	0	No constitutional symptoms noted
	1	Poor sleep, rashes, or nail changes
	2	Sleep disorder, fatigue, altered taste, headaches, or generalized pain
	3	10%–20% unintentional weight loss, or mild diffuse cerebral anomalies
	6	$>20\%$ unintentional weight loss, cerebral atrophy
	12	Patient institutionalized or dead due to cobaltism manifestations
Audio-vestibular	0	No audiovestibular symptoms noted
	1	Notable tinnitus
	2	Nuisance neurosensory deafness or transient vertigo
	3	Neurosensory deafness for which hearing aides are considered; or unremitting vertigo
	6	Neurosensory deafness for which hearing aides are unequivocally indicated
	12	Patient notably deaf despite hearing aids
Optic	0	No vision symptoms noted
	1	Nonspecific visual changes or cataract surgery
	2	Minor neurosensory blindness, patient remains legal to drive
	3	Major neurosensory blindness, patient has inadequate vision to legally drive
	6	Major neurosensory blindness, patient requires adaptive computer monitor to read
	12	Major neurosensory blindness, patient cannot read even with adaptive computer monitor
Peripheral motor sensory	0	No peripheral motor-sensory problems noted
	1	Mono sensory-motor neuropathy, peripheral dysesthesia, or myalgia
	2	Sensory polyneuropathy, untreated tremor, or imbalance
	3	Motor-sensory polyneuropathy, treated movement disorder, or generalized myopathy
	6	Deep brain stimulation or CSF shunting performed; or patient requires stick, crutches, or walker due to neuropathy, imbalance, or movement disorder
	12	Patient requires a wheelchair owing to neuropathy, imbalance, or movement disorder; or patient develops convulsions

(Continued next page)

TABLE 1. (Continued)

Symptom Category	Score	Description
Cardiovascular (excluding atherosclerotic causes)	0	No cardiovascular abnormality noted
	1	Relative tachycardia, exercise or altitude intolerance; or one drug hypertension
	2	Breathlessness with nonsport activity, diastolic cardiomyopathy, or hypertension requiring multiple drugs
	3	Systolic cardiomyopathy, pericarditis, pericardial effusion, cardiac dyspnea with minimal exertion, or arrhythmia resulting in treatment
	6	Systolic cardiomyopathy with breathlessness at rest; or proximal aortic dissection; or pericardial tamponade; or implantation of defibrillator
Thyroid	12	Referral for heart transplant or placement of heart assist device
	0	Normal thyroid function and tests or no thyroid abnormality noted
	1	Abnormal thyroid test results, thyroid supplementation not indicated
	2	Thyroid-stimulating hormone (TSH) 6–12 mIU/L or thyroid supplementation instituted, but thyroid function studies at time of diagnosis unknown or unreported
Hematologic Oncologic Immune	3	TSH >12 mIU/L or goiter and hypothyroid
	0	Hematocrit <50% or hemoglobin <16.6 g/dL or no hematological abnormality noted
	1	Hematocrit 50%–55% or hemoglobin 16.7–18.3 g/dL
	2	Hematocrit >55% or hemoglobin >18.3 g/dL; or persistent elevations of C-reactive protein >20 mg/L, or erythrocyte sedimentation rate >30 mm/hr; or fevers unexplained by infection; or regionalized lymphadenopathy; or diagnosis of new rheumatologic disorder
	3	Periprosthetic lymphoma or chronic lymphocytic leukemia not requiring treatment
	6	Lymphoma or chronic lymphocytic leukemia requiring treatment
	12	Periprosthetic sarcoma

APRMD, adverse periprosthetic reaction to metallic debris—pain, masses, or tissue damage attributed to metallosis

(range, 10–398 µg/L) among the remaining patients ($P < 0.001$; Student 2-tailed t test). Similarly, the mean symptom score was 35 (range, 22–53) among those with revision surgery and 15 (range, 3–40) among the remaining patients ($P < 0.001$); those with revision surgery had a symptom score significantly higher at the 95% confidence level than other patients for hip symptoms (6.9 versus 2.6; $P = 0.033$), audiovestibular involvement

(3.3 versus 1.0; $P = 0.039$), peripheral motor-sensory involvement (4.8 versus 0.69; $P = 0.030$), and thyroid disease (2.0 versus 0.63; $P = 0.003$).

DISCUSSION

Our study identified 25 cases of reported arthroprosthetic cobaltism that occurred since the initial report during 2001. Case

TABLE 2. Frequency of Symptoms Among 25 Patients With Reported Systemic Arthroprosthetic Cobaltism

Symptom Category	Number With Symptoms in Category (%)	Mean Symptom Score (Range)	Mean age in Years of Affected Patients (Range)	Number (%) Male Among Affected Patients	Mean Blood Cobalt in µg/L Among Affected Patients (Range)	Mean Latency in Months From Hip Implantation to Presentation Among Affected Patients (Range)
Hip	21 (84%)	4.1 (0–12)	56 (42–75)	14 (67%)	324 (10–1085)	37 (9–75)
Constitutional	18 (72%)	1.8 (0–12)	56 (39–75)	13 (72%)	280 (10–1085)	44 (9–99)
Cardiovascular	15 (60%)	3.2 (0–12)	55 (42–75)	14 (93%)	359 (14–1085)	40 (9–99)
Audiovestibular	13 (52%)	1.8 (0–6)	54 (48–68)	8 (62%)	309 (23–898)	30 (9–60)
Peripheral motor sensory	12 (48%)	2.2 (0–12)	57 (48–75)	9 (75%)	341 (16–625)	36 (9–75)
Thyroid	12 (48%)	1.1 (0–3)	56 (49–65)	7 (58%)	461 (18–1085)	35 (9–75)
Psychosocial	8 (32%)	0.72 (0–6)	53 (48–68)	6 (75%)	155 (16–625)	37 (9–60)
Optic	8 (32%)	1.6 (0–12)	52 (39–60)	5 (63%)	366 (45–898)	45 (18–75)
Hematologic, oncologic, immune	5 (20%)	0.36 (0–2)	52 (42–59)	4 (80%)	609 (156–1085)	20 (16–24)
Medical utilization	23 (92%)	5.4 (0–12)	56 (39–75)	16 (70%)	297 (10–1085)	40 (9–99)

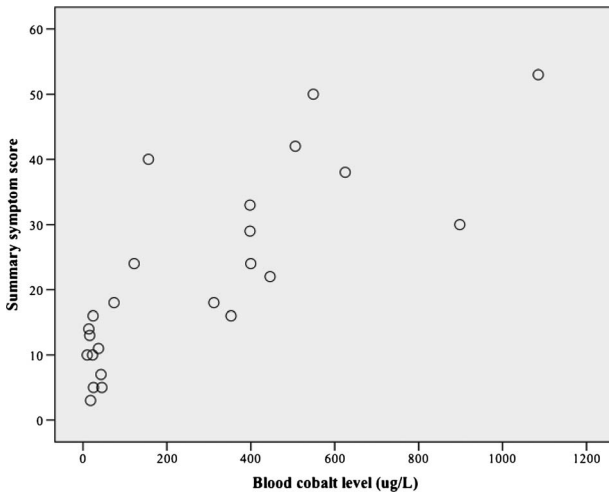


FIGURE 2. Scatter plot of the association between blood cobalt level and a summary clinical symptom score in patients with systemic cobaltism after wear or corrosion of chrome-cobalt hip implants.

reports have accelerated recently and have occurred from 8 countries. Despite the relatively widespread distribution, all but 2 US cases have originated from Alaska, suggesting the true scope of the problem has gone largely unreported. This likely has resulted

from a combination of several factors including the slow onset, the protean symptoms that may mimic many different conditions, lack of uniform screening strategies for at-risk patients, and lack of awareness of arthroprosthetic cobaltism among surgeons and primary care physicians.

An additional difficulty is that hip replacement surgery often occurs in elderly patients or patients with underlying conditions, making it difficult to associate symptoms with cobaltism. In part to address this issue in our review, we developed a symptom scoring tool, which confirmed a strong association between B[Co] but not B[Cr] and symptom severity. This association differed by individual symptom category, with the strongest association between B[Co] and thyroid abnormalities and the weakest with optic abnormalities. This finding may indicate that not all symptoms in the case reports actually resulted from arthroprosthetic cobaltism. It may also indicate that presentation in any particular individual is modified by a variety of factors including underlying illness, age, activity level, and type of physical activities in which the patient engages.

Chrome-cobalt femoral head placement after revision of a fractured ceramic head led to higher B[Co] levels and more severe symptoms than primary metal-on-metal arthroplasty. The mechanism is likely to be due to abrasion of the metal surface by retained ceramic fragments. This was suggested in one case history in which the pieces of the fractured ceramic head were reconstructed and found to be incomplete.¹⁴ Whereas use of a chrome-cobalt head for revision of a failed ceramic-on-ceramic hip likely identifies a particularly high-risk group, the substantial symptoms among those with metal-on-metal primary arthroplasty indicates

TABLE 3. Unadjusted and Adjusted r^2 Values for the Association Between Exposures and Clinical Severity Scores Overall and Within Organ Systems

Clinical Severity Scores	Blood Cobalt Level (B[Co]) in $\mu\text{g/L}$		Latency From Implantation to Explantation or Presentation	B[Co] \times Latency From Implantation to Diagnosis	Blood Chromium Level (B[Cr])
	Unadjusted model r^2 (P value for B[Co])	Adjusted* model r^2 (P value for B[Co])	Adjusted* model r^2 (P value for latency)	Adjusted* model r^2 (P value for B[Co] \times latency)	Adjusted* model r^2 (P value for B[Cr])
Total score [†]	0.63 (<0.001)	0.81 (<0.001)	0.33 (0.018)	0.27 (0.046)	0.21 (0.12)
Hip	0.25 (0.013)	0.29 (0.033)	0.32 (0.017)	0.099 (0.29)	0.039 (0.95)
Psychosocial	0.045 (0.32)	0.22 (0.11)	0.12 (0.72)	0.29 (0.075)	0.15 (0.81)
Constitutional	0.32 (0.004)	0.33 (0.013)	0.059 (0.68)	0.11 (0.37)	0.089 (0.81)
Audiovestibular	0.16 (0.050)	0.18 (0.085)	0.32 (0.018)	0.085 (1.0)	0.080 (0.80)
Optic	0.12 (0.10)	0.13 (0.12)	0.036 (0.58)	0.11 (0.29)	0.021 (0.95)
Peripheral motor sensory	0.14 (0.078)	0.16 (0.064)	0.31 (0.012)	0.007 (0.82)	0.048 (0.38)
Cardiovascular [†]	0.27 (0.009)	0.34 (0.033)	0.11 (0.97)	0.31 (0.040)	0.30 (0.052)
Thyroid	0.32 (0.004)	0.51 (<0.001)	0.20 (0.078)	0.27 (0.75)	0.15 (0.14)
Hematologic, oncologic, immune	0.34 (0.003)	0.38 (0.008)	0.19 (0.072)	0.095 (0.29)	0.11 (0.25)
Medical utilization [†]	0.27 (0.010)	0.29 (0.025)	0.096 (0.53)	0.39 (0.008)	0.35 (0.014)

Associations significant at the 95% confidence level are marked in bold.

*Adjusted for age and sex.

[†]Model with both cobalt and chromium:

- Total score: r^2 , 0.72; chromium, $P = 0.65$; cobalt, $P < 0.001$;

- Medical utilization: r^2 , 0.54; chromium, $P = 0.056$; cobalt, $P = 0.016$;

- Cardiovascular: r^2 , 0.48; chromium, $P = 0.21$; cobalt, $P = 0.026$.

screening and management strategies need to be developed for both groups.

The American Academy of Orthopedic Surgeons upgraded monitoring guidelines for patients with metal-on-metal hips in 2014.¹⁰ These recommendations focus primarily on local adverse reactions to metallic debris and advise B[Co] levels and cross-sectional hip imaging for patients presenting with pain, noise, or swelling at the hip. Going further is Britain's national Medicines and Healthcare Products Regulatory Agency, which in 2012 issued a medical device alert (MDA).²⁰ This medical device alert recommends B[Co] determination for most patients implanted with metal-on-metal hips and notes that a rising level or abnormal hip imaging should prompt consideration for revision surgery even in asymptomatic patients. Perhaps most comprehensively, Australia's independent, not-for-profit group NPS MedicineWise recommends annual B[Co] determination for all patients implanted with metal-on-metal hips (increasing to every 3 months if levels rise), surveillance for periprosthetic complications by a surgeon, and evaluation for constitutional, psychological, neurologic, and cardiovascular manifestations of cobaltism by the patient's primary provider.⁴² This approach could potentially avert the substantial systemic morbidity documented in the case reports presented here as well as lead to earlier identification of the pseudotumors that can result in progressive periprosthetic tissue damage and complicate revision surgery.^{43,44} In this respect, it is worth noting that 4 of the 25 patients did not have hip symptoms; and thus, using this as a sole screening criterion for further evaluation may delay identification of systemic manifestations.

Complicating matters is that the B[Co] level at which risk for adverse outcomes increases is poorly defined. Whereas the mean B[Co] level among reported cases was relatively high (324 µg/L), 17% had a level of less than 20 µg/L and almost half had a level of less than 100 µg/L. These data suggest that at a minimum, B[Co] level greater than 10 µg/L should trigger additional evaluation, but the scope of this evaluation remains undefined. For example, evaluation could include hip radiographs to assess component fixation and position and to assess for bone loss; cross-sectional hip imaging to assess the condition of periprosthetic soft tissue^{45,46}; and audiograms, echocardiograms, and thyroid function studies. Additionally, patients with metal-on-metal hips might benefit from baseline assessment of various organ systems. The use of these approaches will depend on the prevalence of cobaltism in the total population of persons with metal-on-metal hips, their average symptom severity and the proportion with severe symptoms, as well as the economic benefit of routine screening at varying levels of intensity versus waiting until patients become symptomatic. Unfortunately, none of this information is known.

CONCLUSIONS

Future work should be done to define the prevalence and burden of arthroprosthetic cobaltism and the cost-effectiveness of various screening and management strategies. In addition to targeted and systematic studies, another strategy to facilitate these goals is the establishment of joint registries in the United States and other countries similar to those used in many European countries. In the meantime, surgeons and general practitioners should receive training on the potential risk for cobaltism associated with wear or corrosion of chrome-cobalt hip implants. A validated symptom scoring tool would facilitate clinical screening. Finally, it seems prudent to assess B[Co] yearly in patients with chrome-cobalt-containing hip prostheses and to develop a management plan when levels greater than 10 µg/L are identified.

REFERENCES

- Smith IC, Carson BL. *Volume 6-Cobalt an Appraisal of Environmental Exposure*. 1st ed. Ann Arbor, MI: Ann Arbor Science; 1981.
- Isaac GH, Siebel T, Schmalzried TP, et al. Development rationale for an articular surface replacement: a science-based evolution. *Proc Inst Mech Eng [H]*. 2006;220:253–268.
- Currier JH, McHugh DJ, Tower DR, et al. Gouge features on metal-on-metal hip bearings can result from high stresses during rim contact. *Tribology International*. 2012;63:89–96.
- Bozic KJ, Kurtz S, Lau E, et al. The epidemiology of bearing surface usage in total hip arthroplasty in the United States. *J Bone Joint Surg Am*. 2009;91:1614–1620.
- Tower S. Arthroprosthetic cobaltism: identification of the at-risk patient. *Alaska Med*. 2010;52:28–32.
- Van Der Straeten C, Van Quickenborne D, Pennynck S, et al. Systemic toxicity of metal ions in a metal-on-metal hip arthroplasty population. *Bone Joint J*. 2013;95-B(suppl 34):187.
- Alimonti A, Bocca B, Mannella E, et al. Assessment of reference values for selected elements in a healthy urban population. *Ann Ist Super Sanità*. 2005;41:181–187.
- Hodnett D, Wood DM, Raja K, et al. A healthy volunteer study to investigate trace element contamination of blood samples by stainless steel venipuncture needles. *Clin Toxicol (Phila)*. 2012;50:99–107.
- American Conference of Governmental Industrial Hygienists. 2012 threshold limit values (TLVs) and biological exposure indices (BEIs). Appendix B. ACGIH, Cincinnati, Ohio. Available at: http://www.nsc.org/news_resources/studentportal/CaseStudy/FIH%206e%20Appendix%20B.pdf. Accessed September 23, 2014.
- Kwon YM, Lombardi AV, Jacobs JJ, et al. Risk stratification algorithm for management of patients with metal-on-metal hip arthroplasty: consensus statement of the American Association of Hip and Knee Surgeons, the American Academy of Orthopaedic Surgeons, and the Hip Society. *J Bone Joint Surg Am*. 2014;96:e4.
- Langton DJ, Joyce TJ, Jameson SS, et al. Adverse reaction to metal debris following hip resurfacing: the influence of component type, orientation and volumetric wear. *J Bone Joint Surg Br*. 2011;93:164–171.
- Rona G, Chappel CI. Pathogenesis and pathology of cobalt cardiomyopathy. *Recent Adv Stud Cardiac Struct Metab*. 1973;2:407–422.
- Catalani S, Rizzetti MC, Padovani A, et al. Neurotoxicity of cobalt. *Hum Exp Toxicol*. 2012;31:421–437.
- Oldenburg M, Wegner R, Baur X. Severe cobalt intoxication due to prosthesis wear in repeated total hip arthroplasty. *J Arthroplasty*. 2009;24:825 e15–825 e20.
- Megaterio S, Galetto F, Alossa E, et al. Effetti a distanza del rilascio di ioni metallo in usura della testa protesica: presentazione di un caso. *GIOT*. 2001;27:173–175.
- Pelcova D, Sklensky M, Janicek P, et al. Severe cobalt intoxication following hip replacement revision: clinical features and outcome. *Clin Toxicol (Phila)*. 2012;50:262–265.
- Jones DA, Lucas HK, O'Driscoll M, et al. Cobalt toxicity after McKee hip arthroplasty. *J Bone Joint Surg Br*. 1975;57:289–296.
- Frustaci A, Magnavita N, Chimenti C, et al. Marked elevation of myocardial trace elements in idiopathic dilated cardiomyopathy compared with secondary cardiac dysfunction. *J Am Coll Cardiol*. 1999;33:1578–1583.
- Guzzo TJ, Drach GW. Major urologic problems in geriatrics: assessment and management. *Med Clin North Am*. 2011;95:253–264.
- Medicines and Healthcare Products Regulatory Agency. Medical Device Alert, MDA/2012/036; 25 June 2012. Available at: <http://www.mhra.gov>.

- uk/home/groups/dts-bs/documents/medicaldevicealert/con155767.pdf. Last accessed September 23, 2014.
21. Brodner W, Grohs JG, Bitzan P, et al. Serum cobalt and serum chromium level in 2 patients with chronic renal failure after total hip prosthesis implantation with metal-metal gliding contact. *Z Orthop Ihre Grenzgeb.* 2000;138:425–429.
 22. Fritzsche J, Borisch C, Schaefer C. Case report: high chromium and cobalt levels in a pregnant patient with bilateral metal-on-metal hip arthroplasties. *Clin Orthop Relat Res.* 2012;470:2325–2331.
 23. O'Connell E, Mead N, Fesniak H. Idiopathic cardiomyopathy following metal-on-metal hip arthroplasty: the new fact of "beer drinker's cardiomyopathy". *Eur J Cardiovasc Med.* 2013;2:210–211.
 24. Giampreti A, Lonati D, Locatelli CA. Chelation in suspected prosthetic hip-associated cobalt toxicity. *Can J Cardiol.* 2014;30:e13.
 25. Van Quickenborne D, Van Der Straeten C, De Smet KA. Hearing loss in a bilateral hip resurfacing. *Tijdschr voor Geneeskunde.* 2012;68.
 26. Allen LA, Ambardekar AV, Devaraj KM, et al. Clinical problem-solving. Missing elements of the history. *N Engl J Med.* 2014;370:559–566.
 27. Apel W, Stark D, Stark A, et al. Cobalt-chromium toxic retinopathy case study. *Doc Ophthalmol.* 2013;126:69–78.
 28. Dahms K, Sharkova Y, Heitland P, et al. Cobalt intoxication diagnosed with the help of Dr House. *Lancet.* 2014;383:574.
 29. Gilbert CJ, Cheung A, Butany J, et al. Hip pain and heart failure: the missing link. *Can J Cardiol.* 2013;29:639 e1–639 e2.
 30. Ikeda T, Takahashi K, Kabata T, et al. Polyneuropathy caused by cobalt-chromium metallosis after total hip replacement. *Muscle Nerve.* 2010;42:140–143.
 31. Machado C, Appelbe A, Wood R. Arthroprosthetic cobaltism and cardiomyopathy. *Heart Lung Circ.* 2012;21:759–760.
 32. Mao X, Wong AA, Crawford RW. Cobalt toxicity—an emerging clinical problem in patients with metal-on-metal hip prostheses? *Med J Aust.* 2011; 194:649–651.
 33. Ng SK, Ebnetter A, Gilhotra JS. Hip-implant related chorio-retinal cobalt toxicity. *Ind J Ophthalmol.* 2013;61:35–37.
 34. Rizzetti MC, Liberini P, Zarattini G, et al. Loss of sight and sound. Could it be the hip? *Lancet.* 2009;373:1052.
 35. Roessler PP, Witt F, Efe T, Schmitt J. Arthroprosthetic cobaltism and pseudotumour also occur in patients with small diameter femoral ball head metal-on-metal total hip arthroplasties. *Br Med J Case Rep.* 2014: e203362.
 36. Steens W, Loehr JF, von Foerster G, et al. Chronic cobalt poisoning in endoprosthesis replacement. *Orthopade.* 2006;35:860–864.
 37. Tower SS. Arthroprosthetic cobaltism: neurological and cardiac manifestations in two patients with metal-on-metal arthroplasty. *J Bone Joint Surg.* 2010;92:2847–2851.
 38. Tower SS. Arthroprosthetic cobaltism associated with metal on metal hip implants. *Br Med J.* 2012;344:e430.
 39. van Lingen CP, Etterna HB, Timmer JR, et al. Clinical manifestations in ten patients with asymptomatic metal-on-metal hip arthroplasty with very high cobalt levels. *Hip Internat.* 2013;23:441–444.
 40. Pazzaglia UE, Apostoli P, Congiu T, et al. Cobalt, chromium and molybdenum ions kinetics in the human body: data gained from a total hip replacement with massive third body wear of the head and neuropathy by cobalt intoxication. *Arch Orthop Trauma Surg.* 2011;131:1299–1308.
 41. Ziwiell MG, Brandt JM, Overgaard CB, et al. Fatal cardiomyopathy after revision total hip replacement for fracture of a ceramic liner. *Bone Joint J.* 2013;95-B:31–37.
 42. NPS MedicineWise. Monitoring for potential toxicity in patients with metal-on-metal hip. Published 21 September 2012. Available at: <http://www.nps.org.au/publications/health-professional/health-news-evidence/2012/metal-hip-replacement-toxicity>. Accessed September 23, 2014.
 43. de Steinger RN, Miller LN, Prosser GH, et al. Poor outcome of revised resurfacing hip arthroplasty. *Acta Orthop.* 2010;81:72–76.
 44. Graves SE, Rothwell A, Tucker K, et al. A multinational assessment of metal-on-metal bearings in hip replacement. *J Bone Joint Surg Am.* 2011; 93(Suppl 3):43–47.
 45. Lombardi AV Jr, Barrack RL, Berend KR, et al. The Hip Society: algorithmic approach to diagnosis and management of metal-on-metal arthroplasty. *J Bone Joint Surg Br.* 2012;94-B(Suppl 11):14–18.
 46. Kwon YM, Jacobs JJ, MacDonald SJ, et al. Evidence-based understanding of management perils for metal-on-metal hip arthroplasty patients. *J Arthroplasty.* 2012;27(Suppl 8):20–25.