

American Society of Pain and Neuroscience Best Practice (ASPN) Guideline for the Treatment of Sacroiliac Disorders

Dawood Sayed¹, Timothy R Deer^{2,3}, Vinicius Tieppo Francio¹, Christopher M Lam¹, Kamil Sochacki⁴, Nasir Hussain⁵, Tristan E Weaver⁵, Jay Karri^{6,7}, Vwaire Orhurhu^{8,9}, Natalie Holmes Strand¹⁰, Jacqueline Soicher Weisbein¹¹, Jonathan M Hagedorn¹², Ryan S D'Souza¹², Ryan R Budwany², Ahish Chitneni¹³, Kasra Amirdelfan¹⁴, Michael J Dorsi¹⁵, Dan TD Nguyen¹⁶, Christopher Bovinet¹⁷, Alaa Abd-ElSayed¹⁸

¹Anesthesiology and Pain Medicine, The University of Kansas Medical Center, Kansas City, KS, USA; ²Pain Services, Spine and Nerve Center of the Virginias, Charleston, WV, USA; ³Anesthesiology and Pain Medicine, West Virginia University School of Medicine, Charleston, WV, USA; ⁴Department of Anesthesiology and Perioperative Medicine, Rutgers Robert Wood Johnson, New Brunswick, NJ, USA; ⁵Anesthesiology, the Ohio State University Wexner Medical Center, Columbus, OH, USA; ⁶Department of Orthopedic Surgery, University of Maryland School of Medicine, Baltimore, MD, USA; ⁷Department of Anesthesiology, University of Maryland School of Medicine, Baltimore, MD, USA; ⁸Department of Anesthesiology, University of Pittsburgh Medical Center, Williamsport, PA, USA; ⁹Pain Medicine, MVM Health, East Stroudsburg, PA, USA; ¹⁰Anesthesiology and Pain Medicine, Mayo Clinic, Phoenix, AZ, USA; ¹¹Interventional Pain Management, Napa Valley Orthopaedic Medical Group, Napa, CA, USA; ¹²Department of Anesthesiology and Perioperative Medicine, Mayo Clinic, Rochester, MN, USA; ¹³Department of Rehabilitation & Regenerative Medicine, New York Presbyterian – Columbia & Cornell, New York, NY, USA; ¹⁴Director of Clinical Research, Boomerang Healthcare, Walnut Creek, CA, USA; ¹⁵Neurosurgery, University of California Los Angeles, Los Angeles, CA, USA; ¹⁶Neuroradiology & Pain Solutions of Oklahoma, Edmond, OK, USA; ¹⁷The Spine Center of SE Georgia, Brunswick, GA, USA; ¹⁸Anesthesiology, University of Wisconsin, Madison, WI, USA

Correspondence: Dawood Sayed, Anesthesiology and Pain Medicine, The University of Kansas Medical Center, Kansas City, KS, USA, Tel +1 785-550-5800, Email dsayed@kumc.edu

Abstract: Clinical management of sacroiliac disease has proven challenging from both diagnostic and therapeutic perspectives. Although it is widely regarded as a common source of low back pain, little consensus exists on the appropriate clinical management of sacroiliac joint pain and dysfunction. Understanding the biomechanics, innervation, and function of this complex load bearing joint is critical to formulating appropriate treatment algorithms for SI joint disorders. ASPN has developed this comprehensive practice guideline to serve as a foundational reference on the appropriate management of SI joint disorders utilizing the best available evidence and serve as a foundational guide for the treatment of adult patients in the United States and globally.

Keywords: sacroiliac joint, sacroiliitis, chronic pain, best practices, radiofrequency ablation, sacroiliac joint fusion

Introduction

The sacroiliac (SI) joint (SIJ) has been a major source of pain in many patients as either a primary problem or an issue secondary to gait disorders, spinal pathology, or certain risk factors. Despite the high prevalence of this disorder, it is underdiagnosed and may go untreated, poorly treated, or treated with highly invasive methods. The goal of this paper is to better define the anatomy, diagnosis, and best practices for treatment of this common and often poorly misunderstood pathology. These guidelines should be utilized by all clinicians involved in the care of patients suffering from SI disorders (SID) to improve clinical outcomes and safety.

Methodology

Development Process

The American Society of Pain and Neuroscience (ASPN), through its mission to increase evidence-based access to treatment, has commissioned a systematic guideline process to outline the current state of the art in treatment of sacroiliac joint disease. Members

of the consensus group were selected from among experts across a broad spectrum of specialties interested in the treatment of sacroiliac joint disease within both ASPN and other societies. Specialists from anesthesiology, neurosurgery, pain medicine, physiatry, primary care, and radiology participated in the formulation of these guidelines. The current guidelines will examine the evidence and current treatment options. The consensus work group was convened and at regular intervals, members have evaluated the level of current evidence in the peer-reviewed literature for topics that have been identified as critical for treatment. The purpose and scope of this guideline is to serve as reference for the appropriate treatment of adults with sacroiliac disease for both clinicians and payors.

Work groups convened to conduct literature searches and examine the evidence for the topics developed by lead authors in outline form. After the literature search was completed, each author was asked to provide cited references, and evidence rank. The section leaders then formulated the recommendation grades, based on the evidence, which were reviewed by at least three different, nonconflicted working group members. If conflicts of interest were identified, recusal was required as outlined below. ASPN utilizes the United States Preventative Services Task Force (USPSTF) format with slight modification for interventional pain treatment. This process has been established in previous ASPN publications. Once literature was reviewed, consensus statements were created and graded based upon the ASPN-USPSTF criteria listed in Table 1. The process by which section leaders then created consensus points included in-person meetings, teleconference, or other electronic or audio-video communications to define the consensus; agreement by at least 80% of the contributing authors was considered a quorum. Consensus strength was defined, as described in previous ASPN guidelines. If a recommendation was proposed with <50% consensus, based on assigned evidence rank and recommendation grade, then no consensus was achieved.

This consensus guideline gives guidance to clinicians concerning sacroiliac treatment and evidence-based practice and outcome optimization. However, these recommendations should not be construed as a standard of care, but instead represent best practices. This guidance is based on several factors and peer-reviewed evidence, and regardless of the strength of evidence, requires interpretation for clinical application.

Management of Conflict of Interest

All authors were required to disclose conflicts of interest prior to assignment of topics. The senior authors determined the extent of the conflict of interest ensuring balanced inquiry and evaluation for each manuscript section. One of the co-primary

Table 1 ASPN Criteria for Quality of Evidence

Grade	Definition	Suggestions for Practice
A	ASPN recommends the service. There is high certainty that the net benefit is substantial.	Offer or provide this service.
B	ASPN recommends the service. There is high certainty that the net benefit is moderate or there is moderate certainty that the net benefit is moderate to substantial.	Offer or provide this service.
C	ASPN recommends selectively offering or providing this service to individual patients based on professional judgment and patient preferences. There is at least moderate certainty that the net benefit is small.	Offer or provide this service for selected patients depending on individual circumstances.
D	ASPN recommends against the service. There is moderate or high certainty that the service has no net benefit or that the harms outweigh the benefits.	Discourage the use of this service.
I Statement	ASPN concludes that the current evidence is insufficient to assess the balance of benefits and harms of the service. Evidence is lacking, of poor quality, or conflicting, and the balance of benefits and harms cannot be determined.	Read the clinical considerations section of USPSTF Recommendation Statement. If the service is offered, patients should understand the uncertainty about the balance of benefits and harms.

Notes: Adapted with permission from Dove Medical Press. Deer TR, Grider JS, Pope JE, et al. Best practices for minimally invasive lumbar spinal stenosis treatment 2.0 (MIST): consensus guidance from the American Society of Pain and Neuroscience (ASPN). *J Pain Res.* 2022;15:1325–1354.¹

Abbreviations: ASPN, American Society of Pain and Neuroscience; USPSTF, United States Preventative Services Task Force.

authors without conflict were identified for each section and was the adjudication determination official for any issues of potential conflict. All authors were asked to recuse themselves on any recommendation potentially affected by a disclosed conflict. Additionally, authors without conflict vetted all recommendations for bias.

Literature Search, Evidence Ranking

The world literature in English was searched using Medline, EMBASE, Cochrane CENTRAL, BioMed Central, Web of Science, Google Scholar, PubMed, Current Contents Connect, Meeting Abstracts, and Scopus to identify and compile the evidence for sacroiliac joint treatments (per section as listed in the manuscript) for the treatment of pain. Manuscripts from 2000-present were included in the search process. Search words were selected based upon the section represented. Identified peer-reviewed literature was critiqued using the USPSTF criteria for quality of evidence,² with modifications for interventional pain studies (Table 1). After USPSTF letter grading was assigned, the working subgroup then assigned the “level of certainty regarding benefit” as described in Table 2.

For each major section or topic, ASPN formulated consensus points. Consensus points should not be confused with recommendations based on consensus alone (Evidence Level II), which were rendered as clinical guidance in the situations where, due to the lack of evidence-based literature (such as randomized controlled trials [RCTs]), prospective observational studies, and retrospective cohort/case series) the best available guidance is expert opinion.

Relevant Anatomy

The SIJ is the largest axial joint in the human body and is diarthrodial in nature. Specifically, there are two bony surfaces of the joint, the sacrum and the ilium. The joint space is approximately 1–2 millimeters wide and is largely limited to the

Table 2 Level of Certainty Regarding Benefit

Level of Certainty	Description
High	The available evidence includes consistent results from well-designed, well-conducted studies in representative primary care populations. These studies assess the effects of the preventive service on health outcomes. This conclusion is therefore unlikely to be strongly affected by the results of future studies. Evidence Level: I-A - At least one controlled and randomized clinical trial, properly designed
Moderate	The available evidence is sufficient to determine the effects of the preventive service on health outcomes, but confidence in the estimate is constrained by such factors as: <ul style="list-style-type: none"> • The number, size, or quality of individual studies. • Inconsistency of findings across individual studies. • Limited generalizability of findings to routine primary care practice. • Lack of coherence in the chain of evidence. As more information becomes available, the magnitude or direction of the observed effect could change, and this change may be large enough to alter the conclusion. Evidence Level I-B - Well-designed, controlled, non-randomized clinical trials (prospective observational studies conforming to STROBE criteria) or Evidence Level I-C – Retrospective cohort or large case studies (>20 subjects)
Low	The available evidence is insufficient to assess effects on health outcomes. Evidence is insufficient because of: <ul style="list-style-type: none"> • The limited number or size of studies. • Important flaws in study design or methods. • Inconsistency of findings across individual studies. • Gaps in the chain of evidence. • Findings not generalizable to routine primary care practice. • Lack of information on important health outcome Evidence Level II - Expert opinion based of risk: benefit or based upon case reports

Note: Reprinted with permission from Dove Medical Press. Deer TR, Grider JS, Pope JE, et al. Best practices for minimally invasive lumbar spinal stenosis treatment 2.0 (MIST): consensus guidance from the American Society of Pain and Neuroscience (ASPN). *J Pain Res.* 2022;15:1325–1354.¹

Abbreviations: STROBE, Strengthening the Reporting of Observational Studies in Epidemiology.

anterior third of the sacral–iliac interface, whereby synovium exists.^{3,4} The remaining two-thirds of the joint is comprised primarily of ligamentous tissue, including the ventral, interosseous, and iliolumbar ligaments, which contribute to overall stability by limiting movement.^{4,5} Stability is also due to discontinuity of the posterior capsule, which has many ridges and depressions that serve to limit movement of the joint.⁶ Unique to the SIJ is the existence of both hyaline cartilage and fibrocartilage.⁷

The innervation of the SIJ has yet to be clearly defined; however, several nerves have been implicated in signaling pain from the SIJ. The posterior SIJ, which is a common location of pain, has been thought to receive innervation from the lateral branches of the L4 to S3 dorsal rami nerve roots;⁸ however, the L3 and S4 dorsal rami nerve roots have also been considered.⁹ In addition, minor innervation may come from the superior gluteal nerve.¹⁰ Although ventral rami nerve roots may also have a contribution, this is thought to be relatively minor and clinically unimportant. In contrast to the posterior aspect, the anterior SIJ is thought to be innervated by the lateral branches of the L2 to S2 ventral rami nerve roots; however, some have also suggested a lack of innervation to this area.^{4,9}

The bony anatomy of the SIJ can vary between individuals and drastically changes with age. The sacral aspect of the joint is generally concave whereas the iliac component is convex. With age, this iliac surface can degenerate and become rough in texture.³ In contrast, the sacral surface, which already has a rough and irregular surface, can also undergo similar degenerative changes; however, these occur many years after iliac degeneration has begun. With age, the joint space also decreases and becomes a less effective shock absorber; however, age-related autofusion does not typically occur.

Biomechanics

The primary function of the SIJ is to preserve truncal stability. This is aided by its wedge-shaped structure with ridges and depressions on the articular surface.¹¹ The shape of the articular surface changes with age and degree of joint stress, but overall, joint motion is kept to a minimum and generally does not exceed 2 to 3 degrees in either transverse or longitudinal planes and 2 millimeters in translation.^{12,13} Changes to the supporting ligaments, however, may be seen with pregnancy, where hormonal changes assist with joint laxity and hypermobility for childbirth.³ As opposed to other joints, there are no muscles that specifically act on the SIJ,¹² and movement is indirectly assisted by truncal and lower extremity muscles.

The SIJ itself can move in all three axes, but overall, movement in each is limited and relatively static. This has largely been confirmed by exposing the joint to various static load forces with fixation of the ilia. Specifically, Miller et al¹⁴ found that with fixation of both ilia, the movement of the SIJ was minimal; however, fixation of one ilia resulted in significantly larger motion in all the planes. Further, in the single SIJ tests, forces as high as 1440 newtons (N) or 160 newton-meters did not result in failure of the joint.¹⁴ Similarly, in another study by Vleeming et al,¹³ the SIJ was found to be mobile but largely limited to about 4 degrees. Thus, specific motions of the SIJ, which was previously thought to be immobile, are nutation (sacral base movement anteroinferior in relation to ileum) and counter nutation (sacral base movement posterosuperior in relation to the ileum).¹⁵ Ligaments that oppose nutation include the sacrotuberous and sacrospinous ligaments, whereas the long dorsal ligaments oppose counter nutation (see [Figure 1](#)).¹⁶

It is important to note that significant axial compressive/shear force and torsion can lead to SIJ dysfunction and pain complaints. Specifically, this is more pronounced when forces are applied in a unidirectional and asymmetric manner, which can disrupt overall joint stability and lead to ligamentous strain.^{12,15} The ligaments which contribute most to this stability include the iliolumbar, posterior SI, interosseous, sacrotuberous, and sacrospinous ligaments.¹²

Best Practice Statement on SI Anatomy

It is recommended that clinicians should have a thorough understanding of the anatomy and biomechanics of the SIJ.

Diagnosis

SIDs comprise various more discrete pathologies, which include SIJ dysfunction, sacroiliitis, and SIJ arthropathy, all of which can occur independently or collectively.^{17–19} Given the varying pathophysiological mechanisms underlying these different entities and because of the plethora of non-SID diagnoses that can also cause chronic low back pain, the specific and reliable diagnosis of SID can be challenging. However, a nuanced appreciation of SIJ anatomy and biomechanics

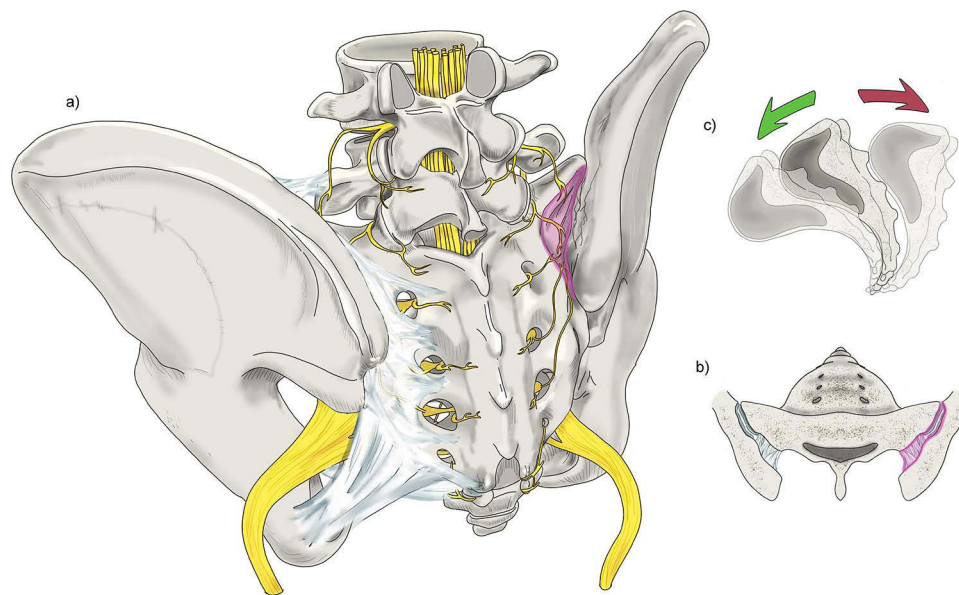


Figure 1 Anatomy of the SIJ. (a) Posterior-oblique view of the sacrum and iliac bones, ligaments, and nervous supply. SIJ is highlighted in pink overlay. (b) Diarthrodial nature of the SIJ space (pink overlay). The joint consists of an anterior one-third consisting of synovium and posterior two-thirds which is primarily ligamentous. (c) Exaggeration of sacral movement in nutation and counternutation. Original medical illustration by Kamil Sochacki, DO.

along with the collective utilization of the patient history, physical examination with provocative maneuvers, imaging modalities, and anesthetic blocks can facilitate the diagnosis of SID.^{17–21}

Patient History

While low back pain is the most prevalent patient complaint, descriptions of mechanical pain that radiates into the buttock and sometimes to the proximal lower extremity or groin is most consistent with the SID pain referral.^{18–20} There exist some studies that have associated upper buttock pain and groin pain with upper SID involvement. With regard to provocative positions, transitions from sitting to standing and vice versa are particularly implicated.

Risk factors predisposing towards SID include the following clinical and epidemiological factors:

- a. Gait abnormalities, scoliosis, and leg-length discrepancies, as they facilitate asymmetric SIJ load bearing.
- b. Lumbar fusion surgeries, particularly fusions extended to the sacrum and more extensive fusions can translate excess shear onto the inferior SIJs.
- c. Obesity, particularly in patients with excessive abdominal girth.
- d. Pregnancy, given ligamentous laxity during pregnancy and hypermobility of the SIJ.
- e. Inflammatory spondyloarthropathies, including ankylosing spondylitis can particularly cause focal inflammation in bilateral SIJs.
- f. Connective tissue disorders, such as Ehlers–Danlos syndrome, that affect the supporting ligaments.

Best Practice Statement on Patient History

It is recommended that a relevant history should be taken consistent with complaints in the diagnostic criteria of SID, and that risk factors that put the patient at a higher incidence of SID of the patient should heighten the clinician's suspicion for it as the source of lower back pain.

Physical Examination

While there exist several specialized tests to support a diagnosis of SID, the Fortin finger test is one of the more specific tests in the physical exam.^{18–20} This test is positive if the patient's major foci of pain is within 1 cm of the posterior

superior iliac spine, generally inferomedially. Laslett et al described the presence of 3 of the following 5 provocative tests is associated with a high specificity of SID pathology.²² These provocative tests are positive if they serve to reproduce the patient's pain. All the following tests are performed with the patient supine, unless otherwise specified:

- a. SIJ distraction: lateral pressure over the anterior iliac spine impinges the SIJs bilaterally.
- b. SIJ compression: posterior-to-anterior compression over the sacrum or medially directed compression (with the patient in a lateral decubitus position) of the iliac crest.
- c. Gaenslen's maneuver: excessive hip flexion of the contralateral SIJ with hip extension of the implicated laterality (by having this leg hanging off the exam table).
- d. Patrick's test: hip flexion (to at least 90 degrees), abduction, and external rotation of the implicated laterality.
- e. Thigh thrust: applying a high-velocity thrust into the femur (in 90 degrees of flexion) from superior to inferior into the SIJ.

Best Practice Statement on the Physical Examination in SIJ Dysfunction

The clinician should understand the validated physical examination maneuvers that play a role in the diagnosis of SID. The presence of three positive provocative maneuvers increases the specificity of diagnosing SIJ dysfunction, although less than three positive provocation maneuvers does not entirely rule out the SIJ as a source of pain.

Imaging Modalities

For chronic low back pain overall, the utility of imaging modalities has been shown to lack clinical relevance in certain etiologies.^{18–20,23} Moreover, the presence of various degenerative findings on imaging tests has not been shown to correlate to clear pathology with reliable specificity. In a review of computed tomography (CT) scans of 373 patients without low back pain, Eno et al found that radiographic signs of SIJ degeneration were present in 65.1% of patients.²⁴ These findings are expected given that the presence of non-specific radiographic degenerative changes increases with age. However, imaging studies may be helpful to rule out alternate non-degenerative pathologies including tumor, infection, fracture, etc. Moreover, imaging studies may also prove useful in assisting with the planning of advanced interventions and surgeries.

Best Practice Statement on Imaging of the SIJ

The clinician should obtain appropriate imaging and rule out other pathologies such as fracture, malignancy, and spinal disease. If planning surgical treatment, advanced imaging such as CT or magnetic resonance imaging (MRI) should be performed within 12 months or with any change in symptomatology.

Diagnostic Intra-Articular Injections

While injections into the SIJ can prove therapeutic, they can additionally provide valuable diagnostic utility.^{17,19–21} Injectates with anesthetic only will be expected to provide rapid analgesic benefit that persists for only hours, depending on the anesthetic type used. Steroid injections will be expected to provide pain relief that is delayed 2–5 days and can be sustained for weeks to months. Close follow-up with the patient following the procedure and incorporation of a pain diary will help characterize the diagnostic utility of intra-articular injections. The pain diary will ideally include recordings of the patient's pain severity along with functional measures. Evidence does not suggest that degree of pain relief over 50% corresponds with improved outcomes when considering surgical fusion.²⁵ See [Table 3](#) for a summary of SIJ pain diagnosis methods.

Best Practice Statement on Diagnostic Intra-Articular Injection of the SIJ

The patient should experience greater than 50% relief when an appropriately performed local anesthetic only injection is completed that is consistent with duration of the local anesthetic utilized. A second confirmatory local anesthetic injection can be considered, but not mandatory, when using diagnostic injections to determine candidacy for surgical treatment.

Table 3 Diagnosis of SIJ Pain

Three of Five Provocative Maneuvers	Intra Articular SIJ Injections	Imaging
SIJ Distraction SIJ Compression Gaenslen's Maneuver Patrick's Test Thigh Thrust	>50% pain relief with local anesthetic intra articular SIJ injection	Absence of other source of pathology on imaging (CT/MRI)

Abbreviations: SIJ, sacroiliac joint; CT, computed tomography; MRI, magnetic resonance imaging.

Conservative Care of SIJ Disorders

Conservative therapies for SIJ dysfunction focus on elimination of pain generators, restoration of normal mechanics in the hip/lumbopelvic region, and on restoring functionality and activity of the patient. Conservative measures include physical therapy, anti-inflammatories, and external supports such as pelvic belts. Conservative measures should be optimized prior to consideration of interventional pain techniques or surgical intervention. Similar to other causes of acute back pain, acute SIJ pain resolves in the majority of patients with conservative care.

With acute presentation of SIJ-related pain, activity modification is typically recommended. Avoidance of triggering activities is suggested in the first 1–3 days. The next subacute (or recovery) phase (3 days to 8 weeks) is typically focused on physical therapy and efforts to increase range of motion, stretch, and strengthen the affected areas. Physical therapy seeks to address not only the acute pain but also the underlying etiologies of pain to include muscle imbalances and postural imbalances.

Orthoses also have a role in conservative management of SIJ pain. In pelvis-spine anatomical preparations, SI belts were found to limit sagittal motion of the SIJ in response to load bearing.²⁶ SI belts have also been shown to modify large muscle group activation patterns in patients with SIJ pain on electromyographic analysis.²⁷ Whether the magnitude of electromyographic change is enough to translate into lower pain scores and improved SIJ pain symptoms is of clinical interest. Hammer et al demonstrated a nonsignificant reduction in pain scores between belt-wearing and non-belt wearing individuals with SIJ pain and significant improvement in gait speed and cadence suggesting functional lifestyle improvement.²³ The available body of evidence supporting significant reductions on a long-term basis using SI orthoses is lacking, however use of SI belts in SIJ dysfunction has been associated with improvements in pain (measured by visual analog scale [VAS]) when coupled with physical therapy.²³

Medication management typically involves non-steroidal anti-inflammatory drugs (NSAIDs). When looking at all causes of low back pain (to include SIJ pain), NSAIDs were found to significantly reduce pain scores and disability. Depending on the patient presentation, there may also be a role for muscle relaxant medications. Topical agents such as lidocaine or menthol patches may also provide some mild relief for patients.

The chronic, or maintenance phase, involves continued participation in a home exercise program and utilization of medications as needed. In this phase, more invasive interventions are frequently considered for unresolved pain.

Best Practice Statement on Conservative Care

Appropriate conservative care should be considered and when acceptable attempted prior to interventional or surgical treatment of SID. See [Table 4](#) for a summary of conservative care.

SIJ Injections

SIJ injections can be used for both diagnostic and therapeutic purposes using various imaging techniques including but not limited to CT, fluoroscopy, and ultrasound. Absolute contraindications to injections include local malignancy and infection. Relative contraindications include coagulopathy, pregnancy (depending on the imaging type), systemic infection or osteomyelitis. All procedures should be performed under sterile conditions as a standard of care.

Table 4 Conservative Care of SIJ Disorders

Acute (1–3 days)	Subacute (3 days - 8 weeks)	Chronic/Maintenance Phase (>8 weeks)
Avoid Triggering Activities	Focus on increasing activity, increasing mobility, strengthening, and stretching musculature with physical therapy, normalizing posture, and mechanics	Interventional Pain Management Options, home exercise program
Medications: NSAIDs	Medications: NSAIDs	Medications: NSAIDs

Abbreviation: NSAID, non-steroidal anti-inflammatory drug.

According to Pulisetti et al, the most precise method of confirmatory diagnostic injections of the SIJ is with CT guidance.²⁸ The most common complications are vasovagal reactions.²⁸ The majority of SIJ injections are typically performed under fluoroscopic guidance in an ambulatory setting.²⁸ With the patient prone on the table, the image intensifier is positioned in a contralateral oblique fashion from 10 to 20 degrees to help visualize the joint space.²⁸ Joint access may be confirmed with the administration of contrast in anteroposterior, oblique and lateral views under fluoroscopy.²⁸ Once location is confirmed, an injectate of an average of 3–5 cc is administered intra-articular.²⁸ Both Khuba et al and Chauhan found that the oblique angulation may be unnecessary and that one might enter the lower part of the posterior joint in an anterior-posterior image alone allowing for access to the joint with lower fluoroscopy times.^{29,30}

Complications from SIJ injections can range from none³¹ to increased pain in approximately 15–30% of patients.²⁸ Transient perineal anesthesia or a temporary sciatica-like syndrome post injection have also been reported.²⁸ Although rare, complications of septic arthritis can occur in patients with increased risk factors including diabetes mellitus, presence of prosthetic material, localized infections, in the elderly, and patients on immunosuppressive medications.³²

Under ultrasound, the SIJ is a hypoechoic cleft area between the 2 echogenic lines of the sacrum and iliac bone as described by Hartung.³³ Saunders et al modified Hartung's technique by targeting the synovial portion of the joint with the goal of injecting into and around the dorsal interosseous ligament while avoiding the synovial part of the joint.³⁴ Commonly, the location of the dorsal interosseous ligament is at the S1/S2 level.³⁴

Serious complications of ultrasound guided intra-articular injections like advancement of the needle into the retro-pelvic area are uncommon.³⁵ Under ultrasound, accuracy of the placement is less likely intraarticular.²⁰ For most, the duration of procedure time is much greater with ultrasound than other modalities but this is likely related to other variables.³⁶

Best Practice Statement on Intra-Articular Corticosteroid Injections for SIJ Pain

Image-guided, intra-articular corticosteroid injections are recommended for persistent SIJ pain that has persisted despite conservative measures for 4 weeks. Fluoroscopic and CT guided injections are the preferred imaging modality of choice, although ultrasound guidance can be considered in situations where radiation exposure may be problematic.

Neuroablative Treatment of SIJ Pain

After an appropriate trial of conservative care, and appropriate response to diagnostic blockade, neuroablative techniques can be considered in patients with SIJ pain and dysfunction. The most common neuroablative approach involves radiofrequency ablation (RFA) of the lateral branches of the S1-S3 dorsal rami along with medial branches of L5 dorsal rami and possibly L4.²⁰ However, rarer modalities of ablation, such as intra-articular chemical neurolysis as well as cryoablation, have also been offered with low-quality evidence supporting mild efficacy and limitations due to adverse effect profile.^{21,37,38}

Lateral Branch Blocks

Soto et al describe a multi-site, multi-depth 16-injection technique under fluoroscopy where the sacral foramina are compared to a clock face with the lateral margin being the center of the face.³⁹ On the right side, at the S1 and S2 levels, the needles are placed at the 2:30, 4:00, and 5:30 positions.²⁹ At the same levels on the left, needles are placed at 9:30,

8:00, and 6:30 positions.³⁰ At the S3 level, needles are placed at 2:30 and 4:00 on the right and 9:30 and 8:00 on the left.³⁹ Each of these targets are then injected with 0.2 mL of 0.75% bupivacaine, pulled back approximately 3 mm, and injected with another 0.2 mL of bupivacaine.⁴⁰ The goal of this technique is to capture all the lateral branches that do not run in a constant plane nor do they emerge from the posterior sacral foramina at a consistent location.⁴¹

Ultrasound (US)-guided lateral branch block uses the probe placed on the lower sacrum to identify the sacral hiatus which is midline.⁴² The probe is then moved to visualize the posterior foramina which will appear as gaps in the hyperechoic bony contour of the sacrum. The injections should also be placed at the lateral sacral crest between the S2 and S3 transverse tubercle, immediately above the S2 transverse tubercle, and at the level of the S1 tubercle directly.⁴³

Both intra-articular SIJ injections and lateral branch blocks have been utilized as a diagnostic tool for SIJ pain and as a precursor prior to performing lateral branch radiofrequency neurotomy. The specificity of intra-articular blocks has been questioned due to leakage of local anesthetic from the joint space, spread of local anesthetic to nearby structures, and coverage of the synovial portion of the joint without coverage of the interosseous or dorsal SI ligaments.⁴⁴ Diagnostic blockade of the S1-3 lateral branches and the L5 primary dorsal rami (with possible inclusion of the L4 primary dorsal rami) is the preferred diagnostic approach prior to performing neuroablative techniques. In a pilot study by Cohen et al, 13 of 18 patients with SIJ pain experienced significant relief after undergoing diagnostic blocks at the L4-5 dorsal rami and S1-3 lateral branches. Among nine patients who achieved >50% pain relief from diagnostic blocks, eight patients (89%) achieved $\geq 50\%$ pain relief after lateral branch and L4-5 dorsal rami RFA which persisted at the 9-month follow-up.⁴⁵ Dreyfuss et al performed a study on multi-site, multi-depth lateral branch blocks on twenty asymptomatic patients. Ten patients were randomized to receive 0.75% bupivacaine while ten patients were randomized to receive sham (normal saline) multi-site, multi-depth lateral branch blocks. After performing this procedure, provocation testing using a 25-gauge spinal needle probe into each subject's interosseous and dorsal SI ligaments was performed. Seventy percent of subjects in the cohort receiving 0.75% bupivacaine had an insensate interosseous and dorsal SI ligament, versus only 0–10% in the sham cohort. However, only 20% of the interventional cohort and 10% of the sham cohort did not feel SIJ capsular distention. Therefore, this study concluded that multi-site, multi-depth lateral branch blocks are effective in diagnosing extra-articular SIJ pain and may be a valuable tool in determining if lateral branch RFA may help with SIJ pain.⁴⁶ However, multi-site, multi-depth lateral branch blocks may possibly not effectively block the intra-articular portion of the SIJ, which is innervated by both ventral and dorsal nerves.

There is variability among studies in terms of what nerves to target during diagnostic blocks, minimum pain relief threshold that designates a successful block (ranging from 50% to 80% pain relief), and the number of successful diagnostic blocks necessary prior to proceeding with RFA. In addition to targeting S1-3 lateral branches, some studies targeted both L4 and L5 dorsal rami,⁴⁵ whereas other studies targeted only the L4 dorsal rami.⁴⁷ Although many studies utilized a pain relief threshold of $\geq 50\%$ to define a successful diagnostic block, others implemented stricter criteria of $\geq 75\%$ or $\geq 80\%$ pain relief. Implementing a stricter threshold for diagnostic blocks (eg, $\geq 80\%$) in clinical trials allows the study team to selectively choose patients with a higher likelihood of benefitting from RFA and conduct a study with a higher likelihood of producing positive results. In real-world clinical practice, implementing this strict threshold would prevent patients who obtained $\geq 50\%$ pain relief but under 80% pain relief from proceeding to lateral branch RFA, even though a substantial portion of these patients may attain clinically meaningful pain relief from lateral branch RFA. Therefore, we recommend that a threshold of $\geq 50\%$ pain relief from diagnostic blocks of lateral branches (S-1) and L5 dorsal rami (\pm L4 dorsal rami) be utilized prior to proceeding with RFA. This is consistent with the IMMPACT guidelines which propose that 50% or greater pain relief is considered as substantial improvement in pain.⁴⁸ Finally, diagnostic accuracy of single diagnostic blocks may be poor, which has been highlighted in the literature for lumbar medial branch blocks.⁴⁹ In addition to inducing a possible robust placebo response, other reasons for a false-positive diagnostic block include leakage of local anesthetic to surrounding pain-generating structures that will not be targeted with RFA, excessive topical and superficial anesthesia, utilization of sedation, and patient non-compliance with participating in pain-generating activities after diagnostic blockade. For these reasons, dual diagnostic blocks at the lateral branches and L5 dorsal rami (\pm L4 dorsal rami) are recommended prior to proceeding with RFA.

Radiofrequency Ablation

Prior to performing radiofrequency ablation (RFA), a diagnostic block of the lateral sacral branches (S1-3) and L5 dorsal rami is recommended,³⁸ even if the patient has previously received intra-articular SIJ injections. Although many older studies have utilized intra-articular SIJ injection as the standard for selecting candidates for lateral branch RFA, this strategy does not account for extra-articular sources of pain such as the posterior sacral ligaments as well as posterior joint complex that are targeted by lateral branch RFA.¹⁹ A cutoff of 50% pain relief or higher from lateral branch diagnostic block may be implemented prior to offering RFA. Furthermore, a multi-site, multi-depth lateral branch block approach is recommended as an important tool that may prognosticate if lateral branch RFA may assist with extra-articular SIJ pain.⁴⁶ Contraindications to offering neuroablative modalities for SIJ pain include sacral fracture, malignancy, infection, and coagulation.⁴⁵

Best Practice Statement on Diagnostic Blockade Prior to Neuroablative Procedures of the SIJ

Dual diagnostic blockade of the L5 primary dorsal ramus and sacral lateral branches (S1-3) with 50% improvement in pain and function is the preferred strategy prior to neuroablative procedures of the SIJ.

Historically, a leapfrogging RFA technique (see [Figure 2](#)) has been utilized sequentially within the SIJ, but only 36% of patients experienced over 50% pain relief at six months [Figure 2](#). This was attributed to only partial denervation of the SIJ.⁵⁰ Currently, the lateral sacral branches (S1-3) and L5 dorsal rami are the preferred targets for RFA to treat SIJ joint, with sustained relief for at least six months reported in over 60% of participants.^{45,51}

Monopolar RFA modalities comprise both conventional monopolar RFA and cooled monopolar RFA, with perpendicular and perforaminal placement of RFA probes about 3–5 mm laterally and 8–10 mm laterally, respectively, from the posterior sacral foramina border.^{52–54} Using clock face positions, S1 and S2 perforaminal RFA probe placement targets the 1:00, 3:00, and 5:30 positions on the right side, and 6:30, 9:00, and 11:00 positions on the left side.^{52–54} In addition, S3 perforaminal RFA probe placement targets 1:30 and 4:30 positions on the right side, and 7:30 and 10:30 positions on the left side.^{52–54} Cooled RF probes limit the impact of tissue charring on lesion size and can increase lesion diameter by 200–300% compared to conventional monopolar RFA (see [Figure 3](#)).^{21,55}

Several bipolar RFA modalities are available and involve current flow between needles to create lesions between the needles, in contrast to the lesion created around each single needle tip using monopolar RFA modalities.²¹ The

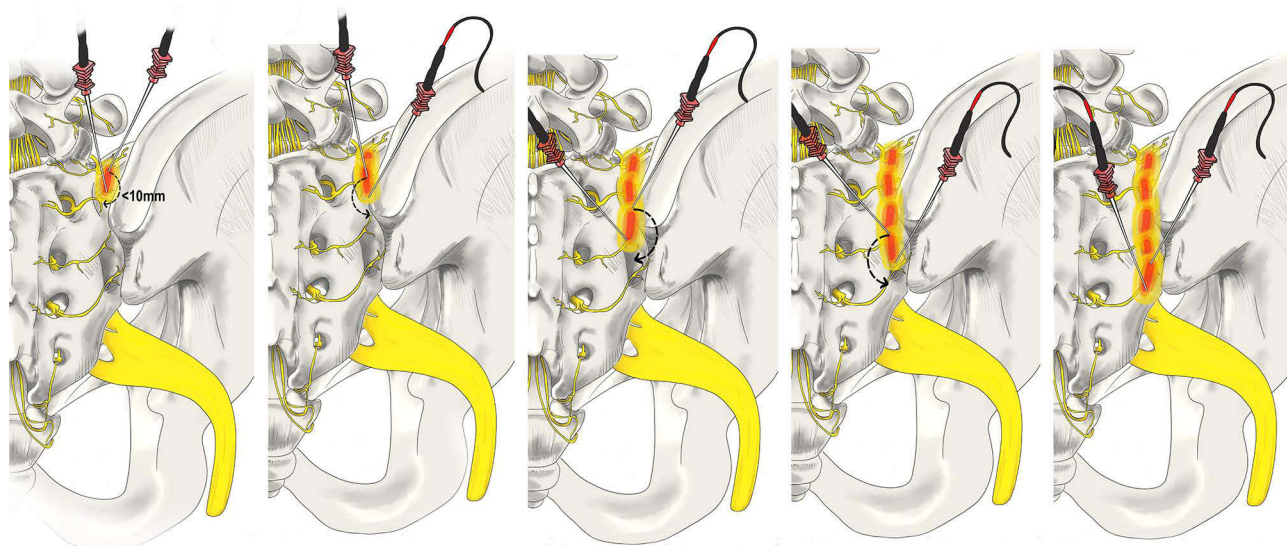


Figure 2 Leapfrog Radiofrequency Ablation Technique: A bipolar radiofrequency ablation strategy utilizing two probes placed within 10mm of one another along the SIJ. A lesion is made before moving the superior probe inferior to the second probe. A lesion is made, and the process is repeated with the lead probe being positioned inferiorly once again. Original medical illustration by Kamil Sochacki, DO.

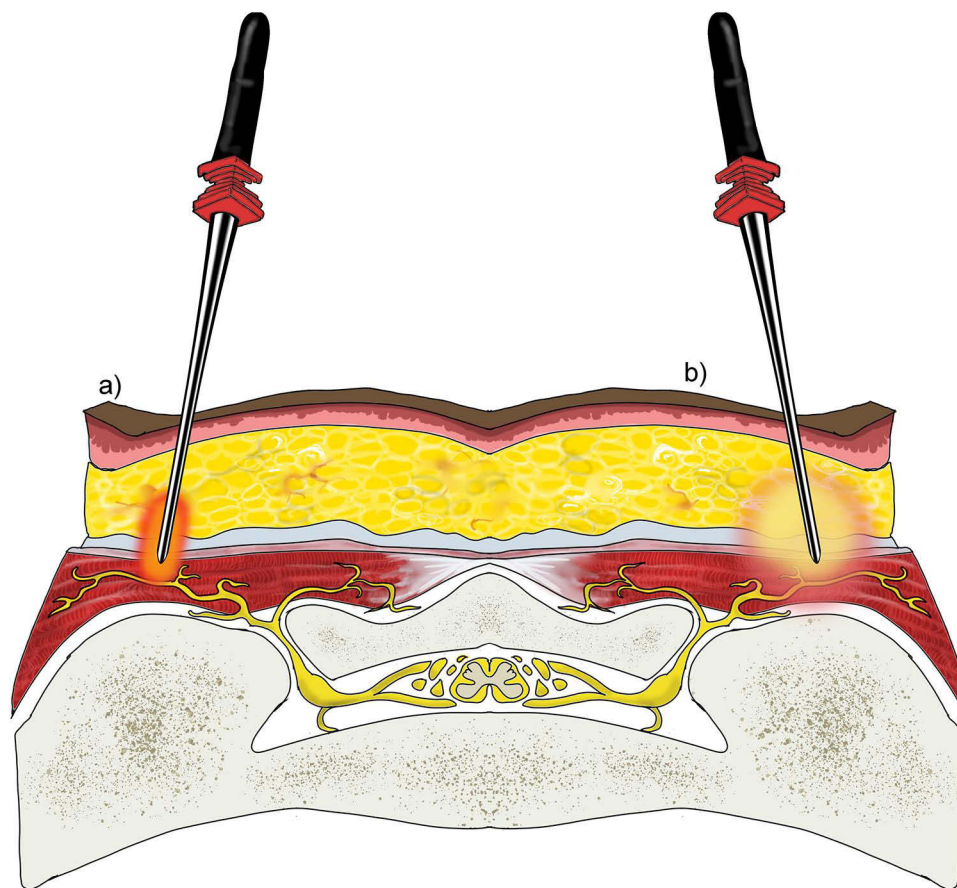


Figure 3 Conventional versus Cooled Radiofrequency Ablation. (a) Conventional RFA requires precise placement of the RFA probe within 1–2 mm of the intended target. Conventional RFA probes can reach temperatures of 100°C and insulating properties prevent heat radiofrequency waves from reaching further target tissue. (b) Cooled RFA needles utilize continuously circulating coolant within a hollow exterior shell to modulate temperature at the tip of the probe to around 60°C. This cooling mechanism avoids charring surrounding tissue, allowing for more effective heat transfer beyond the immediate proximity of the probe tip. The result is a significant difference in the overall size, shape, and area of effect of the ablated lesion, as compared to conventional RFA. Original medical illustration by Kamil Sochacki, DO.

perforaminal bipolar leapfrog technique involves lesions created 5 mm laterally from the posterior sacral foramina border and spans from the 12:00 position to the 6:00 position along the lateral half of the foramen.³⁷ Another bipolar RFA modality involves bipolar lesions created in a straight line about 4 mm laterally from the posterior sacral foramina and spanning from superior of S1 foramen to inferior of S3 foramen.⁵⁶ However, given that needles using this method are placed close to the border of the sacral foramina, the risk exists for inadvertent heating and nerve damage to the sacral spinal nerves. Similarly, RFA probes have been developed which contain a multi-tined expandable electrode and is positioned 10 mm laterally from the posterior sacral foramina and spans in a straight line from the base of S1 superior articular process to the S3 foramen level. These RFA probes are spaced 15 mm apart from each other. Another variation of this technique is highlighted by the posterior sacral network (PSN) lateral crest technique that involves US-guided needle insertion and lesions from the first to third transverse sacral tubercles.⁵² The linear strip lesion techniques may achieve similar capture rates of lateral branch nerves compared to the perforaminal bipolar leapfrog technique, but avert the need for precise identification of posterior sacral foramina borders.⁵²

Another approach to RFA is performed by using a multilesion probe (Simplicity III, NeuroTherm[®], Wilmington, MA).⁵⁵ The multilesion probe contains a radiofrequency electrode with three active regions, which create two bipolar and three monopolar lesions across the lateral branches of S1-S4 with a single percutaneous entry point (see Figure 4). Additional advantages with the multilesion probe include no requirement for introducer needles and the creation of a continuous strip lesion. Schmidt et al reported that 71.4% of patients with refractory SIJ pain experienced >50% pain

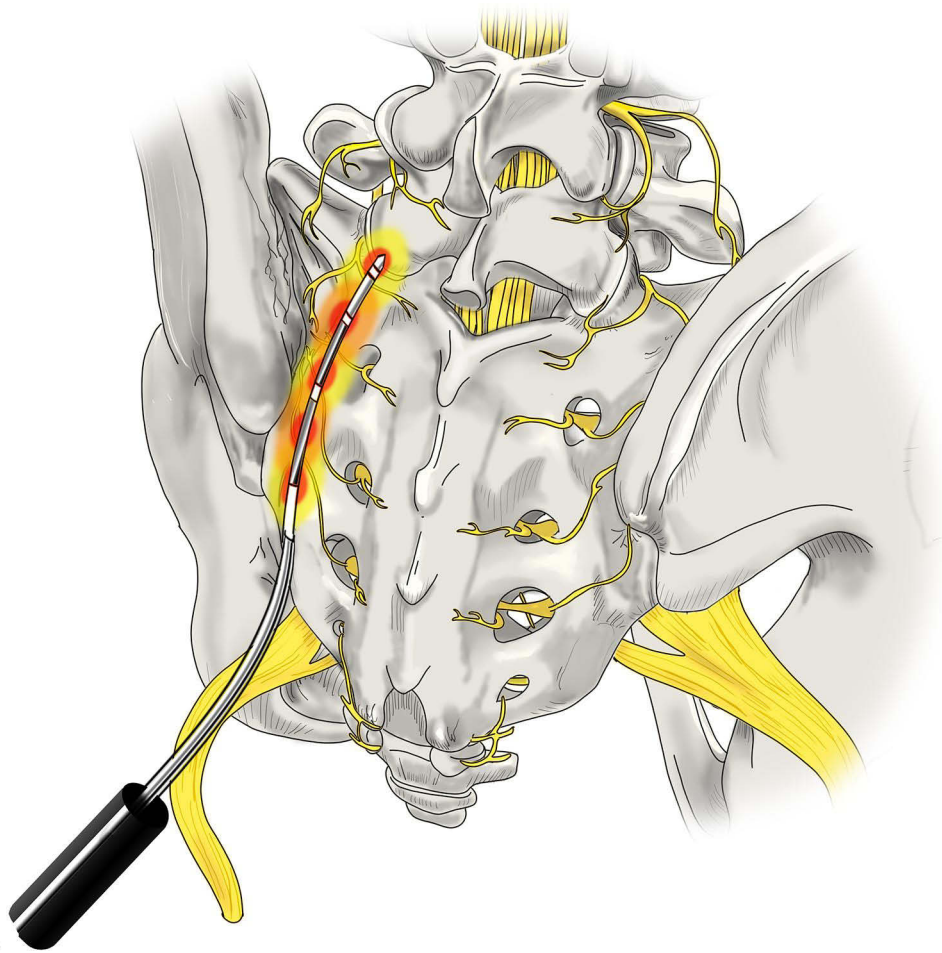


Figure 4 RFA with multilesion probe. This technique utilizes a singular probe which is tunneled through the tissue via a single site to generate a true strip lesion at the SIJ. The probe contains three electrodes creating a combination of monopolar and bipolar lesions. Original medical illustration by Kamil Sochacki, DO.

relief six weeks and 54.5% of patients experienced >50% pain relief at six months after lateral branch ablation using the multilesion probe.⁵⁵

Outcomes and Challenges with Radiofrequency Ablation

Dilemmas in RFA for SIJ pain can stem from whether targeting lateral sacral branches (S1-3) and L5 dorsal rami are sufficient to treat pain of SIJ etiology, and which RFA modalities adequately ablate these targets. Evidence from histological, anatomical, and in vivo studies demonstrates that the posterior aspect of the SIJ, or extra-articular component, receives innervation from the lateral branches of the posterior rami of S1-3 and varying innervation from L5 and S4.^{45,51,57,58} This is consistent with a randomized, double-blind study demonstrating that multisite, multi-depth sacral lateral branch blocks mainly relieve pain from the extra-articular component of the SIJ, and not from the intra-articular component of the SIJ.⁴⁶ The intra-articular component of the SIJ may predominantly receive innervation from the ventral rami of L5-S2 nerve roots (lumbosacral trunk) and the obturator and superior gluteal nerves.³⁸ Thus, in addition to course variability of lateral branch nerves, lateral sacral RFA may not provide benefit in all painful manifestations of SIJ pain because it predominantly targets the posterior nerve supply to the SIJ and may not address pain originating from the ventral aspect of the joint.²¹

In terms of RFA modality, a cadaveric study demonstrated that bipolar techniques may capture a larger percentage of lateral branches compared to monopolar techniques.⁵² This may account for the suboptimal clinical outcomes using monopolar techniques, which create a relatively small lesion size and may spare lateral branches between non-lesioned

gaps.⁵² The continuous and overlapping lesions from bipolar techniques may be capable of capturing all lateral branches.⁵² This cadaveric study demonstrated that the Palisade™ and PSN lateral crest technique had the highest probability of capturing 100% of targeted lateral branches, followed by peri-foraminal bipolar RFA and cooled monopolar RFA.⁵²

Synthesis of the available evidence generally reveal that lateral branch RFA is effective and treatment responder rates range between 32% and 89%.⁵⁴ High-quality evidence is limited to two randomized, sham-controlled trials.^{54,59} One trial randomized 28 patients to either receive cooled RFA of L4-5 primary dorsal rami and S1-3 lateral branches, or placebo denervation. A cross-over arm also allowed patients who failed from placebo injections to be treated with monopolar conventional RFA. At one month, 79% of subjects who received cooled RFA met the endpoint of >50% relief from their baseline pain, while only 14% met this endpoint in the placebo group. Persistent efficacy in relief was reported in 64% and 57% of subjects at the three- and six-month time points after cooled RFA.⁵⁴ Another trial randomized 51 participants (2:1 ratio) to either receive cooled RFA of L5 primary dorsal ramus and S1-3 lateral branches, or placebo denervation. The study demonstrated that 47% of treated patients achieved the primary endpoint ($\geq 50\%$ pain relief at three months) versus only 12% in the sham group.⁵⁹ In summary, a pooled analysis of these two trials revealed subjects treated with sacral lateral branch ablation were about four times more likely to achieve 50% reduction in pain intensity at three months compared to those treated with placebo denervation.⁶⁰ These results are consistent with other observational studies highlighting efficacy of sacral lateral branch block in treating posterior SIJ pain.⁶¹ Limitations across studies exist due to heterogeneity in selection criteria and RF technique utilized, which may impact success rates and external validity of results.

Studies comparing RFA modalities for SIJ pain are lacking. While some studies demonstrate slightly higher efficacy with cooled RFA versus monopolar RFA for SIJ pain, others reveal no difference.^{62,63} Another observational study highlighted that multi-electrode RFA probe may be more favorable versus monopolar perforaminal technique, although statistical significance was not indicated.⁶¹

Best Practice Statement on Neuroablative Technique and Approach for SI Pain

RFA of the SIJ should be performed by an established and researched method and repeated no more than at six-month intervals when an improvement of 50% pain relief and functional improvement is seen.

Regenerative Medicine

When patients with confirmed SIJ pain do not obtain satisfactory pain relief with conservative measures or intra-articular steroid injections, and want to avoid more invasive options, intra-articular regenerative medicine injections may be considered. Specifically, this term refers to platelet-rich plasma (PRP), bone marrow aspirate stem cell concentrate (BMAC), stromal vascular fraction (SVF), or a combination of these injectates. These options aim to reverse the underlying causative pathology by healing the damaged tissues.

The two options most commonly utilized and well-studied are PRP and BMAC.⁶⁴ Platelet rich plasma is whole blood that is centrifuged to create a concentrate of plasma full of platelets and associated platelet-derived growth factors (PDGF). The PDGF are important for the healing process through increasing fibroblast and/or osteoblast metabolic activity, reducing cellular apoptosis, promoting angiogenesis, and increasing the expression of the specific growth factors to increase the tensile strength of new tissue.⁶⁴⁻⁶⁶

Unfortunately, there is a scarcity of peer-reviewed published data pertaining to regenerative medicine injections for SIJ-related pain, and there is no evidence to suggest that one regenerative medicine injectate is superior to another. There has been one RCT⁶⁷ and two prospective observational studies on this topic.^{31,68} In 2015, Navani and Gupta performed a prospective case series on 10 adult patients with SIJ pain of greater than six months duration and had failed conservative treatments.³¹ All patients underwent a single SIJ injection with 4 cc of PRP utilizing fluoroscopic guidance. All patients experienced at least a 50% reduction in the VAS score and improved function at 12 months post-injection. None of the patients required additional treatments after the PRP injection during the 12-month study follow-up. In 2017, Ko et al reported a prospective case series of four patients that underwent ultrasound guided SIJ PRP injection.⁶⁸ At 12-months post-injection all patients reported a statistically significant reduction in pain and improvement in quality of life. Also in 2017, Singla et al performed a prospective RCT studying the efficacy and safety of PRP versus

methylprednisolone in ultrasound guided SIJ injections.⁶⁷ They enrolled 40 patients with chronic low back pain and a diagnosis of SIJ pathology, and subjects were randomly assigned to either Group S (1.5 mL of methylprednisolone (60 mg), 1.5 mL of 2% lidocaine, and 0.5 mL of saline) or Group P (3 mL of leukocyte-free PRP and 0.5 mL of calcium chloride). Subjects were evaluated at 2 weeks, 4 weeks, 6 weeks, and 3 months. Group P had higher improvements in pain relief, disability, and quality of life at 3 months compared to Group S. In a systematic review, Sanapati et al described the evidence grade for regenerative medicine as Level IV (scale Level I to V), based on the studies above.⁶⁹ They reported that there is a lack of high-quality RCTs, but that the published evidence suggests that regenerative medicine may be effective in managing SIJ pain.

Best Practice Statement on the Use of Regenerative Medicine Techniques for SIJ Pain

The use of regenerative medicine is an evolving therapy with developing evidence. The current use of these therapies should be used based on current literature, and application of these treatments should be considered on an individualized basis when other more validated treatments fail to provide benefit or are contraindicated.

Surgical Techniques – Minimally Invasive Approaches

Minimally Invasive Posterior SI Fusion with Allograft

Options for minimally invasive methods for SIJ fixation include the posterior, oblique, and lateral approaches. When considering these approaches, several considerations need to be met. These include a history and physical exam findings indicating sacroiliitis, failure of previous conservative management, the performance of a diagnostic anesthetic injection at the SIJ on two occasions, and exclusion of more serious disease states such as malignancy. Additionally, three out of five physical exam findings that are diagnostic of SIJ dysfunction must be positive which include the SIJ distraction test, the thigh thrust, the Gaenslen's maneuver, the compression test, and the flexion, abduction and external rotation (FABER) test.^{20,21} Depending on the technique of posterior fixation, one or two allografts may be used.⁷⁰ In addition, a titanium construct is possible.⁷¹ The procedure is normally performed in the prone position, with either local anesthetic and mild sedation, or in some settings, general endotracheal anesthesia. A stab incision is made to access the Steinmann pin to the middle third of the SIJ in procedures where one allograft is used. In a procedure where two allografts are used, the Steinmann pins are placed in the inferior third and superior third of the SIJ as seen in [Figure 5](#). After placement of the Steinmann pin, the inside dilator is placed into the outside dilators and advanced until localized to the SIJ. Next, a decorticator is placed at the location and 1–2 allografts are placed depending on the type of procedure used as described above and shown in [Figure 5](#). After confirmation with the use of fluoroscopy, the incision is properly irrigated, and wound closure is performed.

Various studies have been conducted on the use and outcomes with minimally invasive posterior SIJ fixation with allografts. Sayed et al performed a retrospective analysis of the efficacy and safety of a posterior SI cadaveric allograft implant (PainTEQ, Tampa, FL, USA).⁷² In the study, fifty patients were assessed for outcomes 12-months post implant. In the group, the average NRS score improved from 6.98 pre-fusion to 3.06 at 12 months post-op. There were no procedure-related adverse events or complications. In a study by Deer et al, a retrospective data analysis was conducted on a total of 111 patients who underwent posterior SIJ fixation as a salvage method after failing spinal interventions (PainTEQ, Tampa, FL, USA) and reported an overall pain relief of 67.6% while the overall pain reduction in patients who reported a history of failed back surgery syndrome was 76.5%.⁷³ Prospective data from the SECURE trial at 6 months demonstrated a mean VAS reduction of 34.9 and functional improvement was demonstrated by a mean reduction in Oswestry Disability Index (ODI) of 17.7.⁷⁴ Updated 12 month data from this prospective, multicenter SECURE trial was recently published.⁷⁵ Results displayed consistency and durability, with responder rates of 66%, 74.4%, and 73.5% at the 3, 6, and 12-month follow-ups. Pain scores, ODI, and PROMIS 29 were all significantly improved at 12 months ($p < 0.0001$).

Posterior Oblique Approach

In the posterior oblique approach, one to three surgical implants are placed across the SIJ ([Figure 6b](#)).^{76,77} In one described method, a sacral outlet view is obtained with the fluoroscope and the posterior sacral iliac spine is positioned between the S1 and S2 foramina.⁷⁸ The trajectory is lateral to the posterior sacral iliac spine and towards the sacral

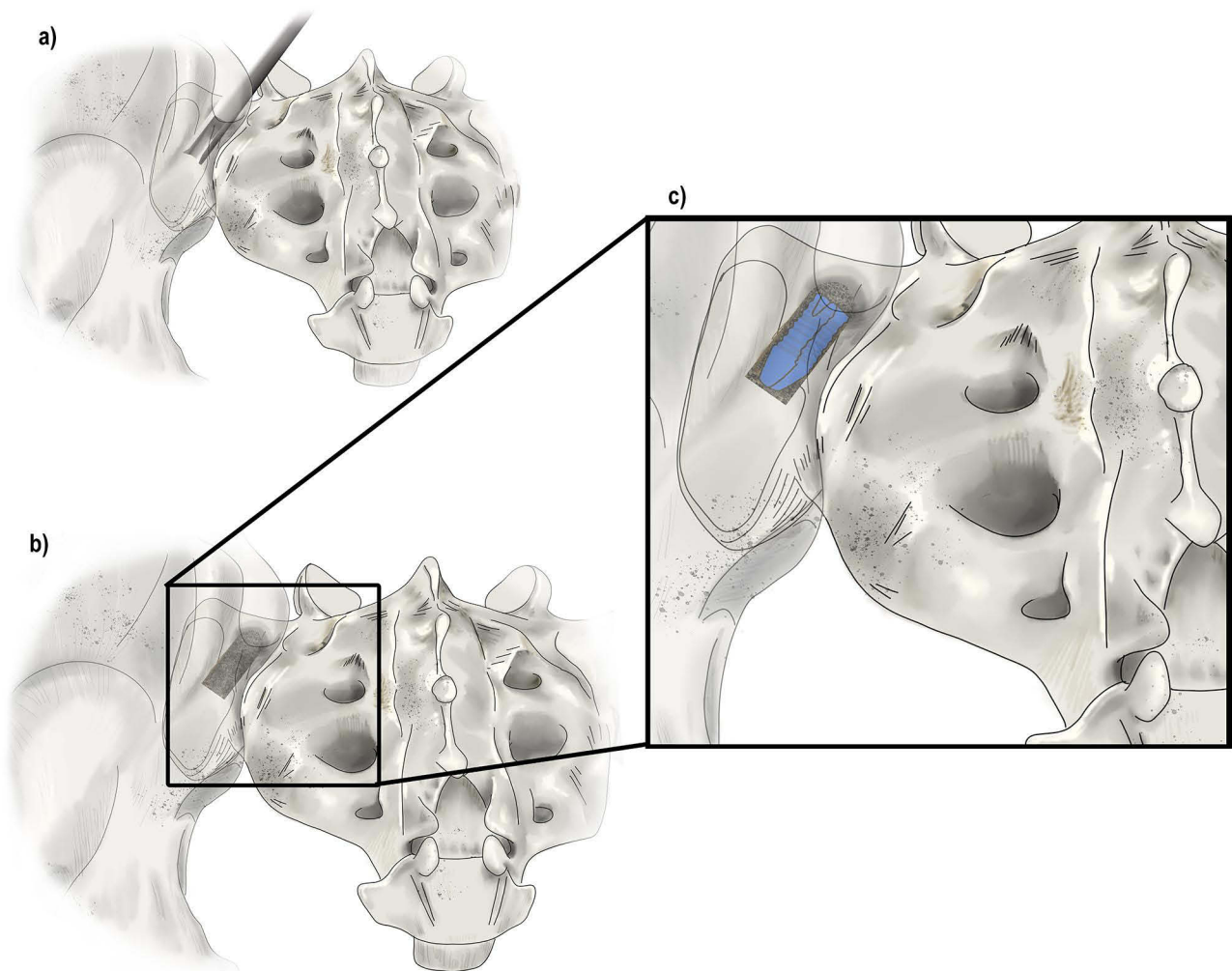


Figure 5 Surgical Techniques: Posterior Allograft Fusion. (a) A large pin (not shown here) is inserted into the joint between the sacrum and the ilium. Next, a tissue dilator and cannula (shown) are inserted to create joint space separation. (b) A rasp is inserted into the cannula to prepare the site for the allograft while decorticating the area. (c) Finally, the allograft which contains the demineralized bone matrix is inserted into the decorticated site to allow for healing and stabilization of the joint. Original medical illustration by Kamil Sochacki, DO.

promontory.⁷⁸ A pedicle access kit (PAK) needle is placed through the ilium, across the SIJ, and into the sacrum.⁷⁸ A guidewire replaces the PAK needle and a threaded implant is placed across the SIJ until the proximal end is flush with the ilium cortex.⁷⁸ This process is repeated up to three times, placing an implant each time as deemed necessary by the surgeon.⁷⁸

Lateral Minimally Invasive SI Fusion

Minimally invasive lateral approach to SIJ fusion currently accounts for the most common approach to minimally invasive SIJ fusions and is the most published and studied. The lateral transarticular approach to SIJ fusion involves the placement of devices across the SIJ from lateral to medial which fixate the ilium and sacrum together (Figure 6a).⁷⁹ At least two, and generally three, implants are placed through the ilium, or wing bone of the pelvis, across the SIJ, and into the sacrum, the large bone at the base of the spine, to immediately reduce the motion of the joint and facilitate long-term fusion of the ilium to the sacrum. This approach, although with higher risk than the posterior approach, has gained popularity because it is less invasive than other previous open approaches and results in less disruption of muscles, ligaments, and tendons. When compared to open SIJ fusion, this approach was associated with shorter operative times, fewer operative complications, and a greater improvement in pain scores at 2 years.⁸⁰

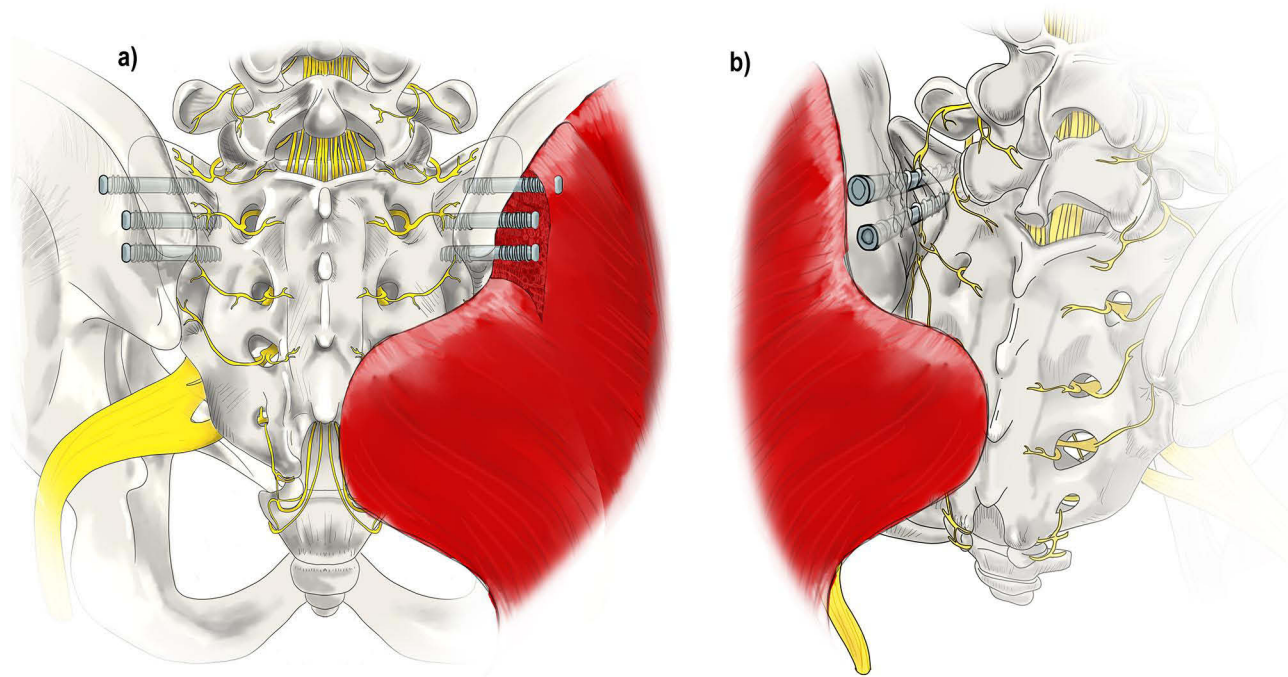


Figure 6 Surgical Techniques: Lateral and Posterior-Oblique Sacral Fusions. (a) The lateral fusion involves the placement of devices across the SIJ from lateral to medial which fixate the ilium and sacrum together. At least two titanium implants are placed through the ilium, or wing bone of the pelvis, across the SIJ, and into the sacrum, the large bone at the base of the spine, to immediately reduce the motion of the joint. This technique involves disruption of musculature. (b) The posterior-oblique approach involves placing implants in a medial to lateral trajectory. The insertion point is the posterior-superior iliac spine which spares dissection of the musculature and minimizes potential injury to other structures. Original medical illustration by Kamil Sochacki, DO.

Lateral SI fusion is most commonly performed under general anesthesia. Favorable patient satisfaction and reduction of pain scores have been reported.⁸⁰ In a prospective study of 172 patients treated with lateral SI fusion, Duhon et al found that SIJ pain decreased from 79.8 at baseline to 30.4 at 12 months and remained low at 26.0 at 24 months ($p < 0.0001$ for change from baseline). ODI decreased from 55.2 at baseline to 31.5 at 12 months and remained low at 30.9 at 24 months ($p < 0.0001$ for change from baseline). Quality of life (SF-36 and EQ-5D) improvements seen at 12 months were sustained at 24 months. The proportion of subjects taking opioids for SIJ or low back pain decreased from 76.2% at baseline to 55.0% at 24 months ($p < 0.0001$).⁸¹ Polly et al conducted a multicenter prospective randomized controlled trial of 148 patients with SIJ pain randomized to lateral fusion or non-surgical care with the option for crossover. By month 24, in the fusion group, 83.1% and 82.0% received either clinical improvement or substantial clinical benefit in VAS SIJ pain score. Similarly, 68.2% and 65.9% had received clinical improvement or substantial clinical benefit in ODI score at month 24. In the NSM group, these proportions were $< 10\%$ with non-surgical treatment only. Parallel changes were seen for EQ-5D and SF-36, with larger changes in the surgery group at 6 months compared to NSM.⁸² Clinical data from studies on patients who have undergone this technique have shown that it generally reduces the pain caused by SIJ dysfunction, reduces disability, and improves the quality of life of patients.⁸³ Risks of the minimally invasive lateral approach appear to be significantly less than risks of open invasive techniques.^{21,84}

Surgical Techniques (Open)

Traditionally, SIJ fusions were conducted with the use of an open technique. One of the first techniques for an open SIJ fusion is the lateral open transiliac subgluteal approach initially described by Smith-Petersen et al in 1921.⁸⁵ In this procedure, the surgical incision is made in the posterior aspect of the iliac crest to access the lateral aspect of ilium.⁸⁵ During the incision, the direction of the incision is from the posterior superior spine toward the direction of the gluteus maximus for 3–4 inches until the junction of the ilium and sacrum is accessed. After the incision has been made, the flap is retracted, and the posterior-lateral surface of the ilium is exposed. Additionally, cartilaginous tissue at the SI junction is

removed to allow for access to the joint. After access has been obtained, the joint is fixed with joints and screws and the aforementioned flap is sutured in place.⁸⁵ Over the course of years, various other methods and variations of the Smith-Petersen method have been described.⁸³ For example, another technique by Gaenslen et al describes a posterior approach to avoid excessive gluteal dissection described in the original Smith-Petersen et al procedure.⁸⁴ Additionally, in recent years, another procedure by Khurana et al describes the use of demineralized bone matrix in a screw accessing the SIJ.⁸⁵ Despite many years of use of the open technique, one of the first procedures to shift towards a minimally invasive approach was described by Wise et al that used a percutaneously inserted fusion cage and initiated the shift towards minimally invasive techniques for SIJ arthrodesis.⁸⁶

Best Practice Statement on Surgical Treatment for SIJ Pain

Minimally invasive surgical treatment can be considered when patients have failed 6 months of conservative treatment and the diagnosis has been confirmed via history, physical exam, and greater than 50% pain relief after a diagnostic, image guided, SIJ injection. Currently, there is no comparative evidence to claim superiority of one minimally invasive technique over another. The recommendation is to choose the safest approach with the greatest chance of clinical success. Approach and implants used should have peer reviewed prospective clinical evidence which demonstrate clinical efficacy and safety.

Algorithm of SIJ Treatments

Given the numerous treatment options available for treating SIJ pain, Falowski et al recently published an evidence-based, proposed algorithm for the appropriate and sequential use of physical therapy, medications, injections, radiofrequency denervation, and joint fusion.²¹ Largely, they propose the sequential escalation to more interventional therapies if and when conservative measures like physical therapy and medications prove to have suboptimal benefit. However, the early use of a SIJ injection may provide additive diagnostic benefit following which the algorithm can continue to be utilized. In addition to the evidence-based proposal, they also cite that patient-directed algorithms may be susceptible to insurance coverage policies.

Evidence and Recommendations for Sacroiliac Joint Interventions and Surgery

Clinical Evidence on SIJ Injections

An evidence summary for SIJ injections is in [Table 5](#), and recommendations can be found in [Table 6](#).

Table 5 Evidence Summary for SIJ Injections

Study Author	Study Type	Study Size	End Point	Evidence Level	Notes
Maugars et al, 1996 ⁴¹	Prospective Double blind RCT	10	NRS	I-A	Compared to sham injection, 62% and 58% of patients at 3 months and 6 months after IA steroid injections noted improvement of pain
Kim et al, 2010 ⁸⁷	Prospective RCT	48	NRS	I-A	Study comparing prolotherapy to SIJ steroid injections found that 58.7% of patients undergoing prolotherapy and 10.2% of patients having SIJ injections noted >50% improvement in pain at 15 months. Interestingly, to be eligible, patients had to have local only SIJ injections that lasted 3 months.
Jee et al, 2014 ⁴³	Prospective RCT	120	NRS, ODI	I-B	Study comparing US v. fluoroscopically guided SIJ injections. Accuracy was greater with fluoroscopic guidance (98.2%) compared to US guidance (87.3%). At 2 weeks, 48.7% decrease in pain and 56.2% decrease in debility for US guided injections while 48.1% decrease in pain and 55.5% decrease in debility seen in fluoroscopic guided SIJ injections. At 12 weeks, 39.7% decrease in pain and 45.6% decrease in debility was seen in US guided injections while 39.7% decrease in pain and 44.8% decrease in debility seen in fluoroscopically guided injections.

(Continued)

Table 5 (Continued).

Study Author	Study Type	Study Size	End Point	Evidence Level	Notes
Liliang et al, 2011 ⁸⁸	Prospective cohort study	52	NRS	I-B	Study evaluating efficacy of dual SIJ blocks in diagnosing SIJ disease in patients prior lumbar and lumbosacral fusions. Pain reduction of >75% within 1–4 hours of injection defined a positive block. Overall, 32.7% of patients were diagnosed with SIJ disease with two diagnostic blocks. A third block was used to diagnose an additional 7.7% of patients who had one positive and 1 negative block initially. In total 40.4% of patients were diagnosed with SIJ disease with SIJ block. False positive rate was deemed 26.0% and false negative was 10.3%.
Chou et al, 2004 ⁸⁹	Retrospective cohort study	194	NRS	I-C	Patients with back and buttock pain were evaluated for SIJ disease. Of 194 patients, 81 (41.7%) had a positive single diagnostic block. Of these 81 patients, 54 (66.7%) had improvement in their pain after a therapeutic SIJ steroid injection defined as >80% improvement in pain for at least 2 weeks. Several injections were allowed to achieve this definition and duration of relief not defined.
Irwin et al, 2007 ⁹⁰	Retrospective chart review	158	NRS	I-C	Study evaluating SIJ blocks to diagnosis SIJ disease. Of 158 patients, 91 (57.5%) had a positive diagnostic block with local. Of these 91 patients, 42 (46.2%) had pain relief with local and steroid SIJ injection, defining this group as having true SIJ dysfunction.
Hawkins et al, 2009 ⁹¹	Retrospective chart review	155	Subjective % pain relief	I-C	Practice audit of 155 patients with SIJ dysfunction. Of the 155 patients, 120 (77%) responded to SIJ injection. Mean duration of relief for patients receiving multiple injections was 9.3 months per injection.
Borowsky et al, 2008 ⁹²	Retrospective review of two case series	120	VAS, Subjective (Relief defined as >50% decrease in VAS Pain score or ability to perform ADLs as “greatly improved”)	I-C	Study comparing intraarticular to intraarticular and periarticular SIJ injections. At 3 months, 12.5% of patients with intra articular SIJ injection versus 31.25% of patients with combined intra-articular and periarticular injection had relief at 3 months
Maugars et al, 1992 ⁹³	Retrospective chart review	22	Subjective % pain relief	I-B	Diagnosis of sacroiliitis with a sero-negative spondyloarthropathy % improvement maintained for at 1 month after IA steroid injection. 100% improvement: 26.2% 80–90% improvement: 40.5% 70–80% improvement: 14.3% 50–70% improvement: 4.8

(Continued)

Table 5 (Continued).

Study Author	Study Type	Study Size	End Point	Evidence Level	Notes
Visser et al, 2013 ⁹⁴	Single blinded RCT	51	VAS, RAND-36	I-B	Evaluating physiotherapy, manual therapy, and IA SIJ steroid injection. In total, 18 patients randomized to IA SIJ injections with success rate of 50%, defined as complete relief of pain at 6 weeks or 12 weeks post treatment or a VAS score less than baseline at 12 weeks. Physiotherapy was found to be successful in 20% of patients while 72% was successful with manual therapy.
Mohi Eldin et al, 2019 ⁹⁵	Prospective nonrandomized control trial	186	VAS	I-B	Study comparing PRP to PRF IA injection for treatment of sacroiliitis. Both showed decreased VAS at 1- and 6-months post injection compared to baseline though only the difference at 6 months was statistically significant. There was no statistically significant difference between PRP and PRF.
Schneider et al 2020 ⁹⁶	Prospective cohort	34	NRS, ODI	I-C	Study evaluating if physical findings prior to SIJ injection, diagnostic block, or combination of the two would help better predict outcomes after IA SIJ steroid injections. Physical exam alone was unsuccessful to predict >2 decrease in NRS, >50% decrease in NRS or >30% decrease in ODI at 2–4 weeks or 6 months follow up. Local anesthetic response only could predict >50% NRS decrease at 2–4 weeks after injection but not at 6 months. However, combination of >3/6 positive physical exam findings and 100% improvement immediately after injection was successful in predicting >50% NRS decrease and >30% ODI decrease at 6 months.
Singla et al, 2016 ⁶⁷	Prospective RCT	40	VAS, MODQ, SF-12	I-B	US guided IA steroid injection versus IA PRP for sacroiliitis. Both decreased post injection VAS however, PRP found to have statistically significant improvement in VAS scores compared to steroids at 6 weeks and 3 months with preserved improvement in MODQ and SF-12 past 6 weeks only in the PRP group.
Soneji et al, 2016 ³⁵	Prospective RCT	40	NRS	I-B	Study comparing US guided to fluoroscopic guided IA SIJ injection. Both groups provided statistically significant decrease in NRS at 1 month and other follow up points compared to baseline. However, there was no statistically significant difference in post injection NRS reductions between US and fluoroscopic guided injection though it took statistically significant less time to perform the IA injection with fluoroscopy.
Cohen et al, 2019 ⁹⁷	Prospective RCT	125	NRS	I-B	Study evaluating fluoroscopic versus anatomic landmark guidance (site of maximum tenderness) SIJ injection. Success was defined as an NRS decrease >2. There was no statistically significant difference in outcomes at 1 month, though there was statistically significant difference at 3 months with improved pain relief in the fluoroscopically guided approach.
Wallace et al, 2020 ⁹⁸	Prospective cohort	50	NRS, ODI	I-C	Study evaluating US guided IA PRP injections for sacroiliitis. There was a notable decrease in NRS and ODI by 6 months, but no p values reported.

(Continued)

Table 5 (Continued).

Study Author	Study Type	Study Size	End Point	Evidence Level	Notes
Liliang et al 2009 ⁹⁹	Prospective observational study	39	VAS, ODI	I-C	Study evaluating effects of IA SIJ injection with steroids. A group of 150 patients with presumed SIJ pain received an IA SIJ injection with steroid. Those with improvement underwent a second injection with steroids and this group of 39 with improvement with both injections were diagnosed with sacroiliitis. Of this group, 26 (66.7%) had improvement in VAS pain >50% for over 6 weeks with mean duration of relief being 36.8 weeks and a reduction in ODI at last follow up as well.
Chen et al, 2022 ¹⁰⁰	Double blinded RCT	26	NRS, ODI	I-B	Double blinded RCT comparing fluoroscopically guided IA steroid v. PRP injection for sacroiliitis. Both treatment arms resulted in reduction in NRS and ODI. However, steroids had a statistically significant improvement in pain from baseline at 1 and 3 months compared to PRP. The statistically significant difference in NRS reduction was also seen at 6 months in favor of steroids.
Luukkainen et al, 1999 ¹⁰¹	Double blinded RCT	20	VAS, pain index	I-B	Patients with seronegative spondyloarthropathy of SIJ were randomized into periarticular injection of steroids versus saline. At 2 months follow up, there was a statistically significant reduction in VAS and pain index in patients treated with steroids compared to saline.
Luukkainen et al, 2002 ¹⁰²	Double blinded RCT	24	VAS, pain index	I-B	Patients without spondyloarthropathy but with back pain in SIJ region were randomized into periarticular injection of steroids versus saline. At 1 month follow up, there was a statistically significant reduction in VAS and pain index in patients treated with steroids compared to saline.
Rosenberg et al, 2000 ¹⁰³	Double blinded prospective study	37	Imaging accuracy	I-C	CT was used to evaluate location of needle placement and contrast injection in anatomic/clinically guided SIJ injection for sacroiliitis. IA placement was accomplished in 22% of the time with injected material 1 cm away from the joint 68% of the time. Epidural injection was seen in 24% of the patients.
Lee et al, 2010 ¹⁰⁴	Prospective Case Control Study	39	NRS, ODI	I-C	Study comparing Botox to steroid for sacroiliac ligament injections for SIJ pain. NRS and ODI were same at 1 month after injection but statistically significantly lower than steroid at 2 and 3 months.

Abbreviations: RCT, Randomized Control Trial; NRS, Numeric Rating Scale; SIJ, Sacroiliac Joint; IA, Intraarticular; ODI, Oswestry Disability Index; US, Ultrasound; VAS, Visual Analog Scale; ADL, Activities of Daily Living; RAND-36, Research and Development Corporation 36 Item Health Survey; PRP, Platelet rich plasma; PRF, Platelet rich fibrin; MODQ, Modified Oswestry Disability Questionnaire; SF-12, Short Form Health Survey; CT, Computed Tomography.

Clinical Evidence on SIJ RFA

A summary of the published evidence for SIJ RFA is in [Table 7](#) and recommendations are in [Table 8](#).

Clinical Evidence on SIJ Fusion

There are more than 60 studies currently available in the literature. [Table 9](#) summarizes their findings. There is a mix of retrospective, prospective and randomized studies. Of these, 58 studies report pain outcomes, while 38 report disability outcomes following sacroiliac fusion. A recent meta-analysis showed no impact of study design on pain and disability scores following sacroiliac fusion.¹¹³ Substantial literature supports the safety and efficacy of minimally invasive SIJ

Table 6 Best Practice Recommendations for SIJ Injections

Recommendation	Grade	Level	Consensus
Fluoroscopic and CT guidance should be used for SIJ injection given safety and increased duration of relief	B	I-A	Moderate
US guidance can be considered for SIJ injections where radiation exposure may be problematic	B	I-B	Moderate
IA steroid injections may offer benefit compared to conservative therapy for sacroiliitis.	A	I-B	Strong
PRP and PRF IA injections may offer benefit compared to conservative therapy for sacroiliitis.	B	I-B	Moderate
Diagnostic SIJ IA injections combine with physical exam are effective in determining and confirming sacroiliitis when utilized jointly.	A	I-B	Strong

Abbreviations: CT, Computed tomography; SIJ, Sacroiliac joint; US, Ultrasound; PRP, Platelet rich plasma; PRF, Platelet rich fibrin.

Table 7 Evidence Summary for SIJ Radiofrequency Ablations

Study Author	Study Type	Study Size	End Point	Evidence Level	Notes
Cohen et al, 2008 ⁵⁴	Prospective RCT	28	NRS, ODI	I-A	RCT comparing cooled SIJ RFA (L4, L5 dorsal rami and SI-3 lateral branch) to sham RFA with option for 6-month crossover from placebo/sham RFA to conventional RFA. A decrease in NRS was seen from baseline (6.1) at 1 month (2.4), 3 month (2.4), and 6 months (2.6) in the randomized arm. This decrease in NRS was also seen from baseline (6.3) at 1 month (3.6), 3 month (2.1), and 6 months (3.1) in the cross over arm while the NRS remained at 6.5 at baseline, 6.3 at 1 month, and 6.0 at 3 months follow up for the Sham procedure. ODI was also seen to decrease appreciably after RFA and cross over.
Patel et al, 2012 ⁵⁹	Prospective RCT	51	NRS, SF-36BP, SF-36PF, ODI	I-A	RCT comparing cooled SIJ RFA (L5 dorsal rami and SI-3 lateral branches) to sham RFA with option for sham to RFA cross over at 3 months. Success was deemed $\geq 50\%$ decrease in NRS at final time points compared to baseline with either a 10-point increase in SF-36 or a 10-point decrease in ODI. At 3 months, 47% of RFA group was deemed successful compared to 12% of sham. RFA is superior (47%) to sham (12%) at 3 months. This success for initial cooled SIJ RFA was seen to be 59% at 9 months. Those that crossed over at 3 months had a 44% rate of success at 6 months post RFA follow up.
Van Tilburg et al, 2016 ¹⁰⁵	Prospective RCT	60	NRS, GPE	I-A	RCT comparing traditional (85°C) RFA of L5 dorsal rami and SI-4 lateral branches to sham with follow up 3 months after treatment. No statistically significant difference seen between sham and treatment group in NRS or GPE at 1 month or 3 months follow up.

(Continued)

Table 7 (Continued).

Study Author	Study Type	Study Size	End Point	Evidence Level	Notes
Salman et al, 2016 ¹⁰⁶	Prospective RCT	30	VAS	I-A	RCT comparing IA SIJ steroid injections to traditional (80°C) SIJ RFA (L4, L5 dorsal rami and S1-3 lateral branches). Success was defined as >50% decrease in pain intensity compared to baseline. At one month, 20% of steroid group and 73% RFA group was deemed successful. The steroid injection group did not have any notable success at 3 or 6 months while the RFA group had 60% and 53% success at 3 and 6 months respectively.
Juch et al, 2017 ¹⁰⁷	Prospective RCT	228 (SIJ arm)	NRS, GPE, ODI, EQ-5D-3L, RAND-36, West Haven-Yale Multidimensional Pain Inventory	I-A	RCT comparing exercise to exercise and RFA in treatment of facetogenic and SIJ dysfunction as cause of low back pain. There was no statistically significant difference between outcomes comparing exercise alone to exercise with RFA.
Burnham et al, 2022 ¹⁰⁸	Prospective Cohort Study	37	NRS, PDQQ	I-B	Study evaluating efficacy of US and fluoroscopic guided longitudinal axis lateral crest approach for SIJ RFA via single monopolar needle compared to classic palisade technique. Results for relief comparable between this new approach and the palisade technique at 3 months after treatment
Dutta et al, 2018 ¹⁰⁹	Prospective RCT	30	NRS, ODI	I-A	RCT comparing IA SIJ steroid injections to SIJ pulsed RFA (L4, L5 dorsal rami and S1-3 lateral branches). Both IA SIJ injections and RFA provided improvement in NRS and ODI at 3 months and 6 months after treatment. However, there is statistically significant improvement in pain and functioning in patients with SIJ Pulsed RFA compared to IA SIJ.
Patel, 2016 ¹¹⁰	Prospective RCT	41	NRS, SF-36BP, SF-36PF, ODI	I-B	Twelve month follow up data from the Patel et al 2012 paper showing statistically significant improvement in NRS, ODI, SF36-BP, and SF36-PF from baseline at 12 months after SIJ cooled RFA.
Zheng et al, 2014 ¹¹¹	Prospective RCT	155	VAS, ASAS20, ASDAS, BASMI, BASFI	I-A	RCT comparing Celebrex to CT guided SIJ RFA (S1-4) RFA. There were statistically significant greater improvements in VAS, BASFI, total back pain, and nocturnal back pain in both groups at 12 weeks and 24 weeks. However, there was only statistically significant improvement in BASFI in the SIJ RFA arm at 12 weeks and 24 weeks. SIJ RFA was found to result in statistically significant greater reduction in VAS, BASMI, BASFI, total back pain, and nocturnal back pain compared to Celebrex at 12 weeks and 24 weeks.

(Continued)

Table 7 (Continued).

Study Author	Study Type	Study Size	End Point	Evidence Level	Notes
Vallejo et al, 2006 ¹¹²	Prospective Case Series	22	VAS, FACIT	I-C	Study evaluating pulsed RFA (L4, L5 dorsal rami and S1-3) for treatment of sacroiliitis refractory to IA SIJ steroid injections. In total, 126 patients with SIJ dysfunction underwent IA SIJ steroid injection and 22 patients failed to respond. These 22 patients underwent RFA and there was a statistically significant reduction in VAS and improvement in physical as well as functional wellbeing at 6 months compared to baseline.

Abbreviations: RCT, Randomized Control Trial; NRS, Numeric Rating Scale; ODI, Oswestry Disability Index; SIJ, Sacroiliac Joint; RFA, Radiofrequency ablation; SF-36BP, Research and Development Corporation 36 Item Health Survey bodily pain; SF-36PF, Research and Development Corporation 36 Item Health Survey Physical Functioning; GPE, Global Perceived Effect; VAS, Visual Analog Scale; IA, Intraarticular; EQ-5D-3L, 3 Level EuroQOL 5D Health Questionnaire; RAND-36, Research and Development Corporation 36 Item Health Survey; PDQQ, Pain Disability Quality of Life Questionnaire; US, Ultrasound; ASAS20, 20% improvement from baseline of ASA response criteria; ASDAS, Ankylosing Spondylitis Disease Activity Score; BASMI, Bath Ankylosing Spondylitis Metrology Index; BASFI, Bath Ankylosing Spondylitis Functional Index; FACIT, Functional Assessment of Chronic Illness Therapy; CT, Computed tomography.

Table 8 Best Practice Recommendations on SIJ RFA

Recommendation	Grade	Level	Consensus
SIJ RFA may be considered for treatment of sacroiliitis refractory to conventional conservative care.	B	I-B	Strong
There are no comparative studies thus there is no recommended preferred modality of SIJ RFA for sacroiliitis.	I	I-A	Strong
SIJ RFA seems to provide longer lasting relief compared to SIJ steroid injections for treatment of sacroiliitis.	C	I-A	Moderate

Abbreviations: SIJ, Sacroiliac Joint; RFA, Radiofrequency ablation,

Table 9 Summary of Clinical Studies on SIJ Fusion/Stabilization

Author, Year	Study design	Device	Approach	Sample size	Outcome measures	Results	Level of evidence
Al-Khayer, 2008 ¹¹⁴	Case series	HMA screw	Lateral	9	VAS, ODI	Mean VAS decreased from 8.1 to 4.6; mean ODI decreased from 59 to 45	II
Wise and Dall, 2008 ⁸⁶	Case series	Threaded cage		13	VAS	Average improvement of 4.9 cm and 2.4 cm on VAS for axial pain and leg pain respectively	II
Khurana, 2009 ⁸⁵	Case series	HMA screw	Lateral	15	SF-36, Majeed score	Mean SF-36 improved from 37 to 80 for physical function and 53 to 86 for general health; mean Majeed score increased from 37 to 79	II
Rudolf, 2012 ¹¹⁵	Retrospective, observational	iFuse	Lateral	50	Created questionnaire with questions from NRS, SF-36 and ODI	Statistically significant improvement in pain and function was identified at all post-operative time points; clinically significant improvement was observed in 7 out of 9 domains of daily living	I-C
Sachs and Capobianco, 2012 ¹¹⁶	Case series	iFuse	Lateral	11	NRS	Mean NRS was 7.9 (\pm 2.2) and decreased to 2.3 (\pm 3.1), resulting in clinically and statistically significant improvement	II

(Continued)

Table 9 (Continued).

Author, Year	Study design	Device	Approach	Sample size	Outcome measures	Results	Level of evidence
Sachs and Capobianco, 2013 ¹¹⁷	Retrospective, observational	iFuse	Lateral	40	NRS	Mean pain score improved from 8.7 (1.5 SD) at baseline to 0.9 (1.6) at 12 months, a 7.8-point improvement	I-C
Cummings and Capobianco, 2013 ¹¹⁸	Retrospective, observational	iFuse	Lateral	18	VAS, ODI, SF-12 PCS, SF-12 MCS	All patient-reported outcomes showed both clinically and statistically significant improvement at 12 months	I-C
Endres, 2013 ¹¹⁹	Case series	DIANA	Posterior	19	ODI, VAS	Mean ODI decreased 64.1 to 57; Mean VAS decreased from 8.5 to 6.0	II
Gaetani, 2013 ¹²⁰	Retrospective, observational	iFuse	Lateral	12	NRS, ODI, RMDQ	Clinical and statistically significant mean improvement in NRS by 4 points, ODI by 19.4 points, and in RMDQ by 13.6 points	I-C
Smith, 2013 ¹²¹	Retrospective, observational	iFuse	Lateral	263	VAS, surgical parameter	Lateral compared to open approach demonstrated a 3.5 lower VAS score, and lower hospitalization duration, operating time and estimated blood loss	I-C
Mason, 2013 ¹²²	Prospective, observational	HMA screw	Lateral	55	VAS, SF-36, Majeed score	VAS improved from 8 to 4.5; SF-36 improved from 26.6 to 42.9; Majeed score increased from 36.9 to 64.8	I-B
Schroeder, 2013 ¹²³	Case series	iFuse	Lateral	6	VAS, ODI, SRS22	Leg VAS score improved from 6.5 to 2.0, while back VAS decreased from 7.83 to 2.67; ODI scores dropped from 22.2 to 10.5 and SRS22 scores increased from 2/93 to 3.65	II
Sachs, 2014 ¹²⁴	Retrospective, observational	iFuse	Lateral	144	VAS	Mean VAS improved by 6.1 points (5.7–6.6) at last follow up with substantial clinical benefit (decreased >2.5 points) achieved in 91.9% of patients	I-C
Ledonio, 2014a ¹²⁵	Retrospective, observational	iFuse	Lateral	39	ODI	Open and lateral SIJ fusion techniques resulted in statistically and clinically significant improvement in pain and disability, however, the number of patients reaching the minimal clinically important difference and those showing overall improvement were greater in the lateral approach versus open	I-C
Ledonio, 2014b ¹²⁵	Retrospective, observational	iFuse	Lateral	44	Surgical parameters, ODI	Comparison between open and lateral approach revealed that the open group had a higher mean estimated blood loss, surgical time and duration of hospital stay; mean postoperative ODI scores were not different between groups	I-C

(Continued)

Table 9 (Continued).

Author, Year	Study design	Device	Approach	Sample size	Outcome measures	Results	Level of evidence
Rudolf, 2014 ¹²⁶	Retrospective, observational	iFuse	Lateral	17	VAS, ODI, radiographic bony fusion	Mean VAS improved from 8.3 to 2.4; mean ODI cohort was 21.5 (moderate disability) postoperatively; radiographic fusion was seen in 87% of patients	I-C
Duhon, 2016 ⁸¹	Prospective, observational	iFuse	Lateral	172	VAS, ODI, opioid use	VAS decreased from 79.9 to 26; ODI decreased from 55.2 to 30.9; Opioid use decreased from 76.2% to 55%	I-B
Kube, 2016 ¹²⁷	Retrospective, observational	Simmetry	Lateral	18	VAS, ODI, fusion rate	Overall fusion rate was 88%; VAS improved from 81.7 to 44.1 points for back pain and from 63.6 to 27.7 points for leg pain. ODI scores improved from 61.0 to 40.5	I-C
Polly, 2016 ⁸²	RCT	iFuse	Lateral	148	VAS, ODI	Substantial clinical benefit in VAS and ODI reported by 82% and 66% of subjects respectively within the fusion group compared to control	I-A
Sachs, 2016 ¹²⁸	Retrospective, observational	iFuse	Lateral	107	VAS, ODI	Mean VAS at baseline reduced from 7.5 to 2.6; mean ODI was 28.2 at last follow up	I-C
Araghi, 2017 ¹²⁹	Prospective, observational	Simmetry	Lateral	50	VAS, ODI, opioid use	VAS decreased from 76.2 to 35.1; ODI decreased from 55.5 to 35.3 and opioid use reduced from 66 to 30%	I-B
Kancherla, 2017 ¹³⁰	Retrospective, observational	iFuse	Lateral	45	VAS, ODI, SF-12	Mean SF-12 physical score statistically improved comparing early to late survey follow-up, while ODI and VAS did not.	I-C
Rappoport, 2017 ¹³¹	Prospective, observational	SI-LOK	Lateral	32	VAS, ODI	Statistically significant decrease in mean VAS	I-B
Bornemann, 2017 ¹³²	Prospective, observational	iFuse	Lateral	24	VAS, ODI	VAS and ODI improved 84.3 ± 9.2 mm to 40.7 ± 9.2 mm and from 76.8 ± 9.2% to 40.7 ± 9.2% respectively	I-B
Vanaclocha, 2018 ¹³³	Retrospective, observational	iFuse	Lateral	137	VAS, ODI	Comparison between conservative, denervation and lateral fusion treatment. Patients treated with lateral fusion had longer clinical responses with lower opioid use, reduced pain and disability, compared to intermediate response with denervation and short term with conservative treatment	I-C
Cross, 2018 ¹³⁴	Prospective, observational	Simmetry	Lateral	19	NRS, fusion rate	Significant reduction in NRS (74%) noted; 79% bridging bone fusion at 12-month and 94% at 24-month	I-B
Fuchs and Ruhl, 2018 ⁷¹	Retrospective, observational	DIANA	Posterior	171	VAS, ODI, SF-12, SF-MPQ	VAS decreased from 74 to 37mm; ODI improved from 51 to 33; SF-MPQ decreased from 50% to 31%, SF-12 physical component increased from 22% to 41% and mental component increased from 40 to 55%	I-C

(Continued)

Table 9 (Continued).

Author, Year	Study design	Device	Approach	Sample size	Outcome measures	Results	Level of evidence
Rajpal and Burneikiene, 2018 ¹³⁵	Retrospective, observational	RIALTO	Posterior	24	NRS, self-reported satisfaction	NRS decreased from 6.6 to 3.7 and from 4.8 to 1.5 for back and leg pain, respectively; Mean total satisfaction score was 79%	I-C
Darr, 2018 ¹³⁶	Prospective, observational	iFuse	Lateral	103	VAS, ODI, EQ-5D	55 points mean improvement in pain; mean ODI improved of 28 points; 0.3 points improvement on EQ-5D	I-B
Rainov, 2019 ¹³⁷	Prospective, observational	iFuse	Lateral	160	VAS, ODI	SIJ pain decreased from 8.0 to 2.5 ($p < 0.0001$) and disability (ODI) decreased from 45.3 to 16.4 ($p < 0.0001$). The proportion with clinically significant improvements in SIJ pain and ODI was high ($> 95\%$)	I-B
Cleveland, 2019 ¹³⁸	Retrospective, observational	iFuse	Lateral	50	VAS, ODI, DSIIQ	Statistically significant improvement in VAS, ODI and DSIIQ	I-C
Dengler, 2019 ¹³⁹	RCT	iFuse	Lateral	103	VAS, ODI	43.3-point improvement in mean VAS and 26-point improvement in ODI in the surgery group compared to control	I-A
Whang, 2019 ¹⁴⁰	RCT	iFuse	Lateral	103	NRS, ODI, EQ-5D, opioid use, fusion rate	Fusion versus nonsurgical management. Mean NRS decreased by a mean of 54 points, ODI decreased by 26 points, ED-5D increased by 0.29 points; opioid use decreased from 77% to 41%; 88% joint fusion rate	I-A
Patel, 2020 ¹⁴¹	Prospective, observational	iFuse	Lateral	51	ODI, NRS, opioid use	ODI decreased from 52.8 to 27.9; NRS decreased from 78 to 21; opioid use decreased from 57% to 22%	I-B
Claus, 2020 ⁷⁶	Retrospective, observational	iFuse RIALTO	Lateral vs Posterolateral	156	VAS, ODI, SF-12	Significant improvement in VAS, ODI and SF-12 in both cohorts; but no statistical difference between the two groups	I-C
Schmidt, 2020 ¹⁴²	Retrospective, observational	iFuse	Lateral	19	VAS, SF-36	Mean VAS score improved from 7 to 3; all patients had improvement in their SF-36 physical function scores (mean 40 preoperatively to 55 at final follow up)	I-C
Abbasi, 2021 ¹⁴³	Retrospective, observational	Simmetry Corelink LnK	Lateral	62	ODI	Mean ODI improved from 52.2% to 34.9%	I-C
Chin, 2021 ⁷⁷	Case series	Sacrofuse	Lateral	3	VAS, ODI, SF-12	Mean VAS decreased from 8.33 to 2.33, while mean ODI decreased from 62.00 to 19.00 and mean SF PCS increased from 25.53 to 52.32 and mean SF MCS increased from 26.80 to 56.30	II
Sayed, 2021a ⁷²	Retrospective, observational	LINQ	Posterior	50	NRS, % pain relief	Mean NRS reduced from 6.98 to 3.06; average overall 66.5% relief	I-C

(Continued)

Table 9 (Continued).

Author, Year	Study design	Device	Approach	Sample size	Outcome measures	Results	Level of evidence
Sayed, 2021 ^{b70}	Cadaveric case series	LINQ	Posterior	6	Optical tracking system range of motion of the joint versus implantation shift	Unilateral and bilateral fixations generated SJJ motion reductions in flexion-extension, lateral bending, and axial rotation motions; reduction in the total range of motion had a moderate correlation with the shift of the center of instantaneous axis of rotation	N/A
Patel, 2021 ¹⁴⁴	Prospective, observational	iFuse	Lateral	51	ODI, NRS	Mean ODI decreased from 52.8 to 28.3; NRS decreased from 78.5 to 21.5	I-B
Deer, 2021 ⁷³	Retrospective, observational	LINQ	Posterior	111	% pain relief	Mean overall relief of 67.6% ± 28.9%; 91.9% reported >30% pain relief; 46.8% reported >80% pain relief	I-C
Kurosawa, 2021 ¹⁴⁵	Retrospective, observational	Sacral alar iliac screws and plate	Lateral	26	VAS, RMDQ, Preoperative identifiers of poor outcome	Mean VAS improved from 86.8 to 24.6 and RMDQ from 18.9 to 4 on the good outcome group compared to the poor outcome group. Preoperative features associated with poor surgical outcomes were female sex, pain in multiple regions, walking with a cane, and the use of a wheelchair preoperatively	I-C
Kurosawa, 2022 ¹⁴⁶	Case series	iFuse	Lateral	5	VAS, ODI	Mean VAS improved from 88.0 ± 8.4 to 33.6 ± 31.9 mm at 3 months and 46.4 ± 30.9 mm at 36 months. Mean ODI improved significantly from 76.4% ± 3.8% to 46.2% ± 21.9% at 6 months, but not after	II
Rappoport, 2021 ¹⁴⁷	Prospective, observational	SI-LOK	Lateral	32	VAS, ODI	Mean VAS decreased significantly to 20.0, 5.8 and 11.5 for back, left leg and right leg respectively; ODI score decreased significantly to 27.5 points	I-B
Novak, 2021 ¹⁴⁸	Prospective, observational	iFuse	Lateral	20	VAS	Clinical improvement was reported in 81% of patients; mean VAS reduced from 6.1 points to 2.9 points postoperatively	I-B
Wales, 2021 ¹⁴⁹	Prospective, observational	SI-LOK	Lateral	33	SF-36, ODI, ED-5D, Majeed	Overall improvement in all patient reported outcomes, however, only mental component of SF-36, ODI, Majeed scores, and ED-5D-5L were statistically significant	I-C
Calodney, 2022 ⁷⁴	Prospective, observational	LINQ	Posterior	69	VAS, ODI	VAS mean average reduction 34.9; 17.7 mean ODI reduction	I-B
Amer, 2022 ¹⁵⁰	Case series	iFuse	Lateral	20	VAS, ODI, SF-36	Mean VAS improved from 81.25 ± 10.7 SD preoperatively to 52.5 ± 26.8; mean ODI improved from 54.8 ± 11.21 SD to 41.315 ± 15.34; mean PCS and MCS of SF36 improved by 17 and 20 points, respectively	II

(Continued)

Table 9 (Continued).

Author, Year	Study design	Device	Approach	Sample size	Outcome measures	Results	Level of evidence
Kasapovic, 2022 ¹⁵¹	Prospective, observational	iFuse	Lateral	26	VAS, ODI, EQ-5D, opioid use	Mean VAS decreased 8.4 to 4.6; mean ODI decreased from 58.1 to 32.; mean EQ-5D improved from 0.5 to 0.7; opioid use decreased from 82% to 39%	I-B
Kasapovic, 2022 ¹⁵²	Prospective, observational	Torpedo	Lateral	15	NRS, ODI, opioid use	ODI median values were 62% (quartiles 1–3: 53–67) lower than preoperatively; opioid use decreased from 87% to 20%; NRS decreased in all subjects	I-B
Chaves, 2022 ¹⁵³	Retrospective, observational	SI-LOK	Lateral	36	VAS	The mean preoperative VAS score decreased from 7.2 ± 1.1 to 1.6 ± 1.46 postoperatively	I-C
Hermans, 2022 ¹⁵⁴	Retrospective, observational	iFuse	Lateral	29	VAS, EQ-5D, opioid use	Mean VAS improved from 7.83 ± 1.71 to 4.97 ± 2.63; EQ-5D improved from 0.266 ± 0.129 to 0.499 ± 0.260; opioid consumption decreased from 44.8 to 24.1%	I-C
Kucharzyk, 2022 ¹⁵⁵	Prospective, observational	Simmetry	Lateral	250	VAS, ODI, opioid use, fusion rate	Mean VAS reduced from 76.4 to 33.0; mean ODI improved from 54.4 to 30.5; opioid use reduced from 62.7% to 26.9%; 68.7% fusion rate at the last follow-up	I-B
Lynch, 2022 ¹⁵⁶	Retrospective, observational	PSiF	Posterior	57	Back pain severity, pain tolerance	Post-market registry analysis revealed that all clinical outcomes showed statistically significant improvement for back pain severity by 44% (6.8 ± 2 to 3.8 ± 3), pain-tolerant standing time by 183% (29 ± 53 mins. to 82 ± 36 mins.), and pain-tolerant walking distance by 55% (87 ± 267 steps to 135 ± 374 steps)	I-C
Sarkar, 2022 ¹⁵⁷	Retrospective, observational	SI-LOK RIALTO	Lateral vs Posterolateral	43	VAS, fusion rate	Lateral versus posterolateral approach using robotic guidance versus Stealth Navigation System. Mean baseline VAS score decreased from 7.52 ± 1.3 to 1.43 ± 1.22; SIJ fusion rate was 61% at 6 months, 96.4% at 12 months, and 100% at 18 months	I-C
Sayed, 2022 ¹⁵⁸	Retrospective, observational	LINQ	Posterior	7	NRS, opioid use, fusion rate	Subjects who failed fusion with a lateral approach underwent re-surgery with a posterior approach. The mean NRS improvement following posterior fusion was 80%; opioid use decreased with median morphine milliequivalents 20 pre-procedure and 0 post-procedure	I-C
Soliman, 2022 ¹⁵⁹	Retrospective, observational	iFuse	Lateral	33	VAS, ODI	Mean VAS was 68.9 at baseline and decreased to 53.1; similarly showed a significant improvement postoperatively	I-C

(Continued)

Table 9 (Continued).

Author, Year	Study design	Device	Approach	Sample size	Outcome measures	Results	Level of evidence
Wessell, 2022a ¹⁶⁰	Retrospective, observational	iFuse	Lateral	45	VAS, ODI, opioid use, DSIIQ	No change in opioid use from baseline. Significant improvements in VAS from 6.2 to 3.9; ODI and DSIIQ patient-reported outcomes scores also showed significant improvements at 12 months after surgery (ODI: 48.9 preoperative vs 24.6 postoperative, DSIIQ: 53.2 preoperative vs 17.4 postoperative)	I-C
Wessell, 2022b ¹⁶¹	Retrospective, observational	iFuse Simmetry	Lateral	77	Anatomical variants	A positive trend towards better outcomes in bipartite/dysmorphic and accessory joint variants, while semicircular defect and crescent variants trended toward worse outcomes. There appears to be a trend toward differences in surgical outcomes based on SIJ anatomy.	I-C
Wang, 2022 ¹⁶²	Retrospective, observational	SI-LOK	Lateral	10	NRS, opioid use	The average NRS was 5.2 ± 1.0 , and the average opioid administration was 27.6 ± 10.3 morphine equivalents preoperative. At the last follow-up, patients reported an average of $73.1\% \pm 30.1\%$ improvement in their preoperative pain	I-C
Anton, 2023 ¹⁶³	Retrospective, observational	RIALTO	Posterolateral	118	VAS, ODI, fusion rate	94.9% fusion rate based on imaging; ODI and VAS statistically significantly improved from baseline	I-C
Cahueque, 2023 ¹⁶⁴	Retrospective, observational	Sacrix	Posterior	45	VAS, ODI	The posterior approach cohort demonstrated greater VAS reduction, shorter operative time and duration of hospital stay, and improved ODI scores, compared to lateral approach	I-C
Cross, 2023 ¹⁶⁵	Retrospective, observational	Integrity-SI	Posterolateral	75	ODI, NRS, SANE, PROMIS	Statistically significant improvement in ODI, NRS, PROMIS and SANE (patient satisfaction) scores and 81% fusion rate noted up to 12-month	I-C
Jedi, 2023 ¹⁶⁶	Retrospective, observational	SI-LOK	Lateral	85	VAS	Statistically and clinically significant improvement in VAS in all patients at final follow-up	I-C
Raikar, 2023 ¹⁶⁷	Case series	Sacrix	Posterior	19	NRS, radiographic fusion, self-reported function improvement	Mean NRS decreased from 8.95 to 2.32; 94.7% of subjects had >50% pain relief; 100% radiographic fusion noted at 12-month follow up and 94.7% self-reported improvement in function	II
Sayed, 2023 ¹⁶⁸	Cadaveric case series	LINQ	Posterior	6	Range of motion evaluation by optical tracking system between posterior versus lateral approach	During flexion-extension, the posterior approach is equivalent to the lateral approach, however the posterior fusion approach produced superior stabilization during lateral bend and axial rotation	N/A

(Continued)

Table 9 (Continued).

Author, Year	Study design	Device	Approach	Sample size	Outcome measures	Results	Level of evidence
Calodney, 2024 ⁷⁵	Prospective, observational	LINQ	Posterior	86	VAS, ODI, PROMIS 29, Adverse Events	66.0%, 74.4%, and 73.5% of participants classified as responders at the 3-, 6- and 12-month follow-up visits, respectively. VAS scores were significantly reduced ($p < 0.0001$) and ODI scores were significantly improved ($p < 0.0001$). All domains of the PROMIS-29 were also significantly improved (all p 's < 0.0001). Only one procedure-related serious AE was reported in the study.	I-B

Abbreviations: HMA, Hollow modular anchorage; RCT, Randomized clinical trial; VAS, Visual analog scale; NRS, Numeric rating scale; ODI, Oswestry disability index; SF 12/ 36, Short-form (SF) health assessment; PCS, Physical components scale; MCS, Mental components scale; SF-MPQ, Short form McGill Pain Questionnaire; EQ-5D, Euro quality of life health questionnaire; SD, Standard deviation; DSIIQ, Denver Sacroiliac joint questionnaire; SANE, single assessment numeric evaluation; RMDQ, Roland Morris Disability Questionnaire; SRS22, Scoliosis Research Society questionnaire; SIJ, Sacroiliac joint; PROMIS, Patient-Reported Outcomes Measurement Information System[®].

fusion.¹¹³ While the quantity of evidence is currently more robust with the lateral approach given its preexistence, available studies suggest that that the posterior approach has at least similar efficacy with a lower risk profile.^{74,75}

Summary of Safety in SIJ Fusion

Direct comparison of adverse event rates across different procedure approaches is generally not available. Minimally invasive SIJ fusion utilizing a lateral approach has been shown to have a total procedural complication rate of up to 11.11%, with the most common adverse events of wound infection, trochanteric bursitis, and hematoma formation. Shamrock et al reviewed the safety of transiliac SIJ fusion and reported 14 studies of a total of 720 patients with 91 procedural-related, including infection and hematoma, and a revision rate of 2.56%.⁸⁰ Similarly, Heiney et al reported surgical wound infection as the most common complication associated with the transiliac SIJ fusion in a systematic review of 432 subjects.¹⁶⁹ Implant malposition causing symptoms resulting from inadvertent nerve root injury is more likely with the lateral approach, and published data suggests a lower rate of adverse events with the posterior approach.⁷⁴ Meta-regression analysis showed that acute malposition was significantly associated with the lateral approach. Table 10 summarizes these findings from Whang et al 2023.¹¹³ Findings from this meta-analysis suggest a lower rate of serious adverse events compared to previous studies. including the following: implant malposition, 0.43%; wound infection, 0.15%; major bleeding, 0.4%.¹¹³ Risks of the lateral approach are significantly less than risks of open approach but are higher than risks associated with the posterior approach.^{21,140} In a combined cohort of four studies involving 237 subjects who underwent posterior approach sacroiliac fusion, there were no serious adverse events reported, including no implant breakage, bone fracture, infection, bleeding requiring surgery, viscous perforation, but only one device migration.^{72-74,158} Rajpal et al reported two hematomas and one infection on a cohort of 24 subjects.¹³⁵ Posterior sacroiliac fusion approach appears to have a significantly lower safety risk profile due to avoidance of critical neurovascular structures that can be

Table 10 Summary of Adverse Events Reported in the Current Literature

Approach	Total Number of Studies	Total Number of Subjects	Safety Rate
Lateral	47	2348	0.43% implant malposition; 0.145% infection; 0.002% fracture; 0.4% bleeding; 0.6% removal for pain; 0% breakage, migration
Posterolateral	8	317	1.11% removal for pain; 0% malposition, breakage, migration, infection, fracture, bleeding
Posterior	8	497	0.48% removal for pain; 0.35% migration; 0.2% malposition; 0% bleeding, infection, breakage, fracture

Notes: Data from Whang et al.¹¹³

encountered with lateral and posterolateral approaches.¹⁷⁰ There have been no reported serious complications as a result of percutaneous posterior allograft SIJ fusion.⁷²

ASPN Best Practice Statements on Minimally Invasive Sacroiliac Fusion

Recommendations

- Minimally invasive posterior SI stabilization with allograft is considered medically necessary when the appropriate clinical criteria have been met.
- Inclusions
 - 1) A failure of conservative measures to at least include physical therapy and injections.
 - 2) Pain persisting a minimum of 6 months that interferes with functional activities as documented by both a pain score of VAS/NRS of 5 or greater and an ODI of 30 or more.
 - 3) Failure of at least one therapeutic sacroiliac joint injection (less than 50% pain relief for three months duration).
 - 4) Predominant pain pattern consistent with sacroiliac joint pathology.
 - 5) Positive response from at least three validated maneuvers for sacroiliac joint dysfunction.
 - 6) Positive Fortin finger test.
 - 7) Diagnostic imaging: either CT or MRI that excludes destructive lesions of the sacroiliac joint.
 - 8) Diagnostic confirmation of the SI joint as the pain generator demonstrated by at least one image guided (CT or fluoroscopy) intraarticular injection of the SI joint with 50% or greater pain relief for the expected duration of the local anesthetic.
- Exclusions
 - 1) Infection or fracture (unrelated to implant).
 - 2) Tumor.
 - 3) Acute traumatic instability.
- 1. Grade: A
- 2. Level of Evidence: 1-B
- 3. Level of Certainty of Net benefit: High
- Minimally invasive SI fusion with lateral transfixing devices is considered medically necessary when the appropriate clinical criteria have been met (as above).
 1. Grade: A
 2. Level of Evidence: 1-A
 3. Level of Certainty of Net benefit: High
- Minimally invasive SI fusion implants should be used according to FDA labeling.
 1. Grade: A
 2. Level of Evidence: 1-A
 3. Level of Certainty of Net benefit: High
- The use of implants composed of human cell and tissue products for sacroiliac fusion is considered medically necessary only if the guidelines set forth by the FDA Regulation of Human Cells and Tissue is followed and should be registered in the FDA Human Cell and Tissue Establishment Registration.
 1. Grade: A
 2. Level of Evidence: N/A
 3. Level of Certainty of Benefit: High
- ASPN supports the utilization of sacroiliac fusion and stabilization devices with published, peer-reviewed, multi-center, prospective evidence of at least 6 months duration to assess efficacy and safety.
 1. Grade: A

2. Level of Evidence: 1-A
3. Level of Certainty of Benefit: High
 - The current evidence is insufficient to determine the medical necessity of emerging techniques for minimally invasive sacroiliac fusion such as posterior-transfixing, and hybrid approaches.
1. Grade: I
2. Level of Evidence: II
3. Level of Certainty: Low

Conclusion

The treatment of SID is a complex and important matter in the management of patients with back, buttock and leg pain. The best practice of treating this disorder involves 1) An understanding of anatomy; 2) Proper history taking of factors suggesting this pathology; 3) An understanding of comorbid pathologies that can cause similar complaints; 4) An understanding of imaging and ruling out other significant disease processes; 5) An understanding of physical examination for SID; 6) An understanding of diagnostic injections and evaluation of response; 7) An understanding of the proper use and methods of neuroablative procedures; and 8) An understanding of the risk to benefit assessment of various methods of minimally invasive and surgical methods of SID treatment.

When each of these goals are met using best practices, the patient has the most likely chance of an optimal outcome with improvements in both safety and efficacy.

Abbreviations

ASAS20, 20% improvement from baseline of ASA response criteria; ASDAS, Ankylosing Spondylitis Disease Activity Score; ASPN, American Society of Pain and Neuroscience; BASFI, Bath Ankylosing Spondylitis Functional Index; BASMI, Bath Ankylosing Spondylitis Metrology Index; BMAC, Bone marrow aspirate stem cell concentrate; CT, Computed tomography; DSIJQ, Denver Sacroiliac joint questionnaire; EQ-5D, Euro quality of life health questionnaire; FABER test, Flexion, abduction and external rotation; FACIT, Functional Assessment of Chronic Illness Therapy; FDA, United States Food and Drug Administration; GPE, Global Perceived Effect; HMA, Hollow modular anchorage; IA, Intraarticular; MAUDE, Manufacturer and User Facility Device Experience; MODQ, Modified Oswestry Disability Questionnaire; MRI, Magnetic resonance imaging; NRS, Numeric rating scale; NSAID, Non-steroidal anti-inflammatory drug; ODI, Oswestry Disability Index; PAK, Pedicle access kit; PDGF, Platelet-derived growth factors; PDQQ, Pain Disability Quality of Life Questionnaire; PRF, Platelet rich fibrin; PRP, Platelet rich plasma; PSN, Posterior sacral network; RAND-36, Research and Development Corporation 36-Item Health Survey; RCT, Randomized controlled trial; RFA, Radiofrequency ablation; RMDQ, Roland Morris Disability Questionnaire; SANE, Single assessment numeric evaluation; SD, Standard deviation; SF, Short-form health questionnaire (eg, SF-36, SF-12); SI, Sacroiliac; SID, Sacroiliac disorders; SIJ, Sacroiliac joint; SRS22, Scoliosis Research Society; SVF, Stromal vascular fraction; US, Ultrasound; USPSTF, United States Preventative Services Task Force; VAS, Visual analog scale.

Acknowledgments

Editing was provided by Allison Foster, PhD, of Foster Medical Communications.

Funding

Development of this guideline was supported by unrestricted educational grants from SI Bone and PainTEQ.

Disclosure

DS is a consultant to Abbott, PainTEQ, Saluda, Mainstay, Surgentec, Nevro, and holds stock options with PainTEQ, Neuralace, Mainstay, Vertos, and SPR. TRD is a consultant PainTEQ, CornerLoc, and Spinal Simplicity. VTF receives research funding from Nevro Corporation part of an investigator-initiated study grant that is not related to this manuscript. TEW is a consultant for Medtronic and has received research funding from Medtronic, SPR Therapeutics, Nevro, and Boston Scientific. JSW is a consultant for Abbott, SI Bone, Vertos Medical, Biotronik, Saluda, and AbbVie, receives

research funding from Abbott, SI Bone, Saluda, and Medtronic, serves on an advisory board for Abbott, SI Bone, Vertos Medical, and Biotronik, and serves on a speaker board for Abbott, SI Bone, & Abbvie. RSD receives investigator-initiated research grant funding from Nevro Corp and Saol Therapeutics that is paid to his institution. KA is a consultant for Nevro, Saluda, Biotronik, Boston Scientific, and Presidio, reports minor options from PainTEQ. MJD is a consultant for Globus, Camber, LifeSpine, Vyrsa, PainTEQ, Nevro, Abbott, and Biotronik. DTDN is a consultant for SI Bone, Stratus Medical, and Neurovassiss. CB is a consultant for Nevro, Abbott, Vertos, Spinal Simplicity, and PainTEQ; reports personal fees from Nevro, Spinal Simplicity, PainTEQ, and Boston Scientific, outside the submitted work. AA is a consultant for Curonix, Medtronic and Avanos. The authors report no other conflicts of interest in this work.

References

- Deer TR, Grider JS, Pope JE, et al. Best practices for minimally invasive lumbar spinal stenosis treatment 2.0 (MIST): consensus guidance from the American Society of Pain and Neuroscience (ASPN). *J Pain Res.* 2022;15:1325–1354. doi:10.2147/JPR.S355285
- Harris RP, Helfand M, Woolf SH, et al. Current methods of the U.S. preventive services task force: a review of the process. *Am J Preventive Med.* 2001;20(3 SUPPL):21–35. doi:10.1016/S0749-3797(01)00261-6
- Foley BS, Buschbacher RM. Sacroiliac joint pain: anatomy, biomechanics, diagnosis, and treatment. *Am J Phys Med Rehabil.* 2006;85(12):997–1006. doi:10.1097/01.phm.0000247633.68694.c1
- Cohen SP. Sacroiliac joint pain: a comprehensive review of anatomy, diagnosis, and treatment. *Anesth Analg.* 2005;101(5):1440–1453. doi:10.1213/01.ANE.0000180831.60169.EA
- Alderink GJ. The sacroiliac joint: review of anatomy, mechanics, and function. *J Orthop Sports Phys Ther.* 1991;13(2):71–84. doi:10.2519/jospt.1991.13.2.71
- Frost S, Grossfeld S, Kirkley A, Litchfield B, Fowler P, Amendola A. The efficacy of femoral nerve block in pain reduction for outpatient hamstring anterior cruciate ligament reconstruction: a double-blind, prospective, randomized trial. *Arthroscopy.* 2000;16(3):243–248. doi:10.1016/s0749-8063(00)90047-1
- Vleeming A, Schuenke MD, Masi AT, Carreiro JE, Danneels L, Willard FH. The sacroiliac joint: an overview of its anatomy, function and potential clinical implications. *J Anat.* 2012;221(6):537–567. doi:10.1111/j.1469-7580.2012.01564.x
- Nakagawa T. Study on the distribution of nerve filaments over the iliosacral joint and its adjacent region in the Japanese. *Nihon Seikeigeka Gakkai Zasshi.* 1966;40(4):419–430.
- Grob KR, Neuberger WL, Kissling RO. Innervation of the sacroiliac joint of the human. *Z Rheumatol.* 1995;54(2):117–122.
- Fortin JD, Kissling RO, O'Connor BL, Vilensky JA. Sacroiliac joint innervation and pain. *Am J Orthop Belle Mead NJ.* 1999;28(12):687–690.
- Vleeming A, Volkers AC, Snijders CJ, Stoeckart R. Relation between form and function in the sacroiliac joint. Part II: Biomechanical Aspects Spine. 1990;15(2):133–136. doi:10.1097/00007632-199002000-00017
- Kiapour A, Joukar A, Elgafy H, Erbulut DU, Agarwal AK, Goel VK. Biomechanics of the sacroiliac joint: anatomy, function, biomechanics, sexual dimorphism, and causes of pain. *Int J Spine Surg.* 2020;14(Suppl 1):3–13. doi:10.14444/6077
- Vleeming A, Van Wingerden JP, Dijkstra PF, Stoeckart R, Snijders CJ, Stijnen T. Mobility in the sacroiliac joints in the elderly: a kinematic and radiological study. *Clin Biomech.* 1992;7(3):170–176. doi:10.1016/0268-0033(92)90032-Y
- Miller JA, Schultz AB, Andersson GB. Load-displacement behavior of sacroiliac joints. *J Orthop Res.* 1987;5(1):92–101. doi:10.1002/jor.1100050112
- Forst SL, Wheeler MT, Fortin JD, Vilensky JA. The sacroiliac joint: anatomy, physiology and clinical significance. *Pain Physician.* 2006;9(1):61–67.
- Sashin D. A critical analysis of the anatomy and the pathologic changes of the sacro-iliac joints. *J Bone Joint Surg.* 1930;12(4):891–910.
- Rashbaum RF, Ohnmeiss DD, Lindley EM, Kitchel SH, Patel VV. Sacroiliac joint pain and its treatment. *Clinical Spine Surg.* 2016;29(2):42–48. doi:10.1097/BSD.0000000000000359
- Gartenberg A, Nessim A, Cho W. Sacroiliac joint dysfunction: pathophysiology, diagnosis, and treatment. *Eur Spine J.* 2021;30(10):2936–2943. doi:10.1007/s00586-021-06927-9
- Schneider BJ, Rosati R, Zheng P, McCormick ZL. Challenges in diagnosing sacroiliac joint pain: a narrative review. *PM R.* 2019;11:S40–S45. doi:10.1002/pmrj.12175
- Buchanan P, Vodapally S, Lee DW, et al. Successful diagnosis of sacroiliac joint dysfunction. *J Pain Res.* 2021;14:3135–3143. doi:10.2147/JPR.S327351
- Falowski S, Sayed D, Pope J, et al. A review and algorithm in the diagnosis and treatment of sacroiliac joint pain. *J Pain Res.* 2020;13:3337–3348. doi:10.2147/JPR.S279390
- Laslett M, Aprill CN, McDonald B. Provocation sacroiliac joint tests have validity in the diagnosis of sacroiliac joint pain. *Arch Phys Med Rehabil.* 2006;87(6):874. doi:10.1016/j.apmr.2006.04.007
- Hammer N, Möbius R, Schleifenbaum S, et al. Pelvic belt effects on health outcomes and functional parameters of patients with sacroiliac joint pain. *PLoS One.* 2015;10(8):e0136375. doi:10.1371/journal.pone.0136375
- Eno JJT, Boone CR, Bellino MJ, Bishop JA. The prevalence of sacroiliac joint degeneration in asymptomatic adults. *J Bone Joint Surg Am.* 2015;97(11):932–936. doi:10.2106/JBJS.N.01101
- Polly D, Cher D, Whang PG, Frank C, Sembrano J. Does level of response to SI joint block predict response to SI joint fusion? *Int J Spine Surg.* 2016;10:4. doi:10.14444/3004
- Vleeming A, Buyruk HM, Stoeckart R, Karamursel S, Snijders CJ. An integrated therapy for peripartum pelvic instability: a study of the biomechanical effects of pelvic belts. *Am J Obstet Gynecol.* 1992;166(4):1243–1247. doi:10.1016/s0002-9378(11)90615-2
- Jung HS, Jeon HS, Oh DW, Kwon OY. Effect of the pelvic compression belt on the Hip extensor activation patterns of sacroiliac joint pain patients during one-leg standing: a pilot study. *Man Ther.* 2013;18(2):143–148. doi:10.1016/j.math.2012.09.003

28. Pulisetti D, Ebraheim NA. CT-guided sacroiliac joint injections. *J Spinal Disord.* 1999;12(4):310–312. doi:10.1097/00002517-199908000-00007
29. Khuba S, Agarwal A, Gautam S, Kumar S. Fluoroscopic sacroiliac joint injection: is oblique angulation really necessary? *Pain Physician.* 2016;19:8.
30. Chauhan G, Hehar P, Loomba V, Upadhyay A. A randomized controlled trial of fluoroscopically-guided sacroiliac joint injections: a comparison of the posteroanterior and classical oblique techniques. *Neurospine.* 2019;16(2):317–324. doi:10.14245/ns.1836122.061
31. Navani A, Gupta D. Role of intra-articular platelet-rich plasma in sacroiliac joint pain. *Tech Reg Anesthesia Pain Manage.* 2015;19(1):54–59. doi:10.1053/j.trap.2016.09.010
32. Kennedy DJ, Schneider B, Casey E, et al. Vasovagal rates in fluoroscopically guided interventional procedures: a study of over 8000 injections. *Pain Med.* 2013;14(12):1854–1859. doi:10.1111/pme.12241
33. Hartung W, Ross CJ, Straub R, et al. Ultrasound-guided sacroiliac joint injection in patients with established sacroiliitis: precise IA injection verified by MRI scanning does not predict clinical outcome. *Rheumatology.* 2010;49(8):1479–1482. doi:10.1093/rheumatology/kep424
34. Saunders J, Cusi M, Hackett L, Der HV, Van der Wall H. An exploration of ultrasound-guided therapeutic injection of the dorsal interosseous ligaments of the sacroiliac joint for mechanical dysfunction of the joint. *JSM Pain Manag.* 2016;1(1):1003–1006.
35. Soneji N, Bhatia A, Seib R, Tumber P, Dissanayake M, Peng PWH. Comparison of fluoroscopy and ultrasound guidance for sacroiliac joint injection in patients with chronic low back pain. *Pain Pract.* 2016;16(5):537–544. doi:10.1111/papr.12304
36. Ward S, Jenson M, Royal MA, Movva V, Bhakta B, Gunyea I. Fluoroscopy-guided sacroiliac joint injections with phenol ablation for persistent sacroiliitis: a case series. *Pain Pract.* 2002;2(4):332–335. doi:10.1046/j.1533-2500.2002.02043.x
37. Burnham RS, Yasui Y. An alternate method of radiofrequency neurotomy of the sacroiliac joint: a pilot study of the effect on pain, function, and satisfaction. *Reg Anesth Pain Med.* 2007;32(1):12–19. doi:10.1016/j.rapm.2006.08.008
38. Cox RC, Fortin JD. The anatomy of the lateral branches of the sacral dorsal rami: implications for radiofrequency ablation. *Pain Physician.* 2014;17(5):459–464.
39. Homra BK, Eshraghi Y, Guirguis M. Lateral branch blocks. In: Abd-Elseyed A, Sayed D, Abd-Elseyed A, Sayed D editors. *Sacroiliac Joint Pain: A Comprehensive Guide to Interventional and Surgical Procedures.* Oxford University Press; 2021:1. doi:10.1093/med/9780197607947.003.0007
40. Cheng J, Abdi S. COMPLICATIONS OF JOINT, TENDON, AND MUSCLE INJECTIONS. *Tech Reg Anesth Pain Manag.* 2007;11(3):141–147. doi:10.1053/j.trap.2007.05.006
41. Maugars Y, Mathis C, Berthelot JM, Charlier C, Prost A. Assessment of the efficacy of sacroiliac corticosteroid injections in spondylarthropathies: a double-blind study. *Br J Rheumatol.* 1996;35(8):767–770. doi:10.1093/rheumatology/35.8.767
42. King W, Ahmed SU, Baisden J, et al. Diagnosis and treatment of posterior sacroiliac complex pain: a systematic review with comprehensive analysis of the published data. *Pain Med.* 2015;16(2):257–265. doi:10.1111/pme.12630
43. Jee H, Lee JH, Park KD, Ahn J, Park Y. Ultrasound-guided versus fluoroscopy-guided sacroiliac joint intra-articular injections in the noninflammatory sacroiliac joint dysfunction: a prospective, randomized, single-blinded study. *Arch Phys Med Rehabil.* 2014;95(2):330–337. doi:10.1016/j.apmr.2013.09.021
44. Maigne JY, Aivaliklis A, Pfefer F. Results of sacroiliac joint double block and value of sacroiliac pain provocation tests in 54 patients with low back pain. *Spine.* 1996;21(16):1889–1892. doi:10.1097/00007632-199608150-00012
45. Cohen SP, Abdi S. Lateral branch blocks as a treatment for sacroiliac joint pain: a pilot study. *Reg Anesth Pain Med.* 2003;28(2):113–119. doi:10.1053/rapm.2003.50029
46. Dreyfuss P, Henning T, Malladi N, Goldstein B, Bogduk N. The ability of multi-site, multi-depth sacral lateral branch blocks to anesthetize the sacroiliac joint complex. *Pain Med.* 2009;10(4):679–688. doi:10.1111/j.1526-4637.2009.00631.x
47. Lee DW, Pritzlaff S, Jung MJ, et al. Latest evidence-based application for radiofrequency neurotomy (LEARN): best practice guidelines from the American Society of Pain and Neuroscience (ASPEN). *J Pain Res.* 2021;14:2807–2831. doi:10.2147/JPR.S325665
48. Turk DC, Dworkin RH, Allen RR, et al. Core outcome domains for chronic pain clinical trials: IMMPACT recommendations. *Pain.* 2003;106(3):337–345. doi:10.1016/j.pain.2003.08.001
49. Cohen SP, Bhaskar A, Bhatia A, et al. Consensus practice guidelines on interventions for lumbar facet joint pain from a multispecialty, international working group. *Reg Anesth Pain Med.* 2020;45(6):424–467. doi:10.1136/rapm-2019-101243
50. Ferrante FM, King LF, Roche EA, et al. Radiofrequency sacroiliac joint denervation for sacroiliac syndrome. *Reg Anesth Pain Med.* 2001;26(2):137–142. doi:10.1053/rapm.2001.21739
51. Yin W, Willard F, Carreiro J, Dreyfuss P. Sensory stimulation-guided sacroiliac joint radiofrequency neurotomy: technique based on neuroanatomy of the dorsal sacral plexus. *Spine.* 2003;28(20):2419–2425. doi:10.1097/01.BRS.0000085360.03758.C3
52. Roberts SL, Stout A, Loh EY, Swain N, Dreyfuss P, Agur AM. Anatomical comparison of radiofrequency ablation techniques for sacroiliac joint pain. *Pain Med.* 2018;19(10):1924–1943. doi:10.1093/pm/pnx329
53. Cohen SP, Strassels SA, Kurihara C, et al. Outcome predictors for sacroiliac joint (lateral branch) radiofrequency denervation. *Reg Anesth Pain Med.* 2009;34(3):206–214. doi:10.1097/AAP.0b013e3181958f4b
54. Cohen SP, Hurley RW, Buckenmaier CC, Kurihara C, Morlando B, Dragovich A. Randomized placebo-controlled study evaluating lateral branch radiofrequency denervation for sacroiliac joint pain. *Anesthesiology.* 2008;109(2):279–288. doi:10.1097/ALN.0b013e31817f4c7c
55. Schmidt P, Pino C, Vorenkamp K. Sacroiliac joint radiofrequency ablation with a multilesion probe: a case series of 60 patients. *Anesthesia Analg.* 2014;119(2):460–462. doi:10.1213/ANE.0000000000000282
56. Cosman ER, Gonzalez CD. Bipolar radiofrequency lesion geometry: implications for palisade treatment of sacroiliac joint pain. *Pain Pract.* 2011;11(1):3–22. doi:10.1111/j.1533-2500.2010.00400.x
57. Ikeda R. Innervation of the sacroiliac joint. Macroscopical and histological studies. *Nihon Ika Daigaku Zasshi.* 1991;58(5):587–596. doi:10.1272/jnms1923.58.587
58. Vilensky JA, O'Connor BL, Fortin JD, et al. Histologic analysis of neural elements in the human sacroiliac joint. *Spine.* 2002;27(11):1202–1207. doi:10.1097/00007632-200206010-00012
59. Patel N, Gross A, Brown L, Gekht G. A randomized, placebo-controlled study to assess the efficacy of lateral branch neurotomy for chronic sacroiliac joint pain. *Pain Med.* 2012;13(3):383–398. doi:10.1111/j.1526-4637.2012.01328.x

60. Yang AJ, Wagner G, Burnham T, McCormick ZL, Schneider BJ. Radiofrequency ablation for chronic posterior sacroiliac joint complex pain: a comprehensive review. *Pain Med.* 2021;22(Suppl 1):S9–S13. doi:10.1093/pm/pnab021
61. Speldewinde GC. Successful thermal neurotomy of the painful sacroiliac ligament/joint Complex-A comparison of two techniques. *Pain Med.* 2020;21(3):561–569. doi:10.1093/pm/pnz282
62. Tinnirello A, Barbieri S, Todeschini M, Marchesini M. Conventional (Simplicity III) and cooled (sinergy) radiofrequency for sacroiliac joint denervation: one-year retrospective study comparing two devices. *Pain Med.* 2017;18(9):1731–1744. doi:10.1093/pm/pnw333
63. Sun HH, Zhuang SY, Hong X, Xie XH, Zhu L, Wu XT. The efficacy and safety of using cooled radiofrequency in treating chronic sacroiliac joint pain: a PRISMA-compliant meta-analysis. *Medicine (Baltimore).* 2018;97(6):e9809. doi:10.1097/MD.0000000000009809
64. Navani A, Manchikanti L, Albers SL, et al. Responsible, safe, and effective use of biologics in the management of low back pain: American society of interventional pain physicians (ASIPP) Guidelines. *Pain Physician.* 2019;22(1S):1.
65. Miguélez-Rivera L, Pérez-Castrillo S, González-Fernández ML, et al. Immunomodulation of mesenchymal stem cells in discogenic pain. *Spine J.* 2018;18(2):330–342. doi:10.1016/j.spinee.2017.09.002
66. Hunt CL, Her YF, Law LA, et al. Five generations of cell preparation: a translational framework for categorizing regenerative stem cell therapies. *J Am Acad Regen Med.* 2017;1(1). doi:10.4081/jaarm.2017.7239
67. Singla V, Batra YK, Bharti N, Goni VG, Marwaha N. Steroid vs. Platelet-rich plasma in ultrasound-guided sacroiliac joint injection for chronic low back pain. *Pain Pract.* 2017;17(6):782–791. doi:10.1111/papr.12526
68. Ko GD, Mindra S, Lawson GE, Whitmore S, Arseneau L. Case series of ultrasound-guided platelet-rich plasma injections for sacroiliac joint dysfunction. *J Back Musculoskeletal Rehabil.* 2017;30(2):363–370. doi:10.3233/BMR-160734
69. Sanapati J, Manchikanti L, Atluri S, et al. Do regenerative medicine therapies provide long-term relief in chronic low back pain: a systematic review and meta-analysis. *Pain Physician.* 2018;21(6):515–540.
70. Sayed D, Amirdelfan K, Naidu RK, Raji OR, Falowski S. A cadaver-based biomechanical evaluation of a novel posterior approach to sacroiliac joint fusion: analysis of the fixation and center of the instantaneous axis of rotation. *MDER.* 2021;14:435–444. doi:10.2147/MDER.S347763
71. Fuchs V, Ruhl B. Distraction arthrodesis of the sacroiliac joint: 2-year results of a descriptive prospective multi-center cohort study in 171 patients. *Eur Spine J.* 2018;27(1):194–204. doi:10.1007/s00586-017-5313-2
72. Sayed D, Balter K, Pyles S, Lam CM. A multicenter retrospective analysis of the long-term efficacy and safety of a novel posterior sacroiliac fusion device. *J Pain Res.* 2021;14:3251–3258. doi:10.2147/JPR.S326827
73. Deer TR, Rupp A, Budwany R, et al. Pain relief salvage with a novel minimally invasive posterior sacroiliac joint fusion device in patients with previously implanted pain devices and therapies. *J Pain Res.* 2021;14:2709–2715. doi:10.2147/JPR.S325059
74. Calodney AK, Azeem N, Buchanan P, et al. Six month interim outcomes from SECURE: a single arm, multicenter, prospective, clinical study on a novel minimally invasive posterior sacroiliac fusion device. *Expert Rev Med Devices.* 2022;19(5):451–461. doi:10.1080/17434440.2022.2090244
75. Calodney A, Azeem N, Buchanan P, et al. Safety, efficacy, and durability of outcomes: results from SECURE: a single arm, multicenter, prospective, clinical study on a minimally invasive posterior sacroiliac fusion allograft implant. *J Pain Res.* 2024;17:1209–1222. doi:10.2147/JPR.S458334
76. Claus CF, Lytle E, Kaufmann A, et al. Minimally invasive sacroiliac joint fusion using triangular titanium versus cylindrical threaded implants: a comparison of patient-reported outcomes. *World Neurosurg.* 2020;133:e745–e750. doi:10.1016/j.wneu.2019.09.150
77. Chin KR, Pencle FJ, Seale JA, Pandey DK. CT scan and clinical outcomes of novel lateral-oblique percutaneous sacroiliac joint (SIJ) fixation: technique and literature review. *Cureus.* 2021;13(7):e16408. doi:10.7759/cureus.16408
78. Whang P, Cher D, Polly D, et al. Sacroiliac joint fusion using triangular titanium implants vs. non-surgical management: six-month outcomes from a prospective randomized controlled trial. *Int J Spine Surg.* 2015;9:6. doi:10.14444/2006
79. Stark JG, Fuentes JA, Fuentes TI, Idemmili C. The history of sacroiliac joint arthrodesis: a critical review and introduction of a new technique. *Current Orthopaedic Practice.* 2011;22(6):545. doi:10.1097/BCO.0b013e31823563d3
80. Shamrock AG, Patel A, Alam M, Shamrock KH, Al Maaieh M. The safety profile of percutaneous minimally invasive sacroiliac joint fusion. *Global Spin J.* 2019;9(8):874–880. doi:10.1177/2192568218816981
81. Duhon BS, Bitan F, Lockstadt H, et al. Triangular titanium implants for minimally invasive sacroiliac joint fusion: 2-year follow-up from a prospective multicenter trial. *Int J Spine Surg.* 2016;10:13. doi:10.14444/3013
82. Polly DW, Swofford J, Whang PG, et al. Two-year outcomes from a randomized controlled trial of minimally invasive sacroiliac joint fusion vs. non-surgical management for sacroiliac joint dysfunction. *Int J Spine Surg.* 2016;10. doi:10.14444/3028
83. Smith-Petersen M. Arthrodesis of the sacroiliac joint. A new method of approach. *J Orthoped Surg.* 1921;3(8):400–405.
84. Gaenslen FJ. Sacro-ILIAC arthrodesis: indications, author's technic and end-results. *J Am Med Assoc.* 1927;89(24):2031–2035. doi:10.1001/jama.1927.02690240023008
85. Khurana A, Guha AR, Mohanty K, Ahuja S. Percutaneous fusion of the sacroiliac joint with hollow modular Anchorage screws: clinical and radiological outcome. *J Bone Joint Surg Br.* 2009;91(5):627–631. doi:10.1302/0301-620X.91B5.21519
86. Wise CL, Dall BE. Minimally invasive sacroiliac arthrodesis: outcomes of a new technique. *J Spinal Disord Tech.* 2008;21(8):579–584. doi:10.1097/BSD.0b013e31815ecc4b
87. Kim WM, Lee HG, Jeong CW, Kim CM, Yoon MH. A randomized controlled trial of intra-articular prolotherapy versus steroid injection for sacroiliac joint pain. *J Altern Complement Med.* 2010;16(12):1285–1290. doi:10.1089/acm.2010.0031
88. Liliang PC, Lu K, Liang CL, Tsai YD, Wang KW, Chen HJ. Sacroiliac joint pain after lumbar and lumbosacral fusion: findings using dual sacroiliac joint blocks. *Pain Med.* 2011;12(4):565–570. doi:10.1111/j.1526-4637.2011.01087.x
89. Chou LH, Slipman CW, Bhagia SM, et al. Inciting events initiating injection-proven sacroiliac joint syndrome. *Pain Med.* 2004;5(1):26–32. doi:10.1111/j.1526-4637.2004.04009.x
90. Irwin RW, Watson T, Minick RP, Ambrosius WT. Age, body mass index, and gender differences in sacroiliac joint pathology. *Am J Phys Med Rehabil.* 2007;86(1):37–44. doi:10.1097/phm.0b013e31802b8554
91. Hawkins J, Schofferman J. Serial Therapeutic sacroiliac joint injections: a practice audit. *Pain Med.* 2009;10(5):850–853. doi:10.1111/j.1526-4637.2009.00651.x
92. Borowsky CD, Fagen G. Sources of sacroiliac region pain: insights gained from a study comparing standard intra-articular injection with a technique combining intra- and peri-articular injection. *Arch Phys Med Rehabil.* 2008;89(11):2048–2056. doi:10.1016/j.apmr.2008.06.006

93. Maugars Y, Mathis C, Vilon P, Prost A. Corticosteroid injection of the sacroiliac joint in patients with seronegative spondylarthropathy. *Arthritis Rheum.* 1992;35(5):564–568. doi:10.1002/art.1780350512
94. Visser LH, Woudenberg NP, de Bont J, et al. Treatment of the sacroiliac joint in patients with leg pain: a randomized-controlled trial. *Eur Spine J.* 2013;22(10):2310–2317. doi:10.1007/s00586-013-2833-2
95. Mohi Eldin M, Sorour OO, Hassan ASA, Baraka M, Ahmed MF. Percutaneous injection of autologous platelet-rich fibrin versus platelet-rich plasma in sacroiliac joint dysfunction: an applied comparative study. *J Back Musculoskeletal Rehabil.* 2019;32(3):511–518. doi:10.3233/BMR-181366
96. Schneider BJ, Ehsanian R, Huynh L, Levin J, Zheng P, Kennedy DJ. Pain and functional outcomes after sacroiliac joint injection with anesthetic and corticosteroid at six months, stratified by anesthetic response and physical exam maneuvers. *Pain Med.* 2020;21(1):32–40. doi:10.1093/pm/pnz111
97. Cohen SP, Bicket MC, Kurihara C, et al. Fluoroscopically guided vs landmark-guided sacroiliac joint injections: a randomized controlled study. *Mayo Clin Proc.* 2019;94(4):628–642. doi:10.1016/j.mayocp.2018.08.038
98. Wallace P, Bezjian Wallace L, Tamura S, Prochnio K, Morgan K, Hemler D. Effectiveness of ultrasound-guided platelet-rich plasma injections in relieving sacroiliac joint dysfunction. *Am J Phys Med Rehabil.* 2020;99(8):689–693. doi:10.1097/PHM.0000000000001389
99. Liliang PC, Lu K, Weng HC, Liang CL, Tsai YD, Chen HJ. The therapeutic efficacy of sacroiliac joint blocks with triamcinolone acetonide in the treatment of sacroiliac joint dysfunction without spondyloarthropathy. *Spine.* 2009;34(9):896–900. doi:10.1097/BRS.0b013e31819e2c78
100. Chen AS, Solberg J, Smith C, et al. Intra-articular platelet rich plasma vs corticosteroid injections for sacroiliac joint pain: a double-blinded, randomized clinical trial. *Pain Med.* 2022;23(7):1266–1271. doi:10.1093/pm/pnab332
101. Luukkainen R, Nissilä M, Asikainen E, et al. Periarticular corticosteroid treatment of the sacroiliac joint in patients with seronegative spondylarthropathy. *Clin Exp Rheumatol.* 1999;17(1):88–90.
102. Luukkainen RK, Wennerstrand PV, Kautiainen HH, Sanila MT, Asikainen EL. Efficacy of periarticular corticosteroid treatment of the sacroiliac joint in non-spondylarthropathic patients with chronic low back pain in the region of the sacroiliac joint. *Clin Exp Rheumatol.* 2002;20(1):52–54.
103. Rosenberg JM, Quint TJ, de Rosayro AM. Computerized tomographic localization of clinically-guided sacroiliac joint injections. *Clin J Pain.* 2000;16(1):18–21. doi:10.1097/00002508-200003000-00004
104. Salehi H, Moussaei M, Kamiab Z, Vakilian A. The effects of botulinum toxin type A injection on pain symptoms, quality of life, and sleep quality of patients with diabetic neuropathy: a randomized double-blind clinical trial. *Iran J Neurol.* 2019;18(3):99–107.
105. van Tilburg CWJ, Schuurmans FA, Stronks DL, Groeneweg JG, FJPM H. Randomized sham-controlled double-blind multicenter clinical trial to ascertain the effect of percutaneous radiofrequency treatment for sacroiliac joint pain: three-month results. *Clin J Pain.* 2016;32(11):921–926. doi:10.1097/AJP.0000000000000351
106. Salman OH, Gad GS, Mohamed AA, Rafae HH, Abdelfatah AM. Randomized, controlled blind study comparing sacroiliac intra-articular steroid injection to radiofrequency denervation for sacroiliac joint pain. *Egypt J Anaesth.* 2016;32(2):219–225. doi:10.1016/j.egja.2015.07.005
107. Juch JNS, Maas ET, Ostelo RWJG, et al. Effect of radiofrequency denervation on pain intensity among patients with chronic low back pain: the mint randomized clinical trials. *JAMA.* 2017;318(1):68–81. doi:10.1001/jama.2017.7918
108. Burnham TR, Smith A, McCormick ZL, Teramoto M, Burnham R. Evaluation of an ultrasound-assisted longitudinal axis lateral crest approach to radiofrequency ablation of the sacroiliac joint. *Am J Phys Med Rehabil.* 2022;101(1):26–31. doi:10.1097/PHM.0000000000001733
109. Dutta K, Dey S, Bhattacharyya P, Agarwal S, Dev P. Comparison of efficacy of lateral branch pulsed radiofrequency denervation and intraarticular depot methylprednisolone injection for sacroiliac joint pain. *Pain Physician.* 2018;21(5):489–496.
110. Patel N. Twelve-month follow-up of a randomized trial assessing cooled radiofrequency denervation as a treatment for sacroiliac region pain. *Pain Pract.* 2016;16(2):154–167. doi:10.1111/papr.12269
111. Zheng Y, Gu M, Shi D, Li M, Ye L, Wang X. Tomography-guided palisade sacroiliac joint radiofrequency neurotomy versus celecoxib for ankylosing spondylitis: a open-label, randomized, and controlled trial. *Rheumatol Int.* 2014;34(9):1195–1202. doi:10.1007/s00296-014-2959-5
112. Vallejo R, Benyamin RM, Kramer J, Stanton G, Joseph NJ. Pulsed radiofrequency denervation for the treatment of sacroiliac joint syndrome. *Pain Med.* 2006;7(5):429–434. doi:10.1111/j.1526-4637.2006.00143.x
113. Whang PG, Patel V, Duhon B, et al. Minimally invasive SI joint fusion procedures for chronic SI joint pain: systematic review and meta-analysis of safety and efficacy. *Int J Spine Surg.* 2023;17(6):794–808. doi:10.14444/8543
114. Al-Khayer A, Hegarty J, Hahn D, Grevitt MP. Percutaneous sacroiliac joint arthrodesis: a novel technique. *J Spinal Disord Tech.* 2008;21(5):359–363. doi:10.1097/BSD.0b013e318145ab96
115. Rudolf L. Sacroiliac joint arthrodesis-MIS technique with titanium implants: report of the first 50 patients and outcomes. *Open Orthop J.* 2012;6:495–502. doi:10.2174/1874325001206010495
116. Sachs D, Capobianco R. One year successful outcomes for novel sacroiliac joint arthrodesis system. *Ann Surg Innov Res.* 2012;6(1):13. doi:10.1186/1750-1164-6-13
117. Sachs D, Capobianco R. Minimally invasive sacroiliac joint fusion: one-year outcomes in 40 patients. *Adv Orthop.* 2013;2013:536128. doi:10.1155/2013/536128
118. Cummings J, Capobianco RA. Minimally invasive sacroiliac joint fusion: one-year outcomes in 18 patients. *Ann Surg Innov Res.* 2013;7(1):12. doi:10.1186/1750-1164-7-12
119. Endres S, Ludwig E. Outcome of distraction interference arthrodesis of the sacroiliac joint for sacroiliac arthritis. *Indian J Orthop.* 2013;47(5):437–442. doi:10.4103/0019-5413.118197
120. Gaetani P, Miotti D, Rizzo A, et al. Percutaneous arthrodesis of sacro-iliac joint: a pilot study. *J Neurosurg Sci.* 2013;57(4):297–301.
121. Smith AG, Capobianco R, Cher D, et al. Open versus minimally invasive sacroiliac joint fusion: a multi-center comparison of perioperative measures and clinical outcomes. *Ann Surg Innov Res.* 2013;7(1):14. doi:10.1186/1750-1164-7-14
122. Mason LW, Chopra I, Mohanty K. The percutaneous stabilisation of the sacroiliac joint with hollow modular Anchorage screws: a prospective outcome study. *Eur Spine J.* 2013;22(10):2325–2331. doi:10.1007/s00586-013-2825-2
123. Schroeder JE, Cunningham ME, Ross T, Boachie-Adjei O. Early results of sacro-iliac joint fixation following long fusion to the sacrum in adult spine deformity. *HSS J.* 2014;10(1):30–35. doi:10.1007/s11420-013-9374-4

124. Sachs D, Capobianco R, Cher D, et al. One-year outcomes after minimally invasive sacroiliac joint fusion with a series of triangular implants: a multicenter, patient-level analysis. *Med Devices*. 2014;7:299–304. doi:10.2147/MDER.S56491
125. Ledonio CG, Polly DW, Swiontkowski MF, Cummings JT. Comparative effectiveness of open versus minimally invasive sacroiliac joint fusion. *Med Devices*. 2014;7:187–193. doi:10.2147/MDER.S60370
126. Rudolf L, Capobianco R. Five-year clinical and radiographic outcomes after minimally invasive sacroiliac joint fusion using triangular implants. *Open Orthop J*. 2014;8:375–383. doi:10.2174/1874325001408010375
127. Kube RA, Muir JM. Sacroiliac joint fusion: one year clinical and radiographic results following minimally invasive sacroiliac joint fusion surgery. *Open Orthop J*. 2016;10:679–689. doi:10.2174/1874325001610010679
128. Sachs D, Kovalsky D, Redmond A, et al. Durable intermediate-to long-term outcomes after minimally invasive transiliac sacroiliac joint fusion using triangular titanium implants. *Med Devices*. 2016;9:213–222. doi:10.2147/MDER.S109276
129. Araghi A, Woodruff R, Colle K, et al. Pain and opioid use outcomes following minimally invasive sacroiliac joint fusion with decortication and bone grafting: the evolution clinical trial. *Open Orthop J*. 2017;11:1440–1448. doi:10.2174/1874325001711011440
130. Kancherla VK, McGowan SM, Audley BN, Sokunbi G, Puccio ST. Patient reported outcomes from sacroiliac joint fusion. *Asian Spine Journal*. 2017;11(1):120–126. doi:10.4184/asj.2017.11.1.120
131. Rappoport LH, Luna IY, Joshua G. Minimally invasive sacroiliac joint fusion using a novel hydroxyapatite-coated screw: preliminary 1-year clinical and radiographic results of a 2-year prospective study. *World Neurosurg*. 2017;101:493–497. doi:10.1016/j.wneu.2017.02.046
132. Bornemann R, Roessler PP, Strauss AC, et al. Two-year clinical results of patients with sacroiliac joint syndrome treated by arthrodesis using a triangular implant system. *Technol Health Care*. 2017;25(2):319–325. doi:10.3233/THC-161272
133. Vanaclocha V, Herrera JM, Sáiz-Sapena N, Rivera-Paz M, Verdú-López F. Minimally invasive sacroiliac joint fusion, radiofrequency denervation, and conservative management for sacroiliac joint pain: 6-year comparative case series. *Neurosurgery*. 2018;82(1):48–55. doi:10.1093/neuros/nyx185
134. Cross WW, Delbridge A, Hales D, Fielding LC. Minimally invasive sacroiliac joint fusion: 2-year radiographic and clinical outcomes with a principles-based SIJ fusion system. *Open Orthop J*. 2018;12:7–16. doi:10.2174/1874325001812010007
135. Rajpal S, Burneikiene S. Minimally invasive sacroiliac joint fusion with cylindrical threaded implants using intraoperative stereotactic navigation. *World Neurosurg*. 2019;122:e1588–e1591. doi:10.1016/j.wneu.2018.11.116
136. Darr E, Meyer SC, Whang PG, et al. Long-term prospective outcomes after minimally invasive trans-iliac sacroiliac joint fusion using triangular titanium implants. *Med Devices*. 2018;11:113–121. doi:10.2147/MDER.S160989
137. Rainov NG, Schneiderhan R, Heidecke V. Triangular titanium implants for sacroiliac joint fusion. *Eur Spine J*. 2019;28(4):727–734. doi:10.1007/s00586-018-5860-1
138. Cleveland AW, Nhan DT, Akiyama M, Kleck CJ, Noshchenko A, Patel VV. Mini-open sacroiliac joint fusion with direct bone grafting and minimally invasive fixation using intraoperative navigation. *J Spine Surg*. 2019;5(1):31–37. doi:10.21037/jss.2019.01.04
139. Dengler J, Kools D, Pflugmacher R, et al. Randomized trial of sacroiliac joint arthrodesis compared with conservative management for chronic low back pain attributed to the sacroiliac joint. *J Bone Joint Surg Am*. 2019;101(5):400–411. doi:10.2106/JBJS.18.00022
140. Whang PG, Darr E, Meyer SC, et al. Long-term prospective clinical and radiographic outcomes after minimally invasive lateral transiliac sacroiliac joint fusion using triangular titanium implants. *Med Devices*. 2019;12:411–422. doi:10.2147/MDER.S219862
141. Patel V, Kovalsky D, Meyer SC, et al. Prospective trial of sacroiliac joint fusion using 3D-printed triangular titanium implants. *Med Devices*. 2020;13:173–182. doi:10.2147/MDER.S253741
142. Schmidt G, Bologna M, Schorr R. Patient reported clinical outcomes of minimally invasive sacroiliac joint arthrodesis. *Orthop Surg*. 2021;13(1):71–76. doi:10.1111/os.12832
143. Abbasi H, Storlie N, Rusten M. Perioperative outcomes of minimally invasive sacroiliac joint fusion using hollow screws through a lateral approach: a single surgeon retrospective cohort study. *Cureus*. 2021;13(7):e16517. doi:10.7759/cureus.16517
144. Patel V, Kovalsky D, Meyer SC, et al. Prospective trial of sacroiliac joint fusion using 3D-printed triangular titanium implants: 24-month follow-up. *Med Devices*. 2021;14:211–216. doi:10.2147/MDER.S314828
145. Kurosawa D, Murakami E, Aizawa T, Watanabe T. Surgical outcomes of patients with sacroiliac joint pain: an analysis of patients with poor results regarding activities of daily living. *Spine Surg Relat Res*. 2021;5(3):189–195. doi:10.22603/ssrr.2020-0214
146. Kurosawa D, Murakami E, Koga H, Ozawa H. Three-year clinical outcomes after minimally invasive sacroiliac joint arthrodesis using triangular implants in Japan: a pilot study of five cases. *Spine Surg Relat Res*. 2022;6(1):71–78. doi:10.22603/ssrr.2021-0028
147. Rappoport LH, Helsper K, Shirk T. Minimally invasive sacroiliac joint fusion using a novel hydroxyapatite-coated screw: final 2-year clinical and radiographic results. *J Spine Surg*. 2021;7(2):155–161. doi:10.21037/jss-20-627
148. Novák V, Wanek T, Hrabálek L, Stejskal P. Minimally invasive sacroiliac joint stabilization. *Acta Chir Orthop Traumatol Cech*. 2021;88(1):35–38. doi:10.55095/achot2021/006
149. Wales E, Agarwal R, Mohanty K. Are hydroxyapatite-coated screws a good option for sacroiliac joint stabilization? A prospective outcome study. *World Neurosurg*. 2021;148:e164–e171. doi:10.1016/j.wneu.2020.12.104
150. Amer MH, Elnahal WA, Khaled SA, et al. Minimally invasive sacroiliac fusion, a case series, and a literature review. *SICOT J*. 2022;8:42. doi:10.1051/sicotj/2022042
151. Kasapovic A, Ali T, Jaenisch M, et al. Minimally invasive arthrodesis of the sacroiliac joint (SIJ). *Oper Orthop Traumatol*. 2022;34(2):98–108. doi:10.1007/s00064-021-00738-3
152. Kasapovic A, Schwetje D, Ali T, et al. First clinical results of a novel minimally-invasive fusion system for the sacroiliac joint. *Technol Health Care*. 2022;30(5):1139–1145. doi:10.3233/THC-213348
153. Chaves JPG, Maalouly J, Choi JYS. Clinical results following robotic navigation guidance for sacroiliac joint fusion in 36 patients. *Neurosurg Focus*. 2022;52(1):E6. doi:10.3171/2021.10.FOCUS21523
154. Hermans SMM, Knoef RJH, Schuermans VNE, et al. Double-center observational study of minimally invasive sacroiliac joint fusion for sacroiliac joint dysfunction: one-year results. *J Orthop Surg Res*. 2022;17(1):570. doi:10.1186/s13018-022-03466-x
155. Kucharzyk D, Colle K, Boone C, Araghi A. Clinical outcomes following minimally invasive sacroiliac joint fusion with decortication: the evolution clinical study. *Int J Spine Surg*. 2022;16(1):168–175. doi:10.14444/8185

156. Lynch PJ, Tubic G, Foster JM, Puri S, Burnette CA, Block JE. Minimally invasive inferior intra-articular sacroiliac joint fusion: successful application of osseous stabilization using allograft bone. *Orthop Res Rev.* 2022;14:429–435. doi:10.2147/ORR.S387104
157. Sarkar M, Maalouly J, Ruparel S, Choi J. Sacroiliac joint fusion: fusion rates and clinical improvement using minimally invasive approach and intraoperative navigation and robotic guidance. *Asian Spine J.* 2022;16(6):882–889. doi:10.31616/asj.2021.0058
158. Sayed D, Khatri N, Rupp A, et al. Salvage of failed lateral sacroiliac joint fusion with a novel posterior sacroiliac fusion device: diagnostic approach, surgical technique, and multicenter case series. *J Pain Res.* 2022;15:1411–1420. doi:10.2147/JPR.S357076
159. Soliman O, Pflugmacher R, Koch EM, et al. One-year results of minimally invasive fusion surgery of the sacroiliac joint as an alternative treatment after failed endoscopic thermal coagulation. *Technol Health Care.* 2022;30(5):1125–1138. doi:10.3233/THC-213183
160. Wessell N, Wolverson E, Ross P, Akiyama M, Lindley E, Patel V. Opioid prescription monitoring in preoperative and postoperative sacroiliac joint fusion patients. *Internat J Spin Surg.* 2022;16(3):498–504. doi:10.14444/8240
161. Wessell JE, Saway BF, Wolgamott L, et al. Sacroiliac Joint Fusion-A Shift Toward Variant Anatomy and Clinical Implications. *World Neurosurg.* 2022;168:e460–e470. doi:10.1016/j.wneu.2022.10.001
162. Wang TY, Bergin SM, Murphy KR, et al. Sacroiliac joint fusion using robotic navigation: technical note and case series. *Oper Neurosurg.* 2022;23(1):1–7. doi:10.1227/ons.000000000000179
163. Anton G, Alsalahi A, Yoon EJ, et al. Fusion and patient-reported outcomes after navigated decortication and direct arthrodesis in minimally invasive sacroiliac joint fusion using cylindrical threaded implants: a case series and literature review. *Neurosurg Focus.* 2023;55(1):E2. doi:10.3171/2023.4.FOCUS23145
164. Cahueque M, Grajeda J, Ardebol J, Azmitia E. Posterior oblique technique for sacroiliac joint fusion leads to greater pain relief and similar improvement in function compared to the lateral technique: a retrospective, comparative study. *N Am Spine Soc J.* 2023;15:100259. doi:10.1016/j.xnsj.2023.100259
165. Cross WW, Tomov MN, Hung MY, Muir JM. Patient-reported outcomes and computed tomography review after minimally invasive fusion of the sacroiliac joint with aggressive joint decortication and joint compression. *Orthopedics.* 2023;1–7. doi:10.3928/01477447-20230901-04
166. Jedi F, Krysiak R, Hirsch JA, Ventura F, De Vivo E, Manfrè L. Chronic sacroiliac joint dysfunction and CT-guided percutaneous fixation: a 6-year experience. *Neuroradiology.* 2023;65(10):1527–1534. doi:10.1007/s00234-023-03171-4
167. Raikar SV, Nilles-Melchert T, Patil AA, Crum W, Pandey D. Posterior oblique approach for sacroiliac joint fusion. *Cureus.* 2023;15(1):e33502. doi:10.7759/cureus.33502
168. Sayed D, Amirdelfan K, Hunter C, Raji OR. Posterior intra-articular fixation stabilizes both primary and secondary sacroiliac joints: a cadaveric study and comparison to lateral trans-articular fixation literature. *J Orthop Surg Res.* 2023;18(1):406. doi:10.1186/s13018-023-03886-3
169. Heiney J, Capobianco R, Cher D. A systematic review of minimally invasive sacroiliac joint fusion utilizing a lateral transarticular technique. *Int J Spine Surg.* 2015;9. doi:10.14444/2040
170. Sayed D, Grider J, Strand N, et al. The American Society of Pain and Neuroscience (ASPEN) evidence-based clinical guideline of interventional treatments for low back pain. *J Pain Res.* 2022;15:3729–3832. doi:10.2147/JPR.S386879

Journal of Pain Research

Dovepress

Publish your work in this journal

The Journal of Pain Research is an international, peer reviewed, open access, online journal that welcomes laboratory and clinical findings in the fields of pain research and the prevention and management of pain. Original research, reviews, symposium reports, hypothesis formation and commentaries are all considered for publication. The manuscript management system is completely online and includes a very quick and fair peer-review system, which is all easy to use. Visit <http://www.dovepress.com/testimonials.php> to read real quotes from published authors.

Submit your manuscript here: <https://www.dovepress.com/journal-of-pain-research-journal>