

Single Case

A Case of Overlapping Clinical Features of Idiopathic Granulomatous Mastitis, Hidradenitis Suppurativa, and Pyoderma Gangrenosum Successfully Treated with Adalimumab

Vesna Breznik Pij Bogomir Marko

Department of Dermatovenerology, University Medical Centre Maribor, Maribor, Slovenia

Keywords

Idiopathic granulomatous mastitis · Pyoderma gangrenosum · Hidradenitis suppurativa · Autoinflammation · Adalimumab

Abstract

A 36-year-old woman with a 6-month history of painful unilateral mammary nodules and abscesses was initially treated by gynecologists under the diagnosis of idiopathic granulomatous mastitis (IGM). IGM is an entity that has not been described in classical dermatological textbooks and is considered a rare inflammatory breast disease assumingly associated with trauma, infection, or autoimmune system manifestations. In this patient, the lesions were refractory to conventional treatment of IGM comprising of surgical incisions, systemic antibiotics, dexamethasone, and methotrexate. At the initial visit to the dermatology department, a working diagnosis of localized hidradenitis suppurativa (HS) of breast was established, and treatment with systemic doxycycline was initiated. After the diagnostic incisional biopsy, the inflamed nodule deteriorated into a painful ulceration, implying a pathergy phenomenon. Histopathological features were consistent with the granulomatous type of pyoderma gangrenosum (PG). Treatment with systemic methylprednisolone and mycophenolate mofetil was unsuccessful. Subsequently, the patient developed nodules in the inguinal and axillary areas, typical for HS. Finally, adalimumab treatment resulted in the complete resolution of all lesions without relapse even after the biologic therapy was discontinued. Although in this case, IGM was not confirmed histopathologically, we noted several etiopathological and therapeutic similarities between IGM, PG, and HS and summarized them in a unique table. Further observations are needed to ascertain the potential associations among the three entities.

© 2022 The Author(s).
Published by S. Karger AG, Basel

Correspondence to:
Vesna Breznik, vesna.breznik@ukc-mb.si

Background

Idiopathic granulomatous mastitis (IGM) is a rare inflammatory breast disease that affects mostly women of childbearing age with a history of pregnancy [1]. It usually presents with a unilateral painful breast mass and possible abscess, sinus, fistula, and ulcer formation [2, 3], thus sharing clinical similarities with hidradenitis suppurativa (HS) and pyoderma gangrenosum (PG) [4, 5]. Clinically, it can mimic infectious and noninfectious mastitis as well as breast carcinoma; therefore, histopathological confirmation and exclusion of differential diagnoses are mandatory [1]. The etiopathogenesis of IGM is still hypothetical and comprises inflammation as the result of a reaction to trauma, infectious stimuli (*Corynebacterium kroppenstedtii*), antidepressant drugs [6, 7], and hormonal processes (hyperprolactinemia). IGM has also been occasionally associated with immune system manifestations such as erythema nodosum, arthritis [8–10], episcleritis, and HS [11], serving as additional evidence that IGM might be of inflammatory origin, similar to PG and HS. Currently, there is no generally accepted treatment for IGM [7], which makes the management of patients with IGM challenging.

Case Report

A 36-year-old woman presented with a 6-month history of recurrent painful nodules and abscesses in the left breast with occasional fever, chills, and ipsilateral axillary lymphadenopathy. Her previous history was significant for an episode of generalized furunculosis 10 years ago, childbirths 7 and 2 years ago, chronic left nipple retraction, and panic disorder, for which she was treated with paroxetine and alprazolam. She was allergic to penicillin and was a nonsmoker. Her family history was unremarkable.

In gynecology clinics, serial ultrasound (US) examinations of the left breast showed heterogeneous tissue with fluid collections. Magnetic resonance imaging with contrast was suggestive of a large expansive process with necrosis and abscess in the left breast. US-guided aspirations of pus and biptic specimens of the left breast and axillary lymphadenopathy were sent for cytological and histopathological examinations, which revealed a mixed acute and chronic inflammation of breast tissue (lobulitis) and a reactive lymphadenitis of the left axilla, whereas carcinoma of the left breast was excluded. *Staphylococcus aureus* and *C. kroppenstedtii* were isolated from aspirations of pus. Serum prolactin, chest X-ray, and abdominal US were unremarkable. A diagnosis of IGM, related to *C. kroppenstedtii* infection, was established. She was unsuccessfully treated with pus aspirations, surgical incisions, and systemic therapy with antibiotics (empiric azithromycin and clindamycin + ciprofloxacin and targeted vancomycin and teicoplanin), oral dexamethasone 8 mg daily (1 month), and methotrexate 10 mg weekly in combination with folic acid 5 mg (2.5 months). During that therapy, she experienced azithromycin-related skin rash, weight gain with truncal obesity, moon face, and adrenal insufficiency, for which she was prescribed supplementation with hydrocortisone (features of iatrogenic Cushing syndrome).

At her first visit to the dermatology department, she presented with an inverted mamilla and painful nodules and fistulas on the left breast (shown in Fig. 1a). Blood examinations revealed elevated levels of sedimentation 40 mm/h (normal <15) and C-reactive protein (CRP) 60 mg/L (normal range <3). Levels of serum antinuclear antibodies, antineutrophil cytoplasmic antibodies, rheumatoid factor, angiotensin-converting enzyme, calcium, Quantiferon test, hepatitis B and C serology, and chest X-ray were within normal ranges. After a diagnostic incisional biopsy of the left breast, a painful ulceration developed near the incision, indicating a pathergy phenomenon (shown in Fig. 1b). Biptic specimens were sent for bacterial, mycobacterial, fungal, and actinomycetal stains and cultures, which were all

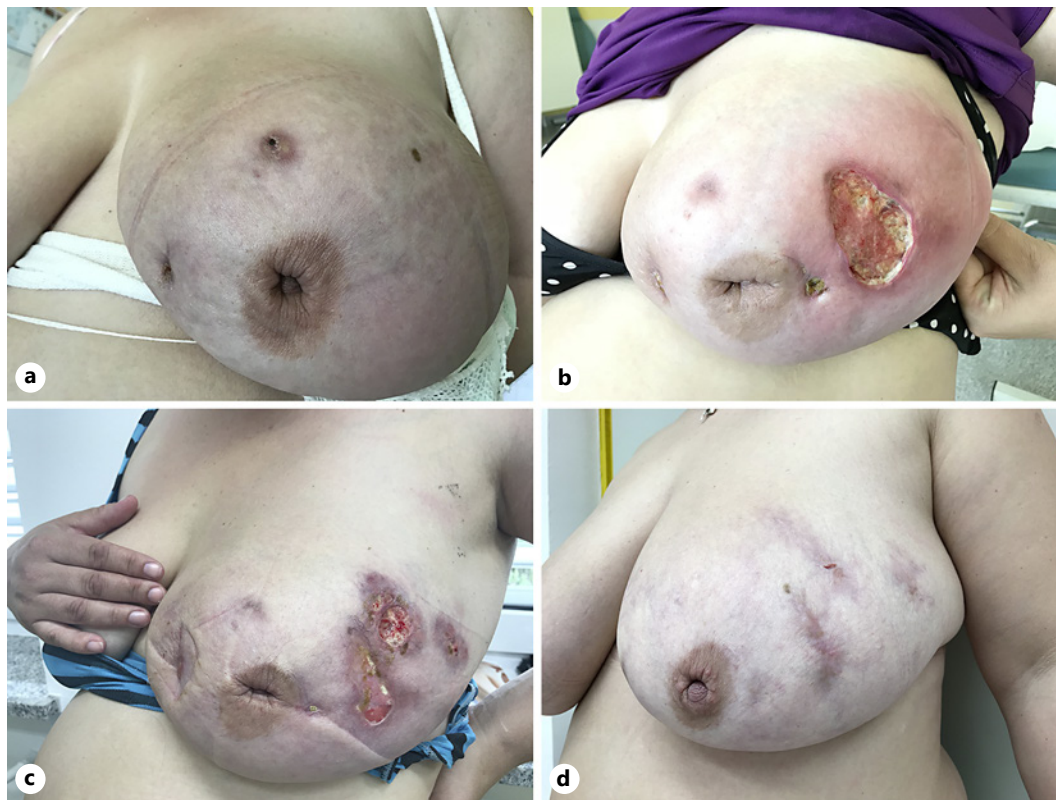

Fig. 1. **a** Painful nodules and fistulas with purulent secretion on the left breast with chronic nipple retraction. **b** Development of a painful ulceration nearby the incisional biopsy (possible pathergy phenomenon). **c** Appearance of new subcutaneous nodules, abscesses, and ulcers during treatment with doxycycline, methylprednisolone, and mycophenolate mofetil. **d** Prompt and complete healing of the breast ulcers and resolution of abscesses and nodules after treatment with adalimumab.

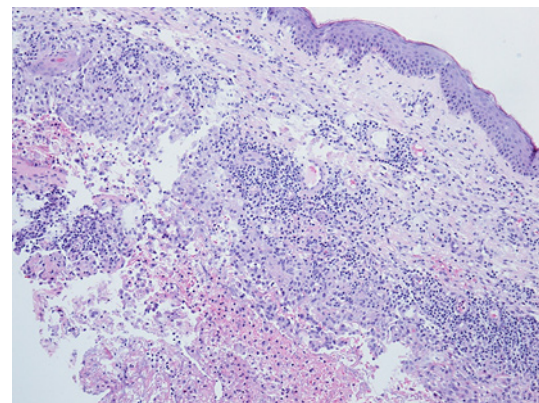


Fig. 2. Non-caseating granulomas with multinucleated giant cells, epithelioid histiocytes, numerous plasma cells, lymphocytes, and infrequent eosinophils. Neutrophils in groups are visible in the central parts of granulomas. Histological features are consistent with the granulomatous type of PG.

negative. Histopathological examination was consistent with the granulomatous type of PG. However, mammary glandular tissue was not captured, and consequently, the diagnosis of IGM could neither be confirmed nor excluded (presented in Fig. 2). In line with the initial working diagnosis of mammary HS, she was prescribed oral doxycycline 100 mg daily. As the diagnosis of PG was established histopathologically, oral methylprednisolone (initial dose of 48 mg daily, which is equivalent to 0.5 mg prednisone/kg daily, with slow tapering) was

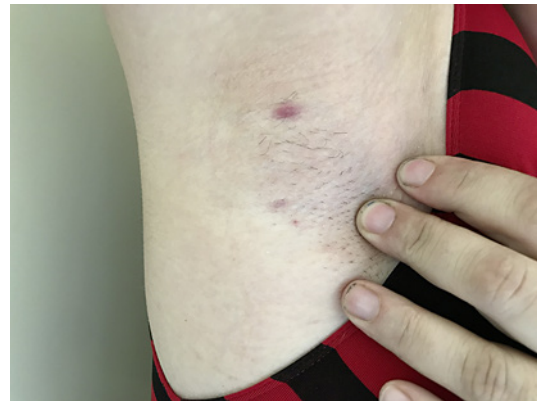


Fig. 3. Painful nodules in inguinal and axillary regions, typical of HS.

additionally prescribed and topical therapy with betamethasone/gentamycin cream and silicone foam wound dressings was initiated. Unfortunately, the systemic corticosteroid treatment led to a deterioration of the patients' panic disorder, additional weight gain, and hypertension. After 2 months, new abscesses and ulcers appeared continually (presented in Fig. 1c); therefore, mycophenolate mofetil (1,000 mg b.i.d.) was added to methylprednisolone, while doxycycline was discontinued. However, the treatment proved to be ineffective after 3 months. Above all, the patient noticed small, painful inguinal and axillary nodules, typical of HS (presented in Fig. 3). Considering that in addition to suppurative lesions on the breast (possible mammary HS) and a history of previous furunculosis (possible unrecognized HS), we took the next step in the treatment ladder for HS and introduced adalimumab, a tumor necrosis factor- α (TNF- α) inhibitor (80 mg s.c./2 weeks), while mycophenolate mofetil and methylprednisolone were discontinued and supplementary treatment with hydrocortisone was reintroduced due to known adrenal insufficiency. Remarkably, we observed complete resolution of all breast lesions within 3 months, more gradual resolution of the axillary and inguinal nodules (presented in Fig. 1d), and a sustained reduction in laboratory inflammatory parameters (CRP 3–6, sedimentation 10–32). During treatment with adalimumab, the patient reported no adverse events. Gradually, her panic disorder and hypertension improved, and her adrenal gland function recovered. Since the patient was planning another pregnancy and no relapse was observed after 14 months, adalimumab was discontinued. She experienced no relapse during 18 months of follow-up without therapy.

Discussion

The presented patient was initially treated for suspected unilateral IGM, a gynecological entity, which has not been described in classical dermatological textbooks. Conventional treatment of IGM with surgical drainage, empirical and targeted systemic antibiotics, corticosteroids, and methotrexate [1, 12] was unsuccessful and, above all, resulted in an iatrogenic Cushing syndrome. On the patients' first visit to the dermatology department, a working diagnosis of a localized form of HS was established based on painful nodules and abscesses on the left breast. However, the unusual clinical presentation required the exclusion of differential diagnoses, including various infectious and inflammatory processes, as well as inflammatory carcinoma [1, 13]. Following the diagnostic incisional biopsy, an ulcer with heavy suppuration evolved nearby. This implied a pathergy phenomenon, which is one of the minor diagnostic criteria of PG [5]. Based on histopathological examination, a diagnosis of granulomatous PG was confirmed. Unfortunately, the mammary tissue was not captured in the biopsy,

and consequently, the diagnosis of IGM could neither be histopathologically confirmed nor excluded. Non-caseating granulomas can be indicative of IGM [1], sarcoidosis, granulomatosis with polyangiitis, and various infections [14, 15], which were all excluded in this patient. Moreover, non-caseating granulomas can also be found in long-lasting severe HS and PG [4, 5]. In the literature, multiple cases of concurrent HS and PG (syndromic HS) have been described [16, 17], with HS commonly preceding PG lesions by several months to years [18]. Several autoinflammatory arthritic-pyodermic syndromes like PG, acne, and HS (PASH) and PG, acne, pyogenic arthritis, and HS (PAPASH) have been recognized, some of them manifesting systemic symptoms of high fever and joint pain along with increased inflammatory activity in the blood and/or skin such as CRP, ESR, TNF- α , and interleukin-1 [19–21]. Moreover, a case of overlapping IGM and HS has been reported [22], in which the authors suggested that IGM might be a localized form of HS and that the link between these two entities may have been missed since IGM and HS patients are seen by gynecologists and dermatologists, respectively [22]. However, in our case, IGM was not histopathologically confirmed, and therefore, based on overall histopathological and clinical features, the overlapping of PG and HS was determined. Nevertheless, while studying the literature, several etiopathological and therapeutic similarities between IGM, PG, and HS were noted and are presented in Table 1. All three entities are more frequent in women than men, can present on the breast, and usually manifest with painful purulent lesions (pustules, abscesses) or even ulcers, frequently running a chronic recurrent course [1, 4, 5, 23]. They share histopathological features of abundant neutrophils and granulomatous inflammation, the latter being diagnostic of IGM, while in PG and HS it is present only in special variants and long-lasting lesions [1, 4, 18, 24]. Although HS, PG, and IGM are known to be associated with underlying systemic diseases such as inflammatory bowel disease, arthritis, and erythema nodosum [5, 10, 18], we have not found any of them in this patient. So far, international treatment guidelines are available only for HS [4], which is probably associated with its highest incidence and the longest recognition among the three entities [1, 25–27], thus enabling the acquisition of robust scientific evidence. Although the etiological role of bacteria within IGM and HS lesions is doubtful, prolonged systemic antimicrobial agents such as tetracyclines are considered to be the first-line treatment of HS [4] and frequently of IGM, especially in cases with isolated *C. kroppenstedtii* [15]. On the contrary, in PG, antibiotic therapy is being seldom used, with dapson reported only in a few case series [25, 28]. Systemic corticosteroids are the most common treatment modality of PG [28] and according to some authors, also of IGM [12, 14], while in HS, they are considered second-line therapy of flares [4]. Classic immunosuppressive drugs, particularly cyclosporin A and methotrexate, are usually considered a second-line treatment of PG [25] and IGM [12] and third-line treatment of HS. Surgery (incision for drainage and wide excision) is the mainstay of therapy of HS [4], however, it is generally contraindicated in PG, being applied only in selected cases (skin grafting) after sufficient immunosuppression has been established [29]. According to some authors, surgical treatment should also be avoided in IGM due to the high rate of surgical complications, including recurrences and fistulas, while others consider it as an efficient treatment option with a low recurrence rate [1, 15].

In this patient, the diagnosis of HS was finally stated, based on the appearance of small nodular axillary and inguinal lesions in conjunction with suppurative breast lesions and a history of generalized furunculosis (possible unrecognized HS). Due to the exhausted conventional treatment of HS and considering the known allergy to clindamycin, a guideline-based treatment with adalimumab was initiated and delivered a prompt and full recovery of breast lesions and slow resolution of axillary and inguinal nodules. Biologic drugs, mostly TNF- α inhibitors infliximab and adalimumab, proved to be efficient in several therapeutically resistant cases of HS [4] and PG [4, 30]. Adalimumab has been reported to be effective in the treatment of PASH syndrome [31, 32] and other syndromic HS [18, 33]. Recently, a case of remission of a

Table 1. Comparison of HS, PG, and IGM

| | HS | PG | IGM |
|-------------------------------------|--|---|--|
| First description | 1854 (Verneuil) | 1916 (Brocq) | 1972 (Kessler and Wolloch) |
| Estimated incidence/year | 6.0/100.000 | 0.3–1.0/100.000 | 2.4/100.000 women |
| Median age at presentation (years) | 38 | 59 | 30 |
| Incidence ratio according to gender | F > M (3:2) | F = M or F > M (76% women) | F >> M |
| Associated diseases | Inflammatory bowel disease, follicular occlusion syndrome, spondyloarthropathy, PG, obesity, hyperandrogenism | Inflammatory bowel disease, inflammatory arthritis, malignancies, IgA gammopathies | Erythema nodosum, episcleritis, inflammatory arthritis, HS, injury, history of lactation or pregnancy |
| Possible triggers | Cigarette smoke, friction/injury | Injury, drugs (tyrosine kinase inhibitors, propylthiouracil, TNF-alpha inhibitors) | Drugs (antidepressants, antipsychotics, oral contraceptives), hormones (prolactin) |
| Typical location | Intertriginous, apocrine gland bearing skin | Shin, breast, surgical scar (any body site) | Breast |
| Typical clinical presentation | Nodule, abscess, sinus tract, scar, fistula, suppuration | Pustule, vesicle/bulka, ulceration with violaceous undermined border | Erythema, nodule, abscess, fistula, ulceration, nipple retraction |
| Number of lesions | Multiple | Solitary or multiple | Solitary or multiple |
| Injury as a possible trigger | Yes (friction, shaving) | Yes | Yes |
| Microbes as a possible trigger | Yes – contaminants of the normal skin flora or superinfection (e.g., staphylococci, corynebacteria, propionibacteria) | No | Yes – contaminants or true infection (e.g., corynebacteria) |
| Etiology | AI, inflammatory, metabolic, hormonal, obesity, smoking | AI, inflammatory, reactive, paraneoplastic | AI, infectious, hormonal, metabolic |
| Pain | Yes | Yes | Yes |
| Course and prognosis | Chronic relapsing and remitting | Acute, may become chronic or recurring | Self-limiting or chronic relapsing and remitting |
| Diagnosis | Clinical | Clinical and histopathological | Histopathological |
| Histology | Seldom performed Follicular plugging and cysts, psoriasiform hyperplasia, neutrophilic abscesses, macrophages, sinus tracts. In severe and long-standing cases non-necrotic granuloma formation, lymphocytes, plasma cells, and giant cells | Supportive Intense neutrophilic infiltrate, neutrophilic pustules, abscess Possible non-necrotic granulomas in lesions of long duration | Diagnostic Non-necrotic granulomas, multinucleated giant cells, epithelioid histiocytes, plasma cells, lymphocytes. Possible lobulocentric inflammation with cystic spaces, rimmed by neutrophils |
| International treatment guidelines | Yes | No | No |
| Topical treatment | C lindamycin 1% solution, resorcinol 15%, i.i. corticosteroid | Corticosteroid, calcineurin inhibitors, wound care, compression i.i. corticosteroid | Wound care if needed |
| Conventional systemic treatment | Tetracycline, clindamycin + rifampicin, corticosteroids, retinoids | Corticosteroids, cyclosporine A, methotrexate, mycophenolate mofetil, azathioprine, colchicine, sulphasalazine, dapsone, thalidomide, intravenous immunoglobulins | Amoxicillin/clavulanic acid, doxycycline, corticosteroids, methotrexate, colchicine, hydroxychloroquine |
| Biologic treatment (reported) | Adalimumab, infliximab, etanercept, ustekinumab | Infliximab, adalimumab, etanercept, ustekinumab, anakinra | Infliximab, adalimumab |
| Surgical treatment | Incision and drainage, wide excision of sinus tracts, and scars | Debridement and skin grafting with negative pressure therapy performed under immunosuppression | Pus aspiration, incision, and drainage, total excision |

5-year-lasting IGM after therapy with adalimumab has been published [34]. The whole presentation of our patient, with lesions typical of PG and HS, occasional fever, reactive lymphadenopathy, elevated laboratory inflammatory parameters, negative rheumatic disease serology, unresponsiveness to conventional immunosuppressive therapy, and a perfect response to systemic treatment with adalimumab, assign toward a putative autoinflammatory syndrome. Unfortunately, we were not able to perform a more specific evaluation of proinflammatory cytokines and chemokines in skin samples and blood or genetic tests for mutations in autoinflammatory genes [20, 21], which might support our hypothesis of the systemic autoinflammatory process. Another limitation of this report is a single case study with this specific constellation of symptoms and skin lesions. Finally, adalimumab was far better tolerated by our patient, compared to previous conventional therapies, causing various morbidities. Therefore, it is important for the gynecologists and infectious diseases specialists, who frequently deal with chronic suppurative mammary lesions, to consider PG and HS in the differential diagnosis to prevent prolonged, ineffective, and potentially harmful conventional treatment.

Conclusion

We presented a case of overlapping clinical and histopathological features of PG and HS, which promptly responded to systemic treatment with adalimumab. Although in this patient we were not able to confirm IGM histopathologically, we found several etiopathological and therapeutic similarities between the three entities. Further observations are needed in order to ascertain the potential associations among the IGM, HS, and PG. Our case also illustrates, that management of chronic suppurative mastitis should include a dermatovenerology specialist, due to specific knowledge of inflammatory skin diseases, including contemporary treatment with potentially more efficient and safe biologic agents.

Acknowledgment

We are grateful to Vesna Jurčič, pathology specialist from the Institute of Pathology, Faculty of Medicine at the University of Ljubljana, Ljubljana, Slovenia, for performing the pathological examination and supplying the microscopic pictures.

Statement of Ethics

Written informed consent was obtained from the patient for publication of the details of this medical case and any accompanying images. This case complied with the Declaration of Helsinki. Ethical approval was not required for this study in accordance with local/national guidelines.

Conflict of Interest Statement

The authors have no conflicts of interest to declare.

Funding Sources

No funding was received.

Author Contributions

Vesna Breznik was in contact with the patient, involved in photography, obtaining a written consent, and manuscript writing. Pij Bogomir Marko was supervising of the study. All the authors contributed to the diagnosis of the patient, literature review, and evaluation of the manuscript.

Data Availability Statement

All patient data are available in this article. Should you require further information, please contact the corresponding author.

References

- 1 Wolfrum A, Kümmel S, Theuerkauf I, Pelz E, Reinisch M. Granulomatous mastitis: a therapeutic and diagnostic challenge. *Breast Care*. 2018;13(6):413–8.
- 2 Wilson JP, Massoll N, Marshall J, Foss RM, Copeland EM, Grobmyer SR. Idiopathic granulomatous mastitis: in search of a therapeutic paradigm. *Am Surg*. 2007;73(8):798–802.
- 3 Al-Khaffaf B, Knox F, Bundred NJ. Idiopathic granulomatous mastitis: a 25-year experience. *J Am Coll Surg*. 2008;206(2):269–73.
- 4 Zouboulis CC, Desai N, Emtestam L, Hunger RE, Ioannides D, Juhász I, et al. European S1 guideline for the treatment of hidradenitis suppurativa/acne inversa. *J Eur Acad Dermatol Venereol*. 2015;29(4):619–44.
- 5 George C, Deroide F, Rustin M. Pyoderma gangrenosum: a guide to diagnosis and management. *Clin Med*. 2019;19(3):224–8.
- 6 Johnstone KJ, Robson J, Cherian SG, Wan Sai Cheong J, Kerr K, Bligh JF. Cystic neutrophilic granulomatous mastitis associated with *Corynebacterium* including *Corynebacterium kroppenstedtii*. *Pathology*. 2017;49(4):405–12.
- 7 Yukawa M, Watatani M, Isono S, Fujiwara Y, Tsujie M, Kitani K, et al. Management of granulomatous mastitis: a series of 13 patients who were evaluated for treatment without corticosteroids. *Int Surg*. 2015;100(5):774–82.
- 8 Nakamura Y, Yamaguchi M, Nakamura A, Muto M. Tender, red nodules and arthralgia in a young woman with mastitis. *Clin Exp Dermatol*. 2014;39(3):410–2.
- 9 Olfatbakhsh A, Beheshtian T, Djavid GE. Granulomatous mastitis, erythema nodosum, and oligoarthritis in a pregnant woman. *Breast J*. 2008;14(6):588–90.
- 10 Salesi M, Karimifar M, Salimi F, Mahzouni P. A case of granulomatous mastitis with erythema nodosum and arthritis. *Rheumatol Int*. 2011;31(8):1093–5.
- 11 Jacquin-Porretaz C, Devalland C, Delapparent T, Nardin C, Dupond AS. [Idiopathic granulomatous mastitis associated with erythema nodosum]. *Ann Dermatol Venereol*. 2019;146(8–9):571–6.
- 12 Akbulut S, Yilmaz D, Bakir S. Methotrexate in the management of idiopathic granulomatous mastitis: review of 108 published cases and report of four cases. *Breast J*. 2011;17(6):661–8.
- 13 Tuli R, O'Hara BJ, Hines J, Rosenberg AL. Idiopathic granulomatous mastitis masquerading as carcinoma of the breast: a case report and review of the literature. *Int Semin Surg Oncol*. 2007;4:21.
- 14 Mathew M, Siwawa P, Misra S. Idiopathic granulomatous mastitis: an inflammatory breast condition with review of the literature. *BMJ Case Rep*. 2015;2015:bcr2014208086.
- 15 Wu JM, Turashvili G. Cystic neutrophilic granulomatous mastitis: an update. *J Clin Pathol*. 2020;73(8):445–53.
- 16 Tannenbaum R, Strunk A, Garg A. Overall and subgroup prevalence of pyoderma gangrenosum among patients with hidradenitis suppurativa: a population based analysis in the United States. *J Am Acad Dermatol*. 2019;80(6):1533–7.
- 17 Hsiao JL, Antaya RJ, Berger T, Maurer T, Shinkai K, Leslie KS. Hidradenitis suppurativa and concomitant pyoderma gangrenosum: a case series and literature review. *Arch Dermatol*. 2010;146(11):1265–70.
- 18 Groleau PF, Grossberg AL, Gaspari AA. Hidradenitis suppurativa and concomitant pyoderma gangrenosum treated with infliximab. *Cutis*. 2015;95(6):337–42.
- 19 Scheinfeld N. Diseases associated with hidradenitis suppurativa: part 2 of a series on hidradenitis. *Dermatol Online J*. 2013;19(6):18558.
- 20 Marzano AV, Damiani G, Ceccherini I, Berti E, Gattorno M, Cugno M. Autoinflammation in pyoderma gangrenosum and its syndromic form (pyoderma gangrenosum, acne and suppurative hidradenitis). *Br J Dermatol*. 2017;176(6):1588–98.
- 21 Vinkel C, Thomsen SF. Autoinflammatory syndromes associated with hidradenitis suppurativa and/or acne. *Int J Dermatol*. 2017;56(8):811–8.

- 22 Join-Lambert O, Fraitag S, Ribadeau-Dumas F, Leguern AS, Behillil S, Del Castillo FJ, et al. Is granulomatous mastitis a localized form of hidradenitis suppurativa? *Eur J Dermatol*. 2009;19(5):513–4.
- 23 Miller IM, McAndrew RJ, Hamzavi I. Prevalence, risk factors, and comorbidities of hidradenitis suppurativa. *Dermatol Clin*. 2016;34(1):7–16.
- 24 D'Epiro S, Salvi M, Mattozzi C, Giancristoforo S, Faina V, Macaluso L, et al. Facial superficial granulomatous pyoderma. *Int Wound J*. 2015;12(6):737–8.
- 25 Quist SR, Kraas L. Treatment options for pyoderma gangrenosum. *J Dtsch Dermatol Ges*. 2017;15(1):34–40.
- 26 Kessler E, Wolloch Y. Granulomatous mastitis: a lesion clinically simulating carcinoma. *Am J Clin Pathol*. 1972;58(6):642–6.
- 27 Vazquez BG, Alikhan A, Weaver AL, Wetter DA, Davis MD. Incidence of hidradenitis suppurativa and associated factors: a population-based study of Olmsted County, Minnesota. *J Invest Dermatol*. 2013;133(1):97–103.
- 28 Reichrath J, Bens G, Bonowitz A, Tilgen W. Treatment recommendations for pyoderma gangrenosum: an evidence-based review of the literature based on more than 350 patients. *J Am Acad Dermatol*. 2005;53(2):273–83.
- 29 Romanelli M, Janowska A, Oranges T, Dini V. Skin grafting in pyoderma gangrenosum. *Eplasty*. 2018;18:ic11.
- 30 Rousset L, de Masson A, Begon E, Villani A, Battistella M, Rybojad M, et al. Tumor necrosis factor- α inhibitors for the treatment of pyoderma gangrenosum not associated with inflammatory bowel diseases: a multicenter retrospective study. *J Am Acad Dermatol*. 2019;80(4):1141–3.
- 31 Saint-Georges V, Peternel S, Kaštelan M, Brajac I. Tumor necrosis factor antagonists in the treatment of pyoderma gangrenosum, acne, and suppurative hidradenitis (PASH) syndrome. *Acta Dermatovenerol Croat*. 2018;26(2):173–8.
- 32 Fattore D, Pistone G, Bongiorno MR. A case of pyoderma gangrenosum, acne, hidradenitis suppurativa (PASH) syndrome associated with diabetes mellitus type 1 treated with adalimumab. *G Ital Dermatol Venereol*. 2019;154(2):218–20.
- 33 De Wet J, Jordaan HF, Kannenberg SM, Tod B, Glanzmann B, Visser WI. Pyoderma gangrenosum, acne, and suppurative hidradenitis syndrome in end-stage renal disease successfully treated with adalimumab. *Dermatol Online J*. 2017;23(12):6.
- 34 Cadena-Semanate RE, Estrella-Tapia LF, Contreras-Yametti FI, Contreras-Yametti JE, Salazar-Molina RD. Adalimumab in a patient with refractory idiopathic granulomatous mastitis: a case report. *Breast J*. 2021;27(1):99–102.