

RESEARCH ARTICLE

Open Access



Risk factors of neurological deficit and pulmonary cement embolism after percutaneous vertebroplasty

Ming-Kai Hsieh^{1,2,3*} , Fu-Cheng Kao^{1,2,3}, Ping-Yeh Chiu^{1,2,3}, Lih-Huei Chen^{1,2,3}, Chia-Wei Yu^{1,2,3}, Chi-Chien Niu^{1,2,3}, Po-Liang Lai^{1,2,3} and Tsung-Ting Tsai^{1,2,3}

Abstract

Background: The risk factors, incidence, and clinical management of pulmonary cement embolism and neurological deficit during percutaneous vertebroplasty (PVP) were evaluated.

Methods: Three thousand one hundred and seventy-five patients with symptomatic osteoporotic vertebral compression fractures (OVCFs) treated with PVP were retrospectively reviewed in a single institution. Clinical parameters such as age, gender, number of fractures, and time from fracture to vertebroplasty were recorded at the time of surgery. Image and surgical parameters including the amount of cement, the vertebral level, uni- or bipedicle surgical approach, and leakage pattern were recorded.

Results: Type-C leakage, including paraspinal (25%), intradiscal (26%), and posterior (0.7%) leakage, was more common than type-B (11.4%) and type-S leaks (4.9%). Cement leakage into the spinal canal (type-C posterior) occurred in 26 patients (0.7%), and four patients needed surgical decompression. Three in nine patients with leakage into thoracic spine needed decompressive surgery, but only one of 17 patients into lumbar spine needed surgery ($p < 0.01$). Age, gender, number of fractures, and time from fracture to vertebroplasty were not risk factors of pulmonary cement embolism or neurological deficit. The risk factor of pulmonary cement embolism was higher volume of PMMA injected ($p < 0.001$) and risk factor of neurological deficit was type-C posterior cement leakage into thoracic spine. The incidence of pulmonary cement embolism was significantly high in the volume of PMMA injected (PMMA injection < 3.5 cc: 0%; 3.5–7.0 cc: 0.11%; > 7.0 cc: 0.9%; $p < 0.01$) which needed postoperative oxygen support.

Conclusions: Cement leakage is relatively common but mostly of no clinical significance. Percutaneous vertebroplasty in thoracic spine and high amount of PMMA injected should be treated with caution in clinical practice.

Keywords: Bone cements, Iatrogenic disease, Adverse effects, Paresis, Pulmonary embolism

Background

With the aging of the population, the incidence of osteoporotic vertebral compression fractures (OVCFs) is increasing and is becoming a major healthcare concern [1].

Percutaneous vertebroplasty (PVP) has gained widespread acceptance and is implemented broadly, mainly as a treatment method for painful OVCFs [2–6]. Its

benefit over conservative treatment has been reported in a large and high-quality randomized clinical trial [7]. However, there are also reports that put into doubt the efficacy of vertebroplasty as a treatment for VCFs. Some studies have found that PVP had no efficacy compared with sham-operated patients [8–10]. Later reports by the same authors showed that vertebroplasty had no or limited value in long-term follow-up studies [10–12].

The complication rate of PVP is low, and has been reported to be 1.6% to 3.8% in meta-analyses [13, 14]. Severe complications of PVP are rare; they are restricted to case reports and mainly comprise sequelae of

* Correspondence: mk660628@gmail.com

¹Department of Orthopedic Surgery, Chang Gung Memorial Hospital, Taoyuan, Taiwan

²Bone and Joint Research Center, Chang Gung Memorial Hospital, Linkou, Taiwan

Full list of author information is available at the end of the article



excessive cement leakage, such as paraplegia [15], neurologic deficits [16, 17], cardiac perforation [18, 19], and even death [20].

The rate of occurrence of cement leakage itself appears to vary, with reported incidences ranging from less than 5% to more than 80% [21–24]. When assessed using computed tomography (CT) scanning, which is known to be substantially superior to intraoperative fluoroscopy or postoperative radiography for detection of cement leakage [24, 25], the incidence of leakage was found to be 63% to 87% [21–25].

PVP can also increase the risk of fractures of adjacent vertebrae [26–30]. The incidence of postoperative infections in patients undergoing PVP is low [31].

In this study, we analyzed clinically significant complications after cement leakage in 3175 patients treated with PVP for symptomatic OVCFs.

Methods

Patients

We retrospectively reviewed the records of 3175 patients treated with PVP for symptomatic OVCFs at our institution between 2001 and 2011. The average number of patients treated per year was 288 (63–381 patients per year). The Chang Gung Medical Foundation Institutional Review Board approved this study (IRB No. 103-3388B) and waived the requirement for informed consent due to the retrospective nature of the study. All patients met the following criteria: (1) focal midline back pain managed inadequately with appropriate conservative treatment, (2) back pain related to VCF location on radiography, and (3) the presence of bone marrow edema on magnetic resonance imaging (MRI), as indicated by a hypointense signal on T1-weighted images and a hyperintense signal on T2-weighted images. Exclusion criteria were active infection, neurologic deficit, pathological fractures, and uncorrected therapeutic anticoagulation.

Clinical parameters such as age, gender, and time from fracture to vertebroplasty were recorded at the time of surgery. Parameters related to imaging and technical characteristics, including the amount of bone cement injected per procedure, the vertebral level of the fracture, surgical approach (uni- or bipedicle), filling pattern, and any leakage of cement, which was classified into three types [25], as follows: B, via the basivertebral vein; S, via the segmental vein; and C, through a cortical defect, were also recorded.

Surgical technique

Percutaneous vertebroplasty was performed under local or general anesthesia with the patient in a prone position on a radiolucent table with his/her spine extended by chest and pelvic bolsters. A preoperative prophylactic single-dose antibiotic was administered to each patient,

and fluoroscopy was used throughout the procedure. A 1-cm incisional wound was made on the pedicle level of the skin; the correct incision site was identified using the anteroposterior view fluoroscopically. An 11- or 13-gauge vertebroplasty needle was gently hammered into the anterior third of the vertebral body, followed by injection of polymethylmethacrylate (PMMA) bone cement (SimplexP; Stryker Howmedica Osteonics, Allendale, NJ, USA), until a satisfactory distribution of the cement, that is, a symmetrical filling of the central and anterior parts of the vertebral body, was obtained, or until cement leakage was noted. When necessary, a second needle was advanced into the vertebral body through the contralateral pedicle, followed by injection of the cement.

Statistical analysis

The imaging and operative data were analyzed using the SPSS statistical software package (SPSS statistical software 16.0; SPSS Inc., Chicago, IL, USA). Comparisons between groups were performed with the use of the *t* test, and *P* values < 0.05 were deemed significant.

Results

This study included 2127 (67%) women and 1048 men (33%), 60 to 98 years old (mean age, 76 years), all with at least 6 months of follow-up. A total of 3812 vertebroplasty procedures were performed in 3175 patients, among which 2644 had a single fracture, 436 had two vertebral fractures, 84 had three fractures, and 11 had four fractures (Table 1). Most operations were performed in subacute stage (56.7%), and chronic stage (40.7%); only 2.6% in acute stage (Table 1). Patient number of cement leakage corresponded to each characteristic were detailed listed (Table 1). There was no significantly statistical difference of types of cement leakage between age, gender, number of fracture treated, and time from fracture to vertebroplasty.

Parameters related to imaging and technical characteristics, including the method of approach, amount of bone cement injected, and local or general anesthesia used were recorded (Table 2). Most operation were performed using unipedicular approach (98.4%) and bipedicular procedures were performed if poor filling of vertebra after unipedicular approach. The volume of cement injected were less than 3.5 cc in 320 patients (8.4%), 3.5 cc to 7 cc in 2821 patients (74%), and more than 7 cc in patients (17.6%). General anesthesia were used only in 153 patients (4.8%) with poor surgical compliance. The levels treated were from T5 to L5; four in T5, ten in T6, eight in T7, 19 in T8, 21 in T9, 36 in T10, 72 in T11, 1170 in T12, 1187 in L1, 601 in L2, 304 in L3, 272 in L4, and 108 in L5; with an emphasis on T12 and L1 (62%).

Table 1 Patient demographics and clinical data

Characteristic	Number (%)	Cement B type (n = 380)	leakage S type (n = 160)	C type-paraspinal (n = 790)	C type-intradiscal (n = 835)	C type-posterior (n = 26)	p value
Age (year) (n = 3175)							
60–69	594 (18.7%)	69	33	148	156	5	<i>p</i> > 0.05
70–79	1254 (39.5%)	148	60	312	330	10	
80–89	1118 (35.2%)	138	56	278	293	9	
90–99	209 (6.4%)	25	11	51	56	2	
Gender (n = 3175)							
Female	2127 (67%)	254	106	529	557	17	<i>p</i> > 0.1
Male	1048 (33%)	126	54	261	278	9	
No. of fractures treated (n = 3175 patients)							
1	2644 (83.2%)	133	133	658	693	19	<i>p</i> > 0.05
2	436 (13.7%)	55	22	109	117	4	
3	84 (2.6%)	11	4	21	22	2	
4	11 (0.5%)	1	0	3	3	1	
Time from fracture to vertebroplasty (n = 3175 patients)							
Acute (0–2 weeks)	82 (2.6%)	9	3	20	21	1	<i>p</i> > 0.05
Subacute (2 weeks–3 months)	1801 (56.7%)	215	88	448	472	15	
Chronic (> 3 months)	1292 (40.7%)	156	69	321	342	10	

Cement leakage condition

Of the total 3812 vertebroplasty procedures performed, cement leakage was found in 2542 vertebrae (66.7%) (Table 3). A detailed demonstration of characters and appearance of cement leakage were also demonstrated in Table 3. Type-B leaks (11.1%) via the epidural venous plexus and type-S leaks (3.9%) via the segmental vein were less common than type-C leaks (51.8%). Type-C leaks, which occurred via a cortical defect, were divided into three groups: type-C paraspinal (24.9%), indicating leaks around a vertebral body; type-C intradiscal (26.2%), indicating leakage into an adjacent disc; and type-C posterior (0.7%), indicating leaks into the spinal canal (Table 3).

Clinically significant complications were noted in 13 augmented vertebrae—four of 26 patients with a type-C

posterior leak needed decompression surgery (Fig. 1) due to canal compromise and nine of 153 patients with a type S leak needed postoperative oxygen support due to pulmonary embolism (Fig. 2).

Incidence of cement leakage and pulmonary embolism was the same in both the thoracic and lumbar areas (Table 4), but there was a statistical difference in neurological deficits between these two locations. Three of nine patients with a T-spine type-C posterior leak needed decompression surgery due to canal compromise, but only one of 17 patients with an L-spine type-C posterior leak needed another surgery (*p* < 0.01) (Table 4).

The volume of PMMA injected was highly correlated with type S leakage and pulmonary cement embolism (PMMA injection < 3.5 cc: 0%; 3.5–7.0 cc: 0.11%; > 7.0 cc: 0.9%; *p* < 0.01) which needed postoperative oxygen support. There was no difference in other types of leakage or neurological deficits (Table 5).



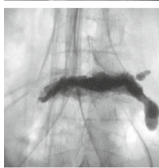
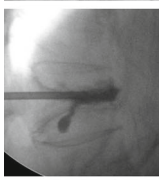

Table 2 Parameters related to imaging and technical characteristics

Operative characteristic (n = 3812 vertebra)	Number (%)
Unipedicular approach	3751 (98.4%)
Bipedicular approach	61 (1.6%)
Volume injected	
< 3.5 cc	320 (8.4%)
3.5–7 cc	2821 (74%)
> 7 cc	671 (17.6%)
Anesthesia	
Local	3022 (95.2%)
General	153 (4.8%)

Discussion

Osteoporosis is a systemic disease that results from progressive bone mineral loss and changes in bony component, leaving the spinal vertebrae vulnerable to VCFs. Painful osteoporotic VCFs can be a devastating burden for patients, as they impair physical function and quality of life. Moreover, VCFs can lead to progressive sagittal spine deformities and changes in spinal biomechanics, which are believed to contribute to a five-fold increased risk of further fracture [32]. Conservative treatment for the pain caused by VCFs includes analgesic medication,

Table 3 Cement leakage of vertebroplasty in 3812 augmented vertebrae

Cement leakage of vertebroplasty in 3812 augmented vertebrae.			
Cement leakage (n=3812)	2542 (66.7%)	Character	Appearance
B type	419 (11.1%)	Leakage via basivertebral vein. Cement spread along the epidural venous plexus just behind the posterior vertebral body	
S type	153 (3.9%)	Leakage via segmental vein. Thin, long and toward heart is usually found on radiographs.	
C type- paraspinal	953 (24.9%)	Leakage via a para-vertebral cortical defect. A irregular mass leakage in paraspinal region is distinguished from that in S-type.	
C type- intradiscal	991 (26.2%)	Leakage via ruptured endplate into disc.	
C type- posterior	26 (0.7%)	Leakage via a posterior cortical defect into the spinal canal. Irregular mass lesion into spinal canal from leakage cement is totally different from the B-type leakage which along the posterior vertebral body.	

bed rest, and back braces; however, these therapies do not address spinal deformities [1]. Furthermore, pain and disability may be prolonged while the fractured vertebral body heals [33]. PVP in osteoporotic VCFs, involving the percutaneous injection of cement directly into the fractured vertebra, is effective in ameliorating VCF-associated pain [34–36]. The limitation of this procedure is the substantial risk of extravertebral cement leakage after high-pressure cement injection, with severe clinical complications including spinal cord compression [15, 37–40], radicular pain [41], and systemic embolism [42–46]. Local leakage of PMMA is frequent, and varies up to more than 70% [1, 47–51]; however, in most cases, the leakage does not produce any symptoms [47–49].

In our review, cement leaks were noted in 69.1% of all performed procedures, but only 0.72% of patients had

clinical complications. These included neurological deficit in four patients (0.26%) who achieved partial or full recovery after decompression surgery, and pulmonary embolism in nine patients (0.46%) who needed postoperative oxygen support.

There were statistical differences in neurological deficits between the thoracic and lumbar spine (Table 4), leading us to believe that cement leakage is not tolerated in the narrowing thoracic spinal canal. It was of interest that only four of 26 patients with a type-C posterior leak had clinical symptoms. We thought that the kyphotic spinal curvature might have made the canal wider. The four patients with a neurological deficit achieved partial or full recovery after decompression surgery.

In our series, the nine patients with symptomatic pulmonary embolism were all in the type-S leak group

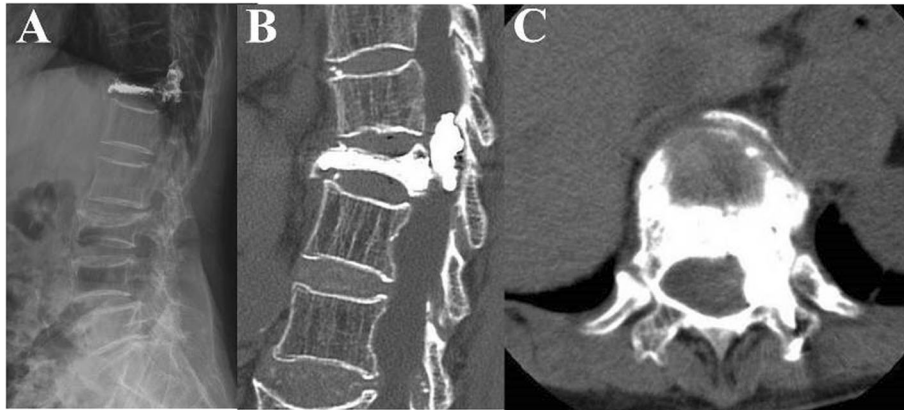


Fig. 1 An 89-year-old female developed severe back pain and left-side lower limb motor weakness after T12 PVP using PMMA cement. Postoperative lateral (a) and CT (b) showing a type-C posterior leakage and cement leakage into the left spinal canal, which caused left-side lower limb weakness (c). The neurological deficit was fully recovered after immediate decompression surgery

(Table 5), and this may be related to the cement embolism pathophysiology. The PMMA flows out through the basivertebral vein and then through the anterior external vertebral venous plexus, which leads to the pulmonary veins via the segmental spinal veins, the vena radicularis magna, the azygos vein, and the accessory hemiazygos vein [52]. A symptomatic pulmonary embolism following vertebroplasty can occur either by migration of acrylic or migration of fat and bone marrow cells [53]. On the one hand, the majority of radiologically detected PMMA migration into lung vessels is asymptomatic and, on the other, fat embolism is more frequent than PMMA

embolism [54]. According to the observation, in cases of symptomatic pulmonary embolism with detectable PMMA in lung vessels after vertebroplasty, fat embolism occurring simultaneously may also contribute to the clinical manifestation of pulmonary embolism. Early symptoms caused by the passing of emboli through the pulmonary artery occur 6 s after injection, which should be distinguished from the very rapid decrease in heart rate and the fall in arterial pressure caused by a nerve reflex response occurs about 2 s after injection.

One study [55] recommended no treatment besides clinical follow-up for asymptomatic patients with peripheral

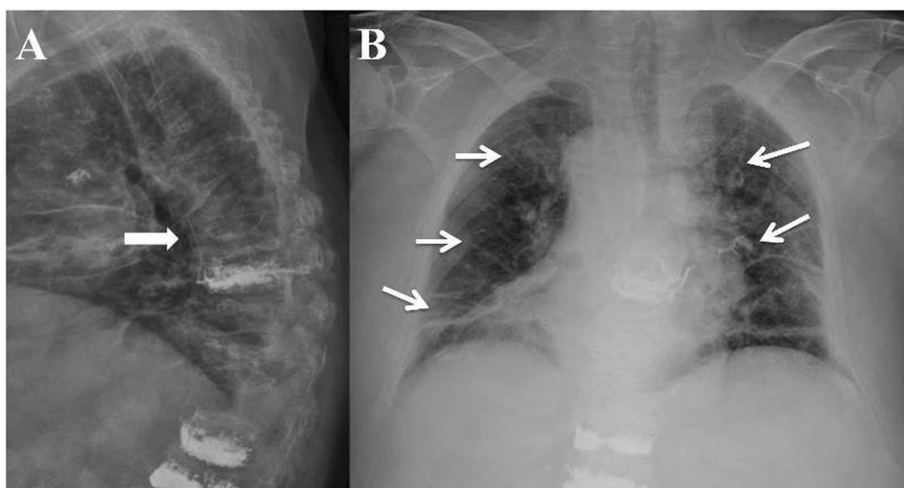


Fig. 2 Postoperative lateral spinal radiograph 1 day after PVP with PMMA of osteoporotic fractures at levels T8, T12, and L1 in an 86-year-old male. The patient had dyspnea and chest pain after operation; type S leakage along the paravertebral veins (arrow) was noted (a). High-density PMMA cement with a tubular shape and branching opacities (arrows) distributed throughout the lungs and corresponding to lung vessels, caused pulmonary embolism, as seen on chest radiograph (b). After oxygen support and anticoagulation therapy for 3 days, follow-up revealed no symptom aggravation

Table 4 Cement leakage and complications during percutaneous vertebroplasty according to thoracic and lumbar spine

Location	T-spine (n = 1340)	L-spine (n = 2472)	P value
Cement leakage			
B type	130 (9.7%)	289 (11.7%)	$p > 0.05$
S type	61 (4.5%)	92 (3.7%)	$p > 0.05$
C type- paraspinal	381 (28.4%)	572 (23.1%)	$p > 0.05$
C type- intradiscal	289 (21.6%)	702 (28.3%)	$p > 0.05$
C type- posterior	9 (0.67%)	17 (0.69%)	$p > 0.05$
Clinical complication			
Neurological deficit	3 (0.22%)	1 (0.04%)	$p < 0.01$
Pulmonary embolism	3 (0.22%)	6 (0.24%)	$p > 0.05$

pulmonary cement embolism, and initial heparinization and a following 6-month coumarin therapy for symptomatic pulmonary cement embolism.

Pulmonary embolism occurs in 4–26% of patients [56–59], but it occurred in only nine patients in our study. While symptoms were resolved after oxygen support and anticoagulation therapy, as recommended [60], no patient required open cardiac surgery to remove the cement from the lungs or from the right perforated ventricle.

Two limitations were in our study. First, this is a retrospective single center study. Second, only X-ray image was not enough to detect cement leakage and result in under estimate the leakage rate.

Conclusion

PVP with PMMA is a common and effective treatment modality for painful osteoporotic vertebral compression fractures, but is not as simple and risk-free as suggested

Table 5 Cement leakage and complications according to volume of cement injected

Volume of cement injected	< 3.5 cc (n = 320)	3.5–7.0 cc (n = 2821)	> 7.0 cc (n = 671)	P value
Cement leakage				
B type	22 (6.8%)	310 (11%)	87 (12.9%)	$p > 0.05$
S type	9 (2.8%)	81 (2.9%)	63 (9.4%)	$p < 0.01$
C type- paraspinal	64 (20%)	790 (28%)	99 (14.8%)	$p > 0.05$
C type- intradiscal	75 (23.4%)	730 (25.8%)	186 (27.7%)	$p > 0.05$
C type- posterior	2 (0.62%)	19 (0.67%)	5 (0.74%)	$p > 0.05$
Clinical complication				
Neurological deficit	0 (0%)	3 (0.11%)	1 (0.15%)	$p > 0.05$
Pulmonary embolism	0 (0%)	3 (0.11%)	6 (0.9%)	$p < 0.01$

in many radiology and spinal surgery studies. Vertebroplasty is a minimally invasive surgical procedure with a high rate of cement leakage (69.1%), but a low incidence of clinical complications (0.72%). When injecting a high volume of cement, physicians should be aware of type S leaks if there are signs of pulmonary embolism, including decreased blood pressure, tachycardia, and dyspnea. Awareness of possible neurological symptoms should be heightened when there is cement leakage into the thoracic spinal canal.

Abbreviations

OVCF: Osteoporotic vertebral compression fracture; PVP: Percutaneous vertebroplasty

Acknowledgments

We thank the Department of Orthopaedic Surgery for their contribution to the study.

Authors' contributions

P-YC, F-CK, and M-KH participated in the study design, data collection, the statistical analysis, and manuscript writing. P-LL, L-HC, and T-TT participated in the study design. N-CC and C-WY used the iThenticate report to assist in ensuring that the correct attribution to the original source was made. F-CK and M-KH advised and assisted the manuscript writing. All authors read and approved the final manuscript.

Funding

There is no finding source.

Availability of data and materials

The data that support the findings of this study are available from Chang Gung Memorial Hospital but restrictions apply to the availability of these data, which were used under license for the current study, and so are not publicly available. Data are however available from the authors upon reasonable request and with permission of Chang Gung Memorial Hospital.

Ethics approval and consent to participate

The Chang Gung Medical Foundation Institutional Review Board approved this study (IRB No. 103-3388B) and waived the requirement for informed consent due to the retrospective nature of the study.

Consent for publication

Consent for publication was available.

Competing interests

The authors declare that they have no competing interests.

Author details

¹Department of Orthopedic Surgery, Chang Gung Memorial Hospital, Taoyuan, Taiwan. ²Bone and Joint Research Center, Chang Gung Memorial Hospital, Linkou, Taiwan. ³College of Medicine, Chang Gung University, Taoyuan, Taiwan.

Received: 11 June 2019 Accepted: 6 November 2019

Published online: 29 November 2019

References

- Hussain A, Erdek M. Vertebroplasty augmentation procedures: examining the controversy. *Pain Physician*. 2013;16:E483–90.
- Layton KF, Thielen KR, Koch CA, et al. Vertebroplasty, first 1000 levels of a single center: evaluation of the outcomes and complications. *AJNR Am J Neuroradiol*. 2007;28:683–9.
- Diamond TH, Champion B, Clark WA. Management of acute osteoporotic vertebral fractures: a nonrandomized trial comparing percutaneous vertebroplasty with conservative therapy. *Am J Med*. 2003;114:257–65.
- Diamond TH, Bryant C, Browne L, Clark WA. Clinical outcomes after acute osteoporotic vertebral fractures: a 2-year non-randomised trial comparing

- percutaneous vertebroplasty with conservative therapy. *Med J Aust.* 2006; 184:113–7.
5. Alvarez L, Alcaraz M, Perez-Higueras A, et al. Percutaneous verte-broplasty: functional improvement in patients with osteoporotic compression fractures. *Spine.* 2006;31:1113–8.
 6. Jensen ME, McGraw JK, Cardella JF, Hirsch JA. Position statement on percutaneous vertebral augmentation: a consensus statement developed by the American Society of Interventional and Therapeutic Neuroradiology, Society of Interventional Radiology, American Association of Neurological Surgeons/Congress of Neurological Surgeons, and American Society of Spine Radiology. *J Vasc Interv Radiol.* 2007;18:325–30.
 7. Klazen CA, Lohle PN, de Vries J, et al. Vertebroplasty versus conservative treatment in acute osteoporotic vertebral compression fractures (Vertos II): an open-label randomised trial. *Lancet.* 2010;376:1085–92.
 8. Buchbinder R, Osborne RH, Ebeling PR, et al. A randomized trial of vertebroplasty for painful osteoporotic vertebral fractures. *N Engl J Med.* 2009;361:557–68.
 9. Kallmes DF, Comstock BA, Heagerty PJ, et al. A randomized trial of vertebroplasty for osteoporotic spinal fractures. *N Engl J Med.* 2009;361: 569–79.
 10. Kroon F, Staples M, Ebeling PR, et al. Two-year results of a randomized placebo-controlled trial of vertebroplasty for acute osteoporotic vertebral fractures. *J Bone Miner Res.* 2014;29:1346–55.
 11. Rad AE, Kallmes DF. Correlation between preoperative pain duration and percutaneous vertebroplasty outcome. *AJNR Am J Neuroradiol.* 2011;32: 1842–5.
 12. Comstock BA, Sitlani CM, Jarvik JG, et al. Investigational vertebroplasty safety and efficacy trial (INVEST): patient-reported outcomes through 1 year. *Radiology.* 2013;269:224–31.
 13. Eck JC, Nachtigall D, Humphreys SC, Hodges SD. Comparison of vertebroplasty and balloon kyphoplasty for treatment of vertebral compression fractures: a meta-analysis of the literature. *Spine J.* 2008;8:488–97.
 14. Lee MJ, Dumonski M, Cahill P, et al. Percutaneous treatment of vertebral compression fractures: a meta-analysis of complications. *Spine.* 2009;34: 1228–32.
 15. Lee BJ, Lee SR, Yoo TY. Paraplegia as a complication of percutaneous vertebroplasty with polymethylmethacrylate: a case report. *Spine.* 2002;27: E419–22.
 16. Patel AA, Vaccaro AR, Martyak GG, et al. Neurologic deficit following percutaneous vertebral stabilization. *Spine.* 2007;32:1728–34.
 17. Harrington KD. Major neurological complications following percutaneous vertebroplasty with polymethylmethacrylate: a case report. *J Bone Joint Surg Am.* 2001;83:1070–3.
 18. Lim SH, Kim H, Kim HK, Baek MJ. Multiple cardiac perforations and pulmonary embolism caused by cement leakage after percutaneous vertebroplasty. *Eur J Cardiothorac Surg.* 2008;33:510–2.
 19. Son KH, Chung JH, Sun K, Son HS. Cardiac perforation and tricuspid regurgitation as a complication of percutaneous vertebroplasty. *Eur J Cardiothorac Surg.* 2008;33:508–9.
 20. Monticelli F, Meyer HJ, Tutsch-Bauer E. Fatal pulmonary cement embolism following percutaneous vertebroplasty (PVP). *Forensic Sci Int.* 2005;149:35–8.
 21. Hulme PA, Krebs J, Ferguson SJ, Berlemann U. Vertebroplasty and kyphoplasty: a systematic review of 69 clinical studies. *Spine.* 2006;31:1983–2001.
 22. Legroux-Gerot I, Lormeau C, Boutry N, et al. Long-term follow-up of vertebral osteoporotic fractures treated by percutaneous vertebroplasty. *Clin Rheumatol.* 2004;23:310–7.
 23. Muijs SP, Nieuwenhuijse MJ, Van Erkel AR, Dijkstra PD. Percutaneous vertebroplasty for the treatment of osteoporotic vertebral compression fractures: evaluation after 36 months. *J Bone Joint Surg Br.* 2009;91:379–84.
 24. Schmidt R, Cakir B, Mattes T, et al. Cement leakage during vertebroplasty: an underestimated problem? *Eur Spine J.* 2005;14:466–73.
 25. Yeom JS, Kim WJ, Choy WS, et al. Leakage of cement in percutaneous transpedicular vertebroplasty for painful osteoporotic compression fractures. *J Bone Joint Surg Br.* 2003;85:83–9.
 26. Chen WJ, Kao YH, Yang SC, et al. Impact of cement leakage into disks on the development of adjacent vertebral compression fractures. *J Spinal Disord Tech.* 2010;23:35–9.
 27. Kamano H, Hiwatashi A, Kobayashi N, et al. New vertebral compression fractures after prophylactic vertebroplasty in osteoporotic patients. *Am J Roentgenol.* 2011;197:451–6.
 28. Kim MH, Lee AS, Min SH, Yoon SH. Risk factors of new compression fractures in adjacent vertebrae after percutaneous vertebroplasty. *Asian Spine J.* 2011;5:180–7.
 29. Weixing X, Daxiang J, Chao W, et al. The incidence of new vertebral fractures following vertebral augmentation. *Medicine (Baltimore).* 2015;94:e1532.
 30. Xiaodong Y, Hailin L, Fei T, et al. Recompression in new levels after percutaneous vertebroplasty and kyphoplasty compared with conservative treatment. *Arch Orthop Trauma Surg.* 2014;134:21–30.
 31. Abdelrahman H, Siam AE, Shawky A, et al. Infection after vertebroplasty or kyphoplasty. A series of nine cases and review of literature. *Spine J.* 2013;13: 1809–7.
 32. Heaney RP. The natural history of vertebral osteoporosis. Is low bone mass an epiphenomenon? *Bone.* 1992;13:S23–6.
 33. Silverman SL. The clinical consequences of vertebral compression fracture. *Bone.* 1992;13(Suppl 2):S27–31.
 34. Laredo JD, Bellaiche L, Hamze B, et al. Current status of musculoskeletal interventional radiology. *Radiol Clin North Am.* 1994;32:377–98.
 35. Cyteval C, Sarrabere MP, Roux JO, et al. Acute osteoporotic vertebral collapse: open study on percutaneous injection of acrylic surgical cement in 20 patients. *AJR Am J Roentgenol.* 1999;173:1685–90.
 36. Deramond H, Depriester C, Galibert P, et al. Percutaneous vertebroplasty with polymethylmethacrylate. Technique, indications, and results. *Radiol Clin North Am.* 1998;36:533–46.
 37. Sidhu GS, Kepler CK, Savage KE, et al. Neurological deficit due to cement extravasation following a vertebral augmentation procedure. *J Neurosurg Spine.* 2013;19:61–70.
 38. Tsai YD, Liliang PC, Chen HJ, et al. Anterior spinal artery syndrome following vertebroplasty: a case report. *Spine (Phila Pa 1976).* 2010;35:E134–6.
 39. Chen YJ, Tan TS, Chen WH, et al. Intradural cement leakage: a devastatingly rare complication of vertebroplasty. *Spine (Phila Pa 1976).* 2006;31:E379–82.
 40. Kulkarni AG, Shah SP, Deopujari CE. Epidural and intradural cement leakage following percutaneous vertebroplasty: a case report. *J Orthop Surg.* 2013; 21:365–8.
 41. Chen JK, Lee HM, Shih JT, Hung ST. Combined extraforaminal and intradiscal cement leakage following percutaneous vertebroplasty. *Spine (Phila Pa 1976).* 2007;32:E358–62.
 42. Kao FC, Tu YK, Lai PL, et al. Inferior vena cava syndrome following percutaneous vertebroplasty with polymethylmethacrylate. *Spine.* 2008;33:E329.
 43. Rothermich MA, Buchowski JM, Bumpass DB, Patterson GA. Pulmonary cement embolization after vertebroplasty requiring pulmonary wedge resection. *Clin Orthop Relat Res.* 2014;472:1652–7.
 44. Prokop A, Hagele M, Pfeilsticker U, et al. Pericardial perforation 2,5 years after kyphoplasty. A rare complication after cement extravasation [in German]. *Unfallchirurg.* 2013;116:80–4.
 45. Panagiotis I, Panagiotis K, Vasilios V. PMMA embolization to the left dorsal foot artery during percutaneous vertebroplasty for spinal metastases. *Eur Spine J.* 2014;suppl 2:187–191.
 46. Chung SE, Kim TH, Yoo KH, Jo BJ. Renal cement embolism during percutaneous vertebroplasty. *Eur Spine J.* 2006;suppl 5:590–594.
 47. Khosla A, Diehn FE, Rad AE, Kallmes DF. Neither subendplate cement deposition nor cement leakage into the disk space during vertebroplasty significantly affects patient outcomes. *Radiology.* 2012;264:180–6.
 48. Kotwica Z, Saracen A. Early and long-term outcomes of vertebroplasty for single osteoporotic fractures. *Neurol Neurochir Pol.* 2011;45:431–5.
 49. Saracen A, Kotwica Z. Treatment of multiple osteoporotic vertebral compression fractures by percutaneous cement augmentation. *Int Orthop.* 2014;38:2309–12.
 50. Hao J, Hu Z. Percutaneous cement vertebroplasty in the treatment of symptomatic vertebral hemangiomas. *Pain Physician.* 2012;16:43–9.
 51. Lee IJ, Choi AL, Yie MY, et al. CT evaluation of local leakage of bone cement after percutaneous kyphoplasty and vertebroplasty. *Acta Radiol.* 2010;51:649–54.
 52. Youssef Abdul-Jalil, Joerg Bartels, Olaf Alberti, and Ralf Becker. Delayed Presentation of Pulmonary Polymethylmethacrylate Emboli after Percutaneous Vertebroplasty. *Spine* 2007 Volume 32, Number 20, pp E589–E593
 53. Aebli N, Krebs J, Davis G, et al. Fat embolism and acute hypotension during vertebroplasty: experimental study in sheep. *Spine.* 2002;27:460–6.
 54. Rauschmann D, von Stechow D, Thomann KD, et al. Complications of vertebroplasty. *Orthopade.* 2003;33:40–7.
 55. Bernhard J, Heini PF, Villiger PM. Asymptomatic diffuse pulmonary embolism caused by acrylic cement: an unusual complication of percutaneous vertebroplasty. *Ann Rheum Dis.* 2003;62:85–6. <https://doi.org/10.1136/ard.62.1.85>.

56. Luetmer MT, Bartholmai BJ, Rad AE, Kallmes DF. Asymptomatic and unrecognized cement pulmonary embolism commonly occurs with vertebroplasty. *AJNR Am J Neuroradio*. 2011;32:654–7.
57. Duran C, Sirvanci M, Aydogan M, et al. Pulmonary cement embolism: a complication of percutaneous vertebroplasty. *Acta Radiol*. 2007;48:854–9.
58. Geraci G, Lo Iacono G, Lo Nigro C, et al. Asymptomatic bone cement pulmonary embolism after vertebroplasty: case report and literature review. *Case Rep Surg*. 2013;2013:591432.
59. Rothermich MA, Buchowski JM, Bumpass DB, Patterson GA. Pulmonary cement embolization after vertebroplasty requiring pulmonary wedge resection. *Clin Orthop Relat Res*. 2014;472:1652–7.
60. Krueger A, Bliemel C, Zettl R, Ruchholtz S. Management of pulmonary cement embolism after percutaneous vertebroplasty and kyphoplasty: a systematic review of the literature. *Eur Spine J*. 2009;18(9):1257–65.

Publisher's Note

Springer Nature remains neutral with regard to jurisdictional claims in published maps and institutional affiliations.

Ready to submit your research? Choose BMC and benefit from:

- fast, convenient online submission
- thorough peer review by experienced researchers in your field
- rapid publication on acceptance
- support for research data, including large and complex data types
- gold Open Access which fosters wider collaboration and increased citations
- maximum visibility for your research: over 100M website views per year

At BMC, research is always in progress.

Learn more biomedcentral.com/submissions

