

Radiological insertion of Tenckhoff catheters for peritoneal dialysis: a 1-year single-centre experience

Trung Quach¹, Peter Tregaskis¹, Solomon Menahem¹, Jim Koukounaras², Nigel Mott² and Rowan G. Walker¹

¹Department of Renal Medicine, Alfred Hospital, Melbourne, VIC, Australia and ²Department of Radiology, Alfred Hospital, Melbourne, VIC, Australia

Correspondence and offprint requests to: T. Quach; E-mail: t.quach@alfred.org.au

Abstract

Background. Peritoneal dialysis (PD) is an important home-based dialysis modality for patients with end-stage kidney disease (ESKD). The initiation of PD requires timely and skilled insertion of a Tenckhoff catheter (TC). At most centres, TCs are inserted laparoscopically by surgeons under general anaesthetic. This requires access to increasingly scarce surgical, anaesthetic and hospital inpatient resources. Radiological insertion of TCs performed as a day procedure under local anaesthetic allows for easier access to the TC insertion with reduced resource requirements. We report our 1-year experience following the introduction of this technique to our PD programme.

Methods. This is a retrospective review of the outcomes for all patients who had TCs inserted radiologically (percutaneously with the assistance of ultrasound and fluoroscopy) over the 12-month period from December 2011 to December 2012. Relevant patient demographics collected included age, gender, body mass index (BMI), previous abdominal surgery and cause of ESKD. Extended details of the insertion procedure were also obtained including length of stay, early complications and time to first use of the catheter for PD.

Results. Thirty Argyle™ Swan Neck TCs were inserted under radiological guidance during the study period. The mean age of patients was 56 (SD ± 14). The male-to-female ratio was 2:1. The mean BMI was 25.7 (SD ± 4.8). PD was the initial dialysis modality in 22 (73%) patients. Of the 30 patients, 14 (46.7%) had previously undergone extraperitoneal abdominal surgery. All catheters were inserted successfully as day cases except four patients (13.3%) who had catheters inserted during an inpatient hospital admission. Most catheters were not accessed for a minimum of 10 days to reduce the chance of exit site leakage, in two cases the catheters were used within 5 days without complication. There were no cases of peritonitis or exit site infection during the observation period. Catheter migration occurred in four patients (13.3%) but only one required surgical intervention. Minor pain issues were noted in six patients (20%) and bleeding around the exit site requiring suturing in two patients (6.7%). The introduction of this technique at our institution saw a 67% increase in the number of patients performing PD.

Conclusions. Radiological insertion of TCs for PD provided improved access to catheter insertion in a timely manner with reduced resource requirements. Over the 12-month observation period we noted a high technical success rate with very few complications. Our study supports radiological insertion of TCs under local anaesthetic as a viable alternative to catheter insertion in theatre under general anaesthetic. The relative ease of radiological TC insertion has resulted in a significant increase in patient uptake of PD at our centre.

Keywords: peritoneal dialysis; radiology; Tenckhoff catheter

Introduction

Peritoneal dialysis (PD) is an important home-based dialysis modality for patients with end-stage kidney disease (ESKD). It represents 23.5% of all dialysis therapy across Australia and New Zealand and 69% of all home-based therapies [1]. Providing dialysis in the home setting delivers many potential benefits to patients including the

engagement in self-care and management, improved employment opportunities and reduced need for travel to dialysis centres [2]. PD provides similar outcomes and possibly a mortality benefit in the early years of dialysis compared with haemodialysis [3, 4]. In addition, it is more cost-effective than satellite haemodialysis and as such delivers numerous flow-on institutional and health system advantages [5, 6].

The initiation and maintenance of patients on PD requires the timely and skilled insertion of a Tenckhoff catheter (TC). There have been a number of techniques of TC insertion described in the literature including open, laparoscopic, peritoneoscopic and percutaneous methods [7–9]. Until recently, at our centre, TCs were all inserted laparoscopically by surgeons under general anaesthetic. The optimal insertion method is unknown due to the lack of randomized controlled trials and depends significantly on patient factors, institutional preference and operator experience [10].

Radiological insertion of TCs under fluoroscopy and ultrasound guidance has been previously described [11–15] and seems comparable in terms of technical success and complication rates to surgically inserted catheters. It is, however, more likely that the radiological procedure can be performed under local anaesthetic as a day case rather than requiring overnight in-patient stay. The timing of catheter placement is vital in ensuring that dialysis can be initiated when required. Ideally, catheters should be inserted considerably (preferably at least 2 weeks) prior to use in order to reduce the likelihood of catheter leaks and infections [10]. The radiological technique could allow for more timely insertion of TCs avoiding the need for pre-operative anaesthetic assessment, access to an operating theatre and the need for an in-patient admission.

In this study, we aim to report our 1-year experience with radiological TC insertion under fluoroscopy and ultrasound guidance.

Materials and methods

Radiological TC insertion for PD was first introduced at our centre in December 2011. At that time, there were 30 patients on maintenance PD, which accounted for 15% of all patients in our dialysis programme.

Patients were initially selected for radiological catheter insertion if they did not have major cardiovascular or respiratory disease, significant bleeding abnormalities or a requirement for intense anticoagulation. The need to be able to lie supine for at least 1 h was an additional requirement. Patients with major abdominal surgery were initially excluded; however, following early experience with this technique, patients who had previously undergone extra-peritoneal surgery were also considered for radiological TC insertion.

The insertion procedures were all coordinated by the PD nursing coordinator. A lone interventional radiologist and radiology fellow performed all procedures.

Patient demographics including age, gender, cause of ESKD and previous abdominal surgery were collected. Outcomes following catheter insertion were obtained including technical success, discharge from hospital on the day of procedure, catheter leaks and migration, time to first use and exit site infection and peritonitis rates.

Technique of TC insertion

The patient was reviewed by the PD nurse coordinator prior to each procedure. The patient's belt line was marked clearly on their skin. Prophylactic antibiotic therapy in the form of cephazolin (1 g intravenously) was administered prior to the procedure.

Informed consent was obtained by the interventional radiologist. The planned insertion site and tunnel and exit

site were marked on the skin taking into account the patient's belt line, previous surgical scars, body habitus and the position of the inferior epigastric artery as determined by ultrasound. Conscious sedation with intravenous midazolam and fentanyl was titrated to the patient's needs during the procedure.

After sterile preparation of the target anatomical region, the area was infiltrated with local anaesthetic using 1% lignocaine subcutaneously. A 2-cm incision was made and blunt dissection performed to the rectus sheath. The peritoneum was punctured with a 19-gauge needle using ultrasound guidance. The position was then confirmed fluoroscopically by the injection of non-ionic iodinated contrast. Angiographic catheter/wire combinations were used to reach the rectovesical/rectouterine pouches. A peritoneogram was performed to ensure there were no loculations or adhesions.

The insertion site was serially dilated until a 15-French peel away sheath was inserted into the peritoneal cavity. The PD catheter was tunnelled from the insertion site to the exit site (antegrade direction), pulling the lateral cuff through the subcutaneous tissues. The remaining catheter was then placed into the peritoneum via the peel away sheath, which was then removed. The medial cuff was then advanced to lie immediately above the rectus sheath and then the final position was confirmed with contrast.

Following the procedure, a further 1 g of cephazolin was added to Freeline Solo™ dialysis bag and flushing of the catheter was performed by the PD nurse coordinator in the radiology suite.

Patients were returned to a Day Procedure Unit ward where the patient was positioned at 45° for 1 h. Observations for haemodynamic state and puncture site were performed every 30 min for 2 h. The patient was discharged home if stable following review by the PD nurse coordinator and a member of medical staff.

Results

A total of 30 TCs were inserted radiologically during the 12-month period of observation. The introduction of this technique at our institution saw a significant growth in the number of patients performing PD, expanding from 30 to a total of 50 prevalent patients (67% growth in total PD patients over a 12-month period). Similarly, the proportion of new dialysis patients commencing PD as their initial dialysis modality improved to 35.8% in 2012, compared with previous levels of 6.0–13.4% in the 4 years prior (Figure 1).

During the study period, 10 patients were referred for surgical insertion of their catheters under general anaesthetic. The reasons for this included contrast allergy, previous major abdominal surgery and the request for creation of a 'back-up' arteriovenous fistula by the referring renal physician.

Baseline patient demographics are detailed in Table 1. Fourteen of 30 (46.7%) patients had previously undergone extra-peritoneal abdominal surgery including prior renal transplant, nephrectomy, inguinal hernia repair, appendectomy and Caesarean section and 14 of 30 (46.7%) patients were overweight as defined by the World Health Organization criteria with a BMI >25 kg/m² and 6/30 (20%) had a BMI in the obese range >30 kg/m². The maximum BMI was 34.4 kg/m². Diabetes and hypertension was the cause of ESKD in 15/30 (50%) of patients.

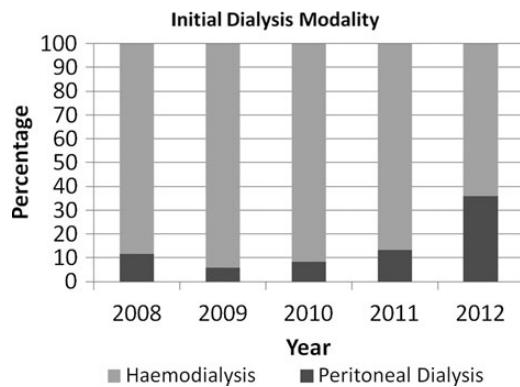


Fig. 1. Initial dialysis modality.

Table 1. Patient demographics

Age (mean \pm SD)	56 years (\pm 14)
Gender (n)	Male (20): female (10)
Cause of ESKD, n (%)	
Hypertension	8 (26.7%)
Diabetes	7 (23.3%)
Glomerulonephritis	5 (16.7%)
Reflux-associated nephropathy	4 (13.3%)
ADPKD	2 (6.7%)
Other	4 (13.3%)
BMI (mean \pm SD)	25.7 kg/m ² (\pm 4.8)
Previous abdominal surgery, n (%)	14 (46.7%)
PD initial dialysis modality, n (%)	22 (73%)

Outcomes and complications of TC insertion are outlined in Table 2. Four patients had radiological TC insertion performed during an inpatient admission and were therefore not performed as a day case. Minor bleeding occurred in 2 (6.7%) cases requiring suturing of the exit site. Pain on flushing of the catheter occurred in 6 (20%) patients but this largely resolved going forward with the routine use of laxatives prior to catheter insertion. Catheter migration occurred in 4 (13.3%); however, only one patient required surgical intervention. All other catheter migrations resolved without any intervention.

Twenty-four out of 30 (80%) patients remained on peritoneal dialysis at the end of the study period. Four patients were converted to haemodialysis: one for catheter malfunction, two for pleural leaks and one for inability to cope with home-based therapy. One patient underwent a successful kidney transplant and one patient had yet to commence PD by the end of the observation period.

Discussion

The initiation of PD is dependent on the timely insertion of a TC in a safe and reliable manner. Traditional techniques of surgical insertion either as an open or laparoscopic procedure may be associated with significant delays in access to operating theatres and the inherent risks associated with a general anaesthetic. This report demonstrates that the insertion of TC radiologically via a percutaneous approach, under mild sedation and local anaesthetic, has a high technical success rate with few major complications and can be safely performed as a day procedure.

Our cohort of patients was similar to previous reports of this technique in terms of age, gender, cause of ESKD and BMI [11, 14, 15]. A significant proportion of our patients

Table 2. Outcomes of catheter insertion

Technical success, n (%)	30/30 (100%)
Day procedure, n (%)	26/30 (87%)
Mean time to first use: (mean \pm SD)	14.7 days (\pm 8.5)
Catheter migration, n (%)	4/30 (13%)
Catheter leak, n (%)	0/30 (0%)
Bleeding, n (%)	2/30 (7%)
Pain, n (%)	6/30 (20%)
Infection, n (%)	0/30 (0%)

were overweight or obese as defined by BMI criteria. There did not appear to be any major differences in complications in those with higher BMI compared with those with lower BMI.

Technical success was achieved in all patients and compares favourably with catheters inserted surgically and previous reports of this technique [11–15]. The largest case series of this insertion technique was reported by Moon *et al.* [14] who performed 134 placements of TC in 114 patients. The authors did not observe any immediate cases of technique failure. Savader *et al.* [12] reported technical success in 18/19 (95%) cases with one failed attempt in a patient with previous major abdominal surgery and adhesions.

Timing of catheter placement is important to ensure that dialysis initiation is provided safely and appropriately. Catheter leak and infections are potential risks associated with early use of post-insertion and guidelines have suggested waiting for at least 2 weeks post-insertion prior to first use [10]. We did not observe any cases of catheter leakage despite two catheters being used within 10 days due to a clinical need to commence dialysis. This is comparable to previous reports. Moon *et al.* [14] reported four (3%) cases of catheter leakage that required catheter rest for 1 week.

Exit-site infection and peritonitis are of major concern and can be a cause of early technique failure. This was not observed in any patients in our cohort. Previous reports of this technique similarly show very low rates of infections [11, 12, 14]. Particular attention to sterile techniques and prophylactic intravenous and intra-peritoneal antibiotics were administered to all patients in our cohort.

Early in our programme, there were several episodes of catheter migration. One case required surgical intervention to reposition the catheter, which was successful. This is similar to previous reports of fluoroscopically inserted catheters [14] as well as surgical methods of catheter placement [8].

Over the 12-month period we have seen significant growth in our peritoneal dialysis programme. Victorian Department of Health recommendations aim for home-based dialysis patients to account for at least 35% of all patients within 6 months of starting dialysis [16]. The improved access to catheter insertion via this technique is likely to have contributed greatly to achieving this target.

There are limitations of a study of this type. It is a cohort study and therefore potentially subject to significant selection and observer bias. Despite this, the experience was very favourable in terms of outcomes and has encouraged us to look at further opportunities in our pre-dialysis population to consider PD as a first option for patients and as a means of promoting home-based dialysis therapies.

Conclusion

Radiological insertion of TC under local anaesthetic with fluoroscopy and ultrasound guidance provides a safe

approach to establishing access for PD. There is a high technical success rate with few major complications. It can be performed under light sedation and is suitable to be carried out as a day procedure. It requires fewer resources than traditional surgical insertion techniques.

Since the introduction of this technique at our institution we have seen a significant growth in our peritoneal dialysis programme. Further studies into long-term outcomes and complications of this procedure will provide added support for establishing peritoneal access in this manner.

Conflict of interest statement. None declared.

(See Editorial Comment by Guest and Abdel Aal. Peritoneal dialysis catheter placement by interventional radiologists. *Clin Kidney J* 2014; 7: 1–2)

References

1. Australia and New Zealand Dialysis and Transplant Registry. ANZDATA registry report 2010. Adelaide: ANZDATA Registry, 2009
2. Coles GA, Williams JD. What is the place of peritoneal dialysis in the integrated treatment of renal failure? *Kidney Int* 1998; 54: 2234–2240
3. Yeates K, Zhu N, Vonesh E et al. Hemodialysis and peritoneal dialysis are associated with similar outcomes for end-stage renal disease treatment in Canada. *Nephrol Dial Transplant* 2012; 27: 3568–3575
4. Heaf JG, Lokkegaard H, Madsen M. Initial survival advantage of peritoneal dialysis relative to haemodialysis. *Nephrol Dial Transplant* 2002; 17: 112–117
5. Berger A, Edelsberg J, Inglese GW et al. Cost comparison of peritoneal dialysis versus hemodialysis in end-stage renal disease. *Am J Manag Care* 2009; 15: 509–518
6. Cass A, Chadban SJ, Gallagher M et al. *The Economic Impact of End-Stage Kidney Disease in Australia*. Australia: Kidney Health Australia, 2010
7. Bargman JM. New technologies in peritoneal dialysis. *Clin J Am Soc Nephrol* 2007; 2: 576–580
8. Crabtree JH. Fluoroscopic placement of peritoneal dialysis catheters: a harvest of the low-hanging fruits. *Perit Dial Int* 2008; 28: 134–137
9. Peppelenbosch A, van Kuijk WHM, Bouvy ND et al. Peritoneal dialysis catheter placement technique and complications. *NDT Plus* 2008; 1(Suppl. 4): iv23–iv28
10. Figueiredo A, Goh BL, Jenkins S et al. Clinical practice guidelines for peritoneal access. *Perit Dial Int* 2010; 30: 424–429
11. Brunier G, Hiller JA, Drayton S et al. A change to radiological peritoneal dialysis catheter insertion: three-month outcomes. *Perit Dial Int* 2010; 30: 528–533
12. Savader SJ, Geschwind JF, Lund GB et al. Percutaneous radiologic placement of peritoneal dialysis catheters: long-term results. *J Vasc Interv Radiol* 2000; 11: 965–970
13. Maya ID. Ultrasound/fluoroscopy-assisted placement of peritoneal dialysis catheters. *Semin Dial* 2007; 20: 611–615
14. Moon JY, Song S, Jung KH et al. Fluoroscopically guided peritoneal dialysis catheter placement: long-term results from a single center. *Perit Dial Int* 2008; 28: 163–169
15. Abdel-Aal AK, Joshi AK, Saddekni S et al. Fluoroscopic and sonographic guidance to place peritoneal catheters: how we do it. *Am J Roentgenol* 2009; 192: 1085–1089
16. Summary of Renal Health Forum, 2012. <http://docs.health.vic.gov.au/docs/doc/Summary-of-Renal-Health-Forum-6-December-2012>

Received for publication: 22.6.13; Accepted in revised form: 28.8.13