

Anterior cervical discectomy and fusion with titanium cages for simple or multilevel herniated discs and spur of the cervical spine: Report of 2 cases and experience in Bali

G. B. Mahadewa Tjokorda, Golden Nyoman, Maliawan Sri, Mizuno Junichi¹

Department of Neurosurgery, Udayana University-Sanglah Hospital, Bali, Indonesia, ¹Center for Spine and Spinal Cord Disorders, Southern Tohoku General Hospital, Iwanuma, Miyagi, Japan

ABSTRACT

This report presents two cases of cervicobrachialgia and radiculopathy due to multiple cervical herniated discs and spur formation that dealt with anterior cervical discectomy and fusion (ACDF) using different titanium interbody cages. The description of the clinical presentation, magnetic resonance imaging (MRI) appearances and management strategy are discussed. Both cases showed chronic neck pain and radiating pain from the shoulder to the arm. They had a history of blurry vision, cluster head ache, weakness, and numbness on the shoulder for 2 years. MRI revealed multiple herniated discs between C4-7 and accompanied by the spur formation leading to the narrowness of the spinal canal and its foramina bilaterally. ACDF were performed and complete decompression of the spinal canal and its foramina were carried out. Twin M-cages (Ammtec Inc.-Japan) were placed in the first case at C5-7 levels and single cage of Smith Robinson (SR) was placed in the second case at C5-6 levels. There were no more blurry vision, cluster headache, weakness, and numbness, immediately after surgery. To our knowledge, this is the first reported cases of ACDF, using twin M-cages and single SR cage in Indonesia, with improvement immediately after surgery. Cervical spondylosis can present with cervicobrachialgia and radiculopathy and surgical treatment produces good functional outcome.

Key words: Anterior cervical discectomy and fusion, cervical disc herniation, immediate improvement, M-cages

Introduction

The clinical symptoms of cervical disc herniation depend on the level and usually consist of radicular pain and/or myelopathy, if there is a suppression of the cord; these symptoms and signs are almost always slowly progressive. Immediate improvement of cervicobrachialgia and radiculopathy after surgery is rare; a

literature search yielded no reports of immediate improvement resulting from anterior cervical discectomy with fusion.^[1-6]

Case Reports

Case 1 Presentation

A 63-year-old woman presented with chronic neck pain spreading to the back of the head. She had a history of blurry vision concomitant with cluster head ache, especially at the back of the head and compromising her sleep-wake cycle. She also had weakness on elevation of the left shoulder grade 4 of 5, in the manual muscle test (MMT); all signs and symptoms started since past 2 years; meanwhile, her reflexes, bladder and bowel function were within normal limit. She had a history of stable radiating pain from the left shoulder to the arm for 2 years but had been fully ambulatory and functional. A cervical MRI performed during the preceding 2 years ago revealed multiple discs herniation of C5-6 and C6-7 and spur formation narrowing the foramina bilaterally but intervention was not undertaken as she had been offered but declined surgery. On

Access this article online	
Quick Response Code:	Website: www.asianjns.org
	DOI: 10.4103/1793-5482.145122

Address for correspondence:

Dr. Tjokorda G. B. Mahadewa, Neuro Surgery, University of Udayana, Division of Neurospine, Sanglah General Hospital, Kesehatan Street 1, Denpasar, Bali, Indonesia. E-mail: tjokmahadewa@hotmail.com

admission, her neck pain worsened and left muscle shoulder worsening grade 3 of 5; on this occasion, MRI [Figure 1a and b] showed the same problem, no change was visible compared with the previous MRIs. In sagittal T2-weighted imaging, MRI [Figure 1b] showed multiple bulging discs on C3-4, prominent at C5-6, and C6-7 with fusion of C4-5 body. MR myelogram of the C-spine revealed multiple cerebrospinal fluid block at the C3-4, C4-5, and C5-6 levels suggesting multiple cervical canal stenosis [Figure 2]. Finally, she agreed to be operated on; by the third day of the surgery, immediate improvement was gained.

Operative procedure

Under general anesthesia, the patient was placed supine on a fluoroscopic imaging table with her arms at her sides and shoulders taped to allow for fluoroscopic imaging. After positioning, fluoroscopic images were obtained in anteroposterior (AP) and lateral planes to determine the level of diseased disc. A standard left-sided approach was undertaken to access the anterior cervical spine at the C5-7 level. A specialized anterior spinal retractor system, Caspar retractor system, was used to assist in exposure. A complete two-level anterior discectomy was performed and preparation of the endplates was performed using ring curettes and endplate elevators and completed endplate leveling using high speed drill (Aesculap®). Lateral fluoroscopically measurement was used to determine appropriate size with regard to height and AP diameter. After the midline was determined, tapering was done and the endplates were then distracted, appropriate-sized M-cages of 7 mm cylindrical cages were inserted into C5-6 level and 6 mm into the C6-7 level, under lateral fluoroscopic guidance. Following this, AP and lateral fluoroscopy were performed to confirm the appropriate positioning and size of the cages.

Postoperative course

Postoperatively, there was no more blurry vision and cluster headache, and left shoulder muscle power improved as grade 5 of 5, immediately 3 days after surgery. A soft cervical collar was worn for 4 weeks, and the patient was allowed to move in this collar as tolerated. After this, initial 4 weeks, the soft collar was discontinued, and the patient was allowed to engage in normal activities of daily living including driving. After 6 weeks, the patient was allowed to return to all normal activities. Postoperative oral pain medication was administered as needed for 5 days; recently, no pain medication was given because the chronic neck pain and radicular pain were bearable. Intra and postoperative radiographic assessments were done; appropriate implant positions and fusion were observed [Figure 3a and b].

Case 2

Presentation

A 42-year-old woman presented with chronic neck pain especially at the back of the head. She had history of blurry vision, pain, numbness, and spasm of the right medial lower arm muscles. She had normal motor function and neurologically otherwise within normal limit. A cervical MRI

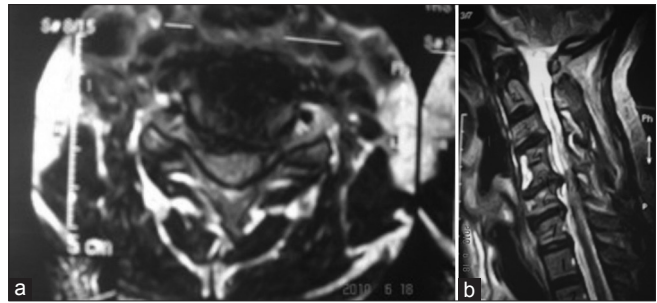


Figure 1: (a) Axial T2-weighted MRI shows bilateral posterior spur formation with narrowing of the C5-6 spinal canal; (b) sagittal T2-weighted Magnetic resonance imaging shows multiple bulging discs on C3-4, prominent at C5-6, and C6-7 with fusion of C4-5 body

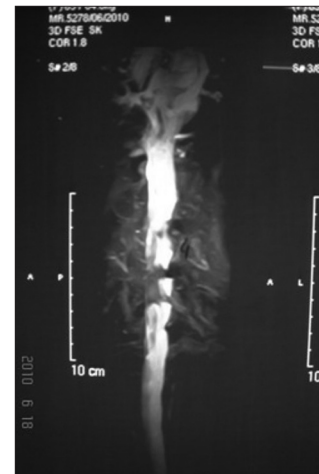


Figure 2: MR myelogram of the C-spine revealed multiple cerebrospinal fluid blocks at the C3-4, C4-5 and C5-6 levels suggesting multiple cervical canal stenosis

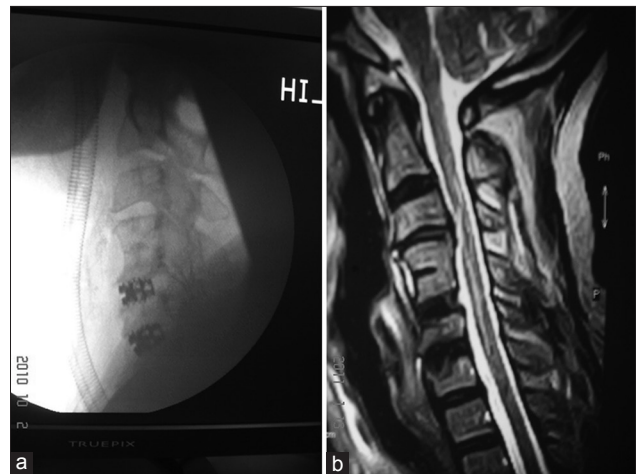


Figure 3: (a) Lateral fluoroscopy view showed an appropriate position of cylindrical M cages at C5-6 and C6-7 levels intraoperatively; (b) sagittal T2-weighted Magnetic resonance imaging 3 months after surgery showed black shadow around the cages as appropriate fusion occurred

revealed multiple discs herniation of C4-5 and C5-6, but spur formation narrowing the foramina especially on the right side of C5-6 [Figure 4a and b].

Operative procedure

The same procedure was carried out as case 1. A single level ACDF was performed on C5-6 and appropriate-sized of square 7 mm M-cages was placed into C5-6 level, under fluoroscopic guidance.

Postoperative course

Postoperatively her symptoms completely subside. A soft cervical collar was worn for 4 weeks and after that, the patient was allowed to engage normal activities. A Plain cervical x-ray performed immediate after surgery revealed good position of the titanium cage [Figure 5].

Discussion

The first published report involving application of the intervertebral disc arthroplasty was reported in 1964 by Reitz and Joubert who performed 75 cervical disc arthroplasties in patients with intractable headache and cervicobrachialgia.^[1] Cervical arthroplasty was also reported by several other authors. Arm pain was improved averagely in 46%, neck pain in 45%, and neck disability index was improved in 31% of patients.^[7-11]

Immediate improvement of cervicobrachialgia and radiculopathy after surgery is rare. In this case, timely neural decompression played an important role for patients' immediate recovery and although there was no evidence, improvement apparently resulted from cerebrospinal fluid flow resumed at the respective level in association with adequate decompression and fusion procedure. In the meantime, improvement in headache and blurry vision remained unclear. The possible mechanism that the annulus is rich in nerve endings, which is easily irritated and inflamed when a disc prolapse occurs, then spreads the pain through the muscles to the head. Rarely, blurred vision can be improved in ACDF. This is may be the result of improved blood flow to the occipital lobe, the part of the brain that controls vision, due to decompression of the disc which improved blood flow between the vertebrae through vertebral arteries.^[12]

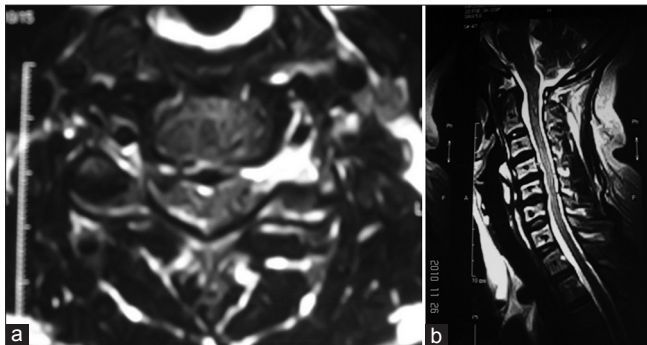


Figure 4: (a) Axial T2-weighted Magnetic resonance imaging shows right-sided posterior spur formation with narrowing of the C5-6 spinal foramina; (b) sagittal T2-weighted Magnetic resonance imaging shows multiple bulging discs on C4-6, prominent at C5-6

Previously, iliac bone was used to fulfill the intervertebral body space as a spacer but donor site pain was annoying for the patient very much. Apaceramic as another option for spacer was preferred but nonunion or breakages were frequent.^[5,7,8] The latest is using a titanium cage that is easier to use and can allow instant solid fusion. The use of these implants help to avoid additional pain in the iliac bone, avoid the risk of infection in the donor site, prevent a non-union complication and prevent graft malposition, and prevent the possibility of cord compression by bone graft movement. While ensuring the instant stability of the surgical site, keep good alignment and ensure cervical spinal fusion.^[4-6]

An intracystic medullary lesion was formed as a bad prognosticator of a permanent change. Medial type of disc herniation perhaps be one cause of this pathology since the disc material compressing the anterior spinal artery, causing permanent change due to ischemic and necrosis of the cord.^[1,3,6,7,13,14] In our patients, there were spur formation of bilaterally, bulging disc at C4-7 levels, and these lesions may have precipitated neurological deficit because narrowing canal and its foramina had presumably rendered the neural elements very fragile to minor incremental change in spur size.^[6-16] Earlier treatment had not been accepted by the first patient; symptomatic spinal stenosis should be decompressed as early in their course as possible. If only 2 years ago, the patient agreed to have surgery, may be the chronic neck pain and radicular pain could have been better.

These cases contains two simple lessons: 1) cervical spondylotic can present with cervicobrachialgia and radiculopathy, as a neurological deficit; and 2) surgical treatment is worthwhile and can result in good functional outcome, especially if the neurological deficit is predominantly due to involvements of radiculopathy as opposed to myelopathy. The only disadvantage of the ACDF is the need of titanium cages that cost high in Bali.

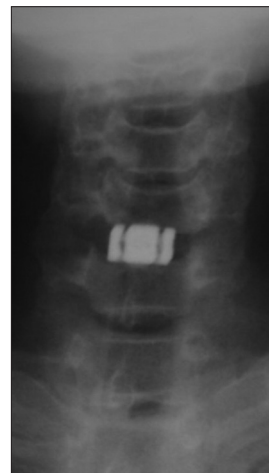


Figure 5: Anteroposterior (AP) cervical x-ray showed a good position of 7 mm square M-cage at C5-6 level

References

- Bertagnoli R, Yue JJ, Pfeifer F, Fenk-Mayer A, Lawrence JP, Kershaw T, *et al.* Early results after ProDisc-C cervical disc replacement. *J Neurosurg Spine* 2005;2:403-10.
- Bolesta MJ, Rehtine GR II, Chrin AM. One- and two-level anterior cervical discectomy and fusion: The effect of plate fixation. *Spine J* 2002;2:197-203.
- Bose B. Anterior cervical arthrodesis using DOC dynamic stabilization implant for improvement in sagittal angulation and controlled settling. *J Neurosurg Spine* 2003;98:8-13.
- Bose B. Anterior cervical instrumentation enhances fusion rates in multilevel reconstruction in smokers. *J Spinal Disord* 2001;14:3-9.
- Cherry C. Anterior cervical discectomy and fusion for cervical disc disease. *AORN J* 2002;76:998-1012.
- Emery SE. Cervical spondylotic myelopathy: Diagnosis and treatment. *J Am Acad Orthop Surg* 2001;9:376-88.
- Guyer RD, Ohnmeiss DD. Intervertebral disc prostheses. *Spine (Phila Pa 1986)* 2003;28 (Suppl 15):S15-23.
- Hilibrand AS, Fye MA, Emery SE, Palumbo MA, Bohlman HH. Increased rate of arthrodesis with strut grafting after multilevel anterior cervical decompression. *Spine (Phila Pa 1986)* 2002;27:146-51.
- Hodges SD, Humphreys SC, Eck JC, Covington LA, Van Horn ER, Peterson JE. A modified technique for anterior multilevel cervical fusion. *J Orthop Sci* 2002;7:313-6.
- Iseda T, Goya T, Nakano S, Kodama T, Moriyama T, Wakisaka S. Serial changes in signal intensities of the adjacent discs on T2-weighted sagittal images after surgical treatment of cervical spondylosis: Anterior interbody fusion versus expansive laminoplasty. *Acta Neurochir (Wien)* 2001;143:707-10.
- Sekhon LH. Cervical arthroplasty in the management of spondylotic myelopathy. *J Spinal Disord Tech* 2003;16:307-13.
- Krista N. Herniated Cervical Disc Symptoms and Vision. Available from: http://www.ehow.com/facts_6796903_herniated-cervical-disc-symptoms-vision.html#ixzz29ilJmgC1. [Last cited on 2012 Oct20].
- Wang MY, Green BA, Vitarbo E, Levi AD. Adjacent segment disease: An uncommon complication after cervical expansive laminoplasty: Case report. *Neurosurgery* 2003;53:770-3.
- Yamasaki S, Kokubun S, Ishii Y, Tanaka Y. Courses of cervical disc herniation causing myelopathy or radiculopathy: An analysis based on computed tomographic discograms. *Spine (Phila Pa 1976)* 2003;28:1171-5.
- Wigfield C, Gill S, Nelson R, Langdon I, Metcalf N, Robertson J. Influence of an artificial cervical joint compared with fusion on adjacent-level motion in the treatment of degenerative cervical disc disease. *J Neurosurg* 2002;96:17-21.
- Wigfield CC, Skrzypiec D, Jackowski A, Adams MA. Internal stress distribution in cervical intervertebral discs: The influence of an artificial cervical joint and simulated anterior interbody fusion. *J Spinal Disord Tech* 2003;16:441-9.

How to cite this article: Mahadewa Tjokorda GB, Nyoman G, Sri M, Junichi M. Anterior cervical discectomy and fusion with titanium cages for simple or multilevel herniated discs and spur of the cervical spine: Report of 2 cases and experience in Bali. *Asian J Neurosurg* 2016;11:453-4.

Source of Support: Nil, **Conflict of Interest:** None declared.