

Autoamputation of a Giant Colonic Lipoma

Hye Kyong Jeong, Sung Bum Cho, Tae Jin Seo, Kyoung Rok Lee, Wan Sik Lee, Hyun Soo Kim, and Young Eun Joo

Department of Internal Medicine, Chonnam National University Medical School, Gwangju, Korea

Most colonic lipomas are asymptomatic and need no treatment, whereas lesions larger than 2 cm can cause acute abdominal pain, changes in bowel habits, gastrointestinal bleeding, intussusception or bowel obstruction. Autoamputation of polypoid lesions in the gastrointestinal tract is indeed a rare phenomenon, and its precise mechanism remains unknown. It presumably occurs due to ischemic necrosis of the polyp by peristalsis-induced torsion or tension. Here, we report a case of autoamputation of a giant colonic lipoma in a 48-year-old man. In our case, colonoscopic examination showed a huge autoamputated mass in the rectum and a remnant long stalk in the transverse colon. The autoamputated mass in the rectum was completely removed after fragmentation using an electrosurgical snare, and the remnant long stalk located in the transverse colon was also resected safely by endoscopic snare polypectomy. To our knowledge, these endoscopic treatments for removal of an autoamputated mass and a remnant long stalk of colonic lipoma have not been reported previously. (**Gut Liver 2011;5:380-382**)

Key Words: Autoamputation; Colonic lipoma; Colonoscopic surgery

INTRODUCTION

Lipomas are soft tissue tumors deriving from the proliferation of mature adipocytes. They are found most commonly in the colon, but may develop in any part of the gastrointestinal tract.¹⁻³ Colonic lipomas are usually benign neoplasms that are asymptomatic and detected incidentally at radiological investigation, colonoscopy, surgery or autopsy. Lesions larger than 2 cm may present with abdominal pain, changes in bowel habits, bleeding, intussusception or bowel obstruction.¹⁻³

Autoamputation of polypoid lesions in gastrointestinal tract is an extremely rare phenomenon.⁴⁻¹⁰ But the precise mechanism

of the phenomenon remains unknown. It presumably occurs because of ischemic necrosis of polyp by peristalsis induced torsion or tension.⁴⁻¹⁰

We, herein, report a case of autoamputation of giant colonic lipoma in a 48-year-old man and review the literature pertaining to this condition.

CASE REPORT

A 48-year-old man was admitted to Chonnam National University Hwasun Hospital with 3-month history of abdominal discomfort caused by positional change. Three years ago, he underwent surgery for advanced gastric cancer. On admission, his abdomen was soft and non tender, but a movable huge mass was detected on rectal examination. All laboratory examinations including complete peripheral blood cell counts, blood biochemistry and carcinoembryonic antigen were within normal range. Colonoscopy revealed a huge movable mass with a diameter of 8 cm, covered by focally ulceration and hemorrhagic mucosa in the distal rectum (Fig. 1A) remnant long stalk with necrotic and ulcerative tissue the in transverse colon (Fig. 1B). We resected a remnant long stalk by a standardized technique of snare polypectomy after injection of the base with epinephrine or saline solution (Fig. 1C and D). And a huge movable mass in the rectum was completely removed after fragmentation of mass using polypectomy snare (Fig. 2A and B). There was no procedure-related complication. Histopathologic examinations of huge mass and remnant stalk revealed normal mature adipocytes compatible with those of lipoma (Fig. 3). His symptom disappeared soon after removal of colonic lipoma and he remains asymptomatic.

DISCUSSION

Most colonic lipomas are asymptomatic but may cause ab-

Correspondence to: Young Eun Joo

Department of Internal Medicine, Chonnam National University Medical School, 8 Hak-dong, Dong-gu, Gwangju 501-757, Korea

Tel: +82-62-220-6296, Fax: +82-62-225-8578, E-mail: yejoo@chonnam.ac.kr

Received on May 12, 2010. Accepted on June 7, 2010.

pISSN 1976-2283 eISSN 2005-1212 <http://dx.doi.org/10.5009/gnl.2011.5.3.380>

Hye Kyong Jeong and Sung Bum Cho contributed equally to this work.

© This is an Open Access article distributed under the terms of the Creative Commons Attribution Non-Commercial License (<http://creativecommons.org/licenses/by-nc/3.0>) which permits unrestricted non-commercial use, distribution, and reproduction in any medium, provided the original work is properly cited.

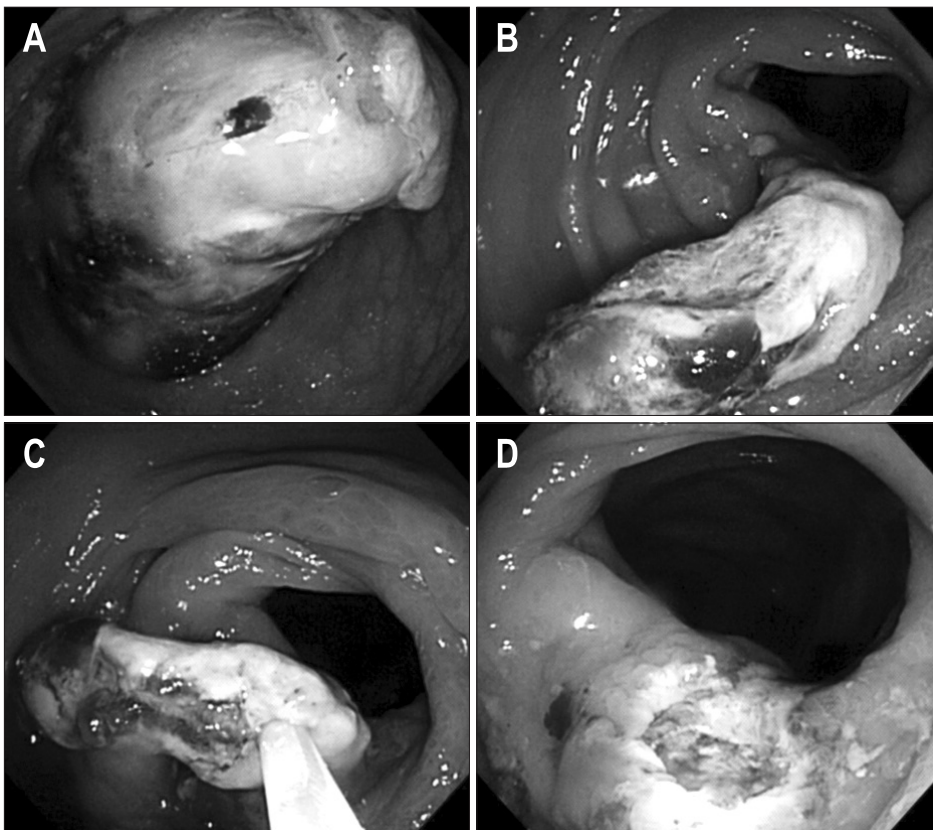


Fig. 1. Colonoscopy shows a huge, movable mass that came off the colonic wall; it is covered with focal ulcerations and hemorrhagic mucosa with a small ulcer and is located in the distal rectum (A). A remnant long stalk covered by necrotic and ulcerative tissue in the transverse colon (B). Removal of the remnant long stalk using injection-assisted snare polypectomy (C). View of the base of the ulcer defect caused by electrosurgery after stalk removal (D).

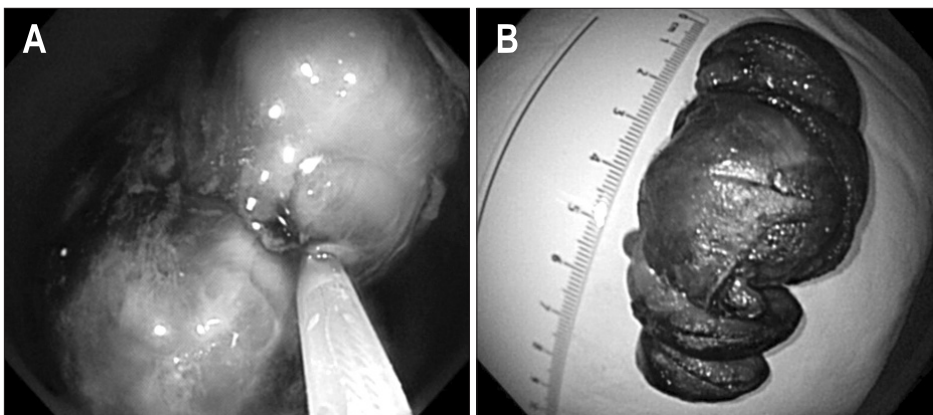


Fig. 2. The autoamputated mass is fragmented by polypectomy snare (A) and then removed (B).

dominal pain, bowel habit changes, gastrointestinal bleeding, perforation, intussusception or bowel obstruction according to size and location.¹⁻³

Autoamputation of colonic lipoma is indeed rare clinical presentation.⁴⁻¹⁰ The underlying mechanisms of this presentation are still poorly understood. Several mechanisms have been hypothesized. This unusual presentation may follow twisting of the pedicle/stalk, ulcerogenic medications, or necrosis and cancerous infiltration of the polyp base. Torsion or tension may result in twisting polyp, causing ischemic necrosis and tearing of the polyp base or amputation. Especially, pedunculated polyps may be easily distorted and are subjected to mechanical tension.⁴⁻¹⁰ In our case, colonoscopy revealed a huge movable

mass with focally ulceration and hemorrhagic mucosa in the rectum and remnant long stalk with necrotic and ulcerative tissue on the transverse colon. Therefore, although not observe the polyp just before autoamputation, we believe that the large pedunculated polyp had undergone extensive ischemic necrosis possibly as a consequence of torsion induced by peristalsis, and autoamputation had undergone.

According to previous reports, significant complications associated with autoamputation of gastrointestinal polypoid lesions include intussusceptions, gastrointestinal bleeding and perforation.⁴⁻¹⁰ Fortunately, our case had no significant complication.

The treatments of a remnant lesion after autoamputation of colonic lipoma include observation, surgical resection and

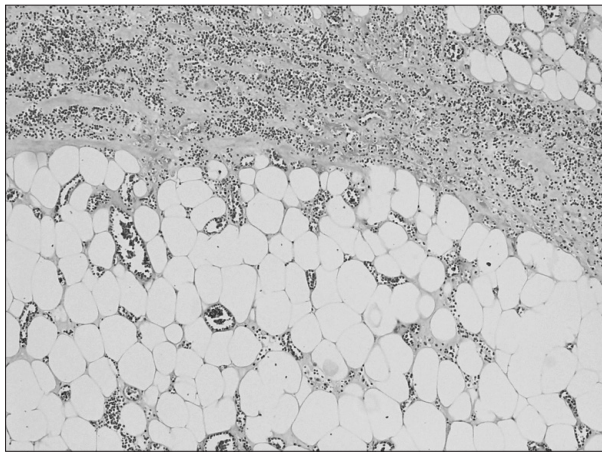


Fig. 3. Microscopic image of resected specimen shows normal mature adipocytes (H&E stain, $\times 100$).

endoscopic treatment.¹⁰ The decision to resect a remnant lesion should be based on clinical judgement about further complications and associated diseases. So, colonoscopic evaluation is necessary not only to determine the size and location of a remnant lesion but also to identify another lesions including coexistence of cancers. In our case, we resected a remnant long stalk located in transverse colon by injection-assisted snare polypectomy. And an autoamputated lipoma mass in the rectum was completely removed after fragmentation of mass using polypectomy snare through intermittent electric current carefully during 100 minutes. There was no procedure-related complication. To our knowledge, autoamputation is rare and endoscopic treatments for such lesions have been not reported before.

Although reported for successful endoscopic removal of colonic lipoma by EUS guiding, injection of epinephrine-saline mixed solution on base of lipoma and using by detachable snare, usually pedunculated type, the endoscopic resection of colonic lipomas is limited because the fatty tissue is inefficient conductor for electronic current and may result in a high rate of complications including perforation and hemorrhage.¹¹⁻¹⁴ Currently, surgical resection should be preferred when lesion is large sessile or broadly-based, can not rule out malignancy, causes significant symptoms including intussusception, or is involved in the propria muscle or serosal layer.¹⁵⁻¹⁸

In conclusion, autoamputation of gastrointestinal polypoid lesions presumably occurs because peristalsis induced torsion or tension on pedicle/stalk can cause ischemic necrosis of polyp base and subsequently sloughing of polyp. Autoamputation should be considered as a rare clinical manifestation of colonic lipoma. Injection-assisted snare polypectomy technique may be useful for removal of colonic lipoma according to clinical judgement.

CONFLICTS OF INTEREST

No potential conflict of interest relevant to this article was

reported.

REFERENCES

- Gordon RT, Beal JM. Lipoma of the colon. *Arch Surg* 1978;113: 897-899.
- McGrew W, Dunn GD. Colonic lipomas: clinical significance and management. *South Med J* 1985;78:877-879.
- Fernandez MJ, Davis RP, Nora PF. Gastrointestinal lipomas. *Arch Surg* 1983;118:1081-1083.
- Nakajima T, Kamano T, Watanabe K, Meguro H, Shibasaki K. A gastric hyperplastic polyp observed endoscopically before and after autoamputation. *Endoscopy* 2003;35:1069-1071.
- Tsakamoto Y, Nishitani H, Oshiumi Y, Okawa T. Spontaneous disappearance of gastric polyps: report of four cases. *AJR Am J Roentgenol* 1977;129:893-897.
- Misra SP, Singh SK, Thorat VK, Gulati P, Malhotra V, Anand BS. Spontaneous expulsion per rectum of an ileal lipoma. *Postgrad Med J* 1988;64:718-719.
- Stebbing WS, Staunton MD. Spontaneous expulsion of a large submucosal colonic lipoma. *J R Soc Med* 1989;82:624-625.
- Radhi JM. Lipoma of the colon: self amputation. *Am J Gastroenterol* 1993;88:1981-1982.
- Kamiya T, Morishita T, Asakura H, Munakata Y, Miura S, Tsuchiya M. Histoclinical long-standing follow-up study of hyperplastic polyps of the stomach. *Am J Gastroenterol* 1981;75:275-281.
- Zamboni WA, Fleisher H, Zander JD, Folse JR. Spontaneous expulsion of lipoma per rectum occurring with colonic intussusception. *Surgery* 1987;101:104-107.
- Kim CY, Bandres D, Tio TL, Benjamin SB, Al-Kawas FH. Endoscopic removal of large colonic lipomas. *Gastrointest Endosc* 2002;55:929-931.
- Raju GS, Gomez G. Endoloop ligation of a large colonic lipoma: a novel technique. *Gastrointest Endosc* 2005;62:988-990.
- Murray MA, Kwan V, Williams SJ, Bourke MJ. Detachable nylon loop assisted removal of large clinically significant colonic lipomas. *Gastrointest Endosc* 2005;61:756-759.
- Kaltenbach T, Milkes D, Friedland S, Soetikno R. Safe endoscopic treatment of large colonic lipomas using endoscopic looping technique. *Dig Liver Dis* 2008;40:958-961.
- Zhang H, Cong JC, Chen CS, Qiao L, Liu EQ. Submucosal colon lipoma: a case report and review of the literature. *World J Gastroenterol* 2005;11:3167-3169.
- Rogy MA, Mirza D, Berlakovich G, Winkelbauer F, Rauhs R. Submucosal large-bowel lipomas: presentation and management. An 18-year study. *Eur J Surg* 1991;157:51-55.
- Jiang L, Jiang LS, Li FY, et al. Giant submucosal lipoma located in the descending colon: a case report and review of the literature. *World J Gastroenterol* 2007;13:5664-5667.
- Bahadursingh AM, Robbins PL, Longo WE. Giant submucosal sigmoid colon lipoma. *Am J Surg* 2003;186:81-82.

A Case of Corrosive Injury-Induced Pharyngeal Stricture Treated by Endoscopic Adhesiolysis Using an Electrosurgical Knife

Sun-Young Kim*, Tae Hoon Oh*, Hwa Mi Kang*, Tae Joo Jeon*, Dong Dae Seo*, Won Chang Shin*, Won-Choong Choi*, and Jeong Hwan Choi†

Departments of *Internal Medicine and †Otorhinolaryngology, Inje University Sanggye Paik Hospital, Inje University College of Medicine, Seoul, Korea

Here, we report a case of corrosive injury-induced pharyngeal stricture in a 69-year-old female, which was successfully treated with endoscopic adhesiolysis using an electrosurgical knife. The patient had ingested sodium hydroxide in an attempted suicide, and immediate endoscopy revealed corrosive injuries of the pharynx, esophagus, and stomach. When a liquid diet was permitted, she complained of nasal regurgitation of food. Follow-up endoscopy revealed several adhesive bands and a web-like scar that did not allow passage of the endoscope into the hypopharyngeal area. For treatment of the hypopharyngeal stricture, the otolaryngologist attempted to perform an excision of the fibrous bands around the esophageal inlet using microscissors passed through an esophagoscope, but this procedure was not effective. We then dissected the mucosal adhesion and incised the adhesive bands using an electrosurgical knife. After this procedure, nasal regurgitation of food no longer occurred. To our knowledge, this case is the first report of endoscopic adhesiolysis with an electrosurgical knife in a patient with a corrosive injury-induced pharyngeal stricture. (**Gut Liver 2011;5:383-386**)

Key Words: Corrosive injury; Pharyngeal stricture; Adhesiolysis; Endoscopy; Electrosurgical knife

INTRODUCTION

The case of corrosive injury-induced pharyngeal stricture, rather than esophageal or gastric injury, was reported rarely. The treatment of corrosive burns, such as timing of endoscopy, antibiotics or steroid therapy, and possible surgical intervention, remain controversial.¹ Most reported cases of pharyngeal

strictures were treated with dilatation, laser ablation and surgery such as flap, bypass or replacement. However, there has been no report of endoscopic adhesiolysis. Herein, we report, to our knowledge, the first case of corrosive injury-induced pharyngeal stricture treated with endoscopic adhesiolysis using electrosurgical knife.

CASE REPORT

A 69-year-old female was presented with drowsy mentality following ingestion of 100 mL of sodium hydroxide for suicide attempt. On presentation, her voice was hoarse, and she was short of breath and drooling her saliva. Immediate endoscopy was performed after her mentality became alert, and it revealed diffuse edematous and inflamed oropharynx (Fig. 1A), esophagus and stomach. While fasting, total parenteral nutrition, antibiotics and proton pump inhibitors were intravenously administered. Psychiatric evaluation was also offered simultaneously.

After 2 weeks of fasting, liquid diet was permitted gradually, but she complained of swallowing difficulty. Follow-up endoscopy revealed several adhesive bands and web-like scar not allowing passage of endoscopy in the hypopharyngeal area (Fig. 1B-D). Examination through the pediatric scope and esophagogram showed healing staged ulcer with stricture in the hypopharynx and mid to lower esophagus. For the hypopharyngeal stricture, fibrous bands around esophageal inlet were excised with microscissors through the rigid esophagoscope by the otolaryngologist under the general anesthesia. However, liquid bolus swallowing still caused nasal regurgitation after the operation. Before considering the definite treatment including surgical reconstruction, we planned to treat conservatively until the pharyngoesophageal ulcers were completely turned into

Correspondence to: Tae Hoon Oh

Division of Gastroenterology, Department of Internal Medicine, Inje University Sanggye Paik Hospital, 761-1 Sanggye 7-dong, Nowon-gu, Seoul 139-707, Korea

Tel: +82-2-950-8867, Fax: +82-2-950-1955, E-mail: osbbang@paik.ac.kr

Received on May 12, 2010. Accepted on June 8, 2010.

pISSN 1976-2283 eISSN 2005-1212 <http://dx.doi.org/10.5009/gnl.2011.5.3.383>

© This is an Open Access article distributed under the terms of the Creative Commons Attribution Non-Commercial License (<http://creativecommons.org/licenses/by-nc/3.0>) which permits unrestricted non-commercial use, distribution, and reproduction in any medium, provided the original work is properly cited.

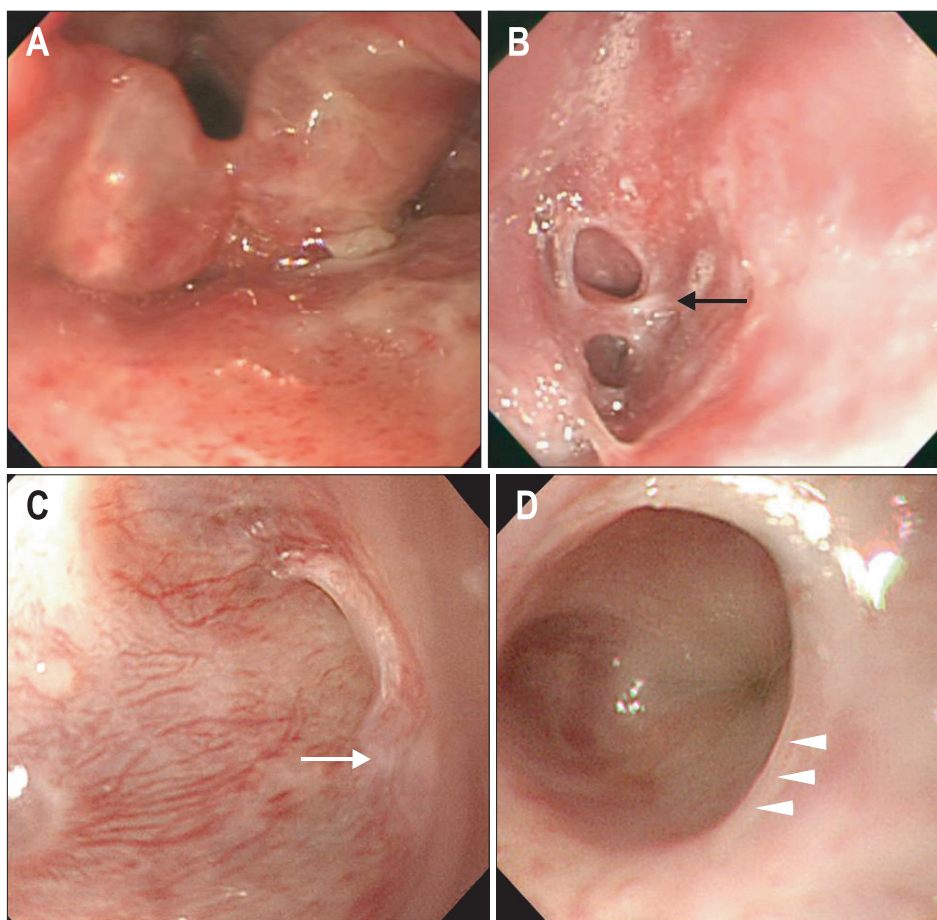


Fig. 1. (A) Endoscopy on the day of admission showing edematous mucosal swelling of the pharynx and arytenoids cartilage. (B-D) Endoscopy after 2 weeks showing several adhesive bands (black arrow), a pharyngeal wall adhesion (white arrow), and a web-like scar lesion (arrowheads) on the hypopharyngeal area. The adult endoscope can not be passed through this area.

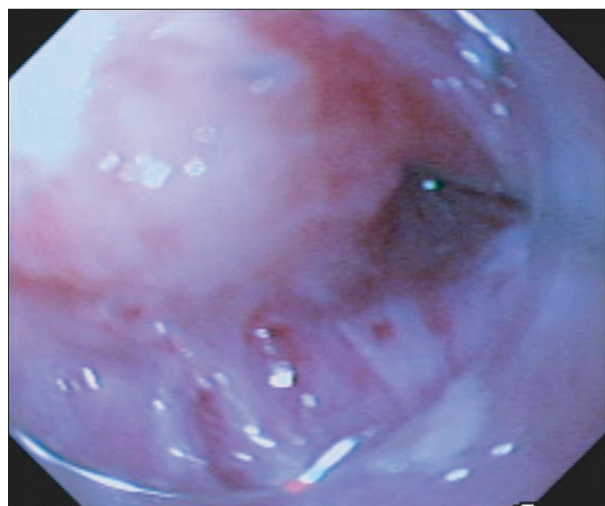


Fig. 2. Endoscopy on the day of procedure showing the tip of the transparent cap that is pushed toward the scar tissue to define the wall plane that is to be incised.

scars.

Four months later, follow-up examination showed persistent luminal strictures of hypopharynx and segmental stricture of lower esophagus without active ulcer, sparing relatively upper esophagus. Because of ineffectiveness of the prior operation,

we decided to perform the endoscopic adhesiolysis with electrosurgical knife for the treatment of hypopharyngeal stricture. While in the supine position and under the general anesthesia, cap-fitted endoscopy (GIF XQ260; Olympus, Tokyo, Japan) was performed. To recognize the wall plane of hypopharynx to be incised, the tip of the transparent cap was pushed toward the scar tissue (Fig. 2). Under the direct visualization of adhered plane through a transparent cap, incisions for the dissection of mucosal adhesion and adhesive bands were performed using IT knife-2 (insulated-tip diathermic knife-2; Olympus Medical Systems, Tokyo, Japan) and Flex knife (fixed flexible snare; Kachu Technology, Seoul, Korea) in ENDOCUT I mode, effect 3, duration 2, interval 4 (VIO 300D; ERBE, Tübingen, Germany) (Fig. 3). We progressed the procedure until the scope was able to be passed into the upper esophageal lumen, and there was no immediate and delayed complication. Following procedure, the patient was given intravenous infusion of proton pump inhibitors and broad-spectrum antibiotics for five consecutive days, starting from the day of procedure, and was kept nil by mouth. The patient did not receive steroid therapy during any stage of her treatment. After three days of fasting, follow-up endoscopic examination showed that luminal narrowing was more improved (Fig. 4), and nasal regurgitation of food was disappeared after the procedure. For the resolution of lower

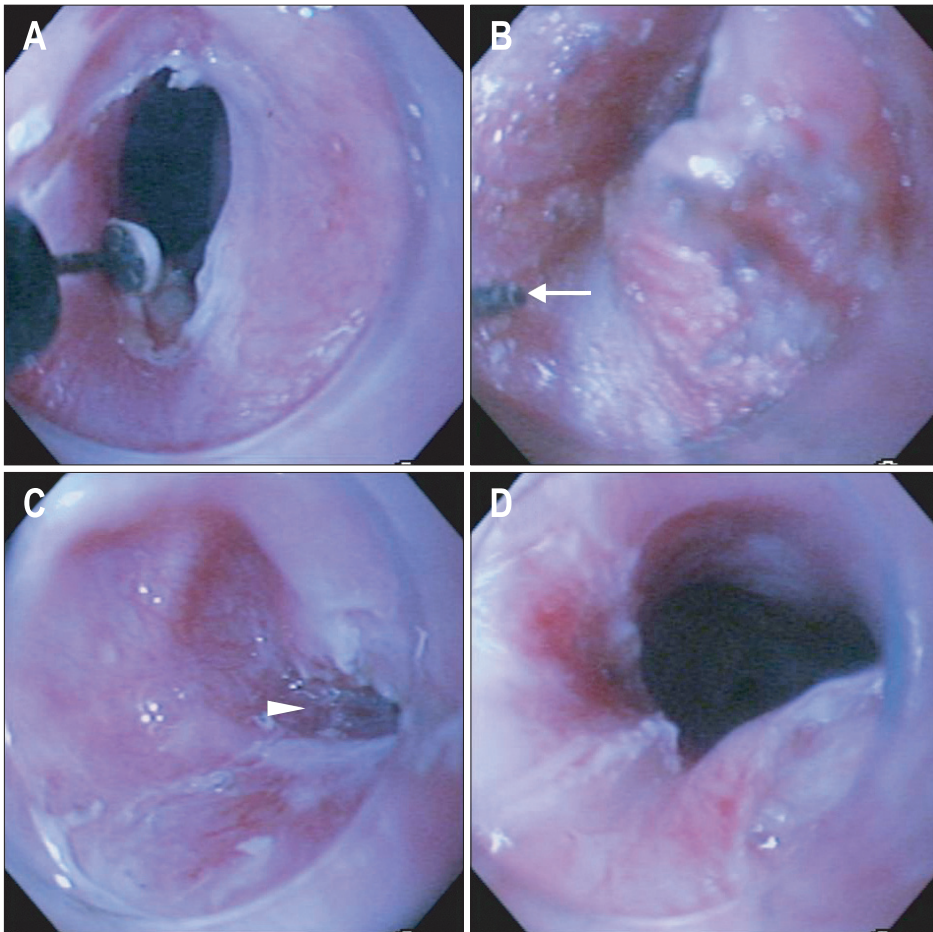


Fig. 3. (A, B) Endoscopy on the day of procedure showing that incision therapy for the dissection of the mucosal adhesion and adhesive bands of the hypopharynx is performed with an IT knife and a Flex knife (arrow) through the cap-fitted endoscopy. (C, D) Endoscopy showing that the adhesive band is incised (arrowhead) and that the lumen is widened.

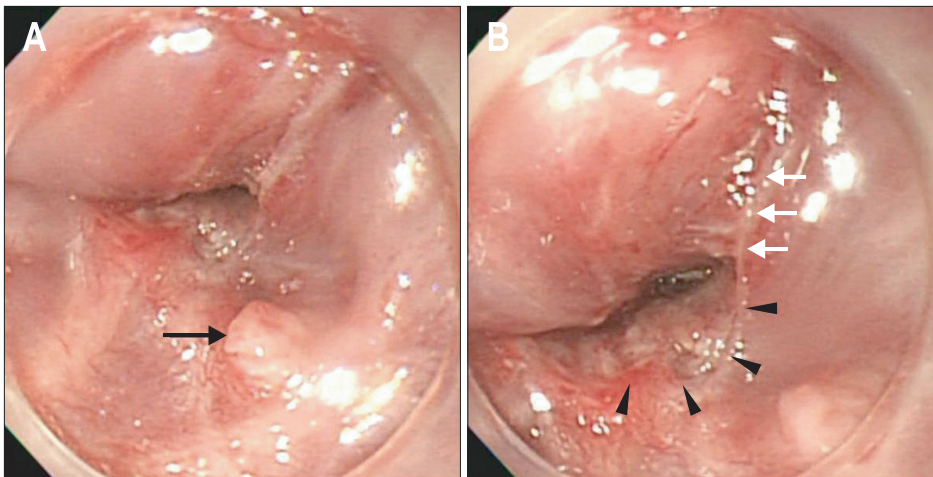


Fig. 4. Follow-up endoscopy after the procedure showing (A) the remnant stump of the adhesive band (arrow) and (B) the dissected linear scar tissue (arrowheads) with a partial remnant of the adhered scar tissue (arrows).

esophageal stricture, balloon dilatation and bougienations were performed twice. She became tolerable with soft diet. She is visiting the outpatient departments and is tolerable with soft diet 11 months after the event.

DISCUSSION

Ingestions of corrosive agents produce a spectrum of injury

of upper aero-gastrointestinal tract. Esophageal injury is the most common and accounts for 70%, gastric injury for 20%, and pharyngeal injury for 10%.² The reason of the less common incidence of clinically significant injury of oropharynx, like our case, is not clear, but we could assume that rapid swallowing of corrosive agent resulted in relatively insignificant hypopharyngeal injury compared to upper esophageal injury.

The stricture of gastrointestinal tract is one of the significant

late complications of corrosive injury. Surgical correction is generally undertaken if multiple, repeated dilations are unsuccessful, but localized, segmental narrowing can be corrected by various methods depending on the length and severity of the stricture.³ For pharyngeal strictures, surgically managed cases including flap⁴ and colon interposition or pull-up of stomach with or without stenting^{5,6} were reported, and there were experiences of local treatments such as laser ablations⁷ and balloon dilation and/or bougienation.⁸ However, there has been no report of endoscopic incision therapy using electrosurgical knife.

The electrosurgical knife has been effectively used to perform the endoscopic submucosal dissection of gastrointestinal tumors, and to treat esophageal rings.^{9,10} Some cases of post operative esophageal strictures which were effectively treated with electrosurgical knife have been also reported.^{11,12} Our case shows the electrosurgical knife could be also useful and effective for treating corrosive injury-induced pharyngeal stricture.

There were several points to be considered to perform this procedure safely and effectively. It is important to discriminate the wall plane to be incised. In case of severe adhesions, the wall plane might not be identified clearly when pushing with cap-fitted endoscope and it might hinder the safe incision. Moreover, it might be technically difficult to perform in case of diffusely extended stricture to upper esophagus, rather than in case of relatively isolated hypopharyngeal stricture. Lastly this procedure should be done under the general anesthesia to avoid the fluctuation of pharyngeal wall provoked by gag and airway reflex.

More validated data would be needed to discuss technical feasibility and specific indication for endoscopic adhesiolysis of pharyngeal stricture. We think endoscopic adhesiolysis with electrosurgical knife is one of the minimally invasive local treatment modalities. Therefore, it could be tried to treat corrosive injury-induced pharyngeal stricture for either palliative or definite treatment, especially before considering the difficult surgical management.

CONFLICTS OF INTEREST

No potential conflict of interest relevant to this article was reported.

REFERENCES

1. Keh SM, Onyekwelu N, McManus K, McGuigan J. Corrosive injury to upper gastrointestinal tract: still a major surgical dilemma. *World J Gastroenterol* 2006;12:5223-5228.
2. Jobe BA, Hunter JG, Peters JH, Esophagus and diaphragmatic hernia. In: Brunicaardi FC, Andersen DK, Billiar TR, et al, eds. *Schwartz's principles of surgery*. 9th ed. New York: McGraw-Hill, 2010:877-879.
3. Mcquone SJ, Eisele DW. Management of pharyngeal and esophageal stenosis. *Oper Tech Otolaryngol Head Neck Surg* 1997;8:231-241.
4. Ananthakrishnan N, Parthasarathy G, Maraju NK, Kate V. Sterno-cleidomastoid muscle myocutaneous flap for corrosive pharyngo-esophageal strictures. *World J Surg* 2007;31:1592-1596.
5. Wu MH, Tseng YT, Lin MY, Lai WW. Esophageal reconstruction for hypopharyngoesophageal strictures after corrosive injury. *Eur J Cardiothorac Surg* 2001;19:400-405.
6. Yannopoulos P, Lytras D, Paraskevas KI. Esophageal reconstruction with intraoperative dilatation of the hypopharynx for the management of chronic corrosive esophageal strictures: a technical tip. *Eur J Cardiothorac Surg* 2006;30:940-942.
7. Goldfarb A, Gross M, Sichel JY, Eliashar R. Severe pharyngeal stenosis after caustic ingestion. *Isr Med Assoc J* 2002;4:305.
8. Piotet E, Escher A, Monnier P. Esophageal and pharyngeal strictures: report on 1,862 endoscopic dilatations using the Savary-Gilliard technique. *Eur Arch Otorhinolaryngol* 2008;265:357-364.
9. Kakushima N, Fujishiro M. Endoscopic submucosal dissection for gastrointestinal neoplasms. *World J Gastroenterol* 2008;14:2962-2967.
10. DiSario JA, Pedersen PJ, Bichiş-Canoutas C, Alder SC, Fang JC. Incision of recurrent distal esophageal (Schatzki) ring after dilation. *Gastrointest Endosc* 2002;56:244-248.
11. Brandimarte G, Tursi A. Endoscopic treatment of benign anastomotic esophageal stenosis with electrocautery. *Endoscopy* 2002;34:399-401.
12. Lee TH, Lee SH, Park JY, et al. Primary incisional therapy with a modified method for patients with benign anastomotic esophageal stricture. *Gastrointest Endosc* 2009;69:1029-1033.