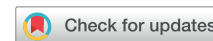

# Scleroderma Renal Crisis in a Systemic Sclerosis With Anti-PM/Scl Antibodies



Marine Jacquier<sup>1</sup>, Christiane Mousson<sup>1</sup>, Jean-Michel Rebibou<sup>1</sup>, Daniela Lakomy<sup>2</sup>, Stéphanie François<sup>2</sup>, Laurent Martin<sup>3</sup>, Mathilde Funes De La Vega<sup>3</sup> and Mathieu Legendre<sup>1</sup>

<sup>1</sup>Department of Nephrology, François Mitterrand Hospital, Dijon, France; <sup>2</sup>Department of Immunology, François Mitterrand Hospital, Dijon, France; and <sup>3</sup>Department of Pathology, François Mitterrand Hospital, Dijon, France

**Correspondence:** Mathieu Legendre, Department of Nephrology, François Mitterrand Hospital, Dijon, France, 5 boulevard Jeanne d'Arc, 21000 Dijon, France. E-mail: [mathieu.legendre@chu-dijon.fr](mailto:mathieu.legendre@chu-dijon.fr)

Received 20 May 2019; revised 25 June 2019; accepted 1 July 2019; published online 11 July 2019

*Kidney Int Rep* (2019) 4, 1499–1502; <https://doi.org/10.1016/j.ekir.2019.07.002>

© 2019 International Society of Nephrology. Published by Elsevier Inc. This is an open access article under the CC BY-NC-ND license (<http://creativecommons.org/licenses/by-nc-nd/4.0/>).

## INTRODUCTION

Systemic sclerosis (SSc) is a multisystem autoimmune fibrosing disease affecting the connective tissue. It particularly affects the skin, notably with skin thickening, but SSc is also characterized by the involvement of many other organs, such as the lungs, the gastrointestinal tract, or the musculoskeletal tissues. One of the most life-threatening situations associated with SSc is scleroderma renal crisis (SRC), which classically associates a hypertensive crisis with oliguric acute kidney injury due to an acute thrombotic microangiopathy.<sup>1,2</sup> In some cases, the diagnosis of this disease can be delayed by atypical presentation such as systemic sclerosis sine scleroderma and/or the presence of rare antibodies. Here we report a case of a histologically confirmed SRC in a patient with systemic sclerosis sine scleroderma and anti-PM/Scl antibodies (Table 1).

## CASE PRESENTATION

A 45-year-old woman was referred to our nephrology intensive care department for nonoliguric acute kidney injury. She did not report any preexisting medical condition except an allergy to animal fur; however, Raynaud syndrome had appeared 5 months before presentation and she was taking telmisartan (40 mg per day) for hypertension. She also had 2 episodes of frontal sinusitis, 2 and 6 weeks before admission. Both episodes had been treated with nasal corticosteroids, prednisolone 40 mg, and pristnamycin 1500 mg per day for 6 days. Two days after recovery from the second episode, she presented with multiple skin lesions on her face (especially on the cheekbones), lips, and arms. Those lesions collapsed with pressure and

filled when the pressure was released. The general practitioner ordered blood tests that revealed kidney injury, and the patient was subsequently referred to our hospital.

On admission, the physical examination revealed blood pressure 222/134 mm Hg, asthenia, odynophagia, and macules that remained stable (Figure 1a). Her skin, especially on the hands and face, was supple without signs of thickening. The rest of the physical examination was unremarkable. Laboratory tests at presentation revealed an acute kidney injury with thrombocytopenia and mechanical hemolytic anemia (Table 2). A renal ultrasound showed normal-sized kidneys with no evidence of urinary outflow obstruction or arterial stenosis.

In view of the concordant clinical history, the recent intake of corticosteroids, and possible malignant hypertensive attack with thrombotic microangiopathy, an SRC was suspected. First, SSc was confirmed with biological analyses. There was a high level of plasma antinuclear antibodies (1:1280) with nucleolar staining. Although the antibodies typically associated with renal crisis were negative, notably anti-RNA polymerase III, the antibodies for anti-PM/Scl 100 were positive (Table 2). A subsequent renal biopsy was concordant with the diagnosis of SRC and malignant hypertension. Optical microscopy showed severe vascular lesions in the medium-size vessels that resembled fibrointimal sclerosis with a narrowing of the vascular lumen. Glomerular alterations were observed (ischemic glomeruli, Figure 1b). In contrast to atypical hemolytic-uremic syndrome, the lesions were not predominantly found in the glomerular vessels.<sup>1</sup> Lesions like capillary wall thickening, double contour, or thrombosis of the capillary lumen were not observed in the glomeruli.

**Table 1.** Teaching points

1	Consider a diagnosis of scleroderma renal crisis even without skin involvement if the rest of the clinical picture is concordant.
2	Obtain results for the complete panel of associated antibodies.
3	Consider a diagnosis of scleroderma renal crisis in cases of acute kidney injury associated with corticosteroid administration.

Immunofluorescence analysis did not find IgA, IgG, IgM, or C3 glomerular deposits.

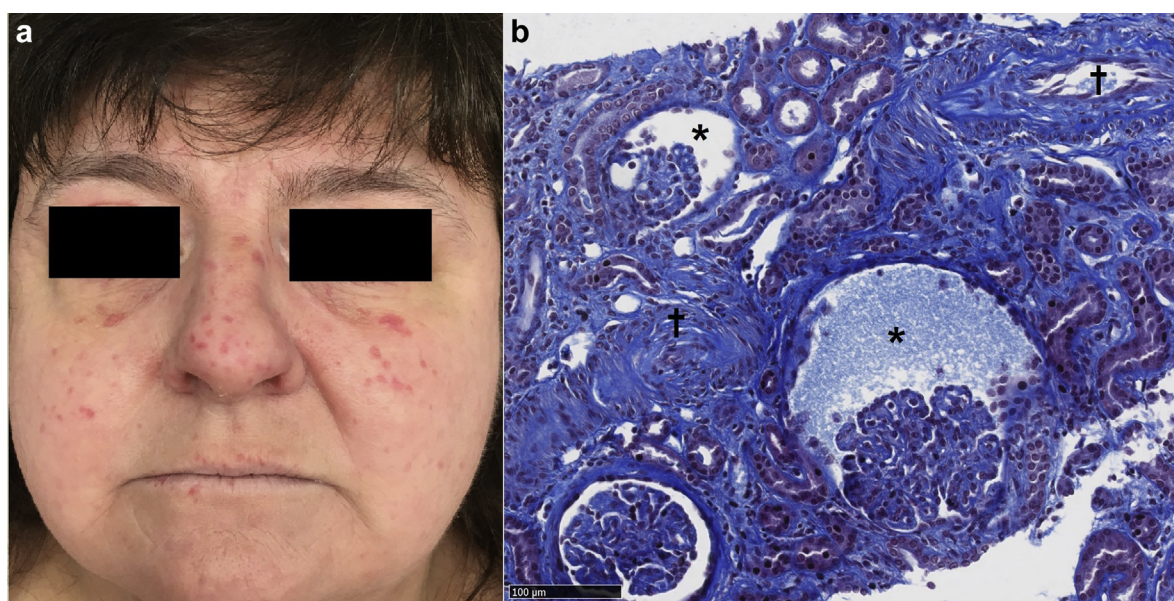
Several megacapillaries were found with nailfold capillaroscopy and, although the patient did not suffer from sclerodactyly, further examinations showed other organ involvement associated with SSc. Barrett esophagus and pericarditis without pulmonary hypertension were respectively observed on gastroscopy and cardiac ultrasonography. No interstitial pulmonary fibrosis was observed on thoracic computed tomography.

One day after admission, the patient was treated with increasing doses of angiotensin-converting enzyme inhibitor (Captopril). Blood pressure was normalized at day 3, and the evolution consisted in a progressive decrease of serum creatinine levels (Figure 2). One year after diagnosis, the serum creatinine level was at 2.1 mg/dl and proteinuria was imperceptible (Table 2). Regarding the involvement of other organs, esophageal discomfort had been successfully treated with proton pump inhibitors and the cardiac examinations were back to normal. Pulmonary function tests remained normal. The skin lesions were stable with no signs of sclerodactyly or calcinosis; however, the patient was suffering from intermittent arthralgia, particularly in the ankles.

## DISCUSSION

This case combined the atypical association of rare clinical and biological manifestations. To our knowledge, this is the first case of SRC associated with SSc sine scleroderma and anti-PM/Scl antibodies.

First, our patient experienced one of the most severe complications of SSc: SRC. This manifestation complicates the course of 4% to 10% patients diagnosed with SSc.<sup>2</sup> Although SRC can occur with normal blood pressure, it usually begins with abrupt-onset hypertension associated with oliguric acute kidney injury and thrombotic microangiopathy. One of the well-known risk factors for this life-threatening disease is, like in our case, the recent administration of systemic corticosteroid therapy (approximately 60% of patients with SRC).<sup>2,3</sup> The other potential risk factors would be disease duration, diffuse and rapidly progressive skin thickening, new cardiac events, and new anemia.<sup>2</sup> The pathogenesis of SRC is still not fully understood, but pathology analyses have made it possible to describe some of its mechanisms.<sup>2</sup> Like in our patient, the classic features include lesions similar to those observed in malignant hypertension.<sup>1</sup> However, it should be highlighted that without any cutaneous symptoms, other forms of thrombotic microangiopathy, like hemolytic-uremic syndrome, should be excluded by clinical and biological aspects. The initially observed vascular lesions appear to be attributable to myxoid intimal thickening. The narrowing of the vascular lumen leads to reduced blood flow, juxtaglomerular apparatus vascular hyperplasia, and to an activation of the renin-angiotensin-aldosterone system, inducing



**Figure 1.** Skin examination and renal histology. (a) Patient's face. Multiple erythematous skin lesions (telangiectasia). (b) Kidney biopsy revealing an increase in arterial mucoid fibrointimal thickness of 2 small vessels (†), and ischemic glomeruli (\*) retracted on the vascular pole. Masson's Trichrome, original magnification  $\times 250$ .

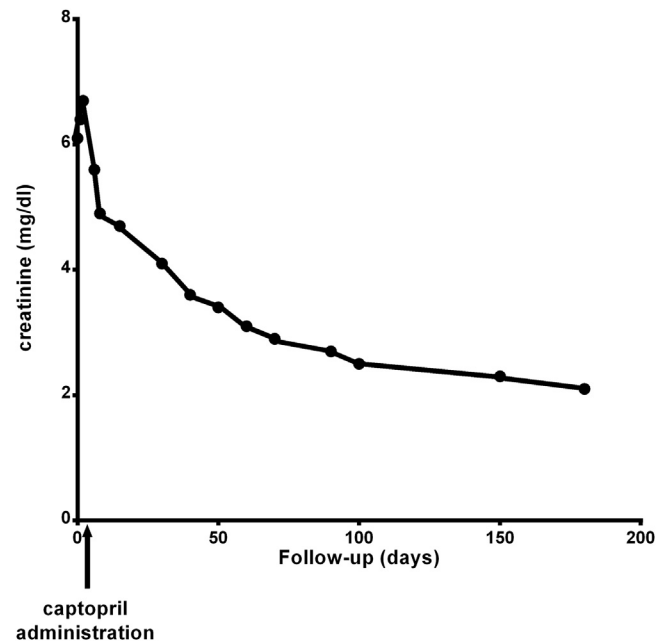
**Table 2.** Laboratory values

Test	6 months before	At admission	Normal range
Hemoglobin (g/dl)	12.0	7.8	11.5–16.0
Blood platelets ( $10^9/l$ )	250	124	150–250
Leukocytes ( $10^9/l$ )	5.0	4.9	4.0–10.0
Sodium (mmol/l)	138	135	135–145
Potassium (mmol/l)	4.2	3.6	3.5–5.4
Bicarbonate (mmol/l)	26	20	20–29
Creatinine (mg/dl)	0.8	6.1	0.6–1.0
Blood urea nitrogen (mmol/l)	5.0	17.4	2.5–6.4
Albumin (g/l)	–	39	34–50
Troponin ( $\mu\text{g/ml}$ )	–	0.29	<0.10
C-reactive protein (mg/l)	5	19	<5
Haptoglobin (g/l)	–	<0.08	0.30–2.00
Lactate dehydrogenase (U/l)	–	427	84–246
CPK (U/l)	–	73	30–190
C3 (g/l)	–	1.4	0.8–1.6
C4 (g/l)	–	0.3	0.1–0.4
Hematuria (cells/ml)	–	43,000	<25,000
Proteinuria (g/24 h)	–	1.3	<0.2
Ferritin ( $\mu\text{g/l}$ )	–	345	8–252
Antinuclear antibodies	–	1:1280	<1:160
Ds-DNA	–	<10	<10
Extractable nuclear antigen	–	Negative	Negative
Anti-Sjogren syndrome A (Ro) Ab	–		
Anti-Sjogren syndrome B (La) Ab	–		
Anti-ribonucleoprotein Ab	–		
Anti-Smith Ab	–		
Anti-scleroderma Ab	–		
Anti-Jo-1 Ab	–		
Anti-PCNA Ab	–		
Anti-ribosomal P Ab	–		
Anti-RNA polymerase III Ab	–	Negative	Negative
Anti-PM/Scl 100 Ab	–	Positive	Negative
C-ANCA	–	Negative	Negative
P-ANCA	–	Negative	Negative
Anti-GBM Ab	–	Negative	Negative
HBV sAg, sAb, cAb	–	Not detected	Not detected
HCV Ab	–	Not detected	Not detected
HIV Ag/Ab	–	Not detected	Not detected

–, not available; Ab, antibodies; Ag, antigen; C-ANCA, cytoplasmic antineutrophil cytoplasmic antibodies; CPK, creatine phosphokinase; Ds-DNA, double-stranded DNA; GBM, glomerular basement membrane; HBV, hepatitis B virus; HCV, hepatitis C virus; P-ANCA, perinuclear antineutrophil cytoplasmic antibodies.

high blood pressure. High blood pressure exacerbates the damage to the renal blood vessels and intensifies disease progression. Then, it appears to induce muscular infiltration and collagen deposits in the vessels, and fibrosis, which gives the “onion skin” appearance. The glomeruli also may undergo changes, such as ischemic lesions with retraction to the vascular pole and sclerosis.<sup>1–4</sup> The prognosis of SRC, and in particular the progression to end-stage renal disease, mainly depends on how quickly treatment is initiated. To break the vicious circle, SRC treatment focuses on blood pressure control with angiotensin-converting enzyme inhibitors, which should be rapidly increased to the maximum dose. On failure, and if severe acute kidney injury has developed, dialysis can be initiated.<sup>3</sup>

Unlike kidney impairment, skin manifestations are common in SSc. The most striking skin abnormalities

**Figure 2.** Time course of serum creatinine.

are skin thickening with lesions such as sclerodactyly, but SSc also is associated with numerous other skin lesions (for instance finger ulcerations, Raynaud syndrome, or telangiectasia).<sup>5</sup> In SSc, skin involvement can be categorized as diffuse cutaneous sclerosis or, more rarely, limited cutaneous sclerosis.<sup>6</sup> Here, the presence of telangiectasia and Raynaud syndrome with no skin thickening were suggestive of SSc sine scleroderma, which is even more unusual (approximately 5%) but probably underdiagnosed.<sup>7,8</sup> It can be described as a total or partial absence of skin thickening, with the occurrence of internal organ involvement and serologic abnormalities. In our case, additional organ impairment was mainly cardiac and digestive.

This presentation also highlights the importance of extending the antibody panel in the absence of classical antibodies (i.e., anti-TOPO1, anti-centromere, anti-RNA polymerase III, or anti-U3 RNP) if SSc is suspected. In addition to the antibodies historically associated with SSc, new antibodies have recently emerged and made it possible to rectify false negative diagnoses in several cases. Among them, anti-PM/Scl antibodies (2% prevalence), which also are observed in polymyositis, dermatomyositis, and overlap syndrome, can be associated with typical SSc manifestations.<sup>7,8</sup> In our patient, the presence of a high titer of antinuclear antibodies with nucleolar staining motivated the screening for these anti-PM/Scl antibodies. Usually, when SSc appears with anti-PM/Scl antibodies, it involves younger patients with more skeletal muscle disease, pulmonary fibrosis, and calcinosis.<sup>7</sup> Unlike in our patient, anti-PM/Scl antibodies are unusually associated with SRC. In a recent study of 1417 patients



with scleroderma, only 4% presented SSc and none of the patients with SSc had anti-PM/Scl antibodies. Bruni *et al.*<sup>9</sup> observed 14 SRCs among 80 patients with SSc and anti-PM/Scl antibodies (5.7%). In this work, steroid treatment did not appear to be a risk factor; nevertheless, our case strongly suggests a cause-effect relationship.

There are other antibodies that should be checked in the absence of the conventional antibodies: anti-U1 RNP (6%–7%), which are associated with a limited cutaneous subset, mixed connective tissue disease and arthritis; anti-Th/To (2%–5%), which are associated with interstitial lung disease and pulmonary hypertension; anti-NOR90/hUBF, which are associated with rheumatoid involvement and Sjogren syndrome; and anti-Ku and anti-RuvBL1/2, which are both associated with myositis.<sup>8</sup>

Our patient has been stable for more than 1 year without a need for immunosuppressive therapy. Esophageal discomfort has not reappeared, and she has not suffered from any other organ failure. Although normal renal function has not been recovered, her progress is encouraging. Considering the benefit of specific therapies with angiotensin-converting enzyme inhibitors, a diagnosis of SRC never should be delayed. This report highlights the fact that even without skin thickening and/or antibodies usually associated with SSc, SRC should not be immediately excluded in cases of abrupt-onset hypertensive crisis with associated kidney failure.

## DISCLOSURE

All of the authors declared no competing interests.

## REFERENCES

1. Batal I, Domsic TR, Medsger TA Jr. Scleroderma renal crisis: a pathology perspective. *Int J Rheumatol*. 2010;2010:543704.
2. Mouthon L, Bussone G, Berezne A, et al. Scleroderma renal crisis. *J Rheumatol*. 2014;41:1040–1048.
3. Teixeira L, Mouton L, Mahr A, et al. Mortality and risk factors of scleroderma renal crisis: a French retrospective study of 50 patients. *Ann Rheum Dis*. 2008;67:110–116.
4. Gordon SM, Stitt RS, Nee RJ, et al. Risk factors for future scleroderma renal crisis at systemic sclerosis diagnosis. *J Rheumatol*. 2019;46:85–92.
5. Diab S, Dostrovsky N, Hudson M, et al. Systemic sclerosis sine scleroderma: a multicenter study of 1417 subjects. *J Rheumatol*. 2014;41:2179–2185.
6. Kucharz EJ, Kopeć-Mędrek M. Systemic sclerosis sine scleroderma. *Adv Clin Exp Med*. 2017;26:875–880.
7. Koschik RW, Fertig N, Lucas MR, et al. Anti-PM/Scl antibody in patients with systemic sclerosis. *Clin Exp Rheumatol*. 2012;30(2 Suppl 71):S12.
8. Stochmal A, Czuwara J, Trojanowska M, et al. Antinuclear antibodies in systemic sclerosis: an update [e-pub ahead of print]. *Clin Rev Allergy Immunol*. <https://doi.org/10.1007/s12016-018-8718-8>. Accessed July 26, 2019.
9. Bruni C, Lages A, Patel H, et al. Resolution of paraneoplastic PM/Scl-positive systemic sclerosis after curative resection of a pancreatic tumour. *Rheumatology (Oxford)*. 2017;56:317–318.