Fuchs' Endothelial Corneal Dystrophy and RNA Foci in Patients With Myotonic Dystrophy

V. Vinod Mootha,[1,2] Brock Hansen,[1] Ziye Rong,[1] Pradeep P. Mammen,[3] Zhengyang Zhou,[2] Chao Xing,[2,4,5] and Xin Gong[1]

[1]Department of Ophthalmology, University of Texas Southwestern Medical Center, Dallas, Texas, United States
[2]McDermott Center for Human Growth and Development, University of Texas Southwestern Medical Center, Dallas, Texas, United States
[3]Department of Internal Medicine, University of Texas Southwestern Medical Center, Dallas, Texas, United States
[4]Department of Bioinformatics, University of Texas Southwestern Medical Center, Dallas, Texas, United States
[5]Department of Clinical Sciences, University of Texas Southwestern Medical Center, Dallas, Texas, United States

Correspondence: V. Vinod Mootha, University of Texas Southwestern Medical Center, 5323 Harry Hines Boulevard, Dallas, TX 75390, USA; Vinod.Mootha@UTSouthwestern.edu.

Submitted: June 5, 2017
Accepted: August 15, 2017

Citation: Mootha VV, Hansen B, Rong Z, et al. Fuchs' endothelial corneal dystrophy and RNA foci in patients with myotonic dystrophy. *Invest Ophthalmol Vis Sci*. 2017;58:4579–4585. DOI:10.1167/iovs.17-22350

Purpose. The most common cause of Fuchs' endothelial corneal dystrophy (FECD) is an intronic CTG repeat expansion in *TCF4*. Expanded CUG repeat RNA colocalize with splicing factor, muscleblind-like 1 (MBNL1), in nuclear foci in endothelium as a molecular hallmark. Myotonic dystrophy type 1 (DM1) is a neuromuscular disorder caused by a CTG repeat expansion in the 3′-untranslated region (UTR) of *DMPK*. In this study, we examine for RNA-MBNL1 foci in endothelial cells of FECD subjects with DM1, test the hypothesis that DM1 patients are at risk for FECD, and determine prevalence of *TCF4* and *DMPK* expansions in a FECD cohort.

Methods. Using FISH, we examined for nuclear RNA-MBNL1 foci in endothelial cells from FECD subjects with DM1. We examined 13 consecutive unrelated DM1 patients for FECD using slit-lamp and specular microscopy. We genotyped *TCF4* and *DMPK* repeat polymorphisms in a FECD cohort of 317 probands using short-tandem repeat and triplet repeat-primed PCR assays.

Results. We detected abundant nuclear RNA foci colocalizing with MBNL1 in endothelial cells of FECD subjects with DM1. Six of thirteen DM1 patients (46%) had slit-lamp and specular microscopic findings of FECD, compared to 4% disease prevalence ($P = 5.5 \times 10^{-6}$). As expected, 222 out of 317 (70%) FECD probands harbored *TCF4* expansion, while one subject harbored *DMPK* expansion without prior diagnosis of DM1.

Conclusions. Our work suggests that DM1 patients are at risk for FECD. *DMPK* mutations contribute to the genetic burden of FECD but are uncommon. We establish a connection between two repeat expansion disorders converging upon RNA-MBNL1 foci and FECD.

Keywords: Fuchs' endothelial corneal dystrophy, myotonic dystrophy, triplet repeat expansion, DMPK, nuclear RNA foci

Fuchs' endothelial corneal dystrophy (FECD, Mendelian Inheritance in Man [MIM] 136800) is an age-related degenerative disorder of the endothelium resulting in corneal edema and loss of vision. FECD affects 4% of whites over the age of 40 in the United States[1] and is the leading indication for corneal transplantation.[2] The corneal endothelium, the inner postmitotic hexagonal monolayer of cells responsible for maintenance of stromal dehydration, is prone to oxidative damage, apoptosis, and premature senescence in FECD.[3–9] The basement membrane of the endothelium, Descemet's membrane, becomes diffusely thickened and develops focal excrescences termed guttae that are visible with slit-lamp and specular biomicroscopy.[10] FECD is a clinical diagnosis based on the presence of confluent central guttae on slit-lamp microscopy. Progressive loss of central endothelial cell density results in corneal edema, scarring, and loss of vision.

FECD can be inherited as an autosomal dominant trait with genetic heterogeneity.[11] Rare heterozygous mutations in collagen, type VIII, alpha 2 gene (*COL8A2*, MIM 120252) cause an early-onset corneal endothelial dystrophy.[12] Other genes including solute carrier family 4, sodium borate transporter, member 11 (*SLC4A11*, MIM 610206), transcription factor 8 (*TCF8*, MIM 189909), lipoxygenase homology domains 1 (*LOXHD1*, MIM 613267), and ATP/GTP binding protein-like 1 (*AGBL1*, MIM 615523) collectively account for a small fraction of adult-onset FECD cases.[13–20] Genome-wide association studies of adult-onset FECD have implicated transcription factor 4 (*TCF4*, MIM 602272) and more recently KN motif- and ankyrin repeat domain–containing protein 4 (*KANK4*, MIM 614612), laminin gamma-1 (*LAMC1*, MIM150290), and Na^+, K^+ transporting ATPase, beta-1 polypeptide (*ATP1B1*, MIM 182330), with the *TCF4* locus noted to have a predominant effect.[21,22]

CTG triplet repeat expansions in the third intron of *TCF4* (CTG18.1 locus) are the most common genetic cause of adult-onset FECD cases in the United States[23,24] *TCF4* is a conserved class I basic helix-loop-helix (bHLH) transcription factor that binds to the canonical E-box promoter sequences of target

Copyright 2017 The Authors

This work is licensed under a Creative Commons Attribution-NonCommercial-NoDerivatives 4.0 International License.

Table 1. Demographic Information and Microscopy Results of DM1 Patients

			Krachmer Grade		CCT, µm		Cell Density, Cells/mm^2		CV		Hexagonal Cells %				
Subject	Age	Sex	OD	OS	OD	OS	OD	OS	OD	OS	OD	OS	*TCF4* Alleles	*DMPK* Alleles	FECD Status*
VVM683†	52	F	2	1	NA	NA	NA	NA	NA	NA	NA	NA	19, 20	5, >100	Y
VVM685	54	F	3	3	571	573	2941	3067	36	38	60	58	13, 19	12, >100	Y
VVM686‡	66	F	3	3	571	557	2857	2358	31	36	59	48	19, >100	11, >100	Y
VVM687	59	M	1	1	604	610	2915	2959	42	39	54	57	13, 28	12, 176	N
VVM688	59	F	4	3	603	599	2632	2545	36	29	48	63	13, 16	5, >150	Y
VVM689	42	M	0	1	581	587	2646	2793	28	34	66	57	13, 13	5, >100	N
VVM691	43	M	0	1	567	578	3185	3205	25	28	71	65	17, 26	13, >100	N
VVM692	42	M	1	1	634	626	2915	3205	27	28	68	72	13, 13	12, >100	N
VVM693	69	M	3	3	585	589	2247	2577	36	34	52	54	16, 17	13, 89	Y
VVM694	42	F	5	4	602	611	2519	2320	35	36	43	70	17, 29	10, ~140	Y
VVM695	66	M	1	1	605	600	2545	2551	32	29	56	62	13, 28	5, 229	N
VVM697	50	F	0	0	546	537	2967	2817	29	36	67	69	16, 19	14, >100	N
VVM700	60	M	1	1	593	587	4132	4000	35	38	56	54	16, 39	5, >100	N

CCT, central corneal thickness based on ultrasound pachymetry; CV, coefficient of variation of endothelial cell size; F, female; M, male; NA, not available; N, no; Y, yes.

* Inclusion criterion for FECD is Krachmer grade of 2 or greater in the more severely affected eye by slit-lamp microscopy.

† Ultrasound pachymetry and specular microscopy were not performed on subject VVM683.

‡ This subject harbored both *DMPK* and *TCF4* triplet repeat expansions. Southern blot analysis of expanded *DMPK* alleles presented where available.

genes.[25,26] The CTG18.1 locus was discovered in 1997 by the repeat expansion detection assay, with expanded alleles of greater than 37 CTG repeats found to be unstable and present in 3% of subjects in Caucasian pedigrees.[27] *TCF4* expansions of greater than 40 CTG repeats confer significant risk for the development of FECD with an odds ratio (OR) of 32.3 in whites.[24] The expanded allele was shown to cosegregate with complete penetrance in 52% of 29 white FECD families and with incomplete penetrance in an additional 10% of these families.[24] Transethnic studies have been performed in Singapore-Chinese, Indian, and Japanese documenting the association of the triplet repeat expansion with FECD in nonwhite populations.[28–30]

Myotonic dystrophy type 1 (DM1) is a paradigm for genetic disorders caused by CTG expansions. In DM1, the expansion is within the 3′-untranslated region (UTR) of the dystrophia myotonia protein kinase gene.[31,32] The expanded DM1 repeat RNA associates with the splicing factor muscleblind-like 1 (MBNL1) in nuclear foci that can be visualized by fluorescent in situ hybridization (FISH) and that are a molecular hallmark for disease.[33,34] Association of MBNL1 with mutant RNA affects the cellular pool of free MBNL1 and triggers missplicing of some MBNL1 target genes in affected brain, muscle, and heart tissues.[34] Accumulation of expanded CUG repeat RNA nuclear foci[35] with colocalization with MBNL1 and missplicing of target genes[36] has been recently reported in endothelial cells of FECD subjects with the *TCF4* repeat expansion.

Gattey et al.[37] reported FECD in four DM1 subjects including a mother–daughter pair. No molecular studies were performed and because these are both common disorders, it can be concluded that additional studies were warranted. In this study, we explored the association between DM1 and FECD. We detected the presence of nuclear RNA-MBNL1 foci in endothelial cells from an organ donor whose corneas were found to be unsuitable for transplantation for the findings of FECD. Surprised that the donor did not harbor a *TCF4* expansion, we hypothesized correctly that the subject harbored a CTG repeat expansion in the 3′ UTR of the *DMPK* gene and subsequently confirmed a clinical diagnosis of DM1. Additionally, we tested the hypothesis that DM1 patients are at risk for FECD and determined prevalence of *TCF4* and *DMPK* triplet repeat expansions in a University of Texas Southwestern (UTSW) FECD cohort.

Methods

Subjects

The study was approved by the UTSW Institutional Review Board (IRB) and conducted in adherence to the tenets of the Declaration of Helsinki.

We obtained corneas from a 54-year-old white male organ donor with "muscular dystrophy" who had succumbed to a cardiac arrest from the eye bank at UT Transplant Services. Certified eye bank technicians had examined the corneas using Cellchek EB-10 specular microscopy (Konan Medical, Irvine, CA, USA) and detected FECD findings of confluent endothelial guttae and decreased endothelial cell density, and therefore found them to be unsuitable for transplantation. Additional control tissues were also obtained from the eye bank.

To test the hypothesis that patients with DM1 are at risk for FECD, we examined 13 consecutive unrelated patients with an established diagnosis of DM1 over the age of 40 (mean = 54.8, standard deviation [SD] = 10.3) from the UTSW Neuromuscular Cardiomyopathy Clinic (Table 1). Clinical genetic testing results for DM1 were obtained where available. All DM1 subjects were white. All subjects underwent an eye examination including slit-lamp microscopy by a cornea fellowship-trained ophthalmologist (VVM). Inclusion criterion for FECD was the presence of slit-lamp examination findings of grade 2 or higher on the modified Krachmer FECD grading scale: grade 0: no central guttae; grade 1: up to 12 scattered central guttae; grade 2: ≥12 scattered central guttae; grade 3: 1- to 2-mm confluent central guttae; grade 4: 2–5 mm of confluent central guttae; grade 5: >5-mm confluent central guttae without stromal edema; grade 6: >5-mm confluent central guttae with stromal edema.[13] Specular microscopy of the corneal endothelium was performed by certified ophthalmic technicians using a Konan SL Specular Microscope (Konan Medical). The endothelial cell density and morphology parameters were calculated by the center method using the microscope's automated software. We obtained central corneal thickness

Table 2. A Comparison* of FECD and Non-FECD Subjects Among DM1 Patients†

Characteristic	FECD	Non-FECD	*P* Value‡
Sex, No. (%)			
M	1 (16.7)	6 (85.7)	2.9×10^{-2}
F	5 (83.3)	1 (14.3)	
Age, mean (SD), y	57.4 (10.0)	52.1 (10.0)	3.7×10^{-1}
Krachmer grade, mean (SD)	3.1 (1.0)	0.7 (0.5)	1.7×10^{-6}
CCT, mean (SD), μm	586.1 (17.7)	589.6 (27.3)	7.0×10^{-1}
Cell density, mean (SD), cells/mm^2	2066.3 (273.4)	3059.6 (478.6)	7.8×10^{-3}
CV, mean (SD)	34.7 (2.7)	32.1 (5.2)	1.3×10^{-1}
Hexagonal cells % (SD)	55.5 (8.1)	62.4 (6.6)	3.9×10^{-2}

* Both eyes of each subject were used for comparison.

† Ultrasound pachymetry and specular microscopy were not performed on subject VVM683.

‡ Fisher's exact test was performed when comparing sex distribution, and 2-sample *t*-test was performed when comparing other variables.

Table 3. Demographic Information of FECD Cohort

Characteristic	Without *TCF4* Expansion *n* = 95*	With *TCF4* Expansion *n* = 222*	*P* Value†
Sex, No. (%)			
M	20 (21.1)	80 (36.0)	8.2×10^{-3}
F	75 (78.9)	139 (62.6)	
Ethnicity, No. (%)			
Caucasian	71 (75.3)	204 (95.8)	2.5×10^{-7}
African	20 (21.3)	6 (2.8)	
Other‡	3 (3.2)	3 (1.4)	
Age, mean (SD), y	67.9 (9.6)	69.6 (10.1)	1.5×10^{-1}
Krachmer grade, mean (SD)	5.1 (1.2)	5.8 (0.6)	4.3×10^{-7}

* There are a few missing values in some variables.

† Fisher's exact test was performed when comparing sex and ethnicity distribution, and 2-sample *t*-test was performed when comparing other variables.

‡ Including Asian, Hispanic, and mixed ancestry.

(CCT) measurements using a Corneo-gage Plus ultrasonic pachymeter (Sonomed, New Hyde Park, NY, USA). The average of three separate measurements was used as the CCT.

Then, we screened a cohort of 317 FECD probands recruited at a cornea referral practice at UTSW for the prevalence of the *DMPK* and *TCF4* triplet repeat expansions. All subjects had undergone an eye examination including slit-lamp biomicroscopy by a cornea fellowship-trained ophthalmologist (VVM) and were found to have slit-lamp examination findings of grade 2 or higher on the modified Krachmer FECD grading scale. The triplet repeat expansions in *DMPK* and *TCF4* were genotyped using a combination of short-tandem repeat (STR) and triplet repeat-primed polymerase chain reaction (TP-PCR) assays.

FISH

Corneal endothelial cells from an organ donor with FECD were examined for the presence for expanded CUG repeat RNA foci. FISH with chemically synthesized $(CAG)_6CA$-5′ Texas red-labeled 2-*O*-methyl RNA 20-mers probe (8 μL at 20 ng/μL) (Integrated DNA Technologies, Coralville, IA, USA) and staining with 4′,6-diamidino-2-phenylindole, H-1500 DAPI (Vector Labs, Burlingame, CA, USA) of endothelial cells from this subject and controls were performed as we previously reported.[35] Cells were imaged at ×60 magnification using a Widefield Deltavision pDV fluorescence microscope (GE Healthcare, Chicago, IL, USA). Images were processed using ImageJ software (https://imagej.nih.gov/ij/). Fifteen representative images were analyzed to derive percentage of cells with RNA foci. After performing the FISH assay, we stained the cells with anti-MBNL1 antibody as previously described.[22]

Genotyping of DMPK and TCF4 Triplet Repeat Polymorphisms

DNA from the organ donor corneal tissue was extracted with Trizol reagent (Life Technologies, Carlsbad, CA, USA) per the manufacturer's protocol. Genomic DNA was extracted from leukocytes of peripheral blood samples from each study subject using Autogen Flexigene (Qiagen, Valencia, CA, USA).

We genotyped the *TCF4* CTG18.1 triplet repeat polymorphism using a combination of STR analysis and TP-PCR assay and examined the amplicons with the ABI 3730XL DNA analyzer (Applied Biosystems, Foster City, CA, USA) as previously reported.[24] We genotyped the CTG triplet repeat locus at the 3′ UTR of *DMPK* with STR analysis and TP-PCR using locus-specific primers (Supplementary Table 1).

Results

Abundant discrete, punctate nuclear RNA foci were identified in 85% of the endothelial cells examined from the subject (16-1348) with FECD and muscular dystrophy (Fig. 1A). Nuclear RNA foci were detected in 61% of the endothelial cells from the subject (16-3407) with FECD and *TCF4* triplet repeat expansion included as a positive control (Fig. 1A). Additionally, we demonstrated colocalization of the splicing factor MBNL1 with the nuclear RNA foci (Fig. 1B) in the subject (16-1348) with FECD and muscular dystrophy. Genotyping results indicated that the subject (16-1348) did not have a *TCF4* triplet expansion but rather had homozygous alleles with 12 CTG repeats at the CTG18.1 locus (Supplementary Fig. S1). Then, we hypothesized that the subject (16-1348) harbored a *DMPK* triplet repeat expansion. STR analysis detected one allele at the *DMPK* locus with 10 CTG repeats, and the TP-PCR assay detected an expansion at the second allele (Supplementary Fig. S1). A certified eye bank technician contacted the family of the organ donor for additional past medical history and learned that a clinical diagnosis of DM1 for the subject (16-1348) had been made 12 years prior at the age of 42. The subject's medical diagnosis had been confirmed with clinical genetic testing which showed evidence of a trinucleotide repeat expansion in the myotonic dystrophy alleles using Southern blot analysis. The CTG repeat numbers of the two *DMPK* alleles were 10 and approximately 300, respectively.

Then, we examined 13 consecutive unrelated patients with an established diagnosis of DM1 for findings of FECD. Our genotyping results confirmed that all DM1 patients had *DMPK* triplet repeat expansions; one DM1 subject harbored both *DMPK* and *TCF4* triplet repeat expansions (Table 1). We observed that 6 out of 13 (46%) of the DM1 subjects had slit-lamp examination findings of grade 2 or higher on the modified Krachmer FECD grading scale, which is significantly higher than the 4% prevalence of FECD in the US population over the age 40 (P value $= 5.5 \times 10^{-6}$). The female DM1 subjects were more likely to be affected with FECD than their male counterparts (P value $= 2.9 \times 10^{-2}$; Table 2), compatible with the known female bias for FECD.[38,39] There was no significant

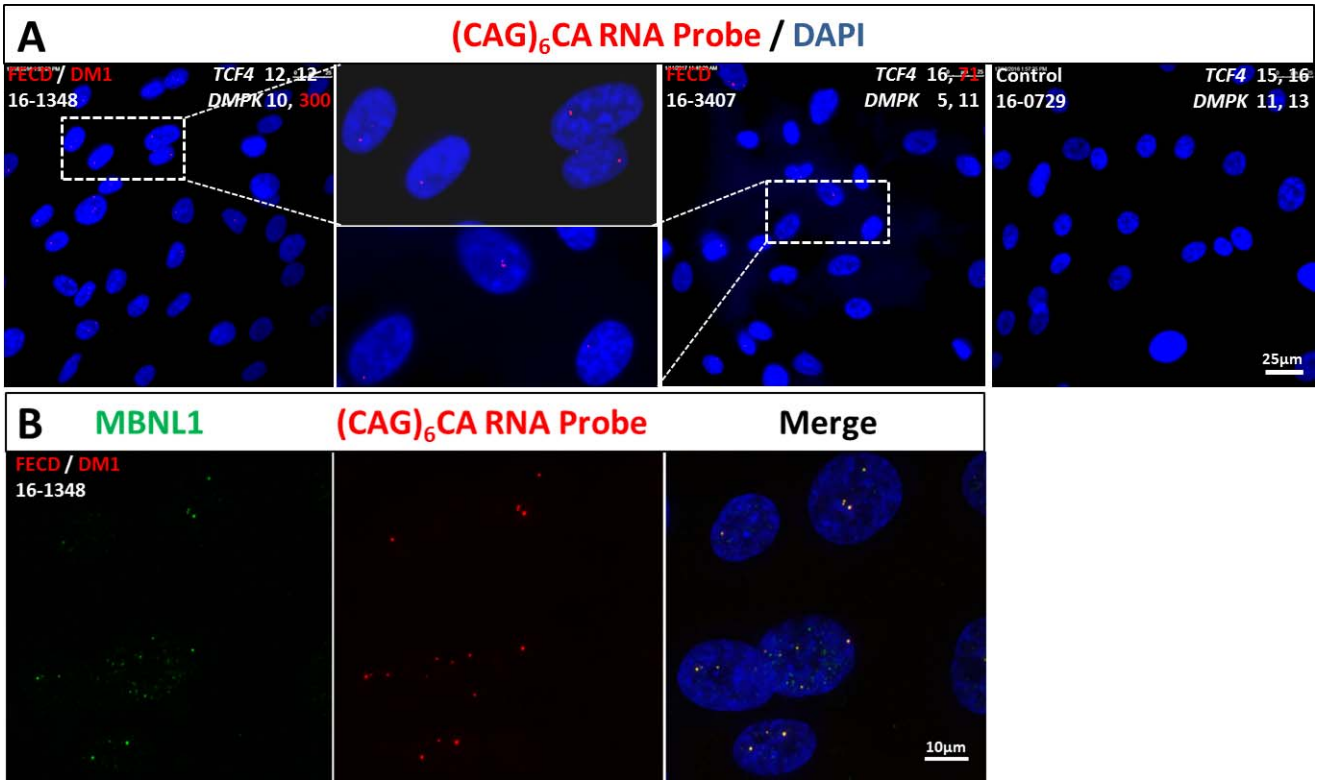

Figure 1. Nuclear RNA foci accumulate and colocalize with MBNL1 in corneal endothelial cells with triplet repeat expansion in *DMPK* gene. (**A**) FISH with a $(CAG)_6CA$-5′ Texas red-labeled 2-*O*-methyl RNA 20-mers probe (Integrated DNA Technologies) on endothelial cells of FECD/DM1 subject (16-1348) with an expanded *DMPK* allele with 300 CTG repeats revealed punctate, nuclear RNA foci (*red*). RNA foci were present in endothelial cells from a FECD subject (16-3407) with an expanded *TCF4* allele with 71 CTG repeats and absent in cells from unaffected subject (16-0729) without the *DMPK* and *TCF4* repeat expansions. DNA was stained with DAPI (*blue*). The *scale bar* represents 25 µm. (**B**) Colocalization of MBNL1 with the expanded CUG repeat nuclear foci. After hybridization with RNA probe (*red*), cells were stained with anti-MBNL1 antibody (*green*) and DAPI (*blue*). The *scale bar* represents 10 µm.

difference between the two groups in terms of age and CCT (Table 2). Specular microscopy confirmed the presence of guttae in all FECD subjects diagnosed by slit-lamp examination (Fig. 2). Based on specular microscopy, the eyes of FECD subjects had a lower endothelial cell density (P value $= 7.8 \times 10^{-3}$) and lower percentage of hexagonal cells (P value $= 3.9 \times 10^{-2}$) compared to the eyes of non-FECD subjects, which is compatible with the increased cellular senescence seen in FECD.

Next, we examined prevalence of the *TCF4* and *DMPK* triplet repeat polymorphisms in the UTSW FECD cohort and found that 222 of 317 (70%) probands harbored *TCF4* expansions. As we had previously reported, the subjects with the *TCF4* triplet repeat expansion had a greater clinical severity of disease in comparison to their counterparts without the expansion (Table 3).[40] Out of 95 FECD subjects who did not harbor an expansion in *TCF4*, only 1 subject was identified with a *DMPK* triplet repeat expansion with alleles of 15 and 71 CTG repeats (Supplementary Fig. S2). She had undergone cataract surgery and corneal transplantation in both eyes for Krachmer grade 6 severity of FECD. Review of her past medical history revealed no prior clinical diagnosis of myotonic dystrophy.

Discussion

Ocular findings frequently associated with DM1 include ptosis, cataracts, reticular macular dystrophy, and peripheral pigmentary retinopathy.[41] Our results indicate that FECD may also be a common ocular finding, with 46% of our DM1 patients affected by FECD. A previous clinical study of DM1 subjects with a mean age of 38 (SD = 13.3) years found no abnormalities in corneal endothelial cell density or morphology using specular morphology.[42] We intentionally screened DM1 subjects over the age of 40 years because FECD is a disease of middle age. Additional studies on larger DM1 cohorts are warranted to validate our findings on the penetrance of the FECD trait with expansions in the *DMPK* triplet repeat polymorphism and to determine any sex bias. Further studies are also warranted to assess FECD clinical severity and any positive correlation to CTG repeat number as previously reported with *TCF4* triplet repeat expansions.[40] Nearly all DM1 subjects develop a cataract.[41] Patients with comorbid FECD should be counseled that they are at increased risk of corneal edema that may require corneal transplantation at the time of or after their cataract surgery.

We found a subject in our UTSW FECD cohort with a *DMPK* expansion without a prior clinical diagnosis of DM1. Individuals with small *DMPK* expansions have a mild DM1 phenotype. They may be asymptomatic except for cataracts and lead active lives with normal life spans.[43]

Our observations confirm that *TCF4* triplet repeat expansions are the predominant cause of FECD. *DMPK1* triplet repeat expansions, however, can also contribute to the overall genetic burden of this disease and provide a different molecular and clinical perspective on the pathogenesis of

Investigative Ophthalmology & Visual Science

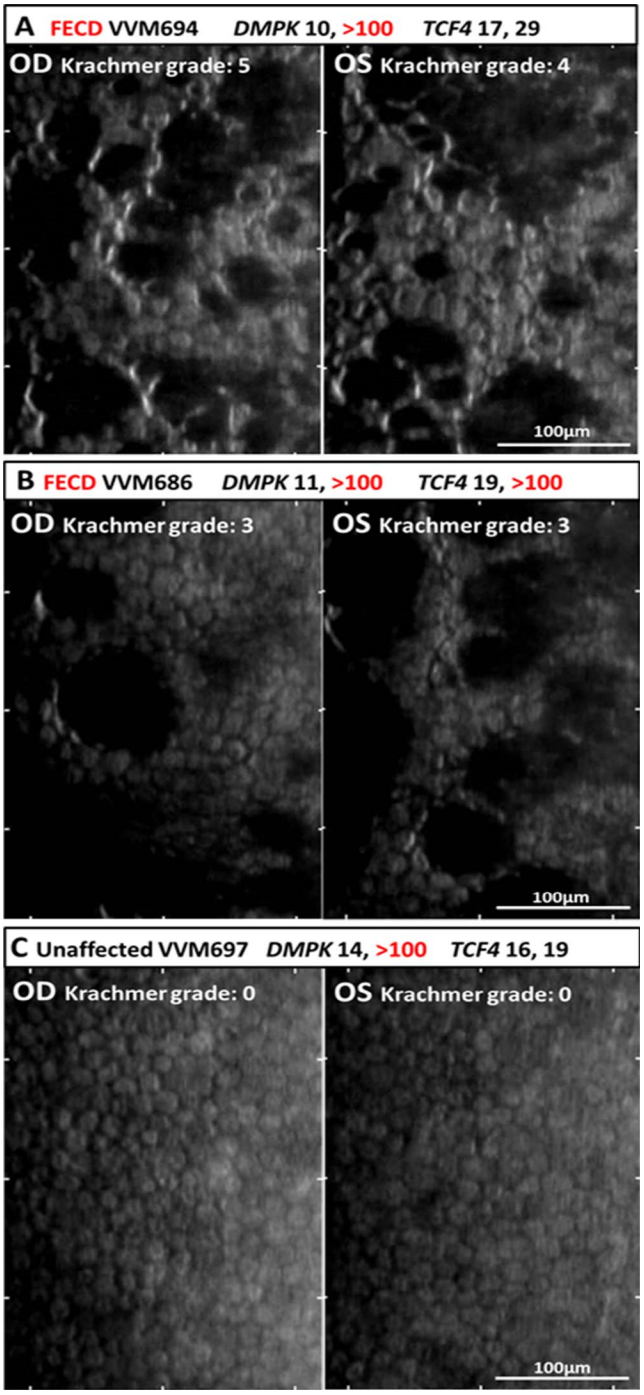

Figure 2. Specular microscopy of corneal endothelium in myotonic dystrophy type 1 patients. (**A**) Specular microscopy of the central endothelium of DM1 subject with FECD Krachmer grade of 5 OD (oculus dexter, right eye) and 4 OS (oculus sinister, left eye) revealed typical FECD findings including numerous focal dark spots corresponding to corneal guttae, increased cellular polymorphism (loss of normal hexagonal pattern), and polymegathism (variation in cell size). Photomicrograph images represent a surface area of 400 by 220 µm. *Bar* represents 100 µm. (**B**) Specular imaging of endothelium of DM1 subject harboring both *DMPK1* and *TCF4* triplet repeat expansions with FECD Krachmer grade of 3 in each eye. Numerous focal dark spots corresponding to corneal guttae are shown in OD. Large dark areas corresponding to confluence of the corneal guttae and marked loss of endothelial cell density and grotesque morphology of remaining cells are shown in OS. (**C**) Specular images of DM1 subject without FECD showing absence of guttae and normal endothelial cell density and morphology in both eyes.

FECD. Several genetic diseases are caused by CTG expansions, and the link between molecular mechanism and disease is best characterized for DM1. As a result, DM1 offers insights that may prove valuable for FECD, where we are in the early stages of understanding mechanism and therapeutic development.

DM1 and FECD, however, are not identical diseases even though they both originate from noncoding CTG expansions. The *DMPK* expansion in DM1 results in a multiorgan disease that involves various tissues in the eye including lens, retina, and corneal endothelium. In contrast, the *TCF4* repeat expansion appears to affect the corneal endothelium without any clinically apparent sequela to other ocular tissues or bodily organs. We speculate that differences in triplet repeat length and/or tissue specific factors define the phenotypic spectrum of these two triplet repeat expansions.

We report here that mutant expansions in *DMPK* and *TCF4* share important similarities, including (1) nuclear foci that contain expanded CUG repeats, (2) association of foci with MBNL1 protein, and (3) an ability to cause FECD. These results suggest that the triplet expansions in both *DMPK* and *TCF4* may cause the same corneal endothelial tissue phenotype of FECD through shared molecular mechanisms that are triggered by toxic gain-of-function RNA. These findings provide a new window on the molecular pathogenesis of FECD and suggest that the DM1 paradigm can be used to facilitate therapeutic development.

Acknowledgments

The authors thank the patients for their participation in this study and also thank Aimee Tilley and Bryan Gallerson for study coordination efforts. We thank eye bank technician Christina Megedyuk and eye bank director Donna Drurry at Transplant Services at the University of Texas Southwestern for their efforts. We thank the collaborating corneal specialists Wayne R. Bowman, James P. McCulley, Steven Verity, Sandhya Iyer, Brad Bowman, and Walter Beebe. We thank David R. Corey, PhD, for helpful discussions on the project and manuscript.

Supported by National Institutes of Health Grants R01EY022161 (VVM) and P30EY020799, and an unrestricted grant from Research to Prevent Blindness, New York, New York, USA. Support also came from National Institutes of Health Grants U54AR068791 (PPM) and UL1TR001105 (CX).

Disclosure: **V.V. Mootha**, None; **B. Hansen**, None; **Z. Rong**, None; **P.P. Mammen**, None; **Z. Zhou**, None; **C. Xing**, None; **X. Gong**, None

References

1. Lorenzetti DW, Uotila MH, Parikh N, Kaufman HE. Central cornea guttata. Incidence in the general population. *Am J Ophthalmol*. 1967;64:1155–1158.
2. *2015 Eye Banking Statisical Report*. Washington, DC: Eye Bank Association of America; 2016.
3. Chi HH, Teng CC, Katzin HM. Histopathology of primary endothelial-epithelial dystrophy of the cornea. *Am J Ophthalmol*. 1958;45:518–535.
4. Laing RA, Leibowitz HM, Oak SS, Chang R, Berrospi AR, Theodore J. Endothelial mosaic in Fuchs' dystrophy. A qualitative evaluation with the specular microscope. *Arch Ophthalmol*. 1981;99:80–83.
5. Bigar F. Specular microscopy of the corneal endothelium. Optical solutions and clinical results. *Dev Ophthalmol*. 1982; 6:1–94.

Investigative Ophthalmology & Visual Science

6. Borderie VM, Baudrimont M, Vallee A, Ereau TL, Gray F, Laroche L. Corneal endothelial cell apoptosis in patients with Fuchs' dystrophy. *Invest Ophthalmol Vis Sci*. 2000;41:2501–2505.
7. Li QJ, Ashraf MF, Shen DF, et al. The role of apoptosis in the pathogenesis of Fuchs endothelial dystrophy of the cornea. *Arch Ophthalmol*. 2001;119:1597–1604.
8. Matthaei M, Zhu AY, Kallay L, Eberhart CG, Cursiefen C, Jun AS. Transcript profile of cellular senescence-related genes in Fuchs endothelial corneal dystrophy. *Exp Eye Res*. 2014;129:13–17.
9. Jurkunas UV, Bitar MS, Funaki T, Azizi B. Evidence of oxidative stress in the pathogenesis of fuchs endothelial corneal dystrophy. *Am J Pathol*. 2010;177:2278–2289.
10. Hogan MJ, Wood I, Fine M. Fuchs' endothelial dystrophy of the cornea. 29th Sanford Gifford Memorial lecture. *Am J Ophthalmol*. 1974;78:363–383.
11. Magovern M, Beauchamp GR, McTigue JW, Fine BS, Baumiller RC. Inheritance of Fuchs' combined dystrophy. *Ophthalmology*. 1979;86:1897–1923.
12. Biswas S, Munier FL, Yardley J, et al. Missense mutations in COL8A2, the gene encoding the alpha2 chain of type VIII collagen, cause two forms of corneal endothelial dystrophy. *Hum Mol Genet*. 2001;10:2415–2423.
13. Zhang C, Bell WR, Sundin OH, et al. Immunohistochemistry and electron microscopy of early-onset fuchs corneal dystrophy in three cases with the same L450W COL8A2 mutation. *Trans Am Ophthalmol Soc*. 2006;104:85–97.
14. Vithana EN, Morgan P, Sundaresan P, et al. Mutations in sodium-borate cotransporter SLC4A11 cause recessive congenital hereditary endothelial dystrophy (CHED2). *Nat Genet*. 2006;38:755–757.
15. Vithana EN, Morgan PE, Ramprasad V, et al. SLC4A11 mutations in Fuchs endothelial corneal dystrophy. *Hum Mol Genet*. 2008;17:656–666.
16. Riazuddin SA, Zaghloul NA, Al-Saif A, et al. Missense mutations in TCF8 cause late-onset Fuchs corneal dystrophy and interact with FCD4 on chromosome 9p. *Am J Hum Genet*. 2010;86:45–53.
17. Krafchak CM, Pawar H, Moroi SE, et al. Mutations in TCF8 cause posterior polymorphous corneal dystrophy and ectopic expression of COL4A3 by corneal endothelial cells. *Am J Hum Genet*. 2005;77:694–708.
18. Mehta JS, Vithana EN, Tan DT, et al. Analysis of the posterior polymorphous corneal dystrophy 3 gene, TCF8, in late-onset Fuchs endothelial corneal dystrophy. *Invest Ophthalmol Vis Sci*. 2008;49:184–188.
19. Riazuddin SA, Parker DS, McGlumphy EJ, et al. Mutations in LOXHD1, a recessive-deafness locus, cause dominant late-onset Fuchs corneal dystrophy. *Am J Hum Genet*. 2012;90:533–539.
20. Riazuddin SA, Vasanth S, Katsanis N, Gottsch JD. Mutations in AGBL1 cause dominant late-onset Fuchs corneal dystrophy and alter protein-protein interaction with TCF4. *Am J Hum Genet*. 2013;93:758–764.
21. Baratz KH, Tosakulwong N, Ryu E, et al. E2-2 protein and Fuchs's corneal dystrophy. *N Engl J Med*. 2010;363:1016–1024.
22. Afshari NA, Igo RP Jr, Morris NJ, et al. Genome-wide association study identifies three novel loci in Fuchs endothelial corneal dystrophy. *Nat Commun*. 2017;8:14898.
23. Wieben ED, Aleff RA, Tosakulwong N, et al. A common trinucleotide repeat expansion within the transcription factor 4 (TCF4, E2-2) gene predicts Fuchs corneal dystrophy. *PLoS One*. 2012;7:e49083.
24. Mootha VV, Gong X, Ku HC, Xing C. Association and familial segregation of CTG18.1 trinucleotide repeat expansion of TCF4 gene in Fuchs' endothelial corneal dystrophy. *Invest Ophthalmol Vis Sci*. 2014;55:33–42.
25. Murre C, Bain G, van Dijk MA, et al. Structure and function of helix-loop-helix proteins. *Biochim Biophys Acta*. 1994;1218:129–135.
26. Ephrussi A, Church GM, Tonegawa S, Gilbert W. B lineage–specific interactions of an immunoglobulin enhancer with cellular factors in vivo. *Science*. 1985;227:134–140.
27. Breschel TS, McInnis MG, Margolis RL, et al. A novel, heritable, expanding CTG repeat in an intron of the SEF2-1 gene on chromosome 18q21.1. *Hum Mol Genet*. 1997;6:1855–1863.
28. Xing C, Gong X, Hussain I, et al. Transethnic replication of association of CTG18.1 repeat expansion of TCF4 gene with Fuchs' corneal dystrophy in Chinese implies common causal variant. *Invest Ophthalmol Vis Sci*. 2014;55:7073–7078.
29. Nanda GG, Padhy B, Samal S, Das S, Alone DP. Genetic association of TCF4 intronic polymorphisms, CTG18.1 and rs17089887 with Fuchs' endothelial corneal dystrophy in Indian population. *Invest Ophthalmol Vis Sci*. 2014;55:7674–7680.
30. Nakano M, Okumura N, Nakagawa H, et al. Trinucleotide repeat expansion in the TCF4 gene in Fuchs' endothelial corneal dystrophy in Japanese. *Invest Ophthalmol Vis Sci*. 2015;56:4865–4869.
31. Brook JD, McCurrach ME, Harley HG, et al. Molecular basis of myotonic dystrophy: expansion of a trinucleotide (CTG) repeat at the 3′ end of a transcript encoding a protein kinase family member. *Cell*. 1992;68:799–808.
32. Mahadevan M, Tsilfidis C, Sabourin L, et al. Myotonic dystrophy mutation: an unstable CTG repeat in the 3′ untranslated region of the gene. *Science*. 1992;255:1253–1255.
33. Davis BM, McCurrach ME, Taneja KL, Singer RH, Housman DE. Expansion of a CUG trinucleotide repeat in the 3′ untranslated region of myotonic dystrophy protein kinase transcripts results in nuclear retention of transcripts. *Proc Natl Acad Sci U S A*. 1997;94:7388–7393.
34. Jiang H, Mankodi A, Swanson MS, Moxley RT, Thornton CA. Myotonic dystrophy type 1 is associated with nuclear foci of mutant RNA, sequestration of muscleblind proteins and deregulated alternative splicing in neurons. *Hum Mol Genet*. 2004;13:3079–3088.
35. Mootha VV, Hussain I, Cunnusamy K, et al. TCF4 triplet repeat expansion and nuclear RNA foci in Fuchs' endothelial corneal dystrophy. *Invest Ophthalmol Vis Sci*. 2015;56:2003–2011.
36. Du J, Aleff RA, Soragni E, et al. RNA toxicity and missplicing in the common eye disease Fuchs endothelial corneal dystrophy. *J Biol Chem*. 2015;290:5979–5990.
37. Gattey D, Zhu AY, Stagner A, Terry MA, Jun AS. Fuchs endothelial corneal dystrophy in patients with myotonic dystrophy: a case series. *Cornea*. 2014;33:96–98.
38. Musch DC, Niziol LM, Stein JD, Kamyar RM, Sugar A. Prevalence of corneal dystrophies in the United States: estimates from claims data. *Invest Ophthalmol Vis Sci*. 2011;52:6959–6963.

39. Afshari NA, Pittard AB, Siddiqui A, Klintworth GK. Clinical study of Fuchs corneal endothelial dystrophy leading to penetrating keratoplasty: a 30-year experience. *Arch Ophthalmol*. 2006;124:777–780.

40. Soliman AZ, Xing C, Radwan SH, Gong X, Mootha VV. Correlation of severity of Fuchs endothelial corneal dystrophy with triplet repeat expansion in TCF4. *JAMA Ophthalmol*. 2015;1–6.

41. Vos TA. 25 years dystrophia myotonica (D.M.). *Ophthalmologica*. 1961;141:37–45.

42. Rosa N, Lanza M, Borrelli M, et al. Corneal thickness and endothelial cell characteristics in patients with myotonic dystrophy. *Ophthalmology*. 2010;117:223–225.

43. Arsenault ME, Prevost C, Lescault A, Laberge C, Puymirat J, Mathieu J. Clinical characteristics of myotonic dystrophy type 1 patients with small CTG expansions. *Neurology*. 2006;66:1248–1250.

Investigative Ophthalmology & Visual Science