



An Unusual Cause of Increasing Excessive Daytime Sleepiness in a CPAP-treated Obstructive Sleep Apnea Patient

Valerie Martinet¹ Laura Sinkunaite² Marie Bruyneel³ 

¹Department of Geriatrics, Centre Hospitalier Universitaire (CHU) Saint-Pierre, Brussels, Belgium

²Department of Neurology, Centre Hospitalier Universitaire (CHU) Saint-Pierre, Brussels, Belgium

³Department of Pneumology, Centre Hospitalier Universitaire (CHU) Saint-Pierre, Brussels, Belgium

Address for correspondence Marie Bruyneel, MD, PhD (e-mail: marie.bruyneel@stpierre-bru.be; bruyneelmarie@hotmail.com).

Sleep Sci 2024;17(2):e208–e211.

Abstract

The onset of narcolepsy type 1 (NT1) occurs after 50 years of age in less than 2% of the cases. In older adults, the diagnosis is often delayed due to the presence of neurological degenerative and inflammatory comorbidities and overlapping sleep disorders.

We report the case of a 63-year-old man with a 5-year history of excessive daytime sleepiness (EDS) and a 2-year diagnosis of obstructive sleep apnea syndrome (OSAS), which. OSAS was confirmed by respiratory polygraphy that showed an apnea-hypopnea index (AHI) of 71 events/hour of sleep associated with significant nocturnal hypoxemia (lowest oxygen saturation: 53%), which lead to the initiation of continuous positive airway pressure (CPAP) treatment. Cognitive complaints, unexplained spells of dizziness, and lack of improvement in EDS with CPAP led to further diagnostic investigation of infectious, inflammatory, and neurodegenerative disorders. Low hypocretin levels in the cerebrospinal fluid (CSF) confirmed the diagnosis of NT1, and the patient's symptoms improved with the treatment with pitolisant.

Though exceptional in older adults, NT1 should be suspected in the presence of atypical EDS with neurological complaints, unexplained dizzy spells, or OSAS that resists the CPAP treatment. Low levels of hypocretin in the CSF are highly specific and rule out other neurological and sleep disorders.

Keywords

- ▶ narcolepsy
- ▶ excessive daytime sleepiness
- ▶ obstructive sleep apnea
- ▶ hypocretin

Case Report

A 63-year-old Congolese man, living between the Congo-Brazzaville and Europe for several years, complained of excessive daytime sleepiness (EDS) for the past 5 years. The patient provided written informed consent for the report of his clinical history.

Two years before, obstructive sleep apnea syndrome (OSAS) had been diagnosed by respiratory polygraphy (home sleep testing). As the apnea-hypopnea index (AHI) was of 71 events/hour of sleep, the patient was treated with continuous positive airway pressure (CPAP). The mean CPAP compliance was of 6.4 hours/night, and the AHI fell to 9 events/hour of sleep with the treatment (data collected

received
January 11, 2023
accepted
August 2, 2023

DOI <https://doi.org/10.1055/s-0043-1777832>.
ISSN 1984-0659.

© 2024. Brazilian Sleep Association. All rights reserved.

This is an open access article published by Thieme under the terms of the Creative Commons Attribution-NonDerivative-NonCommercial-License, permitting copying and reproduction so long as the original work is given appropriate credit. Contents may not be used for commercial purposes, or adapted, remixed, transformed or built upon. (<https://creativecommons.org/licenses/by-nc-nd/4.0/>)

Thieme Revinter Publicações Ltda., Rua do Matoso 170, Rio de Janeiro, RJ, CEP 20270-135, Brazil

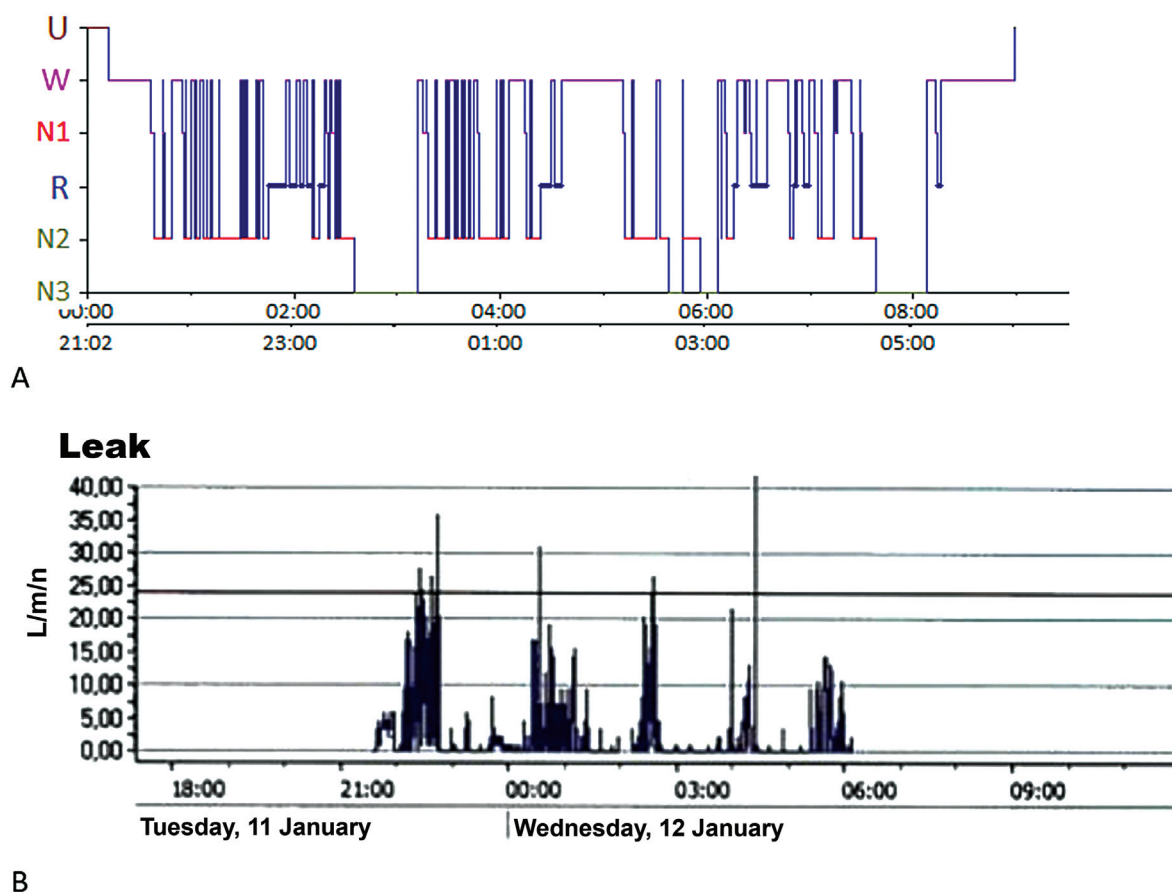


Fig. 1 Trends of the polysomnography (PSG) recorded during the treatment with continuous positive airway pressure (CPAP), showing frequent arousals (hypnogram, ► **Fig. 1A**). The report of the CPAP device revealed significant leaks (► **Fig. 1B**).

from the CPAP device). However, no relief of the EDS occurred, the sleep quality remained poor, and the patient experienced nightmares. He was referred to the memory clinic for memory loss and attention/concentration deficit.

The patient’s score on the Epworth Sleepiness Scale was of 21/24. He spontaneously stopped driving because of EDS. The first polysomnographic (PSG) work-up revealed that the OSAS was not sufficiently controlled despite CPAP due to

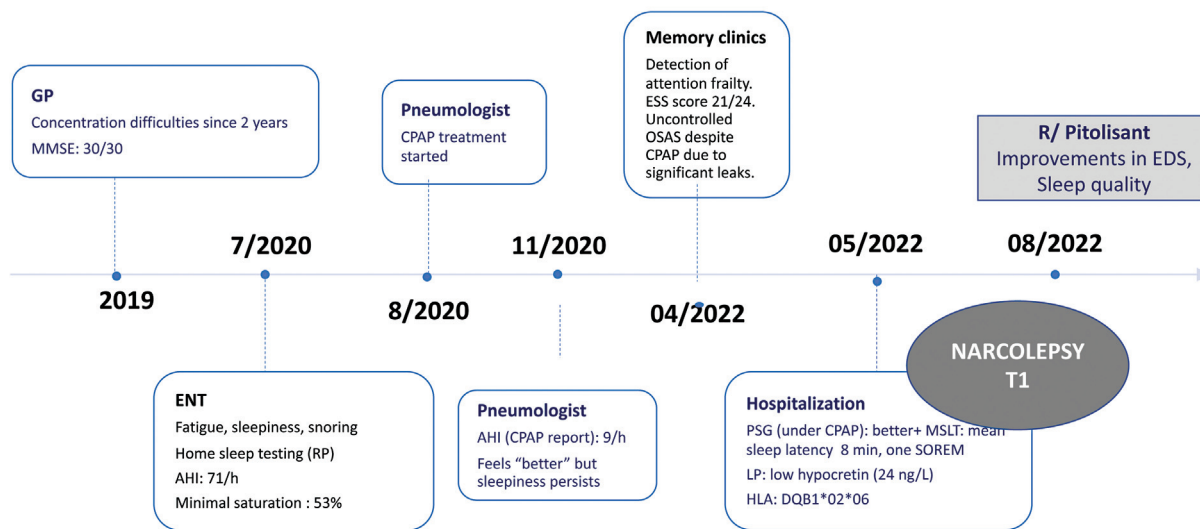


Fig. 2 Timeline of the patient’s management. Abbreviations: AHI, apnea-hypopnea index; CPAP, continuous positive airway pressure, EDS, excessive daytime sleepiness; ENT, ear, nose, and throat specialist; ESS, Epworth Sleepiness Scale; GP, general practitioner; LP, lumbar puncture; MMSE, minimal mental state examination; MSLT, multiple sleep latency test; OSAS; obstructive sleep apnea syndrome; PSG, polysomnography; RP, respiratory polygraphy; SOREM, sleep onset rapid eye movement; T1; type 1

significant leaks (►Fig. 1). The quality of sleep was worse, with reduced sleep efficiency (59%) related to abnormal sleep fragmentation. The mask was changed with leak improvement, but EDS remained unchanged. The general and neurological examinations were within normal limits, and a thorough cognitive evaluation only revealed attentional frailty. The blood analysis failed to show any hematological, metabolic, or inflammatory disturbances. Other diagnoses were considered (such as Parkinson disease, Lewy body dementia), but the patient's symptoms did not fulfill the diagnostic criteria (cerebral MRI: cortico-subcortical atrophy; normal dopamine transporter [DAT] imaging scan). The patient was then admitted for additional analyses. The timeline of patient's management is illustrated in ►Fig. 2.

During this time, he presented with regular spells of dizziness characterized by sudden loss of strength in the lower limbs associated with an irrepressible sleep drive. These episodes never occurred while he was physically active. No hallucinations were described, but his sleep was disturbed by vivid dreams and nightmares. Epilepsy, cardiac arrhythmias, metabolic disturbances, or medication side effects were excluded. Narcolepsy, trypanosomiasis, and anti-IgLON5 disease were suspected. A PSG examination (under CPAP), followed by multiple sleep latency test (MSLT), was performed (►Fig. 3A,B), and it revealed worse sleep quality, better sleep apnea suppression, and objective sleepiness: the mean sleep latency during the MSLT was of 8 minutes, and one sleep onset rapid eye movement (SOREM) cycle was observed. Long-release melatonin was started together with low-dose methylphenidate, 5 mg twice a day. To exclude other diseases, a lumbar puncture with hypocretin-1 dosage, identification of the human leukocyte antigen (HLA), and *Trypanosoma brucei gambiense* serology were performed. The *T. brucei gambiense* serology was negative, as were the anti-IgLON5 antibodies. Finally, the level of hypocretin-1 was severely reduced, at 24 ng/L (normal range: 224-653 ng/L), in the cerebrospinal fluid (CSF), confirming narcolepsy type 1 (NT1). A diagnosis further supported by HLA testing disclosed a pattern associated with narcolepsy: DQB1*02,*06.¹

Finally, a posteriori, the repeated symptoms of malaise were indeed related to cataplexy episodes, which occurred almost every day, especially when laughing with family, and EDS was related to narcolepsy, not to OSA or insomnia. Melatonin and methylphenidate, which were ineffective, were stopped, and pitolisant was initiated. A behavioral intervention was also initiated, including 2 planned 20-minute naps a day, and patient and family education. The patient's complaints, EDS and insomnia, improved with treatment.

Late-onset narcolepsy with cataplexy is rather unusual, although it has been previously described.²⁻⁴ The typical clinical picture of NT1 is the association of EDS, cataplexy, hypnagogic and hypnopompic hallucinations, and sleep palsy. The features associated with PSG features are sleep fragmentation, precocious rapid eye movement (REM) onset, and REM behavior disorder. On MSLT, short sleep latencies during naps (mean: < 8 m) and 2 SOREM cycles are sugges-

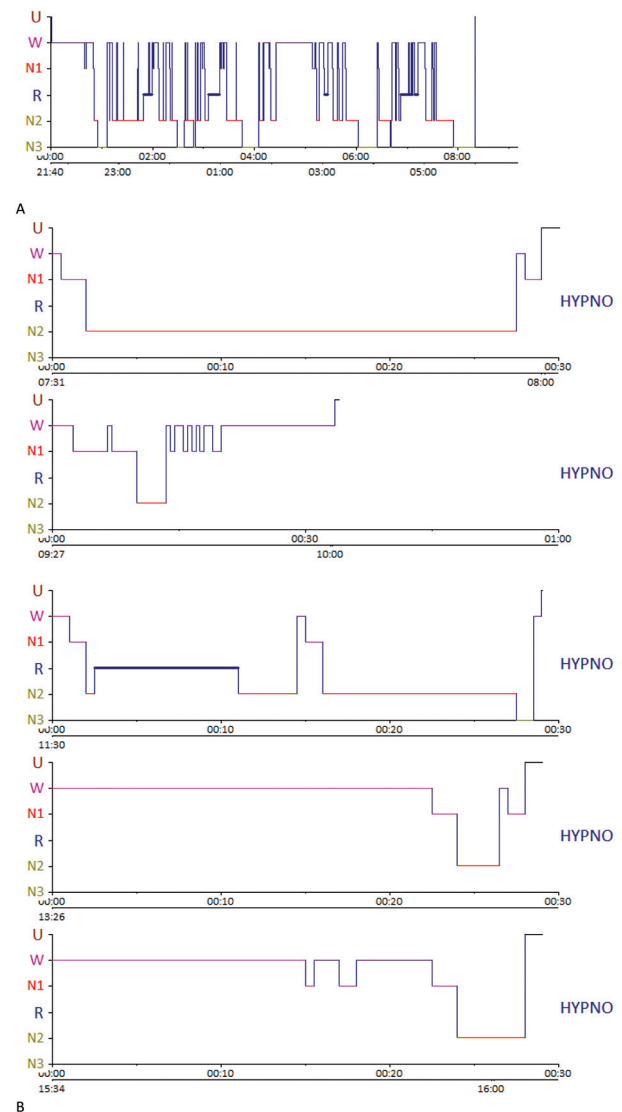


Fig. 3 Trends of the polysomnography (PSG) recorded under the treatment with continuous positive airway pressure (CPAP), after mask adjustment to reduce leaks (hypnogram; A). Sleep quality was not improved. Multiple sleep latency tests were performed the day after (5 naps). During the third nap, a sleep onset rapid eye movement (SOREM) cycle was observed (B).

tive. Type 1 narcolepsy usually occurs during the second and fourth decades of life. In late-onset NT1, the diagnosis can be very difficult to make due to a large panel of differential diagnoses for EDS, including neurologic conditions (such as Alzheimer disease, Parkinson disease, Lewy body disease), metabolic conditions (such as renal failure), and side effects of medications (antidepressive drugs, neuroleptics, for example). However, low hypocretin levels are specific for NT1 while within the normal range in neurologic diseases, and this enabled us to rule out neurodegenerative disorders in the case herein reported.^{5,6} Moreover, physiologic alterations of sleep associated with ageing (such as shorter sleep duration, increased sleep fragmentation, reduction in slow wave sleep) can be also confounding. In the case herein reported, the patient spends several months a year in Sub-Saharan Africa, so sleep sickness also had to be ruled out.

Also a confounding factor, OSAS is frequently associated with NT1, with a 53% prevalence among patients older than 60 years of age^{1,7} and, in the presence of residual EDS (rEDS), despite alleviation of nighttime obstructive respiratory events, hypersomnia of central origin should be excluded.⁷ Other causes of rEDS in OSAS patients need to be ruled out, such as insufficient CPAP compliance, depression, sleep deprivation, and chronic pain. In this case, an additional difficulty was obtaining complete suppression of respiratory events during sleep under CPAP, leading to the supposition that EDS was still related to uncontrolled OSAS. This situation is quite common and often leads us to assume that the persistence of symptoms is related to OSAS. However, in the case herein reported, the severity of the rEDS, the repeated episodes of malaise, and decreased quality of life made us quickly evoke the diagnosis of NT1. We therefore scheduled the lumbar puncture and the HLA test without delay.

To conclude, late-onset NT1 can often be missed due to its rarity and the associated causes of EDS, especially in OSAS. However, a comprehensive work-up should be conducted, as effective medication can dramatically improve the patient's quality of life when NT1 is confirmed. Considerable diagnostic delay has been described in such cases,⁴ encouraging clinicians to suspect this diagnosis regardless of the patient's age. The present report highlights the importance of the analysis of the level of hypocretin in the CSF in the differential diagnosis of other neurological and sleep disorders.

Funding

The authors declare that they have received no funding from agencies in the public, private or non-profit sectors to report the present case.

Conflict of Interests

The authors have no conflict of interests to declare.

References

- 1 Nevsimalova S, Pisko J, Buskova J, et al. Narcolepsy: clinical differences and association with other sleep disorders in different age groups. *J Neurol* 2013;260(03):767–775. Doi: 10.1007/s00415-012-6702-4
- 2 Krishnamurthy VB, Nallamothu V, Singareddy R. An interesting case of late age at onset of narcolepsy with cataplexy. *J Clin Sleep Med* 2014;10(02):203–205. Doi: 10.5664/jcsm.3454
- 3 Quick AD, Black DN, Attarian HP. New-onset narcolepsy with cataplexy in a geriatric patient. *Sleep Med* 2006;7(06):533. Doi: 10.1016/j.sleep.2006.05.007
- 4 Kovalská P, Dostálová S, Machová H, Nytrová P, Maurovich Horvat E, Šonka K. Rare Case of Late-Onset Narcolepsy Type 1. *Case Rep Neurol* 2020;12(03):428–432. Doi: 10.1159/000510633
- 5 Ripley B, Overeem S, Fujiki N, et al. CSF hypocretin/orexin levels in narcolepsy and other neurological conditions. *Neurology* 2001;57(12):2253–2258. Doi: 10.1212/wnl.57.12.2253
- 6 Dauvilliers Y, Baumann CR, Carlander B, et al. CSF hypocretin-1 levels in narcolepsy, Kleine-Levin syndrome, and other hypersomnias and neurological conditions. *J Neurol Neurosurg Psychiatry* 2003;74(12):1667–1673. Doi: 10.1136/jnnp.74.12.1667
- 7 Rosenberg R, Hirshkowitz M, Rapoport DM, Kryger M. The role of home sleep testing for evaluation of patients with excessive daytime sleepiness: focus on obstructive sleep apnea and narcolepsy. *Sleep Med* 2019;56:80–89. Doi: 10.1016/j.sleep.2019.01.014