

Metoclopramide-induced cardiac arrest

Martha M. Rumore,^{1,2} Spencer Evan Lee,³ Steven Wang,³ Brenna Farmer⁴

¹Drug Information, New York - Presbyterian Hospital; ²Pharmacy & Health Outcomes, Touro College of Pharmacy, New York; ³St. John's University, College of Pharmacy and Allied Health Professions, Jamaica; ⁴Division of Emergency Medicine, Weill-Cornell Medical Center/New York Presbyterian Hospital, New York, NY, USA

Abstract

The authors report a case of cardiac arrest in a patient receiving intravenous (IV) metoclopramide and review the pertinent literature. A 62-year-old morbidly obese female admitted for a gastric sleeve procedure, developed cardiac arrest within one minute of receiving metoclopramide 10 mg via slow intravenous (IV) injection. Bradycardia at 4 beats/min immediately appeared, progressing rapidly to asystole. Chest compressions restored vital function. Electrocardiogram (ECG) revealed ST depression indicative of myocardial injury. Following intubation, the patient was transferred to the intensive care unit. Various cardiac dysrhythmias including supraventricular tachycardia (SVT) associated with hypertension and atrial fibrillation occurred. Following IV esmolol and metoprolol, the patient reverted to normal sinus rhythm. Repeat ECGs revealed ST depression resolution without pre-admission changes. Metoclopramide is a non-specific dopamine receptor antagonist. Seven cases of cardiac arrest and one of sinus arrest with metoclopramide were found in the literature. The metoclopramide prescribing information does not list precautions or adverse drug reactions (ADRs) related to cardiac arrest. The reaction is not dose related but may relate to the IV administration route. Coronary artery disease was the sole risk factor identified. According to Naranjo, the association was possible. Other reports of cardiac arrest, severe bradycardia, and SVT were reviewed. In one case, five separate IV doses of 10 mg metoclopramide were immediately followed by asystole repeatedly. The mechanism(s) underlying metoclopramide's cardiac arrest-inducing effects is unknown. Structural similarities to procainamide may play a role. In view of eight previous cases of cardiac arrest from metoclopramide having been reported, further elucidation of this ADR and patient monitoring is needed. Our report should alert clinicians to

monitor patients and remain diligent in surveillance and reporting of bradydysrhythmias and cardiac arrest in patients receiving metoclopramide.

Introduction

Metoclopramide, a dopamine antagonist structurally related to procainamide, has been widely used for its gastric prokinetic and antiemetic effects. The drug blocks dopamine (D2) receptors and may have anti-dysrhythmic properties.^{1,2} In high doses, metoclopramide blocks serotonin receptors in the chemoreceptor trigger zone in the central nervous system (CNS).^{1,3}

In 1974, Shaklai first reported cardiovascular (CV) adverse effects associated with metoclopramide.⁴ We report a case of extreme bradycardia and cardiac arrest following administration of metoclopramide as a preoperative antiemetic.

Case Report

A 62-year-old woman was given metoclopramide 10 mg and glycopyrrolate 0.2 mg through an IV catheter preoperatively for laparoscopic sleeve gastrectomy. Within a minute, the patient reported dizziness and shortness of breath. Oxygen via nasal cannula was administered (O₂ saturation- 96%). The patient developed oxygen desaturation, became rapidly bradycardic (heart rate (HR)- 4 beats/min), and went into cardiac arrest. A code was called and chest compressions were given, for about 15 s, until a pulse was palpated. Her rapid response electrocardiogram (ECG) showed ST depression. The patient became tachycardic (HR- 210 beats/min), and hypertensive (270/176 mmHg). This was thought to be a self-limiting SVT. Per hospital protocol, adenosine was prepped to be administered, but the patient's HR lowered to the 120 s with the underlying rhythm of atrial fibrillation. The patient received two doses of midazolam 1 mg, esmolol 10 mg x 2 and metoprolol 5 mg all IV push and was intubated. She reverted to normal sinus rhythm with a HR in the 80 s, and her blood pressure (BP) stabilized at 125/72 mmHg. The patient was transferred on a ventilator to the intensive care unit for ongoing management. The ST depressions normalized once the HR reached the 70 s – 80 s. Relevant investigation revealed no electrolyte, creatinine or bilirubin abnormalities with the exception of a 1.3 mEq/L magnesium level.

The patient is morbidly obese, weighing 247 lbs., 5'2" tall, with a body surface area of 2.09 m². Past medical history includes a gastric lap band removed in the previous year, coronary

Correspondence: Martha M. Rumore, Drug Information Center, New York-Presbyterian Hospital, 622 West 168th St., New York, NY, 10032, USA. Attn: Pharmacy Dept., VC Basement. Tel. +1.212.305.9992 - Fax: +1.212.342.5348. E-mail: mar9131@nyp.org

Key words: metoclopramide, case report, adverse drug reaction, cardiac arrest, bradycardia, supraventricular tachycardia.

Received for publication: 6 October 2011.
Accepted for publication: 12 October 2011.

This work is licensed under a Creative Commons Attribution NonCommercial 3.0 License (CC BY-NC 3.0).

©Copyright M.M. Rumore et al., 2011
Licensee PAGEPress, Italy
Clinics and Practice 2011; 1:e83
doi:10.4081/cp.2011.e83

artery disease, hypertension, hyperlipidemia, colon cancer and sigmoidectomy, cellulitis, and polio. There was no previous history of chest pain, dysrhythmia, and dyspnea on exertion, syncope or postural hypotension, renal or hepatic impairment. Outpatient medications included lisinopril 10 mg daily, aspirin 81 mg daily, rosuvastatin 5 mg daily, docusate 100 mg twice daily, omeprazole 20 mg daily, calcitonin 200 IU nasal spray daily, and alendronate 70 mg weekly. Baseline HR and BP were not noted in the chart. She had no known prior drug allergies or documented adverse drug reactions (ADRs).

Upon follow-up that day, no pleural effusion or pulmonary edema was noted and lungs were grossly clear on chest x-ray and physical examination. The patient was extubated without difficulty (O₂ sat 96%). She remained in normal sinus rhythm with HR ranging at 70-80 beats/min, and normotensive without the use of vasoactive drugs. Her troponin levels were trended immediately following the arrest: baseline- 0.01 ng/mL (30 min post-event), peaking at 8 h- 0.66 ng/mL, 16 h- 0.39 ng/mL, and 72 h-0.03 ng/mL - all indicating occurrence of initial myocardial injury had occurred. Post-event ECG showed the ST depressions identified during her cardiac arrest had resolved, with no lasting ischemic damage, ECG unchanged from pre-admission. However, myocardial infarction/acute coronary syndrome work up was not further pursued and the possibility of a myocardial infarction could not be completely excluded. The patient underwent sleeve gastrectomy procedure, had no follow-up cardiac evaluation, and was discharged the next day.

Two days following discharge, she presented to the emergency room, complaining of light-headedness and nausea. Her HR was in the 70

s, and a repeat ECG showed no changes. She remained hemodynamically stable, was diagnosed with presyncope, and discharged.

Discussion

Metoclopramide has various physiologic effects with side effects occurring in 10-20% of

patients.⁵ Careful consideration of the risks and benefits of metoclopramide for preoperative nausea and vomiting prophylaxis is necessary. To identify pertinent literature describing CV ADRs from metoclopramide, we conducted a search using MEDLINE (1966- to September 2011), SCOPUS (1996-September 2011), and Google Scholar. Bibliographies of identified articles were reviewed for additional citations. The product manufacturer was contacted but

would not supply any information regarding whether or not they had received reports of cardiac arrest from metoclopramide [Personnel Communication- Rachel Ellerbroek, RN, Baxter Healthcare- Global Pharmacovigilance (847) 948-4281]. A total of seven cases of cardiac arrest were retrieved, making this is the eighth reported case (Table 1). This ADR was submitted to the FDA MedWatch program.

Table 1. Published case reports of metoclopramide-associated cardiac adverse drug events.

Reference	Patient Information	Metoclopramide (M) dose and concomitant medications	Description of event	Probability of causation
Pollera (1984) ⁶	49-year-old woman given high-dose M (1 mg/kg) for four doses.	Stage III ovarian cancer, receiving 3 rd course of intraperitoneal cisplatin; hexamethylmelamine (200 mg/day) was added on later.	Patient had several dystonic episodes and was treated with diazepam and orphenadrine. Six hours after the first dose of M; went into cardiac arrest and died.	Concomitant administration of M with hexamethylmelamine may have contributed to CNS toxicity.
Withington (1986) ⁷	54-year-old male.	Given M 10 mg IV as an anti-emetic. Patient underwent total pancreatectomy; post surgical complications include DVT, PE, chest infection; given dopamine for pressor support.	Within 30 s of M administration, developed sinus bradycardia, asystole for 25 s, progressing to complete heart block and cardiac arrest. Heart rate and BP spontaneously returned to normal.	Rechallenged with a smaller dose (5 mg) of M developed sinus bradycardia with a slight decrease in BP, both resolving within 45 s.
Midtunn (1994) ⁸	62-year-old male with lung emboli and atrial fibrillation.	Patient given M 2.5 mg IV; concomitant digoxin.	Within seconds, developed extreme bradycardia, followed by total heart block.	Rechallenged with M 5 mg IV, again developing bradycardia and total heart block. Concomitant digoxin may have contributed to heart block.
Del Campo (2001) ⁹	30-year-old male trauma patient.	Given M 10 mg IV when enteral nutrition was started.	Within seconds, became bradycardic and went into sinus arrest.	Temporal relationship established. ECG taken during a subsequent dose, and heart rate decreased to 40 beats/min.
Bentsen (2002) ¹⁰	41-year-old male, with intracerebral and subarachnoidal bleeding.	Previously weaned off pressors 2 days prior to being given M 10 mg IV. M was given IV through a central venous catheter directly into the heart.	Following administration, patient had a severe episode of asystole, with 5 subsequent episodes in the next 48 h. Cardiac arrests lasted 15-30 s, one lasting 2 min.	Temporal relationship established. Dopamine infusion rate was being tapered when M was started, possibly predisposing patient to bradyarrhythmias.
Tung (2002) ¹¹	38-year-old woman undergoing sympathectomy of left index finger due to gangrene.	Given M 10 mg IV post-operatively. Given labetalol 10 mg IV 15 min prior. Past medical history includes hypertension, pulmonary hypertension, restrictive lung disease, scleroderma.	Within 5 min of M administration, developed junctional bradycardia without a pulse. Eventually stabilized and required pressor support, but had another episode of bradycardia, could not be resuscitated, and expired.	Temporal relationship established. Concomitant administration of labetalol and M may have contributed to bradyarrhythmia.
Grenier (2003) ¹²	66-year-old female with no history of cardiac disease.	Given two separate doses of M 10 mg IV postoperatively.	One and eight min after each respective dose of M, patient experienced episodes of asystole.	Temporal relationship established. Same symptoms developed when rechallenged.
Schwartz (2010) ¹³	56-year-old male burn patient being treated for atrial fibrillation.	Patient treated with digoxin. Concomitantly treated for a month with M 20 mg IV every 6 h.	After a month of concomitant igoxin and M, patient had 7 episodes of bradycardia and 15 episodes of asystole within 48 h.	After excluding other possibilities, digoxin and M were suspected and discontinued; hours later the bradyarrhythmias resolved.

Assessed using the Naranjo scale,¹⁴ our case highlights a possible association between metoclopramide and cardiac arrest based on: i) occurrence of the effect immediately following metoclopramide injection, ii) the number of previous conclusive reports of bradycardia and cardiac arrest associated with metoclopramide, iii) use of glycopyrrolate which could have caused the reaction, and iv) the ADR was confirmed by objective evidence (Table 2).

Differential diagnosis of cardiac arrest included: acute ischemic events, atypical anaphylaxis, flash pulmonary edema or pulmonary embolism. Anaphylaxis was ruled out because of an absence of allergies or anaphylaxis symptomatology, e.g. pruritis, urticaria, flushing, respiratory distress, nausea, or vomiting. Similarly, myocardial infarction or flash pulmonary edema was unlikely based on the ECG and symptomatology.

Our patient concurrently received glycopyrrolate 0.2 mg IV. Glycopyrrolate is a nonselective anticholinergic drug, which blocks peripheral muscarinic receptors used preoperatively as an antisialogogue. While structurally similar to atropine, glycopyrrolate is a quaternary amine with poor penetration through biologic membranes. Glycopyrrolate has parasympathomimetic effects similar to placebo and, compared to atropine, has fewer CV adverse events and dysrhythmias.¹⁵ Additionally, glycopyrrolate via both the inhalation and IV routes demonstrates bronchodilating effects. Thus, one would not expect to see the respiratory depression as observed with our patient.

A literature search for cardiac arrest from glycopyrrolate revealed only two cases, only one of which was attributed to glycopyrrolate.^{16,17} The first case describes asystole in a heart transplant patient who received concurrent glycopyrrolate 0.8 mg and neostigmine 4 mg IV postoperatively for reversal of neuromuscular blockade. The authors attributed the ADR to neostigmine and did not mention glycopyrrolate.¹⁶ The second case describes ventricular fibrillation and cardiac arrest in a patient with undiagnosed congenital QT prolongation who also concurrently received glycopyrrolate 0.5 mg and neostigmine 2.5 mg IV postoperatively for reversal of neuromuscular blockade. The authors acknowledge that congenital QT prolongation, in and of itself, may result in sudden cardiac arrest and cases have been reported in the literature. Nevertheless, they attributed the cardiac arrest to the QT prolongation effects of glycopyrrolate.¹⁷ The two cases reported in the literature differ from our case in many aspects. First, we note that the doses of glycopyrrolate were 0.5 and 0.8 mg, which is 2-4 times higher than the dose in our case. Unlike the present case, in both cases the glycopyrrolate was given concurrently with neostigmine and to reverse neuromuscular blockade postoperatively. Additionally,

Table 2. Naranjo adverse drug reactions probability scale evaluation for case report.

	Yes	No	Don't know	Score
1. Are there previous conclusive reports of this reaction?	Yes			+1
2. Did the adverse event appear after the suspected drug was administered?	Yes			+2
3. Did the adverse reaction improve when the drug was discontinued, or a specific antagonist was administered?	Yes			+1
4. Did the adverse reaction reappear when the drug was readministered?			N/A	0
5. Are there alternative causes (other than the drug) that could on their own have caused the reaction?	Yes			-1
6. Did the reaction reappear when a placebo was given?			N/A	0
7. Was the drug detected in the blood (or other fluids) in concentrations known to be toxic?			N/A	0
8. Was the reaction more severe when the dose was increased, or less severe when the dose was decreased?			N/A	0
9. Did the patient have a similar reaction to the same or similar drug in any previous exposure?		No		0
10. Was the adverse event confirmed by any objective evidence?	Yes			+1
TOTAL				4

Scale: >8 = highly probable; 5-8 = probable; 1-4 = possible; 0 = doubtful

both cases involved postanesthesia asystole. Also, unlike our case, in both cases the patient had serious underlying CV disease. In our case, the Naranjo probability scale for glycopyrrolate showed that causality was possible. While there is a possibility of an association of cardiac arrest with glycopyrrolate, the association with metoclopramide is stronger in view of the large amount of literature supporting metoclopramide-induced cardiac arrest as well as the number of rechallenge cases that have been reported.^{12,8}

Cases of sinus or cardiac arrest,^{6,7,9-13,18} as well as bradycardia followed by total heart block^{13,8} have been reported. Other reports include cardiac dysrhythmias such as SVT,^{4,19,20} QT prolongation, Torsade de Pointes,^{21,22} ST depression,^{19,20} acute hypotension,²³⁻²⁶ circulatory collapse,²⁷ and congestive heart failure.²⁸ In several of the cases, resolution occurred within 10 min or less.¹⁹ Although there was no re-challenge, in a number of the published cardiac arrest cases, inadvertent metoclopramide rechallenge occurred, confirming a cause-and-effect relationship.^{8,10,12,27} Bentsen reported five repeated episodes of cardiac arrest following five separate metoclopramide injections over 48 h.¹⁰ Asystolic episodes stopped upon drug discontinuation. Other cases have reported repeated circulatory collapse following metoclopramide administration.²⁷ Unlike our case where metoclopramide was administered IV over 1-2 min, metoclopramide was administered over a few seconds

via a central venous catheter. Cases of congestive heart failure following chronic metoclopramide at doses of 40 mg daily are most likely due to a different mechanism of action as dopaminergic inhibition may increase plasma aldosterone, thereby producing sodium retention.²⁸

Our patient's extreme bradycardia and cardiac arrest are similar to previous cases in the literature.^{7-9,11,13} SVT, AV block, bradycardia, heart failure, and hypertension/hypotension but not cardiac arrest are listed in the package insert.²⁹ In our case, SVT was associated with hypertension (BP 270/176 mmHg) and resolved after esmolol and metoprolol administration with conversion to sinus tachycardia. There was no mention of the patient having received epinephrine in accordance with ACLS Guidelines. The duration of the reported cardiac arrests is between 15-30 s, but on one occasion lasted two min.¹⁶

Suggested underlying predisposing or contributory factors for development of cardiac ADRs with metoclopramide include previous cardiovascular disease, atrial fibrillation,⁸ autonomic dysfunction,¹⁸ hyperbilirubinemia,⁷ halothane anesthesia,^{25,26} and pericardial drainage tube.⁸ However, no clear association with any risk factors exists. Cardiac arrest occurred in patients without cardiac disease.¹² In at least some of the previous cases reports, the patients did have a history of coronary artery disease (CAD). Our patient had morbid obesity and CAD; two risk factors for

sudden cardiac arrest. However, the usual chronology for CAD is angina progressing to a myocardial injury/infarction triggering ventricular fibrillation, not bradycardia. Past medical history did not reveal angina.

While any drug-drug interaction was ruled out, our patient was on lisinopril 10 mg daily prior to admission. Chronic use of angiotensin-converting enzyme (ACE) inhibitors has been associated with reduced adrenergic responsiveness and hypotension during anesthesia.¹¹ Whether this possible interaction was contributory to the cardiac arrest is unknown. However, in one cardiac arrest case the patient received an ACE inhibitor.¹¹

Neither age nor dose appears contributory. While the patients in most cases were elderly, cardiac arrest also occurred in middle-aged individuals.¹⁰ Moreover, this ADR is not dose-related as it occurred after single 2.5-10 mg doses.^{8,12,18} The route and rate of administration may be causative. In all cases, metoclopramide was given IV either peripherally or via central venous lines. In several cases metoclopramide was administered over seconds, not slowly over 1-2 min.²⁴ In a 16 patient series, 10 mg IV produced average decreases in systolic and diastolic BP of 22% and 20%, respectively, occurring on average 44s after administration over 10 s.²⁵ However, the package insert states slow injection avoids a *transient but intense feeling of anxiety and restlessness, followed by drowsiness*, not rapid BP decreases.²⁹

Metoclopramide has potent central antidopaminergic and peripheral cholinergic effects.^{1,3} The mechanism(s) for metoclopramide-induced extreme bradycardia, SVT, and cardiac arrest are unknown but may be multifactorial involving: i) a direct cardiac effect; ii) presynaptic autoreceptor blockade and enhanced catecholamine release,^{13,30} iii) other actions caused by enhanced cholinergic neurotransmission,³¹ or iv) 5-HT₃ receptor blockade or 5-HT₄ receptor agonism.³¹

Support for a mechanism involving a direct effect of metoclopramide on the heart may be found in the structural similarity of metoclopramide with procainamide. Figure 1 shows that metoclopramide differs from procainamide by only a 2,5 aryl substitution.¹ Procainamide and cholinergic stimulation, in general, have long been known to cause sinus arrest.¹⁸ A direct effect is likely to appear immediately; in most cases, the heart stopped within 30 s.⁷⁻¹⁰

Support for a mechanism involving presynaptic autoreceptor blocking and catecholamine release is found in metoclopramide's ability to release catecholamines in pheochromocytoma and hypertension.^{30,31} One cardiac arrest case occurred upon dopamine discontinuation.¹⁶ The effect may be the result of increased release and levels³²⁻³⁷ of acetyl-

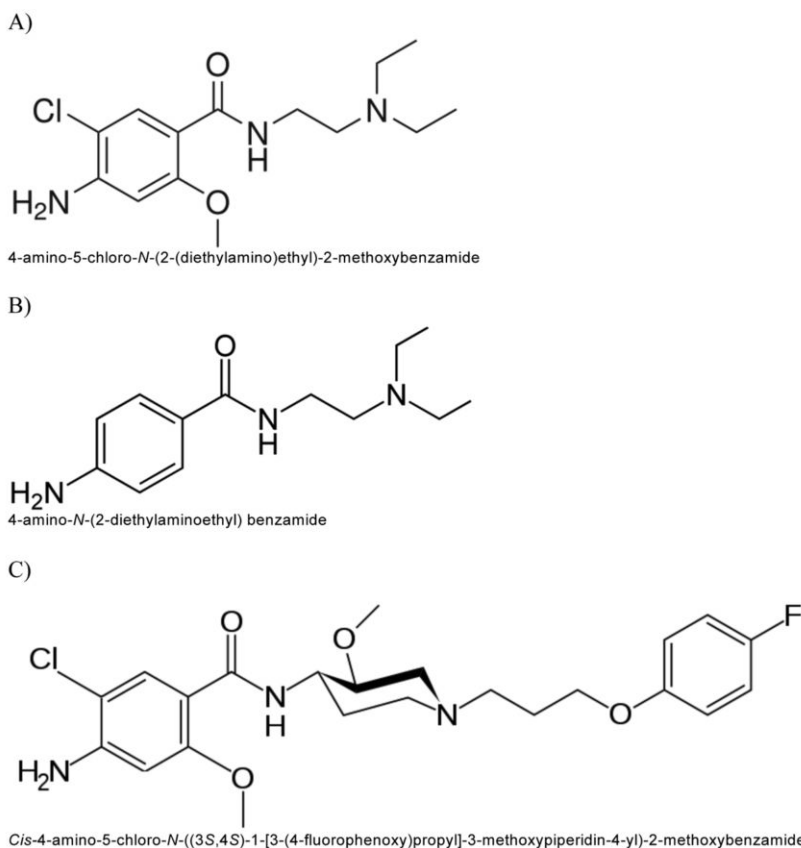


Figure 1. Structural comparison of 3 different agents: A) Metoclopramide; B) Procainamide; C) Cisapride.

choline producing cholinergic-induced bradydysrhythmias. The effect on the heart may be the result of changes in cholinergic tone mimicking vagal stimulation.³⁶

In studies, metoclopramide has been shown to have quinidine-like antidysrhythmic effects, increase atrial and AV nodal refractory periods,³⁸ decrease systolic and diastolic blood pressure, left ventricular systolic pressure, and total peripheral resistance.^{2,39-42}

Another potential mechanism is 5-HT₃ receptor blockade or 5-HT₄ receptor agonism. 5-HT₄ receptors are also located in the heart and the vasculature where they exert a positive chronotropic effect and tachycardia by an action on the atrium. As can be noted in Figure 1, metoclopramide is structurally related to cisapride, both being gastric prokinetic substituted benzamides. Cisapride was known for its cardiotoxic QT prolongation and torsades de pointes. Metoclopramide has been shown to undergo CYP2D6 metabolism. Elimination may be slowed in patients taking inhibitors of this isoform, such as omeprazole.^{32,43-45} Although our patient was receiving omeprazole, a metabolic effect is deemed unlikely since the cardiac arrest occurred immediately in both our case and those reported in the literature.

In summary, metoclopramide may occasional-

ly cause bradyarrhythmias progressing to cardiac arrest and paroxysmal SVT in patients without evidence of underlying cardiac abnormalities.

Conclusions

Cardiac arrest is a rare but serious CV adverse effect of metoclopramide. It would appear to be prudent to monitor patients receiving metoclopramide IV immediately after injection for CV adverse effects. We believe it is also appropriate to warn against rapid IV injection, especially via the central venous route. In view of the number of reported cases, we recommend addition of this ADR to the metoclopramide Prescribing Information. This case should prompt a critical re-evaluation of the risk/benefit of metoclopramide and consideration of therapeutic alternatives, in concert with a search for underlying predisposing factors or mechanisms of action involved.

References

- Schulze-Delrieu K. Metoclopramide. *N Engl J Med* 1981;305:28-33.

2. Thorlum CW, Sewton E. The haemodynamic effects of metoclopramide. *Postgrad Med J* 1973;49 Suppl 4:suppl 4:22-24.
3. Pinder RM, Brogden RN, Sarvyer PR, et al. Metoclopramide: A review of its pharmacological properties and clinical usage. *Drugs* 1976;12:81-137.
4. Shaklai M, Pinkhas J, De Vries A. Metoclopramide and cardiac arrhythmia (letter). *Br Med J* 1974;2:385.
5. Albibi R, McCallum R. Metoclopramide: Pharmacology and clinical application. *Ann Intern Med* 1983;98:86-95.
6. Pollera CF, Cognetti F, Nardi M, Mazza D. Sudden death after acute dystonic reaction to high-dose metoclopramide. *Lancet* 1984;2:460-1.
7. Withington DE. Dysrhythmias following intravenous metoclopramide. *Intensive Care Med* 1986;12:378-9.
8. Middtun M, Oberg B. Total heart block after intravenous metoclopramide. *Lancet* 1994;343:182-3.
9. Del Campo MM, Martinez PG, Sanjuán EM, Reixac JG. [Sinus arrest after the administration of intravenous metoclopramide] (letter). *Med Clin (Barc)* 2001;117:238-9. [Article in Spanish].
10. Bentsen G, Stubhaug A. Cardiac arrest after intravenous metoclopramide—a case of five repeated injections of metoclopramide causing five episodes of cardiac arrest. *Acta Anaesthesiol Scand* 2002;46:908-10.
11. Tung A, Sweitzer BJ, Cutter T. Cardiac arrest after labetalol and metoclopramide administration in a patient with scleroderma. *Anesth Analg* 2002;95:1667-8.
12. Grenier Y, Drolet P. Asystolic cardiac arrest: an unusual reaction following iv metoclopramide. *Can J Anaesth* 2003;50:333-5.
13. Schwartz BG. Metoclopramide and digoxin cause 22 episodes of bradyarrhythmias. *Am J Medicine* 2010;123:5-6.
14. Naranjo CA, Busto U, Sellers EM, et al. A method for estimating the probability of adverse drug reactions. *Clin Pharmacol Ther* 1981;30:239-45.
15. Chung C, Cayne NS, Adelman MA, et al. Improved hemodynamic outcomes with glycopyrrolate over atropine in carotid angioplasty and stenting. *Perspect Vasc Surg Endovas Therapy* 2010;22:164-70.
16. Bjerke RJ, Mangione MP. Asystole after intravenous neostigmine in a heart transplant recipient. *Can J Anesth* 2001;48:305-7.
17. Pleym H, Bathen J, Spigset O, Grisvold SE. Ventricular fibrillation related to reversal of the neuromuscular blockade in a patient with long QT syndrome. *Acta Anaesthesiol Scand* 1999;43:352-5.
18. Malkoff MD, Ponzillo JJ, Myles GL, et al. Sinus arrest after administration of intravenous metoclopramide. *Ann Pharmacother* 1995;29:381-3.
19. Baguley WA, Hay WT, Mackie KP, et al. Cardiac dysrhythmias associated with the intravenous administration of ondansetron and metoclopramide. *Anesth Analg* 1997;84:1380-1.
20. Bevacqua BK. Supraventricular tachycardia associated with postpartum metoclopramide administration. *Anesthesiology* 1988;68:124-5.
21. Chou CC, Wu D. Torsade de pointes induced by metoclopramide in an elderly woman with preexisting complete left bundle branch block. *Chang Gung Med J* 2001;24:805-9.
22. Siddique SM, Shariff N, Vesuwala N, Hafiz T. Metoclopramide as a possible cause of prolonged QT syndrome and torsade de pointes in a patient with heart failure and renal insufficiency. *Ann Intern Med* 2009;150:502-4.
23. Park GR. Hypotension following the intravenous injection of metoclopramide (letter). *Anaesthesia* 1981;36:75-6.
24. Hughes RL. Hypotension and dysrhythmia following intravenous metoclopramide (letter). *Anaesthesia* 1984;39:720.
25. Pegg MS. Hypotension following metoclopramide injection (letter). *Anaesthesia* 1980;36:615.
26. Park GR. Hypotension following metoclopramide administration during hypotensive anaesthesia for intracranial aneurysm (letter). *Br J Anaesth* 1978;50:1268-9.
27. Lau KK, Chan KW, Lok CM, et al. Circulatory collapse in a patient with gastrinoma after metoclopramide administration. *Hong Kong Med J* 2009;15:478-81.
28. Ahmad S. Metoclopramide-induced acute congestive heart failure (letter). *South Med J* 1991;84:283-4.
29. Package Insert. Metoclopramide Injection, U.S.P. Deerfield, IL: Baxter Healthcare Corporation, April 2010.
30. Kuchel O, Buu NT, Hamet P, Laroche P. Effect of metoclopramide on plasma catecholamine release in essential hypertension. *Clin Pharmacol Ther* 1985;37:372-5.
31. Ponte CD, Nappi JM. Review of a new gastrointestinal drug: metoclopramide. *Am J Hosp Pharm* 1981;38:829-33.
32. Hay AM, Man WK. Effect of metoclopramide on guinea pig stomach: critical dependence on intrinsic stores of acetylcholine. *Gastroenterology* 1979;76:492-6.
33. Sommers DK, Meyer FC, van Wyk M, de Villiers IS. Aldosterone response to metoclopramide is mediated through the autonomous nervous system in man. *Eur J Clin Pharmacol* 1988;33:609-12.
34. Sanger GJ. Effects of metoclopramide and domperidone on cholinergic mediated contractions of human isolated stomach muscle. *J Pharm Pharmacol* 1985;37:661-4.
35. Vecca C, Maione S, Iozzi A, Marmo B. Benzamides and cholinesterases. *Res Comm Chem Pathol Pharmacol* 1987;55:193-201.
36. Magnifico F, Pierangeli G, Barletta G, et al. The cardiovascular effects of metoclopramide in multiple system atrophy and pure autonomic failure. *Clin Auton Res* 2001;11:163-68.
37. Magnifico F, Pierangeli G, Contin M, et al. Acute hypotensive effect of metoclopramide in autonomic failure. *Clin Auton Res* 1998;8:63.
38. LaBarre J. A propos du mode d'actio du metoclopramide en therapeutique gastro-intesnale. [Mode of action of metoclopramide in gastrointestinal therapeutics]. *Path Biol (Paris)* 1969;17:663-6. [Article in French].
39. Malmejac J, Laville C. Effects cardiovasculaires du metoclopramide. *Path Biol* 1964;12:1074-8.
40. Ramos AO, Bastos WP, Sakoto M. Influence of metoclopramide in experimental arrhythmias induced by barium or by chloroform and adrenaline. *Med Pharmacol Exp Int J Exp Med* 1967;17:385-90.
41. Bozzi G, Terranova P, Paolino C, et al. The effects of acute administration of metoclopramide on atrial and AV conduction in man. *Boll Soc Ital Cardiol* 1981;26:1853.
42. Xiaodong L, Dongke Z, Gengsheng Z. Effects of metoclopramide on physiologic properties of guinea pig papillary muscles and hemodynamics in dogs. *Chin Pharm Bull* 1986;3:19.
43. Ishizahi T, Horai Y. Review article: cytochrome P450 and the metabolism of proton pump inhibitors—emphasis on rabeprazole. *Aliment Pharmacol Ther* 1999;13 Suppl 3:27-31.
44. Yu J, Paine MJ, Marechal J, et al. In silico prediction of drug binding to CYP2D6: identification of a new metabolite of metoclopramide. *Drug Metabol Dispos* 2006;34:1386-92.
45. Desta Z, Wu GM, Morocho AM, Flockhart Da. The gastroprokinetic and antiemetic drug metoclopramide is a substrate and inhibitor of cytochrome P450 2D6. *Drug Metabol Dispos* 2002;30:336-43.