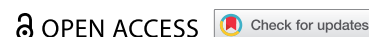

CASE REPORT



Copper deficiency myeloneuropathy with a history of malabsorption: a tale of two cases

Anum Qureshi, Emily Bergbower  and Janki Patel

Department of Internal Medicine, Greater Baltimore Medical Center, Towson, MD, USA

ABSTRACT

Acquired copper deficiency is rare but often seen among patients with intestinal malabsorption syndromes. Often times, these patients can develop myeloneuropathies with copper deficiency as an elusive culprit. With early diagnosis and appropriate supplementation, many symptoms, such as myeloneuropathy, can be reversed entirely. Checking copper levels should be included in the workup of myeloneuropathies to prevent irreversible damage and improving morbidity and mortality.

ARTICLE HISTORY

Received 20 May 2020
Accepted 23 October 2020

KEYWORDS

Copper deficiency;
myeloneuropathy;
malabsorption syndromes

1. Introduction

Copper's primary absorption site is in the small intestine from where it is distributed to the rest of the body (Figure 1). Acquired copper deficiency is rare but often seen among patients with malabsorption syndromes, such as celiac disease, or a history of gastric bypass surgery, small bowel obstruction (SBO), and small intestinal bacterial overgrowth (SIBO). It has been a known cause of anemia for decades but has only been identified as a cause of reversible myelopathy since approximately 2000 with more than 50 cases reported in the literature [1–6]. In fact, copper deficiency is the second most common etiology after B12 deficiency for myeloneuropathy in patients with malabsorption syndromes [2,4]. In cases of subacute combined degeneration, the two deficiencies are often indistinguishable clinically and can even coexist. Treatment of copper deficiency comprises copper supplementation. With appropriate supplementation, many symptoms, such as myeloneuropathy, can be reversed entirely [2]. We are presenting two cases of copper deficiency secondary to malabsorption syndromes leading to myeloneuropathy (Table 1).

2. Case 1



We present the case of a 45-year-old man who presented with complaints of chronic diarrhea and rectal fullness. His medical history was significant for congenital atresia repaired in childhood and short gut syndrome. An infectious workup focused on stool analysis for ova, parasites, and leukocytes was unremarkable. He was subsequently started on

cholestyramine and his diarrhea improved. He was discharged with a recommendation for outpatient gastroenterology follow up.

Several weeks after his initial admission, he presented to neurology clinic with complaints of bilateral hand and foot numbness as well as difficulty keeping his balance. He reported multiple falls at home and a sensation of wobbliness. On exam, he was noted to have a broad-based ataxic gait. His Romberg sign was positive and hyporeflexia of the lower limbs was observed. Additionally, he was noted to have sensory ataxia as well as a loss of vibration and proprioception. MRI of the brain showed moderate subcortical, periventricular, and deep white matter T2/FLAIR abnormalities. Based on these results and his history of chronic diarrhea, nutritional deficiency seemed to be the most likely culprit. Vitamins B1, E, and D were checked. Vitamin E and Vitamin D levels were low while Vitamin B12 and folate levels were normal. However, his copper level was low at 21 mcg/dL (ref 71–175mcg/dL) with a normal ceruloplasmin (12 mg/dL). As a result, he was started on daily oral copper supplementation of 8 mg followed by 2 mg for 8 weeks as well as daily gabapentin. He experienced little improvement in his myeloneuropathy symptoms.

3. Case 2

We present the case of a 69-year-old female who presented with the complaints of recurrent nausea and vomiting. Her medical history is significant for stage IV colon cancer status post (s/p) resection and colostomy placement, viral cardiomyopathy, ventricular tachycardia s/p AICD placement, malnutrition,

CONTACT Anum Qureshi  anqureshi@gbmc.org  Department of Internal Medicine, Greater Baltimore Medical Center, Towson, MD, USA

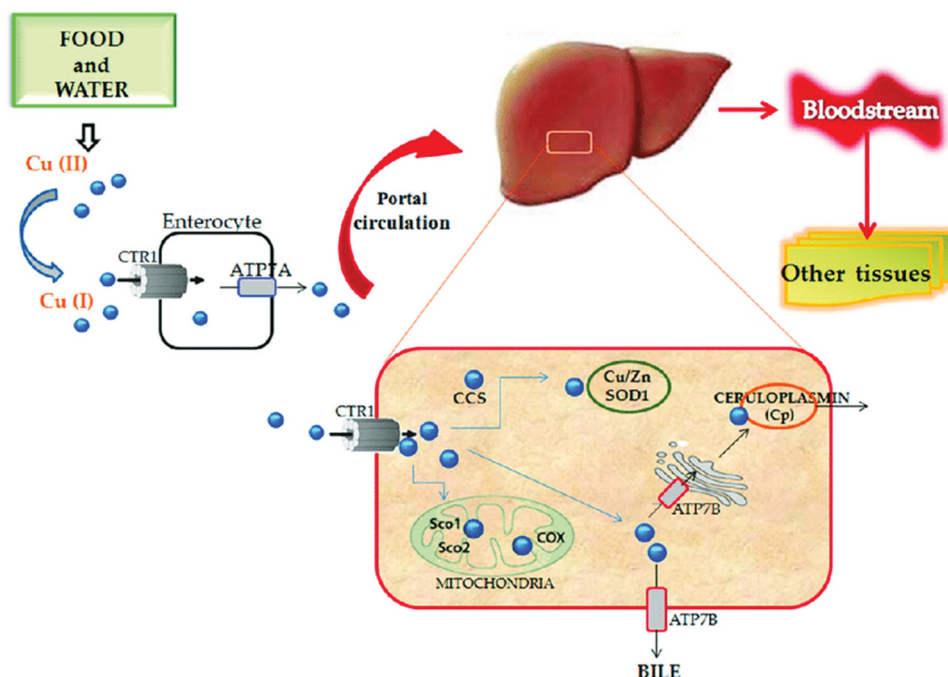


Figure 1. Copper absorption, distribution, and metabolism. Antonucci et al., 2017

hypoalbuminemia, and multiple small bowel obstructions. She was initially assessed at her nursing home where an x-ray of the abdomen showed small bowel obstruction. On admission, a CT scan showed was suggestive of small bowel obstruction with marked dilatation of the stomach and proximal small bowel loops, decompressed distal small bowel, and a transition point within the midline of the pelvis. She was evaluated by colorectal surgery who recommended conservative management and nasogastric (NG) tube placement.

On interview, the patient noted that she had also been suffering from bilateral leg weakness, numbness and tingling for at least 7 months. The sensations followed a sock-like distribution with the left extremity worse than the right. Her neurological exam was significant for pronounced bilateral lower extremity weakness against gravity. She also had absent ankle and knee reflexes. A decrease in sensations of vibration and proprioception was notable in a stocking's distribution on the bilateral lower extremities. Ataxia was notable during finger to nose testing.

She subsequently underwent CT scan of the spine as well as a lumbar puncture due to concerns that metastases were the underlying cause of her symptoms. The CT scan was only suggestive of chronic degenerative changes. The lumbar puncture was done that was negative for any infection or malignancy. Electromyography was performed in the right and left quadriceps, hamstrings, tibialis anterior and right abductor hallucis muscles. The interference pattern in all muscles was reduced representing the presence of a longstanding sensory and motor polyneuropathy of moderate severity. This was

initially thought to be secondary to either chemotherapy as she received capecitabine and subsequently capecitabine, oxaliplatin in combination with radiotherapy for colon cancer which are notorious for causing neuropathy. Another possibility was nutritional deficiency as she had multiple small bowel obstructions in the past. She was noted to have a low copper level of 48 mcg/dL (71–175mcg/dL), and elevated vitamin B1 and B12 levels. As a result, she was started on daily copper supplementation of 2 mg for 2 weeks. She was admitted again with sepsis and SBO. She unfortunately became hospice and died eventually. There was no follow up regarding symptom improvement.

4. Discussion

Copper is an essential trace element absorbed from the intestinal lumen into blood with the help of ATP7A, a P-type ATPase and transmembrane protein. The recommended daily allowance of copper is 0.9 mg/day. Copper is required for the catalytic activity of several critical enzymes, including cytochrome c oxidase, copper-zinc superoxide dismutase, dopamine β -hydroxylase, ceruloplasmin, lysyl oxidase, and tyrosinase. As such, it is essential for the structure and function of these enzymes and deficiencies can lead to significant hematological or neurological deficits [3]. The small intestine, especially the duodenum, serves as the site of copper absorption where metals, including copper and zinc, bind to intracellular ligands and metallothionein (MT). An excess of other metals, especially zinc, increases the affinity of copper for metallothionein

Table 1. Two cases of copper deficiency due to malabsorption leading to myeloneuropathy.

	Case 1	Case 2
Age	45	69
Sex	Male	Female
Medical History	Congenital atresia repaired in childhood and short gut syndrome	Stage IV colon cancer status post resection and colostomy
GI symptoms	Chronic Diarrhea	Constipation, nausea and vomiting
Neuro Symptoms	Bilateral hand and foot numbness, balance problem, multiple falls and wobble gait	Numbness and tingling of feet > hands
Exam	Sensory ataxia, loss of vibration and proprioception, hyporeflexia of the lower limb, broad-based ataxic gait, Romberg sign was positive as well.	Tremor of the outstretched tongue and hands, strength in her hands and legs 4/5, absent ankle and knee reflexes, decrease in sensation in a hands and feet in stocking distribution, reduced vibration and ataxia finger-to-nose testing.
X-ray Abdomen	-	Small bowel obstruction
CT/MRI	MRI: Subcortical, periventricular, and deep white matter T2/FLAIR abnormalities	CT scan of all spines: age related degenerative changes
Lumber Puncture	Not done	No acute abnormalities
Copper	21 mcg/dL (71–175 mcg/dL)	48 mcg/dL (71–175 mcg/dL)
Ceruloplasmin	12 mg/dL (8–36 mg/dL)	-
Treatment	8 mg followed by 2 mg	2 mg daily
Duration of Rx	6 weeks	2 weeks

(MT). So, zinc overload decreases the overall intestinal absorption of copper.

Deficiency usually occurs in patients after gastric bypass surgery since a large portion of the stomach and duodenum responsible for copper absorption is removed. In a study by Miller et al. (2011), prevalence and incidence of copper deficiency were 9.6% and 18.8%, respectively, following Roux-en-Y gastric bypass (RYGB) surgery [7]. Copper deficiency in patients with malabsorption syndromes (i.e., celiac disease, tropical sprue, and inflammatory bowel disease) is caused by mucosal damage from autoimmune and inflammatory processes which impairs absorption.

Myeloneuropathy resulting from copper deficiency is similar to vitamin B₁₂ deficiency in clinical presentation (subacute combined degeneration). Both types of patients usually have a spastic ataxic gait and dorsal column deficits. Neuroimaging with MRI of the brain is usually non-specific, but MRI of the spinal cord will show an increased T2 signal in the paramedian dorsal spinal cord. Electromyography and nerve conduction studies are other useful tests in diagnosis and can show evidence of axonal neuropathy. Nerve and muscle biopsy will show axonal degeneration and vacuolar changes in the muscle. In some of the published case reports, there are patients who develop cerebral atrophy visible on imaging [8]. Other differentials for myeloneuropathy are discussed in Table 2.

Copper repletion and supplementation prevents neurological symptoms from worsening and, in some cases, can reverse or ameliorate these symptoms. Plantone et al. 2015 reported two cases of copper deficiency myelopathy that presented as ataxic gait and sensory symptoms and have significant improvement with copper supplementations and he emphasized on including copper in the diagnostic workup of myelopathy thus irreversible damage can be prevented by early detection [6]. Kumar et al. 2004 also mentioned about three cases of myelopathy and peripheral neuropathy and two-thirds of patients had MRI findings of hyperintense T2 lesions in posterior column and 2 patients responded well to IV and oral copper supplements [9].

Radiological testing was done in one patient but both of our presented patients were started on copper therapy and experienced questionable improvement in their symptoms due to significant delay in starting treatment.

Table 2. Differential diagnosis of myeloneuropathy.

Neoplastic/ Paraneoplastic	Lymphoma, Myeloma, leukemias
Metabolic	Diabetes, Amyloidosis, uremia, Vitamin/Mineral Deficiencies (B12, Folate, Vitamin E, Copper)
Infectious / Inflammatory	Sarcoidosis, GBS, Lyme, HIV, HTLV
Drugs/Toxins	Alcohol, Heavy metals, chemotherapeutic drugs

In conclusion, copper deficiency is often an overlooked cause of myeloneuropathy. Copper supplementation can reverse the deficits. We suggest a lower threshold for checking serum copper levels in patients with a history of malabsorption syndromes, gastric bypass surgery, or SIBO if they present with extremity numbness and weakness before proceeding to invasive workup.

Disclosure statement

No potential conflict of interest was reported by the authors.

ORCID

Emily Bergbower  <http://orcid.org/0000-0002-7937-2661>

References

- [1] Halfdanarson TR, Kumar N, Hogan WJ, et al. Copper deficiency in celiac disease. *J Clin Gastroenterol.* 2009;43(2):162–164.
- [2] Jaiser SR, Winston GP. Copper deficiency myelopathy. *J Neurol.* 2010;257(6):869–881.
- [3] Langley A, Dameron CT. Copper and anesthesia: clinical relevance and management of copper related disorders. *Anesthesiol Res Pract.* 2013;2013:750901.
- [4] Garg RK, Malhotra HS, Kumar N. Approach to a case of myeloneuropathy. *Ann Indian Acad Neurol.* 2016 Apr-Jun;19(2):183–187.
- [5] Cavallieri F, Fini N, Contardi S, et al. Subacute copper-deficiency myelopathy in a patient with occult celiac disease. *J Spinal Cord Med.* 2017 Jul;40(4):489–491.
- [6] Plantone D, Primiano G, Renna R, et al. Copper deficiency myelopathy: A report of two cases. *J Spinal Cord Med.* 2015 Jul;38(4):559–562.
- [7] Gletsu-Miller N, Broderius M, Frediani JK, et al. Incidence and prevalence of copper deficiency following roux-en-y gastric bypass surgery. *Int J Obesity.* 2012;36(3):328–335. .
- [8] Mittal SO, Machado DG. Hypocupremia: a possible association with late cortical cerebellar atrophy. *Tremor Other Hyperkinet Mov.* 2014;4:202.
- [9] Kumar N, Crum B, Petersen RC, et al. Copper deficiency myelopathy. *Arch Neurol.* 2004;61(5):762–766.