

Available online at www.sciencedirect.com

ScienceDirect

journal homepage: <http://Elsevier.com/locate/radcr>

Case Report

Zinner syndrome diagnosed by magnetic resonance imaging and computed tomography: role of imaging to identify and evaluate the uncommon variation in development of the male genital tract

V. Fiaschetti MD, PhD, L. Greco MD, V. Giuricin MD^{*}, D. De Vivo MD, E. Di Caprera MD, R. Di Trapano MD, F. Castellani MD, R. Floris MD

Department of Diagnostic and Molecular Imaging, Interventional Radiology and Radiation Therapy, Fondazione Policlinico "Tor Vergata", viale Oxford 81, Rome 00133, Italy

ARTICLE INFO

Article history:

Received 2 June 2016

Received in revised form

26 September 2016

Accepted 3 October 2016

Available online 19 November 2016

Keywords:

Zinner Syndrome

Seminal cyst

Renal agenesis

ABSTRACT

Seminal vesicle cysts are a very rare condition and its often associated with ipsilateral renal agenesis. The diagnosis of seminal vesicle cysts may be delayed or missed because of the non-specific symptoms of this condition. This article reports a triad of right renal agenesis, ipsilateral seminal vesicle cyst, and ejaculatory duct obstruction (Zinner syndrome) in a 56 years old man.

© 2016 the Authors. Published by Elsevier Inc. under copyright license from the University of Washington. This is an open access article under the CC BY-NC-ND license (<http://creativecommons.org/licenses/by-nc-nd/4.0/>).

A 56-year-old man was sent by his general practitioner to our department because of genitourinary discomfort history that began about a year ago but had worsened over the past 6 months.

His symptoms included perianal pain, dysuria, increased urinary frequency, ejaculation failure, therefore was initially diagnosed prostatitis.

Actually, the serum markers for prostate cancer, prostate-specific antigen and prostatic acid phosphatase, and carcinoembryonic antigen (CEA) were in the normal range, and, in addition, symptoms were not improved after antibiotic therapy.

His past medical history included situs viscerum inversus.

A few days before, the patient had performed ultrasonography (US) in another center (not available) that revealed the presence of a cystic mass localized in the pelvic region. A contrast-enhanced abdomen computed tomography (CT) was performed using a 64-row scanner (LightSpeed VCT, General Electric Medical System, Milwaukee, WI, USA) before and after the injection of iodinate contrast medium (Iomeron 350 mg/mL, Bracco Imaging, Milan, Italy).

^{*} Corresponding author.

E-mail address: evaluna_84@hotmail.it (V. Giuricin).
<http://dx.doi.org/10.1016/j.radcr.2016.10.007>

1930-0433/© 2016 the Authors. Published by Elsevier Inc. under copyright license from the University of Washington. This is an open access article under the CC BY-NC-ND license (<http://creativecommons.org/licenses/by-nc-nd/4.0/>).

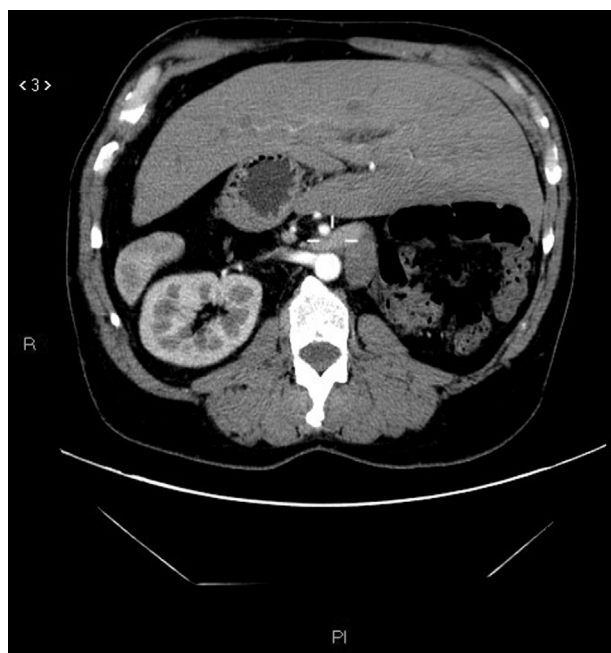


Fig. 1 – A 56-year-old man with a condition of situs viscerum inversus.

CT scan confirmed left kidney agenesis and the condition of situs viscerum inversus (Fig. 1).

In addition, CT demonstrated large lobulated multiloculated cystic lesion of left seminal vesicle with a saccular dilated enlarged ectopic ureter opening into the cystic left seminal vesicle (Fig. 2).

The lesion diameters were approximately 7.9×3.8 cm.

After injection of intravenous contrast material, the cystic lesion did not show enhancement (Figs. 3 and 4).

Pelvic MRI was performed with a 1.5-T scanner (Achieva, Philips medical systems, BEST, Netherlands) using a pelvic phased-array coil.

The imaging protocol included a T1-weighted (W) turbo spin-echo (TSE), a T2-W TSE, a T1-W TSE fat-saturation, performed in the transverse and coronal plane.

No intravenous contrast medium was administered.

MRI showed laterally located cystic lesion in region of left seminal vesicle.

On T1-weighted images, the multiloculated seminal vesicle cyst appeared hypointense. The cystic lesion appeared bright on T2-weighted images (Fig. 5).

The coronal T1-weighted image showed a dilated and ectopic ureter draining into the left seminal vesicle with a length of 10 cm (Fig. 6).

There was also a significant compression over the right ejaculatory duct.

Moreover, the distal part of vas deferens was compressed.

The patient was sent to a specialized urology center for correct planning treatment.

Discussion

Etiology and demographics

Renal agenesis associated with ipsilateral seminal vesicle cysts and obstruction of the ejaculatory duct is a triad of Wolffian duct anomalies and is known as the Zinner syndrome.

This syndrome is frequently associated with other anomalies such as ectopic ureter and megaureter as in our case [1,2].

Malformations of seminal vesicles and particularly seminal vesicles cysts are often associated with other abnormalities of the urogenital system development, such as unilateral renal agenesis.

In fact, both derive from mesonephric duct that form during the fourth week of gestation.

A defect of induction of ureteric bud from the metanephric blastema, often due to a deficiency of the bud development, can lead to lack or to a defect of the kidney formation.

Moreover, male people may have an atresia of the ejaculatory duct, due to a developmental abnormality of the distal part of Wolffian ducts.

Atresia of the ejaculatory duct leads over time to a collection of secretions in the seminal vesicle resulting in the formation of a cyst.

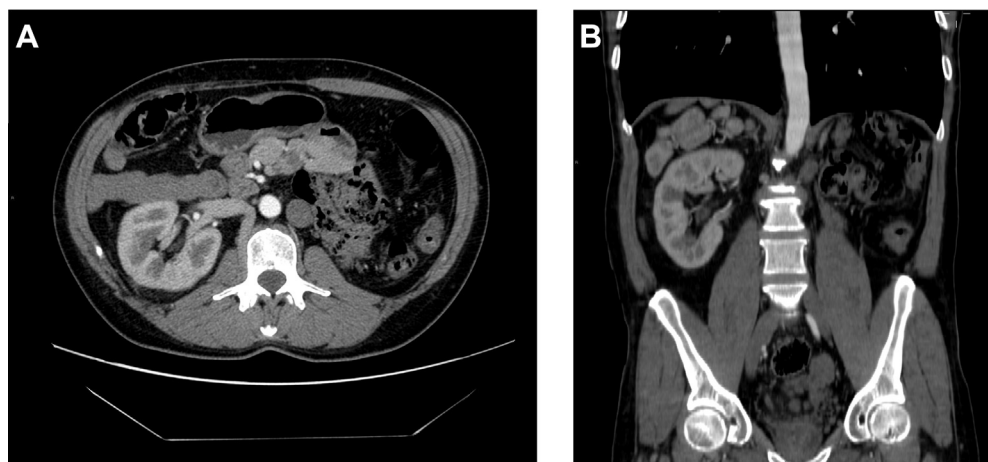


Fig. 2 – Contrast-enhanced axial CT of the abdomen (A) with coronal (B) reconstructions shows a left kidney agenesis.

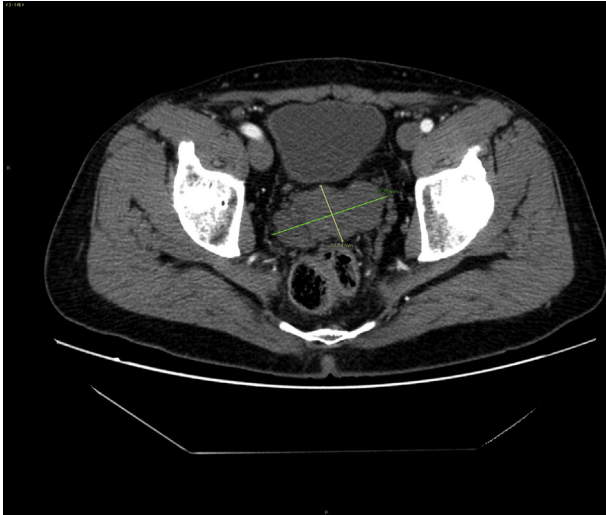

Fig. 3 – Axial CT of the pelvis demonstrated a large lobulated multiloculated cystic lesion of left seminal vesicle; after injection of intravenous contrast material, the cystic lesion did not show enhancement.

In addition, if the ureteric bud originates distal to the urogenital sinus, it has no time to become independent from the mesonephric duct and is dragged from its migration outside the primitive bladder, giving rise to an ectopic ureter.

In males, the ectopic ureter can flow into the back urethra, along the seminal vesicles, deferent duct, or epididymis [1,3,4].

The association of a seminal vesicle cyst with ipsilateral renal agenesis was first reported in 1914 by Zinner and subsequently came to be known as Zinner's syndrome [4].

The diagnosis is usually made between the second to fifth decade of life, when the cyst is enlarged enough to make symptomatic patients [5].

To our knowledge, this is the first case of seminal vesicle cysts combined with genitourinary anomalies and situs viscerum inversus.

In Taipei, an ultrasound-based study was performed which analyzed 280,000 children, demonstrating the presence of seminal vesicle cysts with 0.0%–0.46% incidence in patients with ipsilateral renal agenesis [6].

Clinical and imaging findings

Usually, the seminal vesicles cysts remain symptomatically silent until they grow up to at least 5 cm, sparking an inflammation of the genitourinary system.

Van den Ouden et al. studied 52 patients with Zinner's syndrome and found that the most common symptoms include dysuria (37%), frequency (33%), perineal pain (29%), epididymitis (27%), and pain after ejaculation (21%) [7].

Patients may be asymptomatic or have aspecific perineal pain or infertility [8].

Pavan et al. demonstrated a unique case of paratesticular mass mimicking a varicocele [9].

Several diagnostic instruments can be used to differentiate seminal vesicles cysts from other pelvic masses.

First you may choose to proceed with a noninvasive technique as US or transrectal ultrasonography in evaluating patients with suspected mesonephric duct development failure [10].

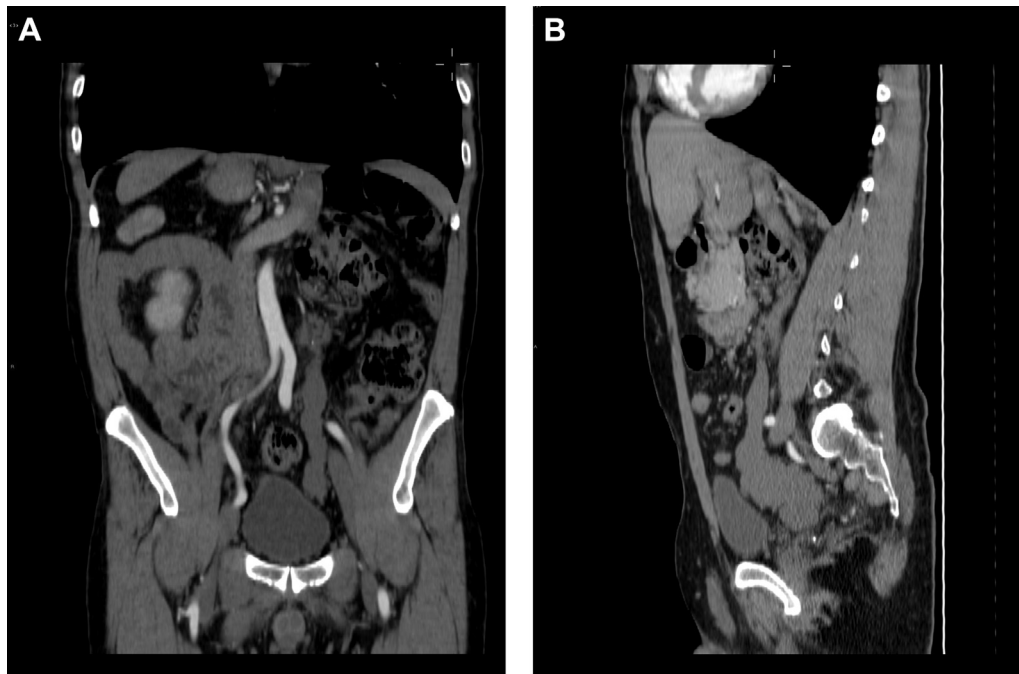


Fig. 4 – Axial TC images (A) with sagittal reconstruction (B) reveal a saccular dilated enlarged ectopic ureter opening into the cystic left seminal vesicle.

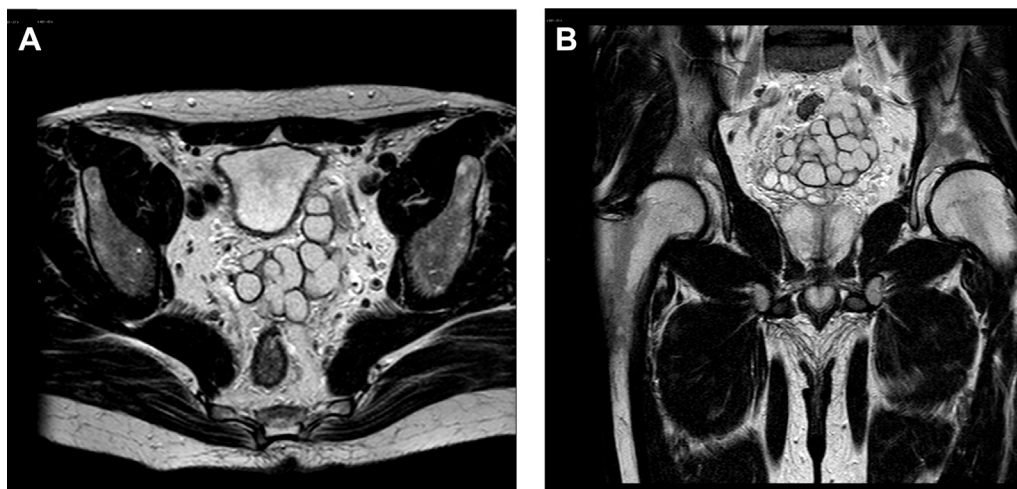


Fig. 5 – Axial MRI of the pelvic region (A), with coronal reconstructions (B) demonstrates a located cystic lesion in region of left seminal vesicle. The cystic lesion appeared bright on T2-weighted images.

This examination can detect the presence of an anechoic mass in the region of the seminal vesicles; however, it is an operator-dependent method and also is a very limited examination that does not allow for an extensive study of pelvic organs, such as computed tomography (CT) and magnetic resonance imaging (MRI).

Kenney et al. [11] reported a large spectrum of image findings, ranging from a cystic pelvic mass with a thick irregular wall to apparent enlargement of the ipsilateral seminal vesicle.

Other reported findings include a well-defined low-attenuation retrovesicular mass arising from the seminal vesicle, cephalic to the prostate gland [2].

Thanks to multiplanar imaging and the use of differently weighted sequences, MRI can thoroughly evaluate all pelvic organs and may also characterize, also through the use of post contrastographic sequences, any pelvic masses.

This leads not only a definitive diagnosis, but the imaging may be useful for surgical planning of seminal vesicles cyst excision, as it shows anatomic relationships between the different pelvic structures.

On MRI, seminal vesicle cysts are of variable signal intensity on T1-weighted images, are generally of fluid signal intensity on T2-weighted images, and are nonenhancing after IV gadolinium administration. Increased T1-weighted intensity is thought to reflect hemorrhage or an increased concentration of proteinaceous fluid [2].

Sometimes MRI can show the connection between ectopic ureter and seminal vesicle, which quite often is lost at TC investigation [12].

Seminal vesicles cysts come into differential diagnosis with several cystic diseases of pelvic organs. These include true cysts of the prostate gland, ureteroceles, müllerian duct cysts, and Gartner's duct cyst [13].

Features which help us to make the differential diagnosis are cyst position, (median, paramedian, or lateral), developmental abnormalities associated such as renal agenesis or anomalies of the external genitalia and not least the MRI characteristics.

Treatment

Treatment can be conservative.

For more than 5 cm or symptomatic cysts, the best treatment is laparoscopic surgery because it has the advantage of magnification, good visualization, direct approach, and less invasiveness [14].

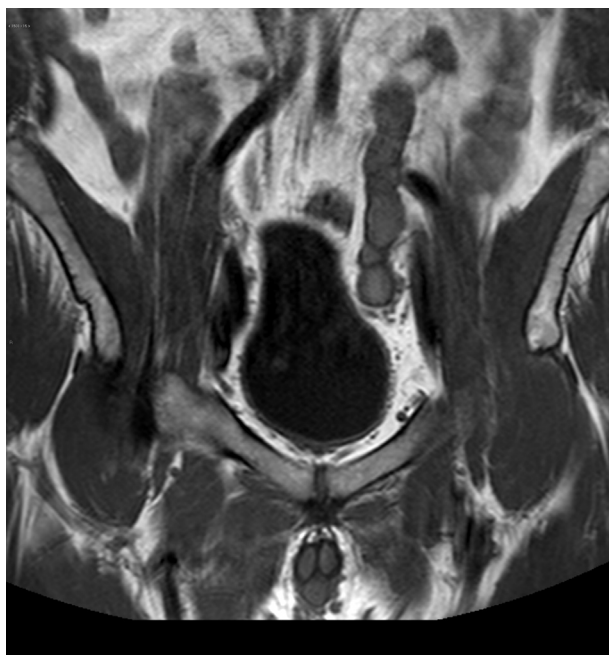


Fig. 6 – The coronal T1-weighted image showed a dilated and ectopic ureter draining into the left seminal vesicle with a length of 10 cm.

In conclusion, both CT and MRI allow to properly investigate renal and seminal vesicles anomalies which are often combined. MRI exceeds CT in studying abdomen and pelvis not only for the absence of ionizing radiation but also for its imaging capability and soft tissue contrast which are crucial features in the assessment of relations between pelvic organs and structures.

REFERENCES

- [1] Ghonge NP, Aggarwal B, Sahu AK. Zinner syndrome: a unique triad of mesonephric duct abnormalities as an unusual cause of urinary symptoms in late adolescence. *Indian J Urol* 2010;26(3):444–7.
- [2] Livingston L, Larsen CR. Seminal vesicle cyst with ipsilateral renal agenesis. *AJR Am J Roentgenol* 2000;175(1):177–80.
- [3] Cihan A, Cimen S, Secil M, Kefi A, Aslan G. Congenital seminal vesicle cyst accompanying ipsilateral renal agenesis and rudimentary ureter. *Int Urol Nephrol* 2006;38:133–5.
- [4] Cherullo EE, Meraney AM, Bernstein LH, Einstein DM, Thomas AJ, Gill IS. Laparoscopic management of congenital seminal vesicle cysts associated with ipsilateral renal agenesis. *J Urol* 2002;167:1263–7.
- [5] Kao CC, Wu CJ, Sun GH, Yu DS, Chen HI, Chang SY, et al. “Congenital seminal vesicle cyst associated with ipsilateral renal agenesis mimicking bladder outlet obstruction: a case report and review of the literature.” *Kaohsiung J Med Sci* 2010;26(1):30–4.
- [6] Sheih CP, Hung CS, Wei CF, Lin CY. Cystic dilatations within the pelvis in patients with ipsilateral renal agenesis or dysplasia. *J Urol* 1990;144:324–7.
- [7] Van den Ouden D, Blom JH, Bangma C, de Spiegeleer AH. Diagnosis and management of seminal vesicle cysts associated with ipsilateral renal agenesis: a pooled analysis of 52 cases. *Eur urol* 1998;33:433.
- [8] Pollack HM, McClennan BL. *Clinical urography*. Philadelphia: Saunders; 2000. p. 804–21.
- [9] Pavan N, Bucci S1, Mazzon G1, Bertolotto M2, Trombetta C1, Liguori G1. It's not always varicocele: a strange case of Zinner syndrome. *Can Urol Assoc J* 2015;9(7-8):E535–8.
- [10] Coşkun B, Dalkılıç A, Sönmez NC, Arsan S, Ofluoğlu Y, Ergenekon E. A case of seminal vesicle cyst associated with ipsilateral renal agenesis diagnosed during an investigation of urinary incontinence. *Turk J Urol* 2013;39(1):53–5.
- [11] Kenney PJ, Leeson MD. Congenital anomalies of the seminal vesicles: spectrum of computed tomographic Findings. *Radiology* 1983;149:247–51.
- [12] Arora SS, Breiman RS, Webb EM, Westphalen AC, Yeh BM, Coakley FV. CT and MRI of congenital anomalies of the seminal vesicles. *AJR Am J Roentgenol* 2007;189(1):130–5.
- [13] Kuo J, Foster C, Shelton DK. “Zinner's syndrome.” *World J Nucl Med* 2011;10(1):20–2.
- [14] Seo IY, Kim HS, Rim JS. Congenital seminal vesicle cyst associated with ipsilateral renal agenesis. *Yonsei Med J* 2009;50(4):560–3.