

A Porcine Model for Endolaparoscopic Abdominal Aortic Repair and Endoscopic Training

Bernardo D. Martinez, MD, Christopher K. Zarins, MD, David A. Daunt, DVM, PhD,
Leslie A. Coleman, DVM, Yamil Saenz, DVM, Thomas J. Fogarty, MD,
George D. Hermann, BSME, Camran R. Nezhat, MD, Eric K. Olsen, PhD

ABSTRACT

Objectives: The goals of this laboratory model were to evaluate the performance of the surgical team and endolaparoscopic techniques in the porcine model of infrarenal abdominal aortic repair.

Methods: Twenty-four pigs underwent full endolaparoscopic aorto-aortic graft implantation with voice-activated computerized robotics. The first group of 10 pigs (acute) was sacrificed while under anesthesia at 0.5 hours (5 animals) and 2 hours (5 animals). The second group of 14 pigs (survival) were recovered from anesthesia and maintained for 7 hours (5 pigs) and 7 days (9 pigs) prior to sacrifice. Survival animals were observed for evidence of hind limb dysfunction. All grafts were visually inspected at autopsy.

Results: All animals survived the operation. All grafts were successfully implanted, and all were patent with intact anastomoses at autopsy. Mean aortic clamp time for each group was as follows: acute, 92.9 ± 28.04 minutes; survival, 59.6 ± 13.8 minutes; $P=0.0008$. Total operative time for each group was as follows: acute, 179 ± 39.6 minutes; survival, 164.6 ± 48 minutes; $P=0.44$ ns. Estimated blood loss for each group was as follows: acute, 214 ± 437.8 mL; survival 169.2 ± 271 mL; $P=0.76$ ns.

The following outcomes were observed: 1 animal died

from respiratory arrest; 1 animal suffered motor sensory dysfunction of the hind limbs (spinal cord ischemia); significant bleeding occurred in 6 of 24 pigs; 8 of the 9 seven-day survivors required minimal pain medication and had normal hind limb function.

Conclusions: The reduction in aortic clamp time, total operative time, and blood loss as the study progressed indicate the feasibility of this surgical protocol and the maturation of the learning process, which is paramount in prevention of 2 main sources of morbidity: bleeding and spinal cord ischemia. The reduction in aortic clamp time between the acute and survival groups was dramatic and statistically significant. An intensive formal training program combining dry and live surgical laboratories is deemed essential for the development of endoscopic skill sets necessary for this challenging procedure.

Key Words: Endolaparoscopy, Abdominal aortic surgery, Endoscopic surgical training, Robotics.

INTRODUCTION

Minimally invasive abdominal aortic surgery has been a subject of great interest since Dion's pioneering work in 1993.¹⁻⁵ The laboratory animal model has been the first step of interaction between the endolaparoscopic surgical team and this new technology prior to clinical application. However, except for the survival studies of Bryne et al⁶ and Audra et al⁷, the problem of spinal cord dysfunction in an aortic endolaparoscopic model due to aortic cross clamping had not been systematically examined.

Our objective was to study the feasibility of infrarenal graft interposition involving 2 end-to-end anastomoses performed with a transperitoneal approach with full endolaparoscopic instrumentation. In addition to the technical aspects of the protocol, we focused particularly on the development of quantitative guidelines for training in the basic endolaparoscopic skills required. In addition to the motor skills, the learning process required adaptation to voice-operated computerized robotic equipment in this endolaparoscopic aortic laboratory model. The end points of training, instrumentation, and technique are 3: (1) control of bleeding, (2) long-term

Minimally Invasive Vascular Surgery Center, St. Vincent Mercy Medical Center, Toledo, Ohio, USA (Drs Martinez, Olsen).

Division of Vascular Surgery, Stanford University School of Medicine, Stanford, California, USA (Drs Fogarty, Zarins).

Department of Comparative Medicine, Stanford University, Stanford, California, USA (Drs Coleman, Daunt).

Ethicon Endo-Surgery University Branch for Education and Research Center, Department of Comparative Medicine, Stanford University, Stanford, California, USA (Dr Saenz).

Fogarty Research, Stanford, California, USA (Mr Hermann).

Stanford Endoscopy Center for Training and Technology, Stanford University School of Medicine, Stanford, California, USA (Dr Nezhat).

Address reprint requests to: Bernardo D. Martinez, MD, Director, Minimally Invasive Vascular Surgery Center, Suite 305, St. Vincent Mercy Medical Center, 2213 Cherry St, Toledo, OH 43608, USA. Telephone: 419 251 3512, Fax: 419 251 2715

© 2003 by JSLS, *Journal of the Society of Laparoendoscopic Surgeons*. Published by the Society of Laparoendoscopic Surgeons, Inc.

graft patency, and (3) elimination of spinal cord ischemia.

METHODS

This study was conducted between April 1998 and January 2000 under Protocol 6127-1 for care and use of laboratory animals at Stanford University, Stanford, California, USA. Twenty-four female pigs with an average body weight of 55 kg (SD±10.4 kg) were made to fast overnight, premedicated for surgery with atropine (0.04 mg/kg, IM), and sedated with tiletamine and zolazepam (Telazol, Lederele Parenteral, Inc, Carolina, Puerto Rico) at 6 mg/kg, IM. Anesthesia was induced with 3% halothane in oxygen delivered by facemask. All animals were orotracheally intubated and anesthesia was maintained with 1% to 3% halothane in oxygen with mechanical ventilation (Hallowell model 2000, Hallowell EMC, Pittsfield, MA, USA) to maintain end-tidal carbon dioxide between 35 mm Hg and 55 mm Hg.

Venous and arterial catheters were placed percutaneously for drug and fluid administration and blood pressure monitoring. Electrocardiogram leads were placed. Following instrumentation of the survival animals, a 20-gauge, 3.5-inch spinal needle (Monoject, Emergency Medical Products, Waukesha, WI, USA) was placed in the lumbosacral joint and morphine sulfate was injected epidurally at 0.1 mg/kg for analgesia.

Serial samples of hematocrit, total serum protein, and arterial blood gases were taken from the auricular arterial catheter. Blood gas samples were analyzed immediately on a calibrated blood gas analyzer (Ciba-Corning model 248, Global Medical Instrumentation, Inc, Albertville, MN, USA). Pulse oximetry (SpaceLabs model 90651A, Spacelabs Medical, Issaquah, WA, USA) and capnography (SpaceLabs model 1890-02, Spacelabs Medical, Issaquah, WA, USA) were performed frequently during anesthesia. Lactated Ringer's solution (Abbott Laboratories, Abbott Park, IL, USA) was administered intravenously at approximately 10 mL/kg/hr throughout anesthesia. Fresh whole, unmatched pig blood was administered to 2 pigs that had experienced intraoperative hemorrhaging. Dobutamine was administered as needed at 0.5 to 5 mcg/kg/min to maintain systemic arterial blood pressure.

The animals were placed in a full right lateral decubitus position (left side up) in the Trendelenburg position (**Figure 1**). Preliminary measurements were made for

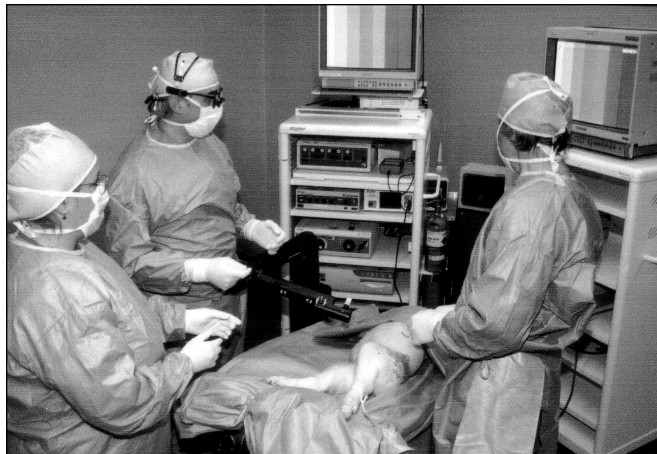

Figure 1. Position of pig and surgical team for endolaparoscopic aortic repair. Pig in the right lateral decubitus position with Trendelenburg positioning. Left to right: scrub nurse, surgeon, assistant. The labeled left costal margin is visible by the assistant's left hand. The AESOP robotic arm is in the center of the field; and the Hermes control system is to the right of the surgeon, who is wearing a voice-activation headset.

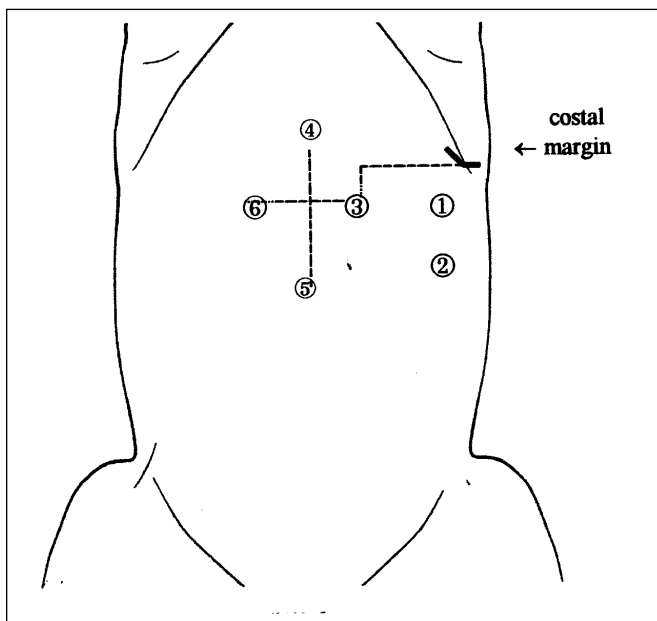


Figure 2. Port placement for porcine endolaparoscopic aortic repair model. (1) Proximal aortic clamping (18 mm). (2) Distal aortic clamping (18 mm). (3) Endoscope (10 mm). (4) Left hand instrument (5 mm). (5) Right hand instrument (5 mm). (6) Assist (10 mm). Starting at costal margin, 10 cm medially, then 3 cm caudally to (3), which is 5 cm from midline. (6) is 3 cm from midline. (4) and (5) are both 6 cm to 7 cm from the line between (3) and (6).

Table 1.
Endoscopic Motor Sensory Skill Acquisition:
A Formal Training Program

Camps	Time (hrs)	Stage	Goals
1	10	Basic Skills	Suture-Cutting (Exercise) Endoknots Equal Hands
2: Aesop and Hermes	30	Quality	Suture Anastomosis
3: Zeus	80	Quality and Speed	20-30 Minutes Anastomosis

positioning the working and clamping ports as indicated in **Figure 2**. The abdomen and groin were prepared with iodine-povidone solution and sterile drapes were applied. Endolaparoscopic instrumentation included the UltraCision Harmonic scalpel and Ethicon Endoscissors (Ethicon Endo-Surgery, Cincinnati, OH, USA); two 512-mm Ethicon Endopath® trocars for the 0° and 30° 10-mm endoscopes (Stryker Endoscopy, Mountain View, CA, USA) and the Nezhat-Schroeder suction irrigation system (Davol, Inc, Cranston, RI, USA); two 355-mm Ethicon Endopath trocars for the vascular instrumentation; two 18-mm GSI flexible ports (production rights currently held by Tyco/USSI, Norwalk, CT, USA) for proximal and distal clamping; the Ethicon Ligaclip clip applicator; two 5-mm needle holders and two 5-mm graspers (Ethicon Endo-Surgery, Cincinnati, OH, USA). CO₂ pneumoperitoneum was created via a 511H Ethicon Endopath nonbladed Optiview trocar or a Veress needle introduced through a small midline incision. The endoscope was positioned with a voice-activated AESOP® 3000 robotic system (Computer Motion, Inc, Goleta, CA, USA). Video functions, light source, and insufflation were remotely controlled with the Hermes voice-activated system (Stryker Endoscopy, Mountain View, CA, USA; Computer Motion, Inc, Goleta, CA, USA).

The surgical team consisted of the endolaparoscopic surgeon, 1 assistant, and 1 scrub nurse. The surgeon had previously trained on a dry laboratory pelvic trainer. At the beginning of the study, the surgeon had accomplished 65 hours of endolaparoscopic training, increasing to 180 hours by the end of the study. The endoscopic training protocol used is divided into the following 3

phases (**Table 1**): 10 hours are devoted to dry laboratory practice in endoscopic suturing, cutting, endo- and exoknot tying (Phase I); 20 hours are devoted to endoscopic suture anastomosis of 8-, 10-, and 12-mm grafts in vitro to develop technical precision (Phase II); and 50 hours are devoted to increasing both quality and speed of anastomosis until they can be completed within 20 minutes to 30 minutes (Phase III).

The transperitoneal approach was deliberately selected as potentially the most difficult procedure for maximum training benefit. This approach was maintained throughout the study so that all procedures could be directly compared as to time parameters and surgical outcome. Trocars and ports were positioned in the abdomen, instrumentation was introduced, and bowel loops were moved to the right side of the abdomen to expose the posterior peritoneum, which was entered with the Harmonic scalpel. Approximately 5 cm of infrarenal aorta was dissected with a combination of blunt and sharp instrumentation, including the UltraCision Harmonic scalpel and Endoscissors. The lumbar branches were visualized and controlled with the Ligaclip endoscopic clip applicator. Systemic heparinization (3 mg/kg IV) was then initiated, and the proximal aorta was clamped with a conventional aortic or carotid clamp (**Figure 3**). Distal aortic occlusion was obtained with a #6 Fogarty venous balloon catheter (Edwards Lifesciences, LLC, Irvine, CA, USA) introduced via the femoral artery in 7 of the 10 acute animals, or an iNTrack clamp (Novare Surgical, Cupertino, CA, USA) in all remaining animals.

Vertical transection of the aortic wall was performed with 5- or 10-mm Endoscissors. An 8- or 10-mm diameter polytetrafluoroethylene graft (IMPRA, Inc., Tempe, AZ, USA) was implanted by continuous end-to-end suture anastomosis with 4-0 and 3-0 Prolene with a TF or BB needle (Ethicon, Sommerville, NJ, USA) and 5-mm endoscopic needle holders. A 10- or 12-cm suture provided optimal ergonomics for tying Endoknots. Then the distal clamp was released and the anastomosis was examined for leaks. Gelfoam (Upjohn Pharmaceuticals, Chicago, IL, USA) was used to control needle site holes. Finally, the proximal clamp was gradually released. The posterior peritoneum was closed with staples and, in the survival group, the port sites were closed with absorbable suture.

The animals were divided into the following 2 groups: acute (10 animals) and survival (14 animals). Five of the acute animals were maintained under anesthesia for 0.5

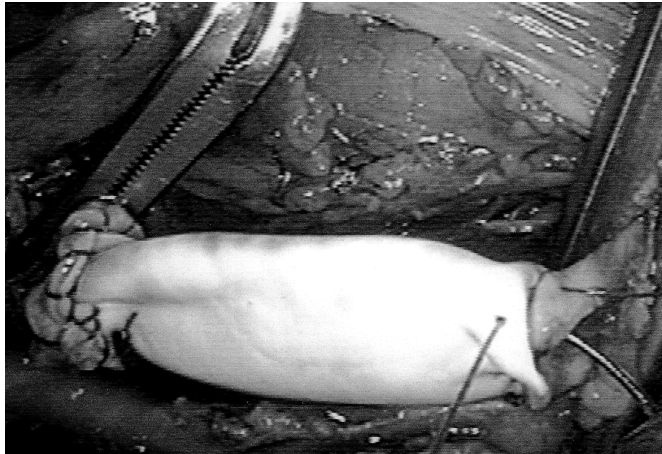


Figure 3. Suturing the distal aortic graft anastomosis with conventional clamps.

hour following surgery and 5 for 2 hours prior to being sacrificed. Five of the survival animals were recovered from anesthesia and maintained for 7 hours, and 9 were maintained for 7 days prior to sacrifice and autopsy. Animals were scored for several behavioral criteria postoperatively. Upon autopsy, 1 cm of proximal and 1 cm of distal host aortic tissue, including the graft end and anastomosis, were harvested, visually inspected under 3.5 times magnification for suture line integrity and photographic analysis. Data groups were compared with 2-tailed Student *t* tests, assuming unequal variance.

RESULTS

Full endoscopic infrarenal aortic grafts involving 2 end-to-end anastomoses was successfully completed in all 24 animals (**Table 2**). Mean aortic clamping time was

92.9±28.04 minutes in the acute group and 59.6±13.8 minutes in the survival group (**Table 3**). Mean total operative time was 179±39.6 minutes for the acute group and 164.6±48 minutes in the survival group. Mean blood loss was 214±437.8 mL for the acute group and 169.2±271 mL for the survival group.

One animal in the survival group died of respiratory arrest due to airway obstruction 2 hours postoperatively, and the other 13 survived until the prescribed sacrifice. Only 1 animal suffered from hind limb dysfunction, due to a prolonged aortic clamping time of 92 minutes. This resulted from a size mismatch between the preselected graft (10 mm) and the host aorta (7 mm), necessitating additional suturing to complete the anastomosis. The animal was able to stand up with assistance but could not ambulate on its own due to severe proprioceptive anesthesia. Histology of the spinal cord showed medullary infarctions, mostly localized in the posterior sensory horns, which is consistent with the clinical symptoms.

Bleeding complications occurred in 6 animals from lumbar branches and a vena cava branch tear during dissection. In 4 animals, control was obtained endoscopically. However, in the case of the caval tear and a proximal/distal lumbar artery tear, the bleeding was more difficult to control, requiring conversion to a mini-laparotomy (5 cm). These animals required 1 unit of packed red cells (250 mL) each.

No bleeding at the graft anastomoses was found on autopsy. The 24 grafts were patent, and all the suture anastomoses were found intact. Two grafts were found to have an isolated 10 x 8-mm adherent blood clot at the anastomotic suture line. All retroperitoneal spaces had perigraft hematomas, which were expectedly small except for in 1 animal that had an estimated 100 mL clot

Table 2.
Porcine Endoscopic Abdominal Aortic Resection Model*

Type of Procedure	Weight of Pig	Aortic Clamp Time	Total Operative Time	Estimated Blood Loss
Acute (n = 10)	63.4 kg ± 6 kg	92.9 m ± 28 m	179 m ± 39.6 m	214 mL ± 437.8 mL
Survival (n = 14)	49.1 kg ± 8.6 kg	59.6 kg ± 13.8 m	164.6 m ± 48 m	169.2 mL ± 271 mL
Significance (<i>t</i> test)†	<i>P</i> = 0.00008	<i>P</i> = 0.0046	<i>P</i> = 0.43 ns	<i>P</i> = 0.34 ns

*Values are group means and standard deviations.

†The surgical time and blood loss parameters for the early (acute) procedures are compared with the later (survival) procedures: ns = not significant.

Table 3. Parameters of Experimental Abdominal Aortic Endolaparoscopic Repair Models

Author	Animal Model	Procedure	Surgical Approach*	No. of Anastomoses*	Aortic Clamp Time (min)	Total Operative Time (min)	Total Blood Loss (mL)
Dion et al 1995 ²	Porcine acute (n=26)	Aortobifemoral	TP	1 Aortic 2 Femoral	85–120†	<240	<250
Byrne et al 1995 ⁶	Canine survival (n=8‡)	Aortobifemoral	TP = 15 RP = 7	1 Aortic 2 Femoral	87 ± 20.6	193 ± 12.3	128 ± 128.1
Ahn et al 1995 ⁹	Porcine acute (n=10)	Aorto-left femoral	TP = 7 RP = 3	1 Aortic§ 1 Femoral	Not reported	147 (120–240)	20 (5–50)
Chen et al 1996 ¹⁰	Porcine acute (n=23)	Custom tube graft	TP = 21 RP = 2	2 Aortic	Not reported	Not reported	Not reported
Dion et al 1996 ³	Porcine acute (n=8)	Aortobifemoral	Ant RP	1 Aortic 2 Femoral	Not reported	270	“Never >550”
Jones et al 1996 ¹¹	Porcine acute (n=10)	Aorto-right femoral¶	TP = 5 RP = 5	1 Aortic 1 Femoral	TP: 27 ± 5 RP: 28 ± 5	TP: 161 ± 22 RP: 192 ± 1	Not reported
Bruns et al 1998 ¹²	Porcine acute (n=20)	Aortobifemoral	TP = 10 RP = 10	1 Aortic 2 Femoral	TP: 60 (45–75) RP: 75 (60–90)	TP: 240 (210–270) RP: 270 (240–300)	Not reported
Hill et al 1998 ¹³	Canine acute (n=5)	Aorto-left femoral#	RP	1 Aortic# 1 Femoral	95	286	400 (1 “Minimal” (4)
Audra et al 2000 ⁷	Porcine survival (n=11)	Thoracic Aorto-left femoral#	Intraleural	1 Aortic# 2 Femoral	74 (53–155)	310 (276–338)	611 (250–1300)
Martinez et al (this study)	Porcine acute (n=10) Porcine survival (n=14)	Aortictube graft	TP	2 Aortic	Acute: 93 ± 28 Survival: 59.6 ± 14	Acute: 179 ± 39.6 Survival: 164.6 ± 48	Acute: 214 ± 437.8 Survival: 169 ± 271

*RP: retroperitoneal; TP: transperitoneal.
 †Combines reported clamp + aortotomy and aortic anastomosis times.
 ‡8 of 24 animals were total laparoscopic procedures.
 §4 end-to-side transperitoneal; 1 retroperitoneal (sutured); 2 end-to-end tranperitoneal; 2 retroperitoneal (tied to a cuff).
 ¶4 simulated an AAA resection.
 ¶A 4-cm open incision was made to complete the end-to-side aortic anastomosis.
 #End-to-side aortic anastomosis.

in the retroperitoneal space and about 200 mL of free serosanguinous intraperitoneal fluid. The nine 7-day survivors were evaluated postoperatively and scored for behavioral criteria. Animals required very little pain medication during the first 24 hours. No wound complications occurred. The 12 survivors with normal hind limb function became ambulatory between 3 and 20 hours postoperatively.

DISCUSSION

Procedure

Nezhat et al⁸ aptly characterized the frontiers of laparoscopic surgery in 1992 as being limited only by the imagination of the surgeon coupled with the progressive development of endolaparoscopic instrumentation. These included the possibilities of coronary bypass by endoscope as had been performed in a porcine model.⁸ Although we demonstrated the feasibility of full endoscopic repair of the abdominal aorta with a tube graft, one of our main goals was the documentation of performance improvement of the surgical team, as reflected by a reduction in surgical time parameters and bleeding as the study progressed. A comparison of the 10 early procedures with the 14 later surgeries indicates a modest reduction in total operative time and estimated blood loss that was not statistically significant. More importantly, a dramatic and highly significant reduction occurred in the aortic cross-clamp time for graft anastomosis: a parameter we deem most vital to surgical outcome and postoperative morbidity. Although other animal models for endolaparoscopic aortic repair have utilized a variety of protocols, grafts, and instrumentation (**Table 3**),^{2,3,6,7,9-13} we observe that our aortic clamp times and total operative times are less than or equal to those of other studies to date, even though they include two demanding intraabdominal anastomoses performed with full endolaparoscopic technique with Endoknot tying. Of course, rapid evolution of endoscopic techniques and instrumentation has occurred since the earliest animal models were developed. Most investigators have reported an observable reduction in surgical time parameters that comes through training and experience, although the learning curve for this procedure may be steep.^{3,6,7,10,13}

Difficulties in retracting the small bowel have led some investigators to prefer a retroperitoneal approach,^{2,3,12} although one study preferred the transperitoneal approach¹⁰ and two others found both approaches equally acceptable.^{9,11}

Robotics

The use of the voice-operated computerized robotic AESOP and Hermes systems greatly improved the level of precision obtainable by the surgeon for visualizing the operative field and recording the procedure for future analysis.¹⁴ This technology reduces the surgeon's dependence on assistants and the associated delays for communication and manual adjustments.

Bleeding

Certainly one of the most difficult tasks in endolaparoscopic surgery is controlling bleeding. Our model demonstrated that secure proximal clamping is critically important in reducing blood loss. The use of the 18-mm GSI flexible ports proved invaluable in permitting the use of conventional instruments for secure proximal and distal clamping while maintaining the pneumoperitoneum. On the other hand, the use of the endoluminal Fogarty balloon for distal aortic occlusion has certain benefits for control in the relatively low-pressure distal aorta. In the absence of a second clamp, more working space is available for the surgeon's instruments. In case of excessive lumbar bleeding, the balloon may be advanced and positioned to help tamponade the site.

Much of the bleeding encountered involved the lumbar vessels, which, in the pig, are very delicate and subject to tearing during aortic dissection. Although this increases the surgical challenge, only 6 of 24 animals (25%) had intraoperative bleeding problems, and only 2 of these (8%) required conversion to a minilaparotomy. We strongly advocate that the endoscopic surgeon always be ready to make an abrupt conversion to open surgery for bleeding control.

Spinal Cord Ischemia

Aortic clamping for graft anastomosis can produce hind limb dysfunction if prolonged. Excessive clamp time in turn is often a function of bleeding problems that may obscure the surgical field and required additional suturing time. In other endolaparoscopic survival studies, Bryne et al⁶ observed paraplegia in 3 of 8 dogs and Aurdra et al⁷ recorded 1 case of paraplegia out of the 9 pigs that survived the procedure. Both studies had clamp times in excess of 100 minutes for some cases. The single case of hind limb sensory dysfunction in our study resulted from a technical error that significantly delayed the anastomosis. All other surviving animals had good

ambulation, in one case within only 3 hours after surgery, after clamp times of less than 90 minutes. We also feel that by taking extra care to minimize aortic dissection and preserve the lumbar vessels, we were able to maintain a better blood supply to the spinal cord.

Training

Other studies have not emphasized the importance of training, although the majority of investigators have taken aortic clamp time and total operative time as benchmarks for performance. The majority of investigators observed a reduction in surgical time as the studies progressed.^{3,6,7,10,13} Aortic clamp time measures the performance of the entire surgical team, particularly the skill of the surgeon and assistant in completing the anastomoses. The integration of the team with the instrumentation and equipment is critical in minimizing this time while preserving the quality of the anastomoses. In our model, the surgeon was committed to a rigorous training protocol as indicated in **Table 1**. The most important aspect of technical proficiency is the brain-eye-hand coordination that must be developed in the motor sensory cortical and subcortical portions of our brain. The simulation in vitro of the type of anastomosis used was very important in this skill development process.

Finally, voice training in the integration of voice-activated AESOP and Hermes robotics, ie, using your voice rather than your hands to direct an instrument or device, made a critical improvement in clamp time as shown in **Table 2**. Voice training is a new experience for the surgeon and requires an integration of the visual and the motor speech areas of the occipital and parietal lobes never before required by the surgeon in the learning and memory process.

CONCLUSION

Nezhat et al⁸ aptly characterized the frontiers of laparoscopic surgery in 1992 as being limited only by the imagination of the surgeon coupled with the progressive development of endolaparoscopic instrumentation. Total endolaparoscopic abdominal aortic replacement with a transperitoneal approach through a pneumoperitoneum is technically feasible and can be completed within a time frame as good as or better than that of retroperitoneal approaches and alternative graft options in other animal models reported in the published literature to date. Although the surgical time may be greater than that

for open procedures, postoperative outcome was of a very good quality in our survival animals. Requirement for pain medication was minimal. Full control of hind limbs and ambulation was obtained as early as 3 hours postoperatively.

A disciplined and intensive training regimen is essential for achieving the necessary skill set for this challenging procedure, but we believe it will become a regular option to reduce postoperative pain, morbidity and hospital stay in select patients. We strongly advocate a comprehensive formal training program combining dry and live surgical laboratory models for surgeons to acquire motor-sensory skills and anatomical familiarity before attempting clinical application.

References:

1. Dion YM, Katkhouda N, Roleau C, Aucom A. Laparoscopy-assisted aortobifemoral bypass. *Surg Laparosc Endosc.* 1993;3:425-429.
2. Dion YM, Chin AK, Thompson TA. Experimental laparoscopic aortobifemoral bypass. *Surg Endosc.* 1995;9:894-897.
3. Dion YM, Gracia CR. Experimental laparoscopic aortic aneurysm resection and aortobifemoral bypass. *Surg Laparosc Endosc.* 1996;6:184-190.
4. Dion YM, Gracia CR. A new technique for laparoscopic aortobifemoral grafting in occlusive aortoiliac disease. *J Vasc Surg.* 1997;26:685-692.
5. Dion YM, Gracia CR, Estakhri M, Demalsy JC, Douville Y, Piccinini E, Stancanelli V. Totally laparoscopic aortobifemoral bypass: a review of 10 patients. *Surg Laparosc Endosc.* 1998;8:165-170.
6. Byrne J, Hallett JW, Kollmorgen CF, Gayari MM, Davies W. Totally laparoscopic aortobifemoral bypass grafting in an experimental model: description of technique with initial surgical results. *Ann Vasc Surg.* 1996;10:156-165.
7. Audra AN, Gloviczki P, Young MM, Karnicki K, Deschamps C, Moir C. Videoendoscopic thoracic aorta-to-femoral artery bypass in the pig. *J Surg Res.* 2000;93:70-74.
8. Nezhat C, Nezhat F, Nezhat C. Operative laparoscopy (minimally invasive surgery): state of the art. *J Gyn Surg.* 1992;8:111-139.
9. Ahn SS, Clem FF, Braithwaite MA, Concepcion B, Petrik PV, Moore WS. Laparoscopic aortofemoral bypass: initial experience in an animal model. *Ann Surg.* 1995;222:677-683.
10. Chen MH, Murphy EA, Levison J, Cohen JR. Laparoscopic aortic replacement in the porcine model: a feasibility study in preparation for laparoscopically assisted abdominal aortic

aneurysm repair in humans. *J Am Coll Surg*. 1996;183:126-132.

11. Jones DB, Thompson RW, Soper NJ, Olin JM, Rubin BG. Development and comparison of transperitoneal and retroperitoneal approaches to laparoscopic-assisted aortofemoral bypass in a porcine model. *J Vasc Surg*. 1996;23:466-471.

12. Bruns CJ, Wolfgarte B, Kasper M, Zenner D, Walter M, Manich B. Gasless videoendoscopic implantation of aortobifemoral vascular prosthesis via transperitoneal versus extraperitoneal approach in an animal model. *Surg Endosc*. 1998;12:137-141.

13. Hill AB, MacKenzie KS, Steinmetz OK, Fried GM. Videoendoscopic thoracic aorta-to-femoral artery bypass. *J Vasc Surg*. 1998;27:948-954.

14. Kavic MS. Robotics, technology, and the future of surgery. *JLS*. 2000;4:277-279.

Acknowledgments: Partial financial support for this study has been provided by the following companies: Fogarty Research; Ethicon Endo-Surgery; Computer Motion; IMPRA, Inc.; Stryker Endoscopy, and Tyco/USSI. We would also like to thank our scrub nurses, Elisa Marles, RN, and Carol Worden, RN, Stanford Health Services, Stanford, CA, USA for their invaluable assistance during the study.

Disclosure: Thomas J. Fogarty, MD, and George D. Hermann, BSME, are affiliated with Fogarty Research, which developed several instruments used in this study. Yamil Saenz, DVM, is presently employed by Ethicon Endo-Surgery, which produces many of the instruments used in the study.