

ORIGINAL PAPER

doi: 10.5455/medarch.2021.75. 269-273

MED ARCH. 2021 AUG; 75(4): 269-273

RECEIVED: JUN 18, 2021

ACCEPTED: AUG 12, 2021

¹Department of Cardiology, Medical College, University of Kufa, Iraq²Al Najaf Cardiac Center, Kufa, Iraq

Corresponding author: Ali Yahya Abdullah Alsallami. Assistant professor in Interventional Cardiology, Department of Cardiology, Medical College, University of Kufa, Iraq, E-mail: aliy.alsalime@uokufa.edu.iq, ORCID ID//www.orcid.org/ https://orcid.org/0000-0001-7653-9203.

Blood Pressure Behavior After Correction Adult Coarctation of Aorta Short Term Follows Up

Ali Yahya Abdullah Alsallami¹, Khalid Amber²**ABSTRACT**

Background: Coarctation of aorta (CoA) is a relatively common congenital cardiac defect often causing few symptoms and therefore can be challenging to diagnose. Usually, untreated CoA may lead to a renal, vascular and cardiac complication that starts to appear at beginning of the fourth decade of life. Several methods have been proved as a modality for the treatment of CoA like balloon dilation, stenting, and surgery, etc. **Objective:** To assess the hypertensive condition after endovascular stenting adult with CoA in short term follow up. **Methods:** We report the outcome in 75 patients, out of these 30 male patients (40%) and 45 female patients (60%) were involved in this prospective longitudinal study, their age range between 16 to 41 years. Stenting of simple coarctation was performed on 75 patients at the Cardiology consult department in Al-najaf cardiac center or from a private clinic between January 2018 to January 2019. For the treatment of all patients, echocardiography, CT chest done to confirm diagnosis then all undergo catheterization of aorta with two sheaths one femoral and other radial to measure pressure gradient across the stenosis and stent localization follow by stenting with pre and post-dilation if needed then measure pressure gradient across stent. **Results:** Out of 75 patients 69 patients (92%) returned for the 6-month follow-up evaluation and 53 patients (70%) returns for the 1-year follow-up evaluation with stent implantation, interrupted coarctation immediately after stent pressure gradient falls in almost all our patient. The patient returns at the time of 6 months and one year follow up, the assessment was done through CT angiography. At the time of six months, 39/69 patients (52%) and at the time of 1 year 18/45 patients (24%) show no aortic wall injury or aneurysm development. **Conclusion:** Uncovered stents appear to be safe in treating CoA with less morbidity and mortality. Stent adult with CoA has the advantage of lowering blood pressure in those suffering from hypertension.

Keywords: Coarctation of aorta (CoA), adult congenital heart diseases, hypertension, interventional cardiology, computed tomography angiography (CTA).

1. BACKGROUND

Coarctation of the aorta (CoA), is a congenital heart defect characterized by constriction of aorta which accounts for 5-8% of all congenital heart defects. CoA may occur as an isolated defect or in association with various other lesions, most commonly bicuspid aortic valve and ventricular septal defect (VSD) and it is most commonly occurs just below the beginning of the subclavian artery (1, 2). Due to CoA, Patients can develop congestive heart failure disease (CHF) which is common in children, and hypertension which is common in older ones if the diagnosis is delayed. The following complication can occur due to untreated coarctation of aorta like cardiac renal, vascular complication which usually starts to appear at beginning of the fourth decade of life (3-6). Hypertension, also known as high or raised blood pressure, is a condition in which the blood vessels have persistently raised pressure. Hypertension is divided into two types namely Refractory hypertension (primary/essential hypertension) and Secondary hypertension. Hypertension classifies according to the level of blood pressure measurements by sphygmomanometer to stages of hypertension (Table 1).

When the systolic pressure remains elevated above 140 mm Hg and diastolic pressure remains elevated above 90 mm Hg, condition known as hypertension. If there is an increase in only systolic pressure it is called systolic hypertension. Changes in lifestyle and proper medications which including a long-acting thiazide which is a diuretic, a calcium channel blocker like amlodipine (5-10 mg orally daily), and a beta-blocker (atenolol 50-100 mg oral-

© 2021 Ali Yahya Abdullah Alsallami, Khalid Amber

This is an Open Access article distributed under the terms of the Creative Commons Attribution Non-Commercial License (<http://creativecommons.org/licenses/by-nc/4.0/>) which permits unrestricted non-commercial use, distribution, and reproduction in any medium, provided the original work is properly cited.

Category	Systolic bp (mm Hg)	Diastolic bp (mm Hg)
Normal	<120	<80
Prehypertension (elevated)	120-129	80
Stage 1	130-139	80-89
Stage 2	>140	>90

Table 1. Normal and raised value of blood pressure

ly daily). There are also other group of drugs which are used to control hypertension apart from this e.g. ACE inhibitors, vasodilators, etc. will help to lower blood pressure and may reduce the risk of health hazards that occurs in hypertension (7).

2. OBJECTIVE

The aim of this study was to assess the hypertensive behavior after endovascular stenting adult with CoA in short term follow up.

3. PATIENTS AND METHODS

We include 75 people, from January 2018 to January 2019, who all had been selected from the private cardiac clinics or visited Al-Najaf’s Cardiology department, all are our patients suffering from coarctation of aorta. Initially, data like name sex, age, blood group, weight, and work profession has been collected from each n every patient, with initial blood pressure, other laboratory findings which include blood glucose, renal function test, lipid profile, blood creatinine. Echocardiography has been done on all patients and after confirming the diagnosis CT scan of the chest was done to confirm the diagnosis of coarctation of aorta in patients, among 50% of them shows stenosis of aorta.

Across the stenosis, for measuring the invasive pressure gradient aortic catheterization with the help of two sheets one femoral and other radial had been done. Modify Seldinger technique is used for safe access during femoral catheterization and Seldinger technique used for radial catheterization. To reach coarctation via femoral sheet a multipurpose guided catheter with guidewire is used.

To reach coarctation via radial sheet after passing from brachiocephalic artery and descending aorta pig-tail catheter with guided wire is used. If the coarctation is suggested for intervention a multipurpose guided catheter with guided wire need to pass through coarctation until we reach the aortic sinus after that guided wire needs to be replaced by stiff guided wire then small sheets need to be replaced with larger ones as for stenting and ballooning, generally, 9Fr size sheaths are used. To achieve zero gradient pressure across coarctation following steps are need to be done initially via radial contrast injection with fluoroscopy for the localization of stent position which is followed by stenting with Palmaz uncover stent after pre and post-dilation if needed then measuring pressure gradient across stent if all the procedure followed properly pressure will come down to zero mm Hg and procedure regards as successful. In all patients before and after stenting invasive blood pressure recorded with follow-up measurement of the

Number of patients	75
Sex	30 Male (40%)/ 45 Female (60%)
Age (year)	16-41/25.7 years (SD ±6.6)
Hypertension	75
Diabetic	3
Smoker	5
Previous surgical correction	0
Associated bicuspid aortic valve	51
Renal impairment	0
Stroke	1
Left ventricular hypertrophy	59

Table 2. Personal and medical history of patient

upper limb in both arms by sphygmomanometer on the first day after 1 month followed by 6 months and 1 year. To know the presence of aortic wall injury or development of aneurysm if any, all patients followed up with a CT scan of the chest after 6 months and 1 year. Table 2 shows the demographic data of patients included in this study.

Indication for intervention in coarctation of aorta patient

If aortic stenosis is > 75% or blood pressure across the stenosis is more than 20 mm Hg in such cases angiography is indicated. There is patient inclusion and exclusion criteria for the treatment are described below.

Inclusion Criteria

- a) Aortic coarctation, either native or recurrent;
- b) A pressure gradient across the stenosis that is invasively greater than 20 mm Hg;
- c) Aorta CT scan reveals an interrupted or continuous aorta;
- d) A patient with symptomatic stenosis and an intrusive pressure gradient of less than 20 mmHg across the stenosis.

Exclusion Criteria

- a) Maintain a healthy blood pressure level during pregnancy;
- b) Aortic aneurysm that can be surgically repaired;
- c) Previous stent coarctation;
- d) A pressure gradient of less than 20 mmHg throughout the stenosis without symptoms;
- e) Patient unwillingness.

Investigation

Initially, data like name sex, age, blood group, weight, and work profession has been collected from each n every patient, with initial blood pressure measures, other laboratory findings which include blood glucose, renal function test, lipid profile, blood creatinine.

Echocardiography has been done on all patients and after confirming the diagnosis CT scan of the chest was done to confirm the diagnosis of coarctation of aorta in patients, among 50% of them shows stenosis of aorta.

Treatment

There are several treatments are available for the correction of CoA such as balloon angioplasty, stenting, stent grafting, hybrid repair. All of these methods uncovered stent is proved better option for correction of CoA.

Techniques used for the treatment of CoA

Modify Seldinger technique is used for safe access during femoral catheterization and Seldinger technique used for radial catheterization.

To reach coarctation via femoral sheet a multi-purpose guided catheter with guidewire is used.

To reach coarctation via radial sheet after passing from brachiocephalic artery and descending aorta pigtail catheter with guided wire is used.

If early intervention is indicated, a multifunction guided catheter with guided wire must be sent through the coarctation until it reaches the aortic sinus, after which the guided wire must be changed with stiff guided wire, and small sheets must be changed with larger sheets, as with stents and balloons.

To achieve zero gradient pressure across coarctation following steps are need to be done initially via radial contrast injection with fluoroscopy for the localization of stent position which is followed by stenting with Palmaz uncover stent after pre and post-dilation if needed then measuring pressure gradient across stent if all the procedure followed properly pressure will come down to zero mm Hg and procedure regard as successful.

Differential diagnosis

- Dilated Cardiomyopathy;
- Pediatric Valvar Aortic Stenosis;
- Congestive heart failure (children);
- Pediatric viral myocarditis.

Patients with coarctation have both hereditary and environmental risk factors, similar to how hypertension has both genetic and environmental risk factors (8, 9). Untreated hypertension can cause significant mortality and morbidity, therefore it's critical to keep it under control. 19 Our study focuses on the benefits of lowering blood pressure by stenting CoA. After a year of follow-up, only 15% of patients who participated in the study still have hypertension, while 85% of patients no longer have hypertension, which is consistent with COSTA 2 trial 25. One finding of this study is that most patients' blood pressure improves immediately after CoA stenting, then rises after a few weeks, but after a year, more than two-thirds of patients had regulated blood pressure readings with or without medication.

Statistical analysis

We utilize mean and standard deviation as descriptive statistics for continuous data and number and percentage as descriptive statistics for categorical data. We utilize paired t-test for continuous variables and chi-square for categorical variables for analysis. EXCEL Microsoft 2016 software is used to perform all calculations.

4. RESULTS

Sources of data

In this study were included 75 people, from January 2018 to January 2019, who all had been selected from the private Cardiac clinics or visited Al-Naiaf's cardiology department.

Blood pressure behavior	Before stenting (n=75)	After stenting (n=75)	P value <
Invasive systolic blood pressure (mmHg) proximal to coarctation area	159.80± (20.5)	120.87± (31)	0.0001
Invasive systolic blood pressure (mmHg) distal to coarctation area	97 ± (14.6)	121.5 ± (24.7)	0.0001
Average difference in invasive systolic blood pressure proximal and distal to coarctation area (pressure gradient)	38 ± (12)	2 ± (3)	0.0001

Table 3. Comparison in invasive systolic blood pressure measurement by catheterization before and immediately after stenting in patients who underwent intervention for CoA. Note-P- value; probability value.

No. of patients	Immediately Post-intervention	6 months follow up	1 year follow up
On follow up			
Blood Pressure Measurement (mmHg)			
Normotensive	74 (98.7%)	61 (88.4%)	45 (84.9%)
Hypertensive	1 (1.3%)	8 (11.6%)	8 (15.1%)
Total	75 (100%)	69 (92%)	53 (70%)

Table 4. Comparison between blood pressure readings immediately, 6 months, and 1 year in patients who underwent intervention for CoA

After 6-month follow-up, we discovered that 88.4 percent of people have improved blood pressure control (no need for antihypertensive medication with a normal blood pressure reading on measurement by sphygmomanometer on both arms). At the 1-year checkup visit, 84.9% had control blood pressure (no need for antihypertensive medication and normal blood pressure reading on both arms when measured by sphygmomanometer), as shown in Table 3. 69 patients (92% of those who had a stent inserted) returned for a 6-month follow-up evaluation, and 53 patients (70% of those who had a stent implanted) returned for a 1-year follow-up

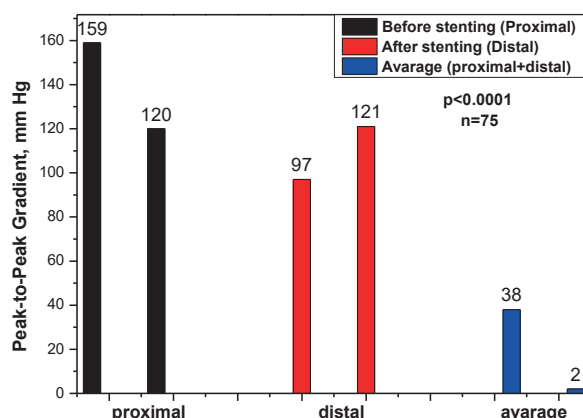


Figure 1. Bar graph illustrating residual gradients at follow-up before and after stenting. Note significant (p<0.0001) decrease in pressure gradient in each condition. N indicated the number of patients in each condition.

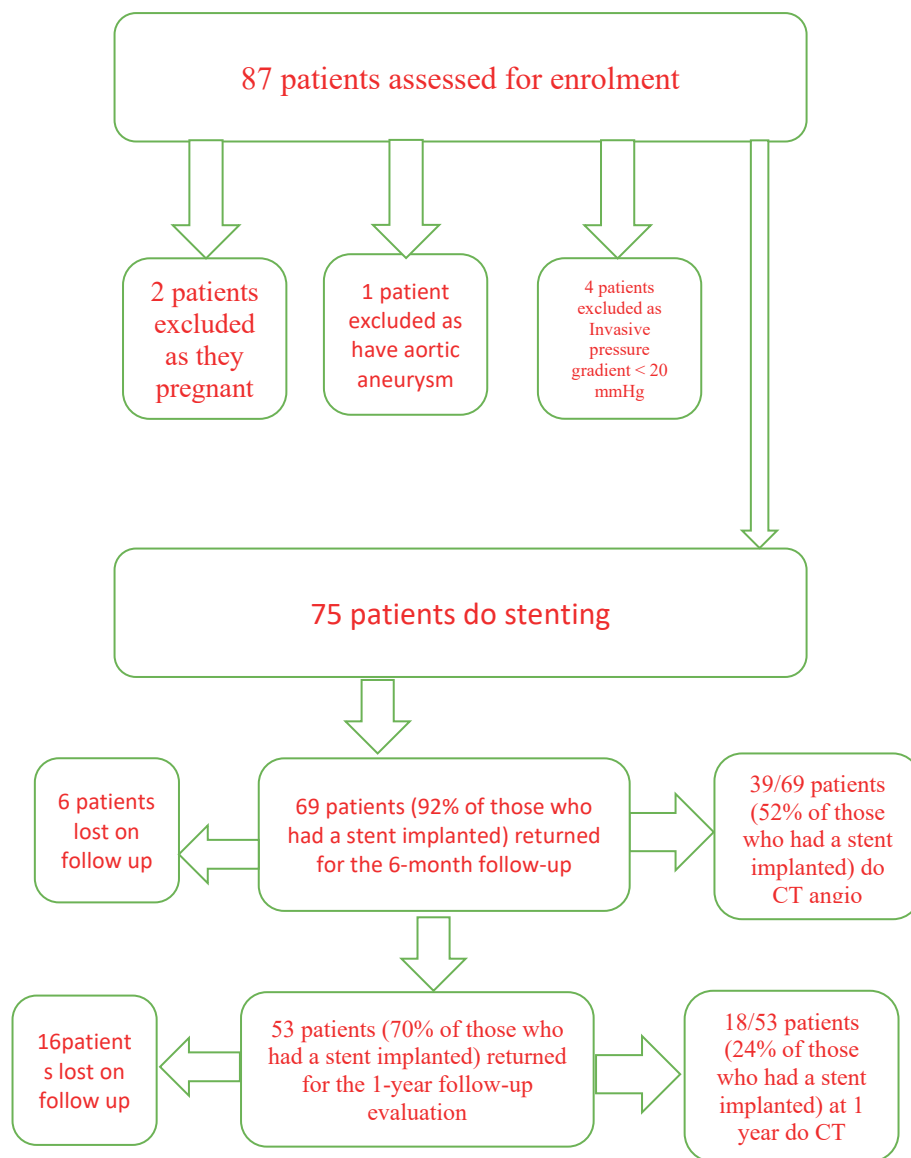


Figure 1. Flow diagram in patient's underwent intervention for CoA

evaluation. Patients returned for follow-up CT angiography at 6 months and 1 year in 39/69 cases. (52% of those who had a stent implanted) at 6 months and 18/45 patients (24 percent of those who had a stent implanted) at one year demonstrate no aortic wall injury or aneurysm formation, and there is no mortality at one-year follow-up, as shown in (supporting S1). Table 3 shows the comparison in invasive systolic blood pressure measurement by catheterization before and immediately after stenting in patients who underwent intervention for CoA. Table 4 includes comparison between blood pressure readings immediately, 6 months, and 1 year in patients who underwent intervention for CoA. Figure 1 shows pressure gradients before and after stenting. The mean value of peak-to-peak systolic pressure gradient between ascending to descending aorta significantly decreased from 159.80 to 120 mm Hg for invasive systolic blood pressure (mm Hg) proximal to coarctation area, for distal stage values increase from 97 to 121 (mm Hg) and for average difference in invasive systolic blood

pressure proximal and distal values are drastically decreased from 38 to 2 (mm Hg) ($p < 0.0001$) at the end of procedure.

Note- probability value (P-value) obtain at < 0.0001 in all cases

Algorithm 1 of patients flow diagram in patient's underwent intervention for CoA

Learning points

Our research has shown that the surgical method of using uncovered stents in the correction of CoA has proven better modality in reducing hypertension by many folds than that of non-surgical treatment like changes in certain lifestyle and selective medications.

One finding of this study is that most patients' blood pressure improves immediately after stenting of CoA.

5. CONCLUSION

Uncovered stent appears to be safe in treating coarctation of aorta with less morbidity and mortality. Stent adult with coarctation of aorta have advantage of low-

ering blood pressure in those suffer from hypertension. We recommend to use uncovered stent in treating indicated coarctation of aorta as primary modality of management as it regard as 1 year flow up show it safe with less mortality and morbidity .

- **Patient Conset Form:** An informed written consent was taken from the family caregivers, following the tenets of the Declaration of Helsinki.
- **Author's contribution:** Both authors were involved in the preparation this article. Final proofreading was made by the first author.
- **Conflicts of interest:** The authors declare that they have no conflicts of interest regarding the publication.
- **Financial support and sponsorship:** Nil.

REFERENCES

1. Forbes TJ, Kim DW, Du W, Turner DR, Holzer R, Amin Z, et al. Comparison of surgical, stent, and balloon angioplasty treatment of native coarctation of the aorta: an observational study by the CCISC (Congenital Cardiovascular Interventional Study Consortium). *J Am Coll Cardiol*. 2011; 58(25): 2664-2674. doi: 10.1016/j.jacc.2011.08.053
2. Butera G, Manica JL, Marini D, Piazza L, Chessa M, Filho RI, et al. From bare to covered: 15-year single-center experience and follow-up in trans-catheter stent implantation for aortic coarctation. *Catheter Cardiovasc Interv*. 2014; 83(6): 953-963. doi: 10.1002/ccd.25404.
3. Qureshi AM, McElhinney DB, Lock JE, Landzberg MJ, Lang P, Marshall AC. Acute and intermediate outcomes, and evaluation of injury to the aortic wall, as based on 15 years experience of implanting stents to treat aortic coarctation. *Cardiol Young*. 2007; 17(3): 307–318. doi: 10.1017/S1047951107000339.
4. Chessa M, Carrozza M, Butera G, Piazza L, Negura DG, Busadori C, Bossone E, et al. Results and mid-long-term 5 followup of stent implantation for native and recurrent coarctation of the aorta. *Eur Heart J*. 2005; 26(24): 2728–2732. doi: 10.1093/eurheartj/ehi491.
5. Presbitero P, Demarie D, Villani M, Perinotto EA, Riva G, Orzan F, et al. Long term results (15-30 years) of surgical repair of aortic coarctation. *Br Heart J*. 1987 May; 57(5): 462-467. doi: 10.1136/hrt.57.5.462
6. Hager A, Kanz S, Kaemmerer H, Schreiber C, Hess J. Coarctation LongTerm Assessment (COALA): significance of arterial hypertension in a cohort of 404 patients up to 27 years after surgical repair of isolated coarctation of the aorta, even in the absence of restenosis and prosthetic material. *J Thorac Cardiovasc Surg*. 2007; 134(3): 738-745. doi: 10.1016/j.jtcvs.2007.04.027.
7. National High Blood Pressure Education Program Working Group on High Blood Pressure in Children and Adolescents. The fourth report on the diagnosis, evaluation, and treatment of high blood pressure in children and adolescents. *Pediatrics*. 2004; 114(2): 555-576.
8. Thanopoulos BD, Giannakoulas G, Giannopoulos A, Galdo F, Tsaoussis GS. Initial and six-year results of stent implantation for aortic coarctation in children. *Am J Cardiol*. 2012; 109(10): 1499-1503. doi: 10.1016/j.amjcard.2012.01.365.
9. Butera G, Gaio G, Carminati M. Redilation of e-PTFE covered CP stents. *Catheter Cardiovasc Interv*. 2008; 72(2): 273-277. doi: 10.1002/ccd.21609.