



# Necrotizing Otitis Externa: A Proposal for Diagnostic and Therapeutic Approach

Marília Batista Costa<sup>1</sup> Ektor Tsuneo Onishi<sup>1</sup>

<sup>1</sup>Department of Otorhinolaryngology - Head and Neck Surgery, Universidade Federal de São Paulo, Escola Paulista de Medicina, Sao Paulo, SP, Brazil

Address for correspondence Marília Batista Costa, MD, Department of Otorhinolaryngology - Head and Neck Surgery, Escola Paulista de Medicina, Universidade Federal de São Paulo, 821 Botucatu St, Sao Paulo, SP 04039-001, Brazil (e-mail: marilia.batista.c@gmail.com).

Int Arch Otorhinolaryngol 2023;27(4):e706–e712.

## Abstract

**Introduction** Necrotizing otitis externa has a high impact on the quality of life of patients and has shown a significant increase in its incidence in recent years. There has been a change in the profile of affected patients and a lack of consensus on the management of these patients.

**Objective** To develop a practical and effective care protocol to standardize the diagnostic and therapeutic management of necrotizing otitis externa.

**Methods** A retrospective cohort study of necrotizing otitis externa patients between January 2015 and December 2020.

**Results** There were 34 patients with two bilateral cases, totaling 36 ears. The mean age was 68.5, with a higher prevalence of males (76%). Diabetes was present in 97% of the samples. The involvement of cranial pairs was identified in 35% of the sample. *Pseudomonas aeruginosa* was the most frequent pathogen isolated, found in 50% of the cases. Among the cultures with bacterial agents isolated, 35% showed resistance to ciprofloxacin. The most frequent exam was computed tomography (94%). Hospital admission was indicated for 31 patients (91%), and ceftazidime was the most prescribed drug (35.5%). There were 11 recurrences (32%), and 12 patients (35%) had complications during treatment. Among the unfavorable outcomes, 12% persisted with some degree of peripheral facial paralysis, 6% maintained dysphagia, and 9% died of the disease.

**Conclusions** The present study developed a diagnostic and therapeutic protocol for the effective management of necrotizing otitis externa. This protocol is a dynamic tool and should be revised and updated as new demands emerge during its implementation.

## Keywords

- ▶ external otitis
- ▶ skull base
- ▶ osteomyelitis
- ▶ diabetes mellitus
- ▶ otolaryngology

## Introduction

Necrotizing otitis externa (NOE) is an invasive infection of the external acoustic meatus (EAM) that spreads to adjacent soft tissues, temporal bone, and skull base.<sup>1</sup> Although rare, epidemiological data shows a sharp increase in cases.<sup>2,3</sup>

The etiologic agent classically described is *Pseudomonas aeruginosa*.<sup>4</sup> However, in recent years, there has been an increase in cases caused by other pathogens, both bacterial and fungal.<sup>5</sup>

Necrotizing otitis externa generally occurs in elderly patients with diabetes, immunosuppression, or other risk

received  
August 9, 2022  
accepted  
September 4, 2022  
article published online  
September 26, 2023

DOI <https://doi.org/10.1055/s-0042-1758719>.  
ISSN 1809-9777.

© 2023. Fundação Otorrinolaringologia. All rights reserved.  
This is an open access article published by Thieme under the terms of the Creative Commons Attribution-NonDerivative-NonCommercial-License, permitting copying and reproduction so long as the original work is given appropriate credit. Contents may not be used for commercial purposes, or adapted, remixed, transformed or built upon. (<https://creativecommons.org/licenses/by-nc-nd/4.0/>)  
Thieme Revinter Publicações Ltda., Rua do Matoso 170, Rio de Janeiro, RJ, CEP 20270-135, Brazil

factors.<sup>6</sup> Clinically, it is similar to acute external otitis (AEO) and does not present pathognomonic features on physical examination, often leading to a delayed diagnosis.<sup>7</sup>

The culture of EAM secretion helps to evaluate antibiotic therapy through an antibiogram analysis, which becomes essential as studies show the increase of *Pseudomonas aeruginosa* strains resistant to ciprofloxacin.<sup>8</sup> Granulation tissue biopsy is crucial for the differential diagnosis with neoplastic processes in EAM, of which clinical and physical examination are similar to NOE.<sup>9</sup>

Computed tomography (CT), magnetic resonance imaging (MRI), and scintigraphy can be ordered for diagnosis and clinical follow-up, each method with its advantages and disadvantages. There is no standardization for the request of these exams, the method of choice being up to the professional.<sup>10</sup>

Treatment consists of constant EAM cleaning, control of comorbidities, and prolonged use of antibiotics. However, there is no systematization of the therapeutic management of these patients. Even with treatment optimization, NOE presents high morbidity and mortality rates for an infectious disease.<sup>11</sup>

Given the changes in the profile of patients affected by NOE and the heterogeneity of the disease, the present study aims to develop a practical and effective care protocol based on clinical, laboratory, and radiological criteria, to standardize diagnostic and therapeutic management of NOE.

## Materials and Methods

A retrospective cohort study of NOE patients was performed between January 2015 and December 2020. The exclusion criteria were clinical improvement after topical treatment < 3 weeks; records with limited data; discontinuation of patient follow-up within the first 30 days; and biopsy results with a final diagnosis of squamous cell carcinoma. The institution approved the present study through its Research Ethics Committee, opinion number 4.161.813.

### Statistical Analysis

The categorical variables were described by absolute and relative frequencies and compared using the chi-squared test or the Fisher exact test, according to the applicability. The continuous variables were assessed considering the normality asymmetry values (skewness) and kurtosis and were expressed as medians and quartiles and compared through the Mann-Whitney test.

All tests were two-tailed and final values of  $p < 0.05$  were considered significant. Statistical analyses were performed using IBM SPSS Statistics for Windows, version 24.0 (IBM Corp. Armonk, NY, USA).

## Results

In the final analysis, 34 patients were included, with 2 bilateral cases totaling 36 affected ears. The mean age was 68.5 years old, with a higher prevalence of males (76%). Diabetes was the most prevalent comorbidity (97%).

The most prevalent symptom was otalgia (100%). As for the physical examination, the most frequent finding was otorrhea (97%). The involvement of cranial pairs was identified in 35% of the sample. A total of 10 (29%) had peripheral facial palsy (PFP), and 5 (15%) showed alterations of other cranial pairs (IX-XII). One finding in all of them was vocal fold paralysis. All findings are detailed in ►Table 1.

The mean value of total leukocytes was 10,631/ $\mu$ L (range: 4,660–26,870), with leukocytosis present in 11 patients (32%). Eight of them had mild leukocytosis ( $\leq 15,000/\mu$ L), 1 moderate (15,000–20,000/ $\mu$ L), and 2 severe ( $>20,000/\mu$ L).

The mean blood glucose of the sample was 220mg/dL (range: 83–494mg/dL) and the mean glycosylated hemoglobin was 9.0% (range: 5.8–16%). As for the inflammation tests, 97% had altered C-reactive protein (CRP) and/or erythrocyte sedimentation rate (ESR), and 76% had both values above normal. The mean CRP value was 40.6mg/L (range: 3.9–175.3), and the ESR was 58.7mm (range: 5.0–123).

*Pseudomonas aeruginosa* was the most frequent pathogen, present in 50% of the samples and isolated in 33%. Out of the 26 cultures with bacterial agents isolated, 17 (65%) showed sensitivity toward ciprofloxacin. The etiological agents isolated are described in ►Table 2.

Admission CT scan was performed in 32 patients (94%). External acoustic meatus soft tissue thickening was present in 91% of the sample. Erosion of the bony part of the EAM, present in 59%, occurred mainly in the anteroinferior wall and on its most medial portion. The changes found in the masticatory space were fat densification and muscle thickening, with the lateral pterygoid muscle being the most compromised.

Magnetic resonance imaging was performed in 14 patients (41%). The most prevalent finding was soft tissue involvement in the retrocondylar and subtemporal regions, each with a 79% prevalence. Involvement of the masticatory space happened in 57% of the sample. Scintigraphy was performed in only 10 patients (29%).

All patients received topical and/or oral antibiotic therapy for an average of 27 days before being admitted to the institution. Hospital admission was indicated for 31 patients (91%). Three patients who underwent outpatient follow-up took ciprofloxacin 750 mg twice daily orally for a mean duration of 98 days (range: 60–150; median 85).

The main pharmacological options initially prescribed to inpatients are shown in ►Table 3. Two patients (6%) underwent tympanomastoidectomy in the early phase of treatment for local debridement and collection of material for biopsy. The average length of hospitalization was 60 days.

Eight patients (23%) had recurrence of NOE. Three of them twice, totaling 11 clinical relapses (32%). The recurrence in all 8 patients occurred an average of 100 days after the termination of the initial therapy regimen. Among the unfavorable outcomes, 12% persisted with some degree of PFP, 6% maintained dysphagia, and 9% died of the disease.

Complications during hospital stay occurred in 12 patients (35%). Acute renal failure was the most common, with hemodialysis required in 6 cases (18%). The average follow-up time was 16 months (range: 1–60).

**Table 1** Sample characterization

Variable	n = 34
Age (years old)	69.5 (61.0–76.7)
Male	26 (76%)
<b>Comorbidities</b>	
Diabetes	33 (97%)
Systemic arterial hypertension	26 (76%)
Dyslipidemia	17 (50%)
Chronic renal failure	11 (32%)
Coronary heart disease	6 (18%)
Hypothyroidism	6 (18%)
History of stroke	6 (18%)
History of acute myocardial infarction	3 (9%)
Neoplasia	3 (9%)
Transplantation history	3 (9%)
Peripheral arterial obstructive disease	2 (6%)
Arrhythmia	2 (6%)
<b>Clinical presentation</b>	
<u>Affected side</u>	
Left	18 (53%)
Right	14 (41%)
Bilateral	2 (6%)
<u>Clinical Complaints</u>	
Otalgia	34 (100%)
Hypoacusis	12 (35%)
Cephalgia	10 (29%)
Aural fullness	9 (26%)
Dysphagia	7 (21%)
Dysphonia	6 (18%)
<u>Physical examination</u>	
Otorrhea	33 (97%)
Edema	30 (88%)
Granulation tissue	24 (70%)
Hyperemia	19 (56%)
Nerve involvement (VII-XII)	12 (35%)
Preauricular involvement	9 (26%)
Trismus	2 (6%)
Lymphadenomegaly	1 (3%)
Perichondritis	1 (3%)
Parotid gland involvement	1 (3%)
<b>Risk Factors</b>	
Absent	25 (73%)
PSAP	3 (9%)
Trauma	3 (9%)
Iatrogenic or aquatic activity	3 (9%)

Abbreviation: PSAP, personal sound amplification product.

Data presented as median (p25-p75) or n(%).

Notes: VII = facial nerve; IX = glossopharyngeal nerve; X = vagus nerve; XII = hypoglossal nerve;

**Table 2** Culture results

Variable	n = 30
<b>Pathogens</b>	
<i>Pseudomonas aeruginosa</i>	15(50%)
<i>Staphylococcus aureus</i>	5(17%)
<i>Candida spp</i>	5(17%)
<i>Coagulase negative Staphylococcus</i>	3(10%)
<i>Proteus mirabilis</i>	2(7%)
<i>Aspergillus fumigatus</i>	1(3%)
<i>Klebsiella pneumoniae</i>	1(3%)
Culture-negative	4(13%)

Data presented as n (%).

**Table 3** Pharmacological options in hospitalized patients

Variable	n = 31
<b>Antibiotic</b>	
Ceftazidime	11(35.5%)
Piperacillin/Tazobactam	4(13%)
Ceftazidime + Ciprofloxacin IV	4(13%)
Cefepime	4(13%)
Meropenem	3(10%)
Ciprofloxacin IV	2(6.5%)
Piperacillin/Tazobactam + Fluconazole	1(3%)
Cefepime + Clindamycin	1(3%)
Meropenem + Vancomycin	1(3%)

Abbreviation: IV, intravenous.

Data presented as n (%).

Note: IV = intravenous.

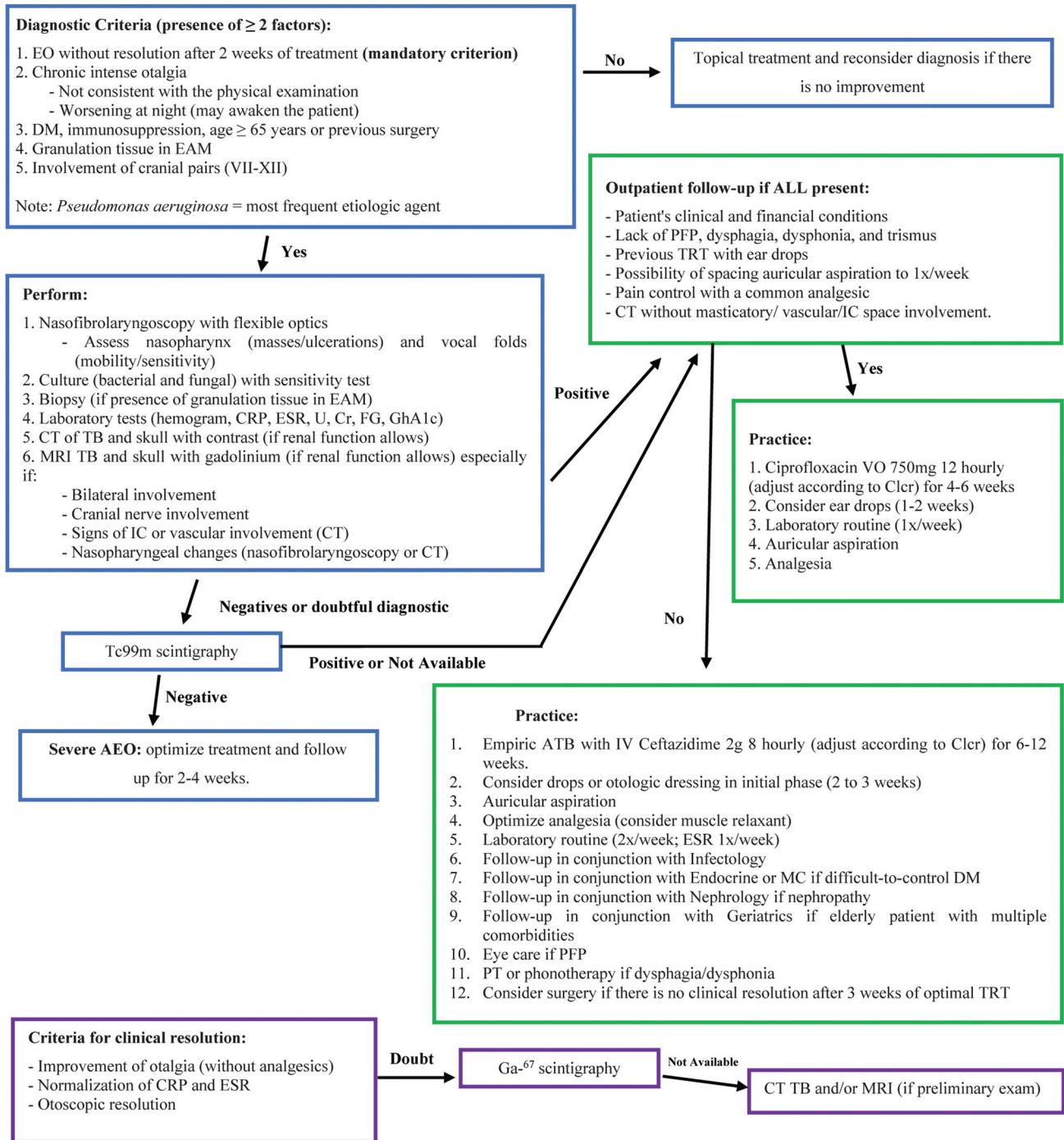
## Discussion

The diagnosis of NOE is commonly based on the combination of three parameters: clinical, laboratory, and imaging tests.<sup>12</sup> Among the clinical criteria, a lack of response to conventional therapy is considered a key indicator for the diagnosis. That is because AEO is the principal differential diagnosis for NOE and usually shows satisfactory clinical resolution after 1 to 3 weeks of conservative treatment.<sup>13</sup>

In the present study, for a more reliable statistical analysis, only patients who had not achieved clinical improvement after 3 weeks of treatment were included. However, to increase the diagnostic sensitivity of the developed protocol (► Fig. 1), the 2-week criterion was chosen. This criterion was established as mandatory since the lack of clinical response is a key to differentiating between AEO and NOE.

Despite being an unspecific complaint, otalgia was also included in the protocol due to its high prevalence and for presenting unique characteristics such as its intensity, which is usually not consistent with the physical examination, as well as the tendency to worsen at night, waking up the patient.<sup>14,15</sup>

**Protocol for clinical and therapeutic management of patients with NOE**



**Fig. 1** Proposed new NOE treatment algorithm.

In our study, all patients had comorbidities related to immunosuppression, diabetes being the most prevalent (97%), corroborating the classical description of the disease.<sup>6</sup> Nonetheless, there are reports of NOE in elderly patients without any other factor of immune system depression.<sup>16</sup> Thus, to make the diagnosis more sensitive, in addition to diabetes and immunosuppression, the age of  $\geq 65$  years old was added to the protocol as a risk factor capable of provoking the disease. That is because elderly patients have a low capacity to promote an effective immune response, resulting

in dysregulation in cytokine production, defective hematopoiesis, and chronic thymus involution.<sup>16</sup>

Although the studied patients did not report any previous otologic surgery, some authors describe its association as a predisposing factor for NOE.<sup>17</sup> Thus, we chose to include it as a risk factor in the diagnostic criteria of the algorithm developed in the present study.

Granulation tissue in EAM was also established in the protocol as one of the criteria to assist the diagnosis of NOE. However, a suspected diagnosis should not depend on its



presence in the findings since it is not unanimous nor pathognomonic of NOE and may occur in simple AEO, and in cases of squamous cell carcinoma.<sup>15,18</sup>

The involvement of cranial pairs (VII-XII) was incorporated into the protocol because it is considered a “red flag” when suspecting NOE. On the other hand, PFP, dysphagia, and/or dysphonia are usually late findings and are not exclusive to this disease.<sup>14</sup>

In the culture exams, *Pseudomonas aeruginosa* was the most frequent causal agent, which is consistent with the literature.<sup>6</sup> However, there is a tendency to increase the prevalence of other pathogens in the etiology of NOE.<sup>17</sup> Therefore, although the isolation of *Pseudomonas aeruginosa* corroborates the diagnosis of NOE, its presence should not be considered mandatory, so it wasn't included in the criteria.

The association between NOE and cranial nerve involvement is well-established in the literature.<sup>19</sup> In the present study, vocal fold paralysis was present in 15% of the sample. Therefore, in addition to the research on cranial pairs, we suggest nasofibrolaryngoscopy as part of the routine evaluation of these patients.

Regarding laboratory tests, only 32% of patients had leukocytosis, mostly mild (up to 15,000/ $\mu$ L), as confirmed by the literature.<sup>20,21</sup> Consequently, we chose not to use this parameter as a diagnostic criterion, but it should be requested regularly in the follow-up of these patients.

The intrinsic relationship between NOE and diabetes was evident in the study. Although some studies suggest that patients with good glycemic control do not progress to more severe forms of NOE, this relationship was not compelling.<sup>17</sup> However, glycemic control is crucial to prevent complications and better clinical management. Thus, serial measurements of blood glucose and glycosylated hemoglobin are recommended.<sup>14,22</sup>

In the study, 32% of the patients had chronic renal failure, and 18% developed acute renal failure during treatment, often related to the use of nephrotoxic medications. Thus, serial laboratory evaluation of renal function is recommended throughout the treatment, even if the patient reports no previous renal comorbidities.

The inflammatory tests ESR and CRP are important parameters used in the diagnosis and follow-up of NOE cases.<sup>4</sup> In the study, 97% of patients had at least one of these values altered, and 76% had both above normality, justifying the recommendation of joint assessment of both tests. However, 3% of the sample had normal CRP and ESR values, demonstrating the importance of using more than one parameter in the management of these patients.

The culture of EAM secretion should be performed in all patients to guide the choice of antibiotics. This measure becomes more relevant with the increasing reports of bacterial resistance in NOE.<sup>23</sup> In our study, 35% of cultures with bacterial agents isolated showed resistance to ciprofloxacin.

Biopsy was performed in only 59% of the sample, despite the presence of granulation tissue in 70% of the cases. The histopathological analysis is extremely important for the differential diagnosis since the neoplastic pictures strongly resemble NOE and is recommended in all patients.<sup>15</sup>

Computed tomography was performed in 94% of the cases, demonstrating its high availability. Therefore, CT was suggested for all patients with suspected NOE. Computed tomography provides data that can corroborate the diagnosis; moreover, it assists in investigation of the disease extent and ruling out possible differential diagnoses.<sup>18</sup>

Magnetic resonance imaging should always be requested for greater detail of soft tissue and intracranial alterations.<sup>18</sup> Given the limitations of the institution, it should be prioritized in case of bilateral involvement, involvement of cranial pairs (VII-XII), nasopharyngeal lesions, or intracranial/vascular alterations on imaging exams. In the study by Kwon et al.<sup>7</sup>, the most prevalent finding on initial MRI, 93% of the sample, was retrocondylar fat infiltration. Our study obtained a similar finding, with a prevalence of retrocondylar soft tissue involvement of 79%. It suggests an early involvement of this region and demonstrates the importance of its evaluation in suspected cases of NOE.

Studies show that professionals tend not to request nuclear medicine exams, given their low availability, due to the conditions of the institution.<sup>10</sup> These exams have been requested in only 29% of the sample. For the effectiveness of the protocol, Tc99m scintigraphy was suggested only in cases of high clinical suspicion and normal CT. If scintigraphy is not available, an empirical NOE treatment should be initiated until the culture result is ready.

The protocol established the possibility of treatment at the outpatient level if all the following are present: clinical and financial conditions of the patient; lack of PFP, dysphagia, dysphonia, and trismus; previous treatment restricted to eardrops; the possibility of spacing the auricular aspiration weekly; pain control with a common analgesic and CT without masticatory, vascular, or intracranial space involvement.

The recommendation in these cases is oral ciprofloxacin 750mg every 12 hours until the culture results are available. This dose may change depending on the creatinine clearance of the patient. Auricular aspiration is an essential part of the treatment, so the use of ear drops may be considered, especially in the first 2 weeks.<sup>15</sup> Regarding laboratory tests, they should be performed weekly to facilitate the management of these cases.

Treatment should last at least 4 to 6 weeks. However, in the case of new symptoms or no clinical outcome in 2 to 3 weeks, hospitalization should be considered.

When hospitalization is required, to optimize treatment and reduce possible complications, we decided on the use of intravenous ceftazidime as the drug of choice until an antibiogram is available.

We recommended a minimum of 6 weeks of intravenous antibiotic treatment. To reduce recurrences after hospital discharge, we suggest switching from intravenous to oral medication during hospitalization for 1 week to evaluate the therapeutic response of the patient. As long as normalized inflammatory tests, normal otoscopy, and a lack of otalgia are maintained, patients are discharged with subsequent outpatient follow-up.

All patients should undergo auricular cleaning and be assessed daily for analgesia. Muscle relaxants may be considered given their good analgesic response in cases of NOE.<sup>24</sup> Drops or otologic dressing may be used initially, especially for the first 2 to 3 weeks or until normalization of otoscopy.<sup>25</sup> Based on the guideline prepared by Nash et al.,<sup>26</sup> we established that laboratory tests are to be performed in hospitalized patients twice a week and ESR weekly.

Indication of surgery as adjunctive therapy is possible in the face of poor clinical response after 3 weeks of optimal antibiotic therapy, especially in cases of sterile cultures. Due to the suspicion of a fungal agent involvement in these cases, surgery, besides promoting local debridement, allows the collection of tissue for culture and histopathological analysis.<sup>27</sup> The decision of which surgical technique to use should be individualized according to the case and the preference of the surgeon.

Hyperbaric oxygen was not included in the protocol due to restricted access by the Brazilian Unified Health System (SUS, in the Portuguese acronym) as well as the lack of evidence of its benefits in NOE.<sup>28</sup>

The resolution criteria established in the protocol were: improvement of otalgia without analgesics, normalization of the otoscopic appearance, and resolution of inflammatory tests (ESR and CRP).

Cançado et al.<sup>29</sup> suggest, in addition to normalization of ESR, performing gallium scintigraphy after 6 weeks of treatment to assess disease control. If the test result is negative, the treatment is suspended. However, due to the limited access to nuclear medicine exams, we opted to indicate it only in doubtful cases. If scintigraphy is not available, CT and/or MRI are performed for comparison with the same tests performed at admission.

Death within 60 to 90 days is considered disease-related mortality.<sup>20,27</sup> In the present study, its prevalence was 9%. In the literature, this prevalence ranges from 2.5 to 42%.<sup>30,31</sup>

The follow-up time is not registered. Some studies suggest a follow-up of 6 to 12 months.<sup>21,31</sup> However, considering that in our study relapses occurred 3 years after the initial presentation, we suggest the follow-up should be longer.

The retrospective nature and small sample size identified here are common limitations, also found in corresponding studies, and are justified by the low prevalence of the disease and the need for extended follow-up.

## Conclusion

Necrotizing otitis externa is a serious infection with high morbidity and mortality rates and has shown a sharp increase in prevalence. It is related to delays in its diagnosis and difficulties in treatment choice. Therefore, the present study developed a protocol to guide diagnostic and therapeutic management of this population, aiming at consistent conduct considering the limitations of the institution without losing its effectiveness. It is worth mentioning that the protocol is a dynamic tool and may change depending on

each case and should be revised and updated as new needs arise during its application.

## Funding

The present research did not receive any specific grant from funding agencies in the public, commercial, or not-for-profit sectors.

## Conflict of Interests

The authors have no conflict of interests to declare.

## References

- 1 Karaman E, Yilmaz M, Ibrahimov M, Hacıyev Y, Enver O. Malignant otitis externa. *J Craniofac Surg* 2012;23(06):1748–1751
- 2 Hutson KH, Watson GJ. Malignant otitis externa, an increasing burden in the twenty-first century: review of cases in a UK teaching hospital, with a proposed algorithm for diagnosis and management. *J Laryngol Otol* 2019;133(05):356–362
- 3 Eweiss AZ, Al-Aaraj M, Sethukumar P, Jama G. Necrotising otitis externa: a serious condition becoming more frequently encountered. *J Laryngol Otol* 2021;25:1–5
- 4 Sharma S, Corrah T, Singh A. Management of Necrotizing Otitis Externa: Our Experience with Forty-Three Patients. *J Int Adv Otol* 2017;13(03):394–398
- 5 Ijaz A, Williams E, Cole J, Watson G. Necrotising otitis externa antibiotic therapy complications: A retrospective cohort analysis. *Clin Otolaryngol* 2022;47(03):491–494
- 6 Peled C, El-Seid S, Bahat-Dinur A, Tzvi-Ran LR, Kraus M, Kaplan D. Necrotizing Otitis Externa-Analysis of 83 Cases: Clinical Findings and Course of Disease. *Otol Neurotol* 2019;40(01):56–62
- 7 Kwon BJ, Han MH, Oh SH, Song JJ, Chang KH. MRI findings and spreading patterns of necrotizing external otitis: is a poor outcome predictable? *Clin Radiol* 2006;61(06):495–504
- 8 Berenholz L, Katzenell U, Harell M. Evolving resistant pseudomonas to ciprofloxacin in malignant otitis externa. *Laryngoscope* 2002;112(09):1619–1622
- 9 Bhat V, Aziz A, Bhandary SK, Aroor R, Kamath P SD, Saldanha M. Malignant Otitis Externa - A Retrospective Study of 15 Patients Treated in a Tertiary Healthcare Center. *J Int Adv Otol* 2015;11(01):72–76
- 10 Cooper T, Hildrew D, McAfee JS, McCall AA, Branstetter BF IV, Hirsch BE. Imaging in the Diagnosis and Management of Necrotizing Otitis Externa: A Survey of Practice Patterns. *Otol Neurotol* 2018;39(05):597–601
- 11 Guevara N, Mahdyoun P, Pulcini C, Raffaelli C, Gahide I, Castillo L. Initial management of necrotizing external otitis: errors to avoid. *Eur Ann Otorhinolaryngol Head Neck Dis* 2013;130(03):115–121
- 12 Lim JWJ, Hill FCE, Kerr S, Briggs R, McLean T. Diagnostic approach to patients at risk of otogenic skull base osteomyelitis. *Acta Otolaryngol* 2022;142(3–4):272–279
- 13 Djerić D, Folić M, Janićijević M, Blažić S, Popadić D. Recurrent malignant otitis externa with multiple cranial nerve involvement: A case report. *Srp Arh Celok Lek* 2016;144(5–6):315–319
- 14 Stern Shavit S, Soudry E, Hamzany Y, Nageris B. Malignant external otitis: Factors predicting patient outcomes. *Am J Otolaryngol* 2016;37(05):425–430
- 15 Morales RE, Eisenman DJ, Raghavan P. Imaging Necrotizing Otitis Externa. *Semin Roentgenol* 2019;54(03):215–226
- 16 Unadkat S, Kanzara T, Watters G. Necrotising otitis externa in the immunocompetent patient: case series. *J Laryngol Otol* 2018;132(01):71–74
- 17 Hopkins ME, Bennett A, Henderson N, MacSween KF, Baring D, Sutherland R. A retrospective review and multi-specialty, evidence-based guideline for the management of necrotising otitis externa. *J Laryngol Otol* 2020;134(06):487–492

- 18 van Kroonenburgh AMJL, van der Meer WL, Bothof RJP, van Tilburg M, van Tongeren J, Postma AA. Advanced Imaging Techniques in Skull Base Osteomyelitis Due to Malignant Otitis Externa. *Curr Radiol Rep* 2018;6(01):3
- 19 Arsovic N, Radivojevic N, Jescic S, Babac S, Cvorovic L, Dudvarski Z. Malignant Otitis Externa: Causes for Various Treatment Responses. *J Int Adv Otol* 2020;16(01):98–103
- 20 Yehekeli E, Eta RA, Gavriel H, Kleid S, Eviatar E. Temporomandibular joint involvement as a positive clinical prognostic factor in necrotising external otitis. *J Laryngol Otol* 2016;130(05):435–439
- 21 Lau K, Scotta G, Wu K, Kabuli MAK, Watson G. A review of thirty-nine patients diagnosed with necrotising otitis externa over three years: Is CT imaging for diagnosis sufficient? *Clin Otolaryngol* 2020;45(03):414–418
- 22 Sylvester MJ, Sanghvi S, Patel VM, Eloy JA, Ying YM. Malignant otitis externa hospitalizations: Analysis of patient characteristics. *Laryngoscope* 2017;127(10):2328–2336
- 23 Glikson E, Sagiv D, Wolf M, Shapira Y. Necrotizing otitis externa: diagnosis, treatment, and outcome in a case series. *Diagn Microbiol Infect Dis* 2017;87(01):74–78
- 24 Honnurappa V, Ramdass S, Mahajan N, Vijayendra VK, Redleaf M. Effective Inexpensive Management of Necrotizing Otitis Externa Is Possible in Resource-Poor Settings. *Ann Otol Rhinol Laryngol* 2019;128(09):848–854
- 25 Marina S, Goutham MK, Rajeshwary A, Vadisha B, Devika T. A retrospective review of 14 cases of malignant otitis externa. *J Otol* 2019;14(02):63–66
- 26 Nash R, Logan S, Patel T, Khalil S, Saeed S. ENT UK guideline on necrotising otitis externa. [ENT UK Web site] May 31, 2020. Available at: Accessed March 18, 2022. [https://www.entuk.org/\\_userfiles/pages/files/guidelines/Necrotising%20otitis%20externa.pdf](https://www.entuk.org/_userfiles/pages/files/guidelines/Necrotising%20otitis%20externa.pdf)
- 27 Abu Eta R, Gavriel H, Stephen K, Eviatar E, Yehekeli E. The significance of tissue biopsy for fungi in necrotizing otitis externa. *Eur Arch Otorhinolaryngol* 2018;275(12):2941–2945
- 28 Phillips JS, Jones SE. Hyperbaric oxygen as an adjuvant treatment for malignant otitis externa. *Cochrane Database Syst Rev* 2013; (05):CD004617
- 29 Cançado SAV, Souza LD, Faleiro RM, Siqueiro JM. Necrotizing Otitis Externa: A Disease Barely Known to Neurosurgeons. *Braz Neurosurg* 2019;38(03):239–245
- 30 Hatch JL, Bauschard MJ, Nguyen SA, Lambert PR, Meyer TA, McRackan TR. Malignant Otitis Externa Outcomes: A Study of the University HealthSystem Consortium Database. *Ann Otol Rhinol Laryngol* 2018;127(08):514–520
- 31 Amaro CE, Espiney R, Radu L, Guerreiro F. Malignant (necrotizing) externa otitis: the experience of a single hyperbaric centre. *Eur Arch Otorhinolaryngol* 2019;276(07):1881–1887