



# Sulcus-Deepening Trochleoplasty and Medial Patellofemoral Ligament Reconstruction for Recurrent Patellar Instability

Michael S. Laidlaw, M.D., Scott M. Feeley, B.S., Jeffrey R. Ruland, B.A., and David R. Diduch, M.D.

**Abstract:** There are multiple etiologies for recurrent patellar instability. While patella alta, an elevated tibial tubercle trochlear groove distance, and prior lateral patellar dislocations with medial patellofemoral ligament (MPFL) insufficiency have been shown to be risk factors for recurrent patellar instability, trochlear dysplasia can result in a significant impediment to normal patellar tracking. With the adequate identification of risk factors, appropriate surgical treatments can be individually tailored to the patient. We present a combined surgical technique of a sulcus-deepening trochleoplasty using knotless suture anchors for fixation, with MPFL reconstruction using gracilis autograft through short, oblique patellar bone tunnels to address severe trochlear dysplasia.

Nearly 50% of patients reporting a history of patellar dislocation have recurrent instability.<sup>1</sup> A recent clinical study by Askenberger et al. suggests that trochlear dysplasia is the main anatomic risk factor associated with first-time patellar dislocations and that in combination with lateral patellar tilt, these 2 risk factors had the strongest association with lateral patellar dislocations in an adolescent population.<sup>2</sup> In fact, the combination of open physes and trochlear dysplasia resulted in a recurrent dislocation rate of 69% in another study.<sup>3</sup> Steensen et al. also reported that even in adults, the most common magnetic resonance imaging (MRI) radiographic finding in recurrent patellar instability is trochlear dysplasia.<sup>4</sup> Dejour type B and D trochlear dysplastic morphologies have been found to

be the most amenable to a sulcus-deepening procedure secondary to the large supratrochlear spur present.<sup>5</sup> Trochleoplasty procedures vary in the type and magnitude of correction obtainable, with the baseline principle of reducing the size of the supratrochlear spur, which many times results in a lateral “kick” of the patella, and providing a more favorable articulation by redefining the trochlear sulcus depth.<sup>6-8</sup> A Dejour sulcus-deepening trochleoplasty seeks to remove the supratrochlear spur so that the new trochlear smoothly transitions to the anterior femoral cortex.

A sulcus-deepening trochleoplasty has been successful at stabilizing the patella and providing less mal-tracking with more normalized kinematics during patellofemoral articulation.<sup>9</sup> In this surgical technique, we describe the use of a sulcus-deepening trochleoplasty using knotless suture anchor fixation, medial patellofemoral ligament (MPFL) reconstruction using autologous gracilis tendon through short, oblique patellar tunnels, and a lateral retinaculum Z lengthening to satisfactorily address recurrent patellar instability in the setting of a Dejour type B dysplastic trochlea (Video 1).

*From the Department of Orthopaedic Surgery (M.S.L., D.R.D.), University of Virginia; and University of Virginia School of Medicine (S.M.F., J.R.R.), Health Sciences Center, Charlottesville, Virginia, U.S.A.*

*The authors report the following potential conflicts of interest or sources of funding: D.R.D. receives support from Depuy Mitek. Full ICMJE author disclosure forms are available for this article online, as supplementary material.*

*Received June 20, 2017; accepted August 10, 2017.*

*Address correspondence to David R. Diduch, M.D., Department of Orthopaedic Surgery, University of Virginia, 400 Ray C. Hunt Drive, Suite 300, Charlottesville, VA 22903, U.S.A. E-mail: DRD5C@hscmail.mcc.virginia.edu*

*© 2017 by the Arthroscopy Association of North America. Published by Elsevier. This is an open access article under the CC BY-NC-ND license (<http://creativecommons.org/licenses/by-nc-nd/4.0/>).*

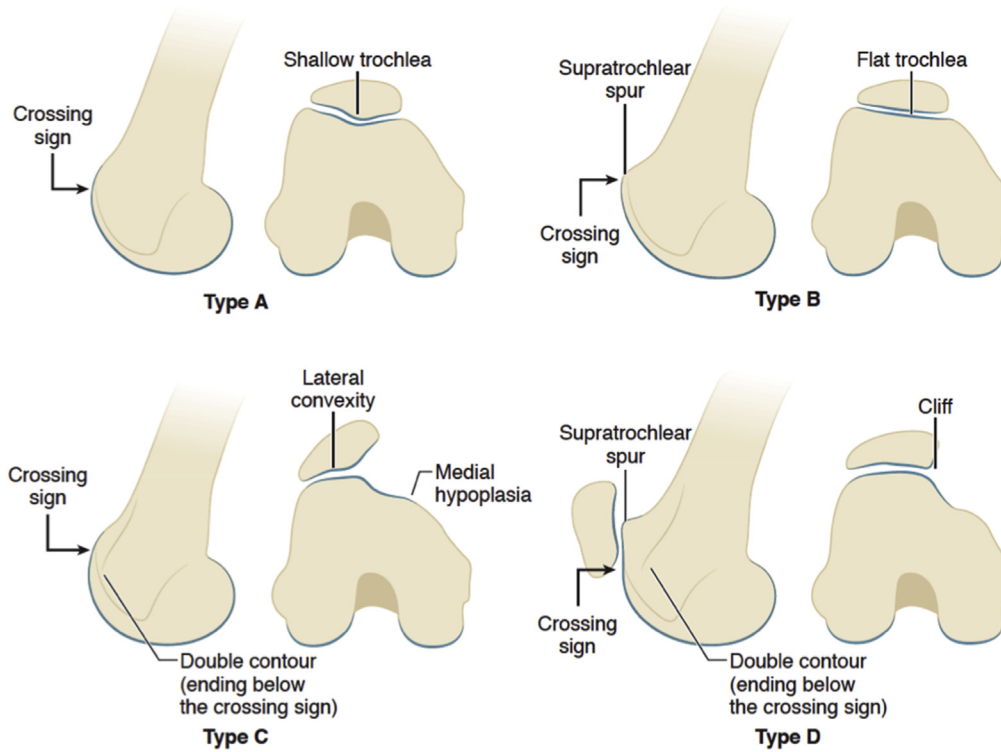
*2212-6287/17779*

*<https://doi.org/10.1016/j.eats.2017.08.061>*

## Surgical Technique

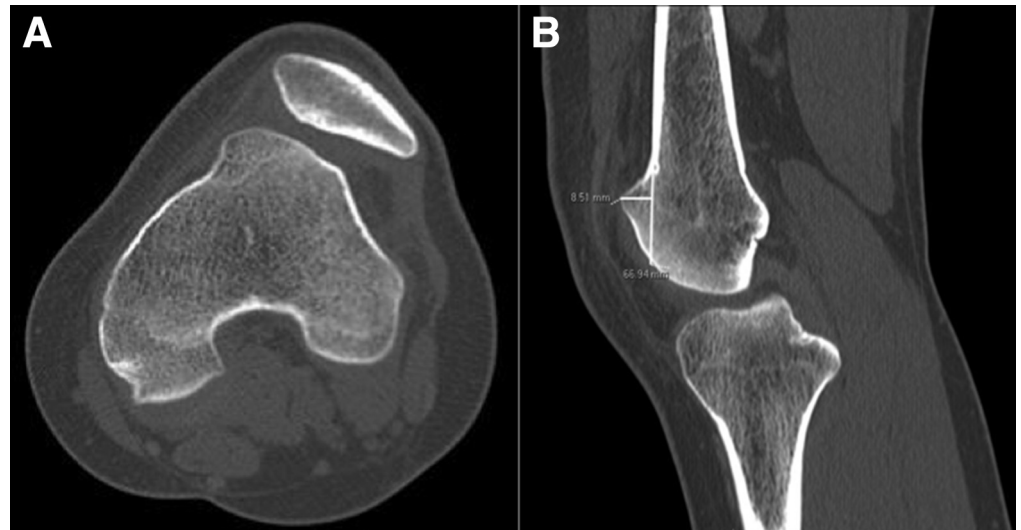### Preoperative Assessment

It is paramount that an adequate preoperative clinical exam and imaging be obtained to gain further insight into the anatomic pathology contributing to the



**Fig 1.** Dejour classification of trochlear dysplasia. Note the 4 morphological variants listed as types A-D with associated radiographic findings. (Reproduced with permission from Dejour D, Saggin PRF. Sulcus-deepening trochleoplasty, in Scott WN, ed., *Insall & Scott surgery of the knee*, 5<sup>th</sup> ed., Philadelphia: Elsevier, 2012; 688-695).

**Fig 2.** Left knee computed tomography (CT) scan. (A) Axial CT image showing high-grade trochlear dysplasia, Dejour B, with significant supratrochlear spur appreciated and lateral patellar subluxation with significant tilt. (B) Sagittal CT image revealing 8.53 mm osseous height of supratrochlear spur.



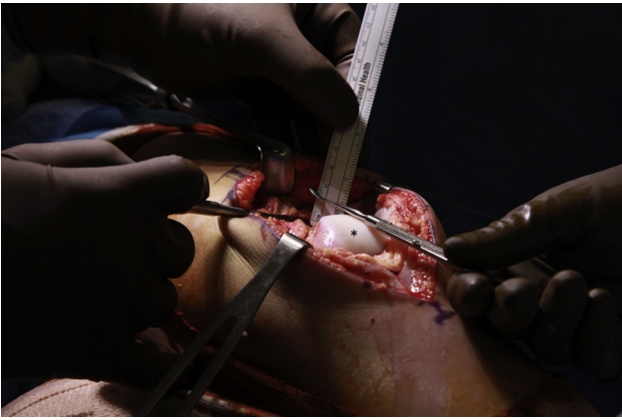**Table 1.** Trochleoplasty Procedure

Indications

- Dejour B/D morphology
- Recurrent primary patellar instability
- Failed previous isolated medial patellofemoral ligament reconstruction or soft-tissue patellofemoral stabilization procedures
- Supratrochlear spur height >5-6 mm

Contraindications

- Dejour A/C morphology
- Osteoarthritis indicative of brittle subchondral bone



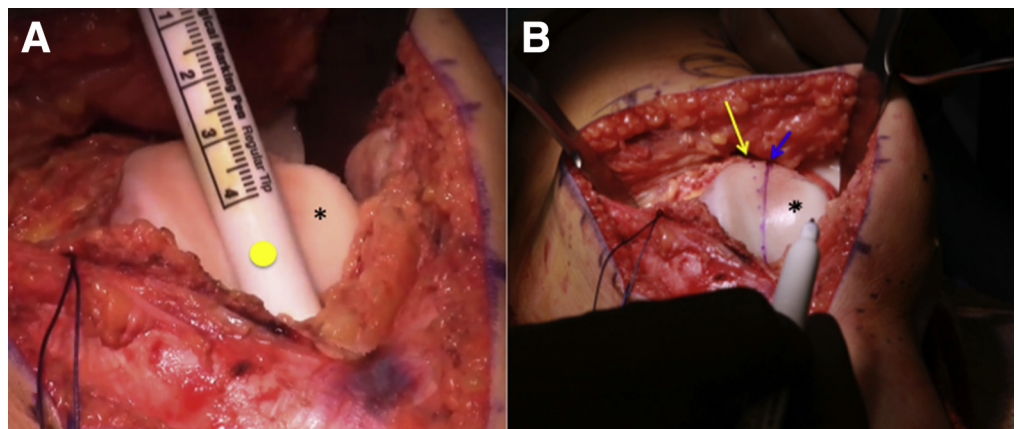
**Fig 3.** Left knee image. A significant supratrochlear spur/boss is appreciated (\*) measuring roughly 14 mm in height from the anterior femoral cortex (note, the preoperative measurement from CT scan [Figure 1](#) accounted for 8.5 mm of osseous spur height with the remaining height as cartilage).

recurrent patellar instability. Many times the presence of a J sign, excessive patellar glide > 2 quadrants, apprehension, and moving apprehension signs are the more reproducible physical exam findings in patellar instability. Plain radiographs are helpful in the baseline determination of existing trochlear dysplasia. The Dejour classification of trochlear dysplasia and descriptive morphologies recognizes 4 main types, seen in [Figure 1](#). Dejour type A, with a shallow trochlear sulcus angle > 145° and a crossing sign, and type C, with a crossing sign and double contour sign, are not indicated for a sulcus-deepening trochleoplasty. Often in severe trochlear dysplasia, a large supratrochlear spur with crossing sign, such as in Dejour type B, as well as the addition of a double contour sign, as seen in Dejour type D, are present and are primary indications for consideration of a trochleoplasty ([Fig 2](#)). Preoperative advanced imaging by MRI or computed tomography (CT) scans is essential in further defining the trochlear morphology. The indications for a

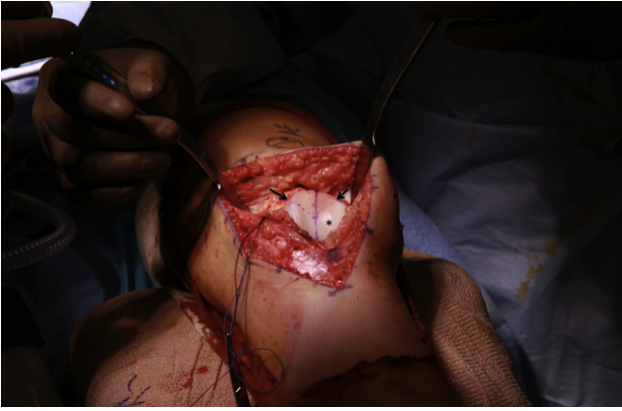trochleoplasty in the setting of recurrent patellar instability are primarily objective findings of a supratrochlear spur height >5 to 6 mm and the presence of a type B or D trochlea ([Table 1](#)).<sup>10,11</sup> Further assessments to quantify patellar tilt, patella alta, and gross patellar maltracking, by elevated tibial tubercle-trochlear groove (TT-TG) distances, are crucial in order to effectively determine what additional surgical procedures are indicated to address the patellar instability.

With the disruption of the MPFL secondary to recurrent patellar instability, an MPFL reconstruction is routinely performed. A patellar tilt angle >20° is indicative of excessive patellar tilt and should be used to assess the potential need for a lateral retinacular lengthening once all other procedures have been completed. A Caton-Deschamps Index ratio >1.3; a patellotrochlear index <0.32; or a sagittal patellofemoral engagement ratio <0.45 are used to critically assess for patella alta and whether a distalizing tibial tubercle osteotomy (TTO) is indicated.<sup>12,13</sup> An elevated TT-TG is assessed with either MRI or CT imaging, with a TT-TG >20 mm suggesting the need for a bony procedure to be combined with a proximal soft-tissue stabilization procedure. CT scans better define this measurement given an MRI can underestimate this measurement by up to 4 mm.<sup>14</sup> A TTO is a powerful corrective tool not only in the setting of isolated maltracking with lateral patellar facet overload syndrome but also with a type A or type C trochlea with associated patellar instability. Commonly, a TT-TG measurement >20 mm is used to perform a TTO with an MPFL reconstruction when a trochleoplasty is not indicated, such as in type A or C trochleas. When a TTO is combined with an indicated trochleoplasty for type B or D trochleas, a more elevated TT-TG of >23 mm is considered as a threshold to add the TTO given that a minimally elevated TT-TG (18-22 mm) can be normalized by the slight lateralization of the newly created trochlear sulcus.

**Fig 4.** Left knee image. (A) A marking pen (yellow dot) is used to roll in line with the native sulcus of the trochlea (\*). (B) A dashed line is drawn along the native sulcus (yellow arrow), and an additional solid line is marked (short blue arrow) just lateral to this. In this case, a line is drawn to help lateralize the created sulcus by 5 mm in order to aid in patellofemoral tracking and articulation.







**Fig 5.** Left knee image. Note the additional dashed lines both medial and lateral (black arrows) have been drawn to delineate the anticipated medial and lateral osteochondral flaps of the trochlea (\*).

### Examination Under Anesthesia/Diagnostic Arthroscopy

The surgical procedure starts with an examination under anesthesia, as this many times will provide additional information without subjective symptoms obfuscating the instability assessment. True patellar glide and lateral tilt can be assessed; however, many times the gross J sign that was present preoperatively will be somewhat diminished given the lack of active quadriceps contraction. Next a standard diagnostic arthroscopy is performed in order to document and address any intra-articular pathology and provide a direct visualization of the patellar instability, maltracking, and arthroscopic J sign, which can be appreciated in [Video 1](#).

A vertical incision is made, incorporating the medial arthroscopy portal. We routinely perform all open procedures under tourniquet to aid in visualization. Should a TTO be required, this incision can be extended distally as needed.

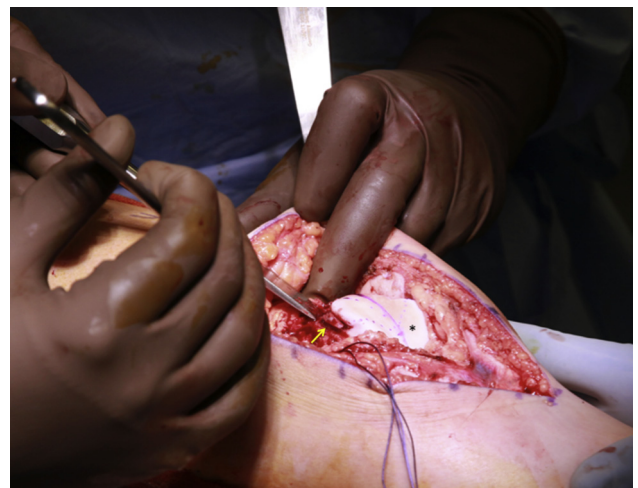### Trochleoplasty

**Templating the Trochlea.** After the medial parapatellar arthrotomy is performed, the actual height of the supratrochlear spur can be measured directly ([Fig 3](#)). A sterile marking pen is then used to assess where the native trochlea sulcus exists. This is completed by rolling the marking pen along the femoral longitudinal axis in the deepest apex of the groove; however, many times it is diminished or flat and nonexistent with the presence of a large supratrochlear spur, as seen in [Figure 4](#). The estimated native sulcus is marked, and the new desired sulcus is drawn as well ([Fig 4](#)). This new sulcus can be lateralized by 4 to 5 mm, which effectively can decrease an elevated TT-TG distance without addressing the tibial side. This is often adequate if a slightly elevated TT-TG exists between 15 and 22 mm. Adequate anticipated osteochondral flaps are then marked out with a marking

pen, which will delineate the new medial and lateral trochlear ridges ([Fig 5](#)).

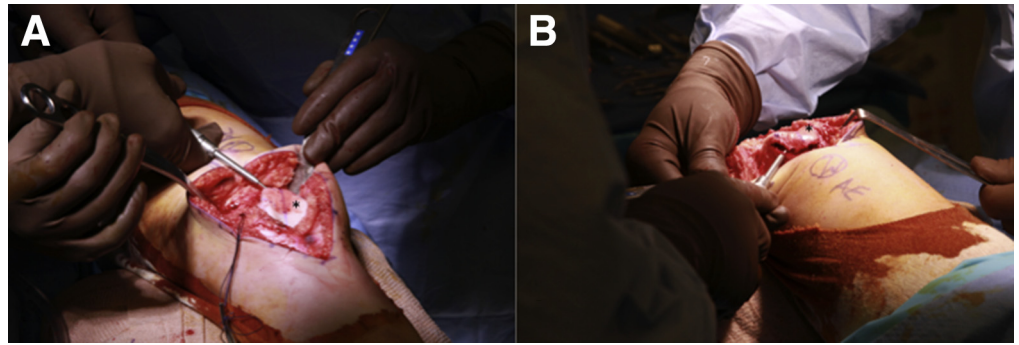**Deepening the Sulcus/Osteochondral Flap Creation.** Next an osteotome is taken to score the cartilage, just below the anticipated articulation line, and the cortical base of the supratrochlear spur, so that a cortical wedge of bone is removed around the articular margin of the trochlea ([Fig 6](#)). This will allow the new trochlea to be flush with the anterior femoral cortex, thus removing the spur's height and anterior offset. This also affords room to introduce a high-speed burr to remove a cavity of cancellous bone beneath the osteochondral shell. We have found the use of a 3-mm egg-shaped burr on a Stryker TPS (total performance system; Stryker Instruments, Kalamazoo, MI) to be most helpful at removing and contouring the spur's subchondral bone ([Fig 7](#)). It is vital to not go beyond the marked flap's most distal border. Creating a deeper apex in the center midline of the new sulcus and tapering it to the periphery medially and laterally will help the leaflets to compress deeper into the sulcus upon fixation. It is important to leave at least a 2- to 3-mm shell of subchondral bone to help limit cartilage injury and allow for adequate healing. A freer can be used to remove the bone slurry produced by this method and to check the resection for adequate depth and contour.

At this point the proximal trochlea osteochondral shell should be ballotable by thumb depression. A no. 20 blade is then positioned on the marked new trochlear sulcus, and a bone tamp and mallet are used to split the osteochondral shell of bone ([Fig 8](#)). This routinely allows satisfactory deformation of the medial leaflet, however, many times the no. 20 blade is also used on the lateral



**Fig 6.** Left knee image. One-inch flat osteotome is used to start the bony resection and a wedge of bone (yellow arrow), the spur height, is removed from the anterior femoral cortex along the periphery of the spur. The trochlea is designated by an asterisk (\*).

**Fig 7.** Left knee images. (A, B) A 3-mm egg burr is used to remove the supratrochlear spur and subchondral bone to create a cavity, deepest in the center and tapered medially and laterally toward the periphery (\*). Great care is taken to preserve roughly 3 mm of subchondral bone, and a freer can be used to assess the level of resection.



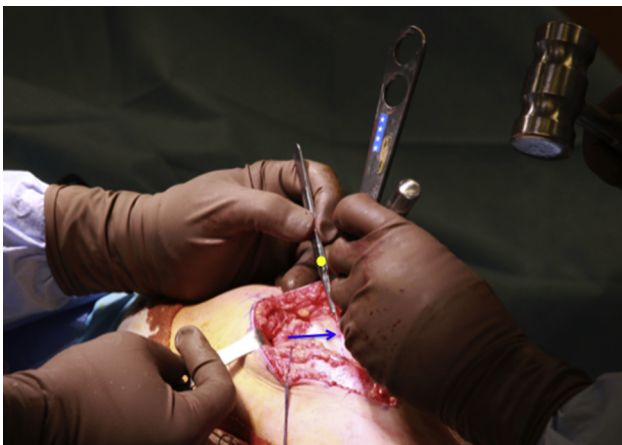edge of the lateral leaflet, up to roughly halfway along its marked course, to create a deformable lateral leaflet. It is important for the splits not to connect at the distal base to avoid a separate, free shingle of bone. The medial leaflet is almost always malleable enough to be bent into the new position without making an extra cut. To improve the transition from the cavity to the unresected bone, the cortical wedge pieces of bone that were initially removed with an osteotome are then placed longitudinally into the defect at the most distal extent of the medial and lateral osteochondral flaps (Fig 9). Furthermore, small cortical bone segments are placed at the periphery along the far medial edge of the medial flap and the far lateral edge of the lateral flap to aid in sulcus angle maintenance while healing. The bone slurry removed at the time of burring is also placed deep within the trochlear defect to aid in healing.

**Trochlea Fixation.** An absorbable knotless suture anchor, such as a 2.9-mm knotless PushLock suture anchor (Arthrex, Naples, FL) loaded with 2 no. 2 vicryl (Ethicon, Cornelia, GA) sutures is placed roughly 5 to

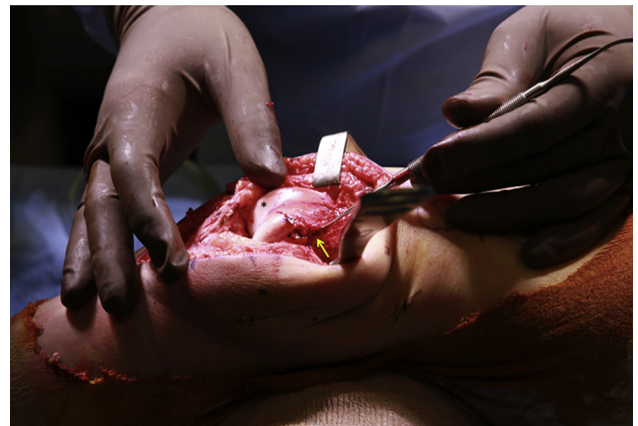10 mm distal to the most distal extent of the sulcus cut line. A single pair of sutures is then draped over the medial osteochondral flap at an angle of pull that will not only maintain the flap reduction but also will not slide into the central osteochondral cut line. This suture is then placed into another knotless 2.9-mm PushLock suture anchor device while maintaining adequate tension on the sutures so it provides compression of the medial leaflet. Once completed, the same procedure is performed for the lateral leaflet with another absorbable knotless suture anchor device. This completes the trochleoplasty and creation of a deepened sulcus (Figs 10 and 11).

**MPFL Reconstruction**

**Patella Tunnel Creation/Graft Passage.** Attention then turns to preparing the patella for tunnel creation and placement. Two short, oblique 3.2-mm drill holes are made, just off the medial patellar cartilage, angled obliquely and anteriorly to exit the anterior patellar cortex in the proximal half of the patella (Fig 12). At the distal-most aspect of the paramedian incision, the

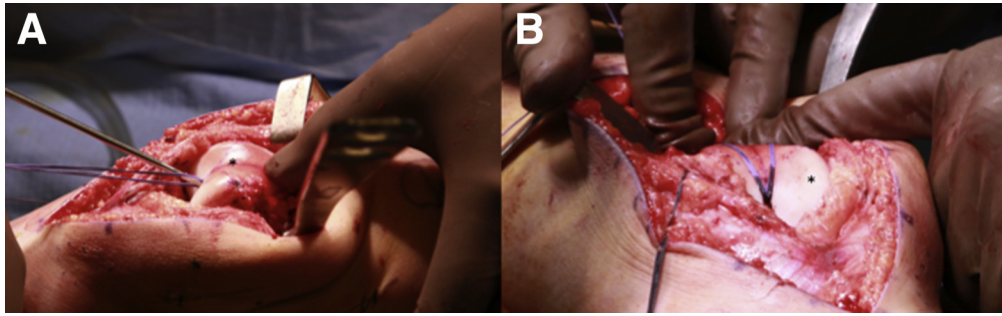


**Fig 8.** Left knee image. A no. 20 blade (yellow dot) is used with a bone tamp to incise the ballottable osteochondral shell along the desired slightly lateralized new sulcus line (blue arrow). This blade is also used up to halfway along the marked lateral leaflet line to create a leaflet that is deformable.



**Fig 9.** Left knee image. A freer is used to place bone fragments (yellow arrow) obtained with the osteotomy (see Fig 5) at the distal-most aspect of the osteochondral flap creation and periphery, medially, and laterally. An asterisk (\*) designates the trochlea.



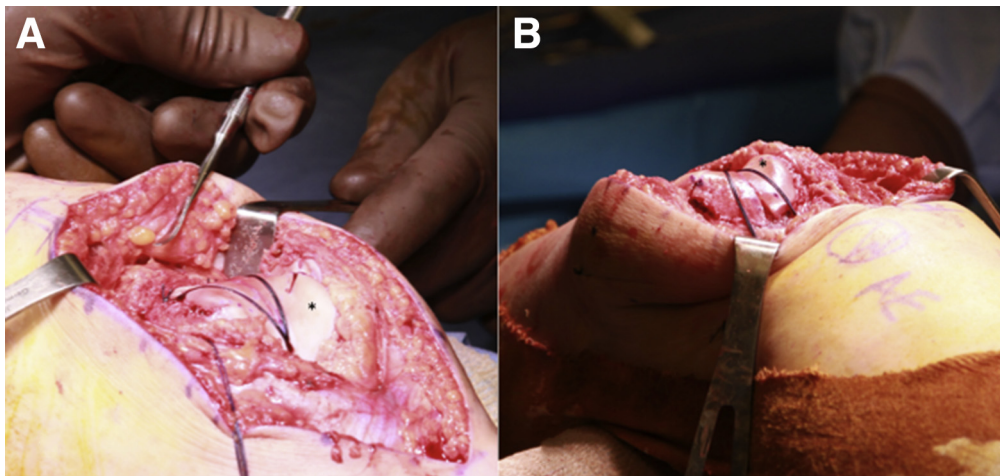


**Fig 10.** Left knee images. (A, B) A double-loaded 2.9-mm absorbable suture anchor is placed with 2 no. 2 absorbable sutures 5-10 mm distal to the extent of the osteochondral split, so as to limit flap instability. The tensioned sutures secure the trochlear flaps (\*) by compression and are secured with a medial and laterally placed absorbable knotless suture anchor.

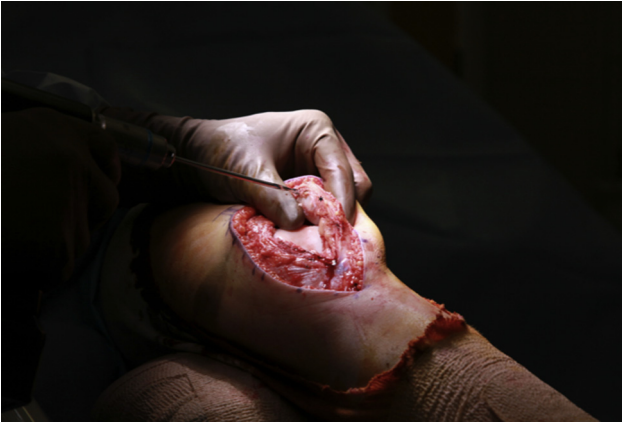hamstring tendons are directly palpated, the upper half of the pes is released, and the gracilis tendon is harvested in standard fashion with a closed tendon harvester. The graft is measured, and the ends are prepared in standard running whipstitch fashion on the back table with no. 0 vicryl (Ethicon). While the length of the graft required for MPFL reconstruction is often times dependent on the size of the leg, we recommend a length of at least 24 cm to account for the looped graft through the drilled patellar tunnels. The bulletted end of the gracilis tendon is then passed in a looped fashion through the patellar tunnels. If the graft is tight, sterile mineral oil can aid in passage. After adequately developing a soft-tissue tunnel for graft passage between layer 2 and layer 3 medially, the MPFL graft is passed through these layers using a suture shuttle and delivered just anterior to the adductor tubercle.

**Femoral Tunnel Creation/Graft Fixation.** With intra-operative C-Arm fluoroscopy to obtain a perfect lateral view, a 3/32" beath pin is placed at Schottle's point (Fig 13). This pin is advanced in an anterior and proximal

direction to help avoid the previously placed suture anchors used to fix the trochleoplasty. The graft ends are then looped around the pin, and the knee is taken from full extension to full flexion to assess for overall graft isometry with attempted lateral patella translation as well as direct visualization of the looped graft ends around the pin. Once satisfactory graft length-tension has been confirmed, the graft ends are measured to assess the depth of reaming required. A 7-mm cannulated acorn reamer is used over the beath pin to create a blind-ended tunnel to the desired length so that tensioning of the graft can occur and will not be limited by a short osseous tunnel. We typically use a 7-mm reamer with a 7-mm diameter biocomposite absorbable interference screw for fixation of a 2-tailed gracilis graft in the femur. A nitinol guide wire is placed into the tunnel at this point, and the graft suture ends are then shuttled through the lateral skin with use of the beath pin (Fig 14). With the knee at roughly 45° of flexion on a radiolucent triangle (Innovative Medical Products, Plainville, CT), the MPFL graft ends are fully introduced into the tunnel and tensioned at roughly



**Fig 11.** Left knee images. (A, B) Note the final construct of osteochondral flap (\*) compression using the 2 no. 2 absorbable sutures to create the new sulcus.



**Fig 12.** Left knee image. A 3.2-mm drill bit is used to create 2 short, oblique patellar tunnels (exiting through the anterior patellar cortex (\*)) that will allow gracilis autograft passage in a looped manner.

0.5 pounds of force, and a 7-mm Milagro interference screw (Depuy Synthes, Raynham, MA) is inserted over the nitinol guide wire. Routinely, as the screw is tightened, we have directly visualized that the graft “creeps” in upon the final turns, which effectively overtightens the graft beyond the desired limit. By performing a half-backwards turn of the screwdriver, this nicely returns the tension to the desired set limit. The patella tracking and translation is assessed through a full arc of motion, with a 1 to 2 quadrant glide laterally with the knee straight.

### Lateral Retinaculum Z Lengthening

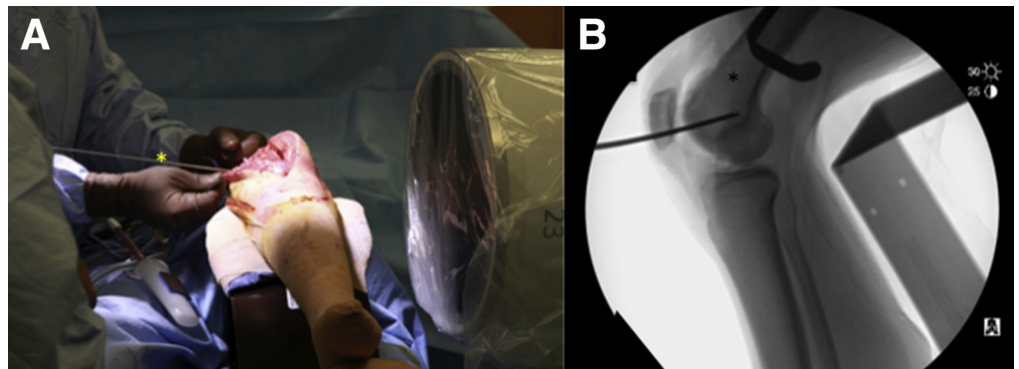
Should the lateral retinaculum be overly tight, potentially causing undue graft tension or relative patellar tilt, we will perform a controlled open lateral retinaculum Z lengthening through the same utilitarian incision (Fig 15). This is saved until the last step, except in unusual circumstances of excessive lateral tightness, to help avoid medial overtensioning of the MPFL graft. Using bovie electrocautery and starting on the most lateral edge of the patella, the superficial layer of the lateral retinaculum is incised vertically and allowed to

reflect laterally. A vertical incision is then made roughly 1.5 to 2 cm posterior to this point through the deep retinacular layer. Upon doing so, many times you will see an improved resting position of the patella with a visible “pop” that will occur. This release is carried distally to the level just above the lateral meniscus and proximal to the most distal extent of the vastus lateralis. The anterior edge of the superficial layer is then reapproximated, by absorbable no. 0 suture, to the posterior edge of the deep layer, effectively lengthening the lateral retinaculum in a controlled manner in a Z fashion (Fig 15). The wound is thoroughly irrigated with copious normal saline. An absorbable no. 1 suture is used to close the medial parapatellar arthrotomy, with great care taken to not incorporate the actual MPFL graft as this will change the overall tension. Successive layer closure is then performed, and the skin is closed with a 3-0 running absorbable suture in subcuticular fashion. The knee is dressed with sterile bandages, and the lower extremity is placed in a hinged knee brace initially locked at 0° to 70° (Fig 16).

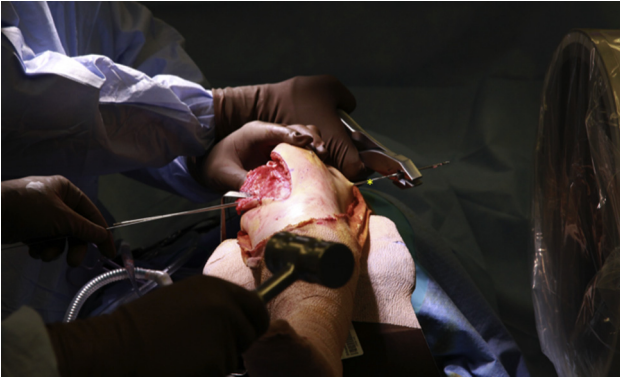### Postoperative Rehabilitation

Patients are placed in a long-leg hinged knee brace and restricted to 50% partial weight bearing to the operative limb for 6 weeks. Physical therapy is started early in the first week as stiffness and scar formation occurs quickly if the knee is not moved in the first few days. The brace is set at 0° to 70° for the first 2 weeks, then 0° to 90° from weeks 2 to 4 postoperatively, and then unrestricted range of motion after the first month. The physical therapist can assist with flexion 15° beyond each brace setting and instruct the patient to do the same with heel slides with the brace removed at home. Additionally, short arc quadriceps activation, isometrics, and electrical stimulation are added with a progression toward stationary bike, elliptical, and leg press between weeks 6 and 12. Jogging is strictly prohibited until after the 12 weeks postoperative point assuming adequate muscle control and absence of an effusion; however, the importance of adequate

**Fig 13.** Left knee image (A) and left knee lateral C-Arm fluoroscopic image (B). Placement of the beath pin (yellow asterisk) is placed using guidance from anatomic landmarks (A) and confirmed on C-Arm image to be correctly placed at Schottle’s point in the femur (\*) (B).





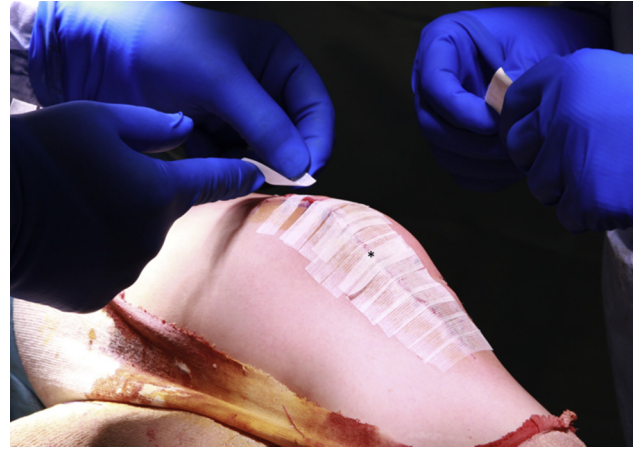


**Fig 14.** Left knee image. After the graft has been checked for isometry by looping the sutures over the beath pin and observing the graft through a full range of motion, the pin is then overreamed with a 7-mm cannulated reamer. The graft suture ends are passed through the beath pin (yellow asterisk) eyelet, and it is malleted through percutaneously. The nitinol guide wire is placed prior to doing so to ensure it is completely in the femoral tunnel. The graft ends are tensioned with 0.5 pounds, and a bioabsorbable screw is then placed with a half turn backwards to limit overtensioning by graft creep.

quadriceps reconditioning cannot be overemphasized. A graduated return to play for sports-specific reconditioning is then allowed with a goal of return to sports by 5 to 6 months postoperatively.

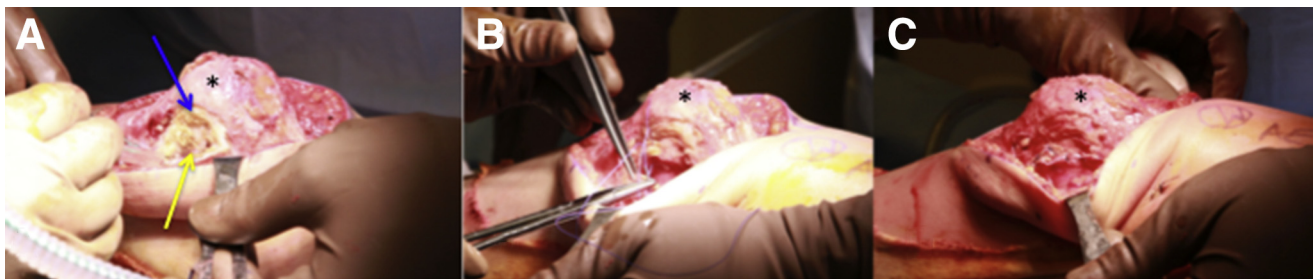
### Discussion

Critically evaluating the etiology of patellar instability and careful attention to preoperative imaging in diagnosing trochlear dysplasia has led to the continued development of surgical procedures aimed to remediate and address this particular variable. For those patients who have a Dejour type B or D trochlea morphology, which presents with symptomatic patellar instability and maltracking, a sulcus-deepening trochleoplasty plus MPFL reconstruction is a reliable technique to stabilize the patella and reduce recurrent instability.<sup>15</sup> These 2 specific dysplastic trochlear subtypes, with associated supratrochlear spurs/boss, have been shown to have increased contact pressures, decreased contact areas, and altered



**Fig 16.** Left knee image. Satisfactory closure is performed with sterile dressing applied. This completes all 3 procedures being performed through a single anterior incision (\*).

kinematics with resultant patellar instability upon biomechanical testing.<sup>5</sup> By eliminating the supratrochlear spur and lateralizing the trochlear sulcus, this places the patella in a more advantageous and favorable tracking pattern with stable articulation. In the largest published case series to date, a sulcus-deepening trochleoplasty provided statistically significant improvements in Kujala scores and an overall 81% patient satisfaction.<sup>16</sup> While the majority of complications were secondary to residual patellar instability, the investigators reported that only 13.8% of patients underwent concomitant MPFL reconstruction at the time of the index trochleoplasty. When an MPFL reconstruction is performed at the time of a trochleoplasty, 2-year follow-up data in 2 separate studies reveal greater than 95% patient satisfaction and no recurrent patellar dislocation events.<sup>17,18</sup> We agree with and routinely provide an MPFL reconstruction as a combined procedure whenever a sulcus-deepening trochleoplasty is performed, as additional 7-year follow-up data further report no recurrence of dislocation specifically with this combined procedure.<sup>19</sup> Biomechanically, initial abnormal patellofemoral kinematics are restored to more normal values after the completion of a



**Fig 15.** Left knee image. (A-C) A lateral retinaculum Z lengthening is performed by incising the superficial lateral retinaculum (blue arrow) just off the lateral aspect of the patella (\*) (A) and then making an incision 1.5-2 cm posterior to this incision through the deep layer (yellow arrow). The anterior edge of the superficial layer is then sutured to the posterior edge of the lateral retinaculum (B). The final construct provides a controlled lengthening of the lateral retinaculum (C).



**Table 2.** Pearls and Pitfalls**Pearls**

- Critically evaluate preoperative imaging for trochlear dysplasia.
- Examination under anesthesia can provide additional insight not appreciated during clinical evaluation.
- Diagnostic arthroscopy can provide a better view and evaluation of patellofemoral wear characteristics with real-time arthroscopic tracking and J sign visualization.
- Delineate the existing sulcus and mark out the new, lateralized trochlear sulcus prior to osteochondral flap creation. Also, mark out the medial and lateral osteochondral lines where the condyle will bend to create the new trochlea.
- Create a cortical window at the base of the supratrochlear spur using an osteotome and keep the cortical bone fragments for later use.
- A 3-mm egg burr is used to adequately resect the excess bone of the spur/boss and to create a deeper cavity in line with the planned sulcus creation, tapering it to the periphery medially and laterally. Ensure at least a 2-3 mm subchondral bone segment for chondral support.
- Ensure the trochlea osteochondral shell is ballotable upon thumb depression, like a diving board.
- Use a no. 20 blade to cut the new central sulcus line and assess whether the trochlea is mobile enough to be reshaped and fixed. In most cases, an additional cut 50% of the length of the lateral osteochondral flap is needed starting at the periphery, but it is crucial that the 2 lines do not connect. This will maintain stable flap segments. Almost never does the medial shell require any cut, as it is the most malleable.
- Place the saved cortical fragments from the initial osteotome cuts distally, at the very base of the trochleoplasty subchondral cavity, to help transition from the cavity to the intact bone as the trochlea is reshaped. This will help prevent settling or a step-off while the osteochondral flaps heal. Additional cortical fragments can be placed along the medial and lateral edges to help lift the margins and deepen the center of the new trochlea.
- Fix the flaps with 2 no. 2 absorbable sutures that are double loaded in an absorbable knotless suture anchor placed 5-10 mm distal to the most distal aspect of the cut sulcus line. Drape, tension, and fix the sutures to knotless suture anchors in the distal femur on either side to fix each osteochondral shingle. The tension is vital given it is the indirect means of fixation to hold down the flaps during healing. Two no. 2 absorbable sutures are used in case one breaks.
- MPFL reconstruction patellar drill tunnels are made with the smallest drill possible to allow graft passage. We recommend a 3.2-mm drill bit with a gracilis graft, angled steeply posterior to anterior, exiting on the anterior patella. A total of 2 drill holes are made in the upper 50% of the patellar length.
- A satisfactory soft-tissue plane is made for graft passage between layer II and layer III, medially, so that it exits just anterior and distal to the palpated adductor tubercle.
- Intraoperative C-Arm use allows the correct identification of Schottle's point and placement of the beath pin.
- Measure the length of the graft off the drill bit and drill a socket for the graft an additional 5 mm beyond that length so that an adequate tunnel length is present and doesn't interfere with graft tensioning.
- Take the slack out of the graft construct and tension with only 0.5 pounds of force. Overtensioning of the graft is the easiest mistake to make. Tension and fix the graft in just enough knee flexion to center the patella in the new trochlea. Deeper flexion magnifies the effect of any mistake in femoral tunnel position for graft kinematics.
- A screwdriver half turn backwards limits excess graft being pulled into the tunnel and restores the desired tension length of the MPFL graft.
- We recommend selective use of a Z lengthening so that it has a controlled lengthening of the lateral retinaculum. Perform this as the last procedure to limit overmedialization of the patella.

**Pitfalls**

- Poor patient selection of an arthritic patellofemoral joint will likely have sclerotic bone, which can complicate and even prevent new trochlear flap creation with possible osteochondral fracture line propagation. Should this destabilize a flap, then possible additional fixation by headless screws could be required.
- Chondral perforation with the burr can occur, especially at the distal extent as the surface curves.
- <2-3 mm subchondral bone segment with potential transfer of heat during burring, resulting in chondrolysis.
- Inadequate tensioning of absorbable suture with loss of fixation resulting in potential nonunion.
- Transverse and large MPFL patella tunnels, with increased risk for patella fracture
- Nonisometric point selection on the femur during tunnel creation. Ensure that a true lateral of the knee is obtained during the placement of the pin at Schottle's point.
- Overtensioning the MPFL graft during femoral fixation, which could result in altered kinematic contact pressures and contact area, or even iatrogenic medial instability.
- If a prior lateral release was performed for patellar instability, then great care will be needed when setting the MPFL tension to ensure the patella is centralized and not overmedialized, which could result in iatrogenic medial instability.

---

MPFL, medial patellofemoral ligament.

deepening trochleoplasty.<sup>9</sup> Knee arthrofibrosis requiring a lysis of adhesions and manipulation under anesthesia is by far the most commonly reported complication of a trochleoplasty, reported in up to nearly 30% of cases.<sup>11,20,21</sup> We have found this to be the most common complication as well; however, the immediate introduction of physical therapy and motion postoperatively helps to lessen this outcome.

There are multiple methods to perform a trochleoplasty and an MPFL reconstruction. Most recent techniques

have detailed the use of biocompression screws to obtain fixation of the trochlear osteochondral flaps and suspensory fixation for patellar graft fixation during MPFL reconstruction.<sup>22</sup> We present a different technique that might present some additional advantages. First, a more traditional Dejour sulcus-deepening trochleoplasty has been presented, which allows for the potential benefit of a defined sulcus creation in the setting of high-grade trochlear dysplasia. As stated above, this also allows for the true lateralization of the sulcus should a slight

elevation in TT-TG be present (TT-TG values between 15 and 22 mm). Benefits of fixation of the osteochondral flaps by indirect compression sutures include not only limiting the violation of the chondral surface, as would be required with headless screws, and the potential for chondral abrasion from proud screws, but also the potential implant cost savings. The use of screws could result in complications of flap fragmentation and fracture. By ensuring an adequate supratrochlear spur height greater than 5 to 6 mm, this will minimize the risk of chondral injury either by direct perforation or by heat-related chondrolysis, as there will still be at least 2 to 3 mm of subchondral bone present with use of the 3-mm egg burr as described above. A further limitation of this technique, in comparison with those that provide an opening wedge to the shallow lateral trochlea, is the fact that the entire trochlear leaflet will require healing back down to the distal femoral metaphyseal bone. A benefit of this described procedure in comparison with the use of metallic hardware or bent Kirschner wires is that a second surgery is not required to remove the implants given the suture is absorbable.

An additional benefit of using short, oblique patellar tunnels for graft passage is that it decreases the risk of patella fracture compared with drilling fully transpatellar tunnels from medial to lateral. Small, oblique tunnels provide stable fixation, with implant cost savings equaling to 2 anchors. Certainly, suture anchor fixation of the graft on the medial edge of the patella is an acceptable option, which reduces fracture risk even further. While it is important to help mitigate the risk of this complication's occurrence, it is even more vital to ensure the correct location of the femoral tunnel as well as the knee flexion angle when the graft is fixed as previous studies have shown the significant impact this can have on graft tensioning and ultimately patellar stability.<sup>23,24</sup> Additional biomechanical studies have also verified the appropriate amount of tension, 0.5 pounds or 2 N, that should be placed on the graft, while placing the femoral screw so as to not overtension the graft.<sup>25,26</sup> The correct positioning of the MPFL graft cannot be overstated.<sup>27</sup>

Another important consideration is to avoid the deepening trochleoplasty procedure in an arthritic patellofemoral joint due to the presence of brittle, eburnated, sclerotic bone. This is a significant risk and potential limitation of this surgical procedure, which can result in fracture propagation when attempting to cut the leaflet with a no. 20 blade or osteotome. The importance of preoperative assessments and patient selection cannot be overstated, as this can result in unstable fragments, which would require additional fixation with multiple headless compression screws and is a challenge for achieving joint congruity. With our evolved experience with this surgical technique, the pearls and pitfalls have been listed in [Table 2](#).

We propose that the above listed surgical technique as a safe, reproducible, and cost-conscious procedure to adequately address recurrent patellar instability in the setting of severe trochlear dysplasia. With the multiple variations of trochlear dysplasia, it is beneficial for all surgeons who manage patellofemoral instability to be aware of variations of surgical procedures to aid in the treatment of this symptomatic condition.

## References

1. Fithian DC, Paxton EW, Stone ML, et al. Epidemiology and natural history of acute patellar dislocation. *Am J Sports Med* 2004;32:1114-1121.
2. Askenberger M, Janarv P-M, Finnbogason T, Arendt EA. Morphology and anatomic patellar instability risk factors in first-time traumatic lateral patellar dislocations. *Am J Sports Med* 2017;45:50-58.
3. Lewallen LW, McIntosh AL, Dahm DL. Predictors of recurrent instability after acute patellofemoral dislocation in pediatric and adolescent patients. *Am J Sports Med* 2013;41:575-581.
4. Steensen RN, Bentley JC, Trinh TQ, Backes JR, Wiltfong RE. The prevalence and combined prevalences of anatomic factors associated with recurrent patellar dislocation: a magnetic resonance imaging study. *Am J Sports Med* 2015;43:921-927.
5. Van Haver A, De Roo K, De Beule M, et al. The effect of trochlear dysplasia on patellofemoral biomechanics: a cadaveric study with simulated trochlear deformities. *Am J Sports Med* 2015;43:1354-1361.
6. Dejour D, Saggin P. The sulcus deepening trochleoplasty—the Lyon's procedure. *Int Orthop* 2010;34:311-316.
7. Blønd L, Schöttle PB. The arthroscopic deepening trochleoplasty. *Knee Surg Sports Traumatol Arthrosc* 2010;18:480-485.
8. Thaanat M, Bessiere C, Pujol N, Boisrenoult P, Beaufile P. Recession wedge trochleoplasty as an additional procedure in the surgical treatment of patellar instability with major trochlear dysplasia: early results. *Orthop Traumatol Surg Res* 2011;97:833-845.
9. Amis AA, Oguz C, Bull AMJ, Senavongse W, Dejour D. The effect of trochleoplasty on patellar stability and kinematics: a biomechanical study in vitro. *J Bone Joint Surg Br* 2008;90:864-869.
10. Pfirrmann CW, Zanetti M, Romero J, Hodler J. Femoral trochlear dysplasia: MR findings. *Radiology* 2000;216:858-864.
11. Donell ST, Joseph G, Hing CB, Marshall TJ. Modified Dejour trochleoplasty for severe dysplasia: operative technique and early clinical results. *Knee* 2006;13:266-273.
12. Biedert RM, Albrecht S. The patellotrochlear index: a new index for assessing patellar height. *Knee Surg Sports Traumatol Arthrosc* 2006;14:707-712.
13. Dejour D, Ferrua P, Ntagiopoulos PG, et al. The introduction of a new MRI index to evaluate sagittal patellofemoral engagement. *Orthop Traumatol Surg Res* 2013;99(8 Suppl):S391-S398.

14. Camp CL, Stuart MJ, Krych AJ, et al. CT and MRI measurements of tibial tubercle-trochlear groove distances are not equivalent in patients with patellar instability. *Am J Sports Med* 2013;41:1835-1840.
15. Song GY, Hong L, Zhang H, et al. Trochleoplasty versus nontrochleoplasty procedures in treating patellar instability caused by severe trochlear dysplasia. *Arthroscopy* 2014;30:523-532.
16. McNamara I, Bua N, Smith TO, Ali K, Donell ST. Deepening trochleoplasty with a thick osteochondral flap for patellar instability: clinical and functional outcomes at a mean 6-year follow-up. *Am J Sports Med* 2015;43:2706-2713.
17. Banke IJ, Kohn LM, Meidinger G, et al. Combined trochleoplasty and MPFL reconstruction for treatment of chronic patellofemoral instability: a prospective minimum 2-year follow-up study. *Knee Surg Sports Traumatol Arthrosc* 2014;22:2591-2598.
18. Nelitz M, Dreyhaupt J, Lippacher S. Combined trochleoplasty and medial patellofemoral ligament reconstruction for recurrent patellar dislocations in severe trochlear dysplasia: a minimum 2-year follow-up study. *Am J Sports Med* 2013;41:1005-1012.
19. Ntagiopoulos PG, Byn P, Dejour D. Midterm results of comprehensive surgical reconstruction including sulcus-deepening trochleoplasty in recurrent patellar dislocations with high-grade trochlear dysplasia. *Am J Sports Med* 2013;41:998-1004.
20. Rouanet T, Gougeon F, Fayard JM, Rémy F, Migaud H, Pasquier G. Sulcus deepening trochleoplasty for patellofemoral instability: a series of 34 cases after 15 years postoperative follow-up. *Orthop Traumatol Surg Res* 2015;101:443-447.
21. Verdonk R, Jansegers E, Stuyts B. Trochleoplasty in dysplastic knee trochlea. *Knee Surg Sports Traumatol Arthrosc* 2005;13:529-533.
22. Dean CS, Chahla J, Serra Cruz R, Cram TR, LaPrade RF. Patellofemoral joint reconstruction for patellar instability: medial patellofemoral ligament reconstruction, trochleoplasty, and tibial tubercle osteotomy. *Arthrosc Tech* 2016;5:e169-175.
23. Burrus MT, Werner BC, Conte EJ, Diduch DR. Troubleshooting the femoral attachment during medial patellofemoral ligament reconstruction: location, location, location. *Orthop J Sports Med* 2015;3: 2325967115569198.
24. Burrus MT, Werner BC, Cancienne JM, Gwathmey FW, Diduch DR. MPFL graft fixation in low degrees of knee flexion minimizes errors made in the femoral location. *Knee Surg Sports Traumatol Arthrosc* 2016.
25. Stephen JM, Kaider D, Lumpaopong P, Deehan DJ, Amis AA. The effect of femoral tunnel position and graft tension on patellar contact mechanics and kinematics after medial patellofemoral ligament reconstruction. *Am J Sports Med* 2014;42:364-372.
26. Beck P, Brown NAT, Greis PE. Patellofemoral contact pressures and lateral patellar translation after medial patellofemoral ligament reconstruction. *Am J Sports Med* 2007;35:1557-1563.
27. Burrus MT, Werner BC, Cancienne JM, Diduch DR. Correct positioning of the medial patellofemoral ligament: troubleshooting in the operating room. *Am J Orthop* 2017;46:76-81.