

# CT diagnosis of a post-embolization ischemic diverticulitis of Meckel

Tom De Beule<sup>1</sup>, Katya Op de Beeck<sup>1</sup>, Gert De Hertogh<sup>2</sup>, Gregory Sergeant<sup>3</sup> and Geert Maleux<sup>1</sup>

Acta Radiologica Short Reports  
3(9) 1–4  
© The Foundation Acta Radiologica  
2014  
Reprints and permissions:  
sagepub.co.uk/journalsPermissions.nav  
DOI: 10.1177/2047981614531954  
arr.sagepub.com



## Abstract

A 23-year-old man presented with hypovolemic shock due to a lower gastrointestinal bleeding. Radiological and endoscopic investigation did not reveal the bleeding site. Emergency visceral angiography showed contrast extravasation at a right-sided branch of the superior mesenteric artery (SMA). Embolization of the bleeding point was performed, resulting in bleeding cessation. One week later, the patient presented with a new episode of moderate anal blood loss associated with diffuse abdominal pain. Computed tomography (CT) revealed an ischemic small bowel diverticulum that was treated by a laparoscopically-assisted segmental small bowel resection. Intraoperative and pathologic analysis confirmed a post-embolization ischemic diverticulitis of Meckel.

## Keywords

Abdomen/gastro-intestinal, computed tomography (CT), angiography, embolization, small bowel, hemorrhage

Date received: 16 January 2014; accepted: 2 March 2014

## Introduction

In 2–3% of the population, the omphalomesenteric duct is incompletely atrophied, and is known as diverticulum of Meckel (1). Secondary changes due to this anomaly result in a zone of ectopic gastric mucosa in the depth of the diverticulum, with risk for developing a peptic ulceration in the vicinity of the unprotected ileal mucosa. Many other complications of this diverticulum have been described, ranging from gastrointestinal bleeding (28%), intussusception and obstruction (11%) to perforation (11%), strangulation (8%), (Littre's) hernia (2%), and a seldom neoplasm (1%). In most cases bleeding is rather occult. However, in rare occasions, there can be a massive bleeding with hemodynamic collapse, even in young children. A diverticulum of Meckel is associated with a 4.8% lifetime risk of developing a complication and this risk decreases with age (2). Diagnosis of a Meckel diverticulum is usually made with the use of 99m-Tcnetium by detecting occult blood loss (3). In order to see blood loss on an angiography, a flow of more than 0.5 mL/min is required (4). Therefore, angiographic investigation for a bleeding Meckel's diverticulum is rare.

## Case report

A 23-year-old healthy male patient presented with a 1-day history of massive rectal blood loss associated with abdominal pain. Abdominal radiograph and ultrasonography (US) did not reveal any alterations. A state of hypovolemia was diagnosed clinically with the presence of a drop in hemoglobin level to 6.8 g/dl. Urgent gastroduodenoscopy and colonoscopy failed to determine the bleeding site. Adherence of blood in the terminal ileum and the ascending colon was seen. His situation aggravated as he became hemodynamically unstable and the patient was immediately referred to the interventional radiology suite for further diagnosis and endovascular management. Selective

<sup>1</sup>Department of Radiology, UZ Leuven/Department of Imaging & Pathology, KU Leuven, Belgium

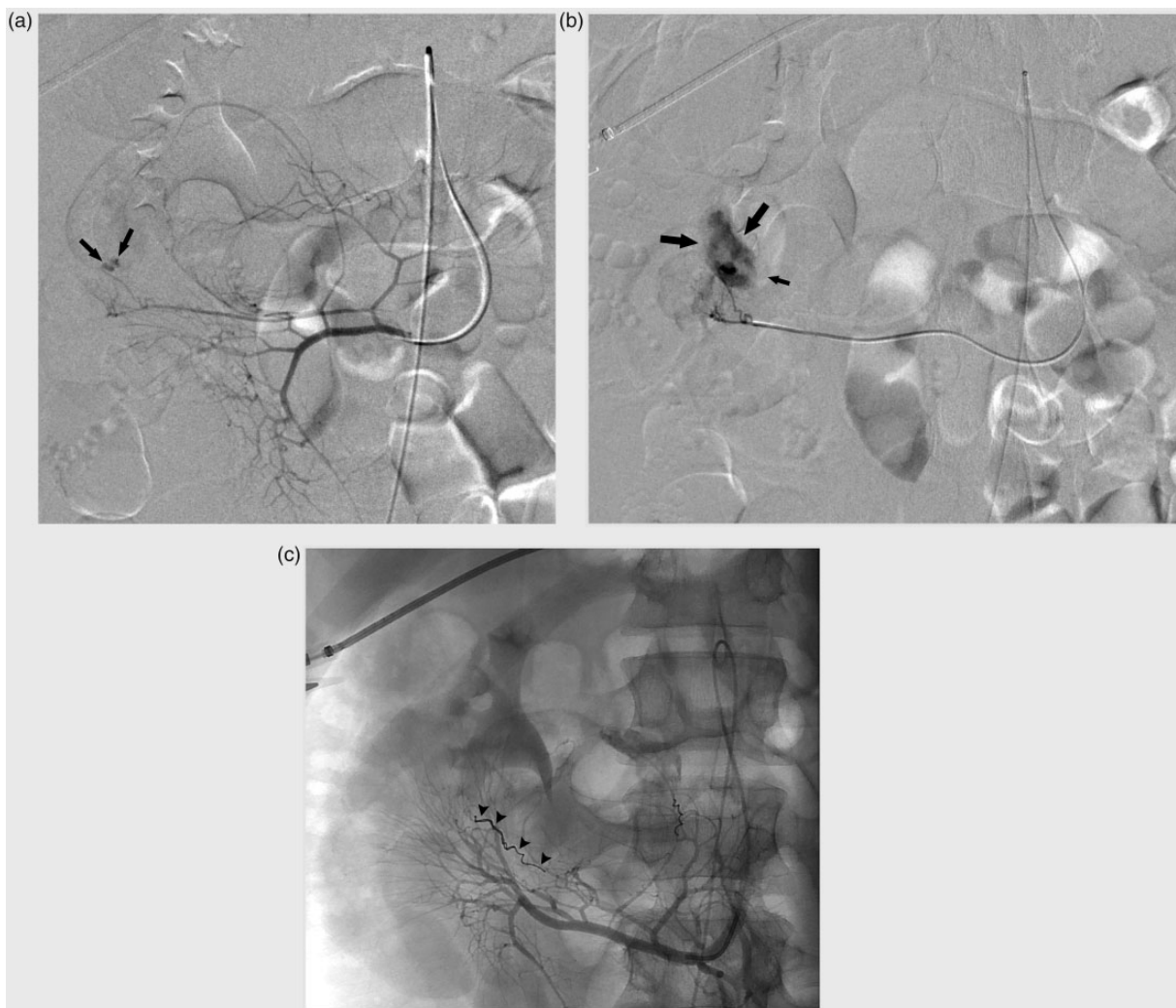
<sup>2</sup>Department of Histopathology, UZ Leuven, Belgium

<sup>3</sup>Department of Abdominal Surgery, UZ Leuven, Belgium

### Corresponding author:

Geert Maleux, UZ Leuven, Department of Radiology, Herestraat 49, 3000 Leuven, Belgium.  
Email: geert.maleux@uzleuven.be





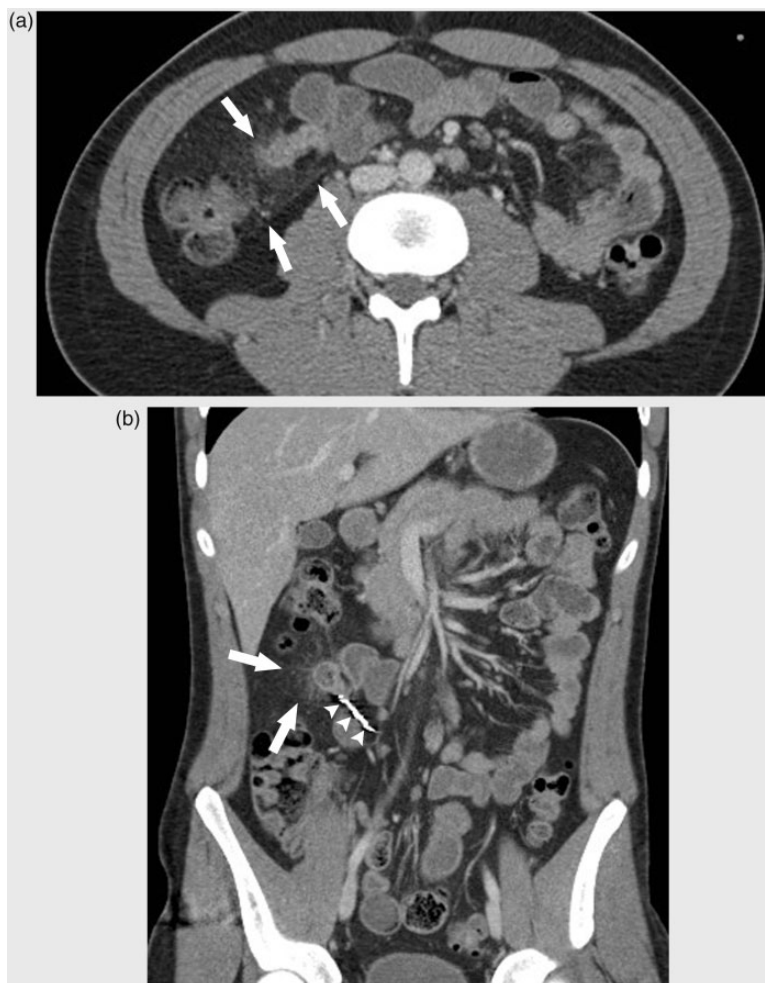**Fig. 1.** (a) Selective catheterization of the superior mesenteric artery showing a terminal artery (arrow) with a contrast blush at the distal end; (b) superselective contrast injection in the omphalomesenteric artery with significant extravasation of contrast material resembling the acute GI bleeding; (c) microcoil embolization of the omphalomesenteric artery and another peripheral more proximal branch.

catheterization of the superior mesenteric artery (Fig. 1a) showed a bleeding from a single artery branching from an ileal artery (Fig. 1b). Successful superselective coil (Microtornado 2/3, Cook Medical, Bloomington, IN, USA) embolization could be achieved through a microcatheter (Progreat 2.7, Terumo Europe, Leuven, Belgium) (Fig. 1c). A control angiography revealed a secondary bleeding location in a more proximal artery branching from the ileal artery, presumably due to collateralization. Subsequent coiling (Microtornado 2/3, Cook Medical, Bloomington, IN, USA) of the artery was successful. Clinically, the patient stabilized and could be discharged 3 days later. A screening abdominal computed tomography (CT) scan to exclude a potential underlying pathology was planned 10 days after discharge. One week later, however, the patient

presented at the emergency department with a new episode of moderate blood loss and abdominal pain. Contrast-enhanced CT showed a diverticulum of the small bowel with a hypodense thickened wall and infiltration of the adjacent mesenteric fat (Fig. 2a and b). Segmental enterectomy of the diverticulum was performed by laparoscopy. Anatomopathological examination confirmed ischemic inflammatory changes of a diverticulum of Meckel with ectopic gastric mucosa at the tip and a giant cell reaction due to the foreign body coils.

## Discussion

Hemorrhage due to a Meckel's diverticulum is mostly a self-limiting disease and occurs in early childhood.



**Fig. 2.** (a) Thickened blind ending structure originating from the terminal ileum with surrounding infiltration of the fatty tissue: ischemic Meckel diverticulum (arrows); (b) coil in the omphalomesenteric artery (arrows).

The bleeding is most often caused by the formation of a peptic ulcer in the wall of the ileum after the prolonged exposure of its mucosa to the acid secretions of ectopic stomach mucosa in the pit of the Meckel diverticulum. Hemorrhage is the most common complication of a diverticulum of Meckel with a broad clinical spectrum ranging from a slow and occult bleeding to a more dramatic manifestation of bright red rectal blood loss associated with hemodynamic instability (5). Catheter-based angiography is a powerful tool to trace the bleeding point and subsequent transcatheter embolization can stop the bleeding (6). However, in order to see significant blood loss on an angiography a flow of more than 0.5 mL/min is required (4).

Catheter-based angiography may show an omphalointestinal artery arising from a distal ileal branch of the superior mesenteric artery. Uniform description of this artery does not exist in the medical literature. Some describe characteristic findings, such as an elongated appearance without branching and ending in a group

of tortuous vessels (7). Angiographic determination of the origin of the bleeding site can therefore be difficult in some cases.

In our case there was a prominent artery originating from the SMA to the right presumably branching from an ileal artery. Because of the prominent contrast extravasation at the distal end, a superselective angiography was performed to occlude this vessel. Embolization with microcoils was performed. Embolization of a lower GI bleeding has a clinical success rate of 76%, however with a high risk of complications if repeat embolization (due to opening of collaterals) is required. Embolization of distal artery supply carries a risk for creating ischemia. This is well known in the standard embolic treatment for lower GI bleeding, but this risk was very large in the earlier age of transcatheter embolization, when superselective catheterization was not yet possible. At a rate of 20–23%, nowadays, ischemic complications after embolization of lower GI bleeds have become less frequent (8).

In our case the bleeding stopped and the patient recovered very quickly. The angiographic characteristics of the bleeding vessels were atypical for a Meckel's diverticulum. Therefore, no further investigation was performed immediately after the embolization procedure in order to exclude an underlying etiology of the bleeding. Owing to the embolization an ischemic diverticulitis occurred and the patient presented again with new signs of moderate anal blood loss and diffuse abdominal pain. CT clearly demonstrated ischemic signs of the diverticulum including thickened wall of the diverticulum and infiltration of the small bowel mesentery. No intestinal contrast extravasation could be identified on CT examination (9).

In conclusion, the atypical angiographic appearance was misleading for the diagnosis of Meckel's diverticulum, resulting in discharge of the patient without further investigation of the bleeding etiology. However, CT examination performed 1 week later revealed post-embolization ischemic Meckel's diverticulum, promptly treated by laparoscopic surgical technique, underlining the value of CT in diagnosing an ischemic post-embolization Meckel's diverticulum.

#### **Conflict of interest**

None declared.

#### **Funding**

This research received no specific grant from any funding agency in the public, commercial, or not-for-profit sectors.

#### **References**

1. Menezes M, Tareen F, Saeed A, et al. Symptomatic Meckel's diverticulum in children: a 16-year review. *Pediatr Surg Int* 2008;24:575–577.
2. Soltero MJ, Bill AH. The natural history of Meckel's diverticulum and its relation to incidental removal: A study of 202 cases of diseased Meckel's diverticulum found in King County, Washington, over a fifteen year period. *Am J Surg* 1976;132:168–173.
3. Sty JR, Starshak RJ. The role of radionuclide studies in pediatric gastrointestinal disorders. *Semin Nucl Med* 1982;12:156–172.
4. Eglinton T, Fernando C. Bleeding Meckel's diverticulum diagnosed with enterocolysis and mesenteric angiography. *N Z Med* 2004;117:U1133.
5. Levy AD, Hobbs CM. From the archives of the AFIP. Meckel diverticulum: radiologic features with pathologic correlation. *Radiographics* 2004;24:565–587.
6. Okazaki M, Higashihara H, Yamasaki S, et al. Arterial embolization to control life-threatening hemorrhage from a Meckel's diverticulum. *Am J Roentgenol* 1990;154:1257–1258.
7. Mitchell AW, Spencer J, Allison DJ, et al. Meckel's diverticulum: angiographic findings in 16 patients. *Am J Roentgenol* 1998;170:1329–1333.
8. Tan KK, Wong D, Sim R. Superselective embolization for lower gastrointestinal hemorrhage: an institutional review over 7 years. *World J Surg* 2008;32:2707–2715.
9. Russ PD, Friefeld GD, Nauck CJ, et al. Infarcted Meckel diverticulum detected by CT. *Am J Roentgenol* 1988;150:299–300.