

# Clinical Features and Pathophysiological Mechanisms of COVID-19-associated Gastrointestinal Manifestations

Abdullah Tarık Aslan<sup>1</sup>, Halis Şimşek<sup>2</sup>

## ABSTRACT

**Aim and objective:** According to the literature, gastrointestinal (GI) involvement may have a remarkable influence on the course of coronavirus disease-2019 (COVID-19). Our aim with this article is to appraise clinical characteristics and presumptive biological mechanisms of digestive tract involvement of COVID-19.

**Background:** In this review article, the English language literature was reviewed by using PubMed and MEDLINE databases, up to February 2021.

**Review results:** The patients with GI involvement are generally presented with diarrhea, nausea/vomiting, anorexia, abdominal pain, and rarely GI bleeding. However, frequencies of these manifestations are diverse in studies published so far, depending on the countries where the studies were conducted, characteristics of the study populations, and methodological differences. Several studies proved that this novel coronavirus gets into the enterocytes by attaching to angiotensin-converting enzyme 2 receptor. Some of them have shown a direct viral invasion and replication of the virus within enterocytes. Along with detection of severe acute respiratory syndrome coronavirus 2 (SARS-CoV-2) in patients' fecal materials, all these results explicitly indicate that the virus has the capability to invade the GI system. These findings may represent a potential risk indicator for fecal–oral spread of the virus. Although pathophysiology of COVID-19 associated GI manifestations remains elusive, direct viral damage, dysfunction in renin–angiotensin–aldosterone system, effects of gut–lung axis, and GI tract microbiome dysbiosis have been proposed as culprit mechanisms of the GI symptoms and inflammatory response.

**Conclusion:** The patients with COVID-19 can be presented with diverse clinical manifestations including the GI symptoms. Understanding the actual impact of the virus on the GI tract depends on uncovering the pathophysiology of COVID-19.

**Clinical significance:** GI involvement of COVID-19 appears to be crucial not only for its clinical consequences but also for its impacts on public health and prevention.

**Keywords:** Angiotensin-converting enzyme 2, COVID-19, Gastrointestinal manifestations, Pathogenesis, SARS-CoV-2.

*Euroasian Journal of Hepato-Gastroenterology* (2021): 10.5005/jp-journals-10018-1347

## BACKGROUND

For the last 1.5 years, a newly emerged transmissible human coronavirus has upset the public health worldwide by causing a disease resulting in acute respiratory distress syndrome (ARDS), multiorgan dysfunction, and even death.<sup>1</sup> Following the extensive dissemination of the virus worldwide, on March 11, 2020, coronavirus disease 2019 (COVID-19) was declared as a new pandemic by the World Health Organization (WHO).<sup>2</sup>

Coronaviruses are infectious agents that are well known to cause infections in many organ systems such as the respiratory system, central nervous system, and gastrointestinal (GI) system in many mammalian species, including humans.<sup>3</sup> In terms of clinical standpoint, severe acute respiratory syndrome coronavirus 2 (SARS-CoV-2) infections usually have mild and self-limiting clinical manifestations, although up to 15% of patients may present with severe and life-threatening disease findings. Moreover, mortality rate of COVID-19 has been reported as 2–3% in many cohorts.<sup>1</sup> The course of severe disease has two distinct phases: the first phase has characteristics of classic viral respiratory infection and, however, the second phase presents with an acute deterioration and complications due to exaggerated cytokine release.<sup>4,5</sup> The most common underlying diseases predisposing to severe COVID-19 are hypertension, diabetes, and cardiovascular diseases.<sup>4</sup> The main complaints of the infected persons are usually high fever, shortness of breath, cough, and fatigue, which may be accompanied by the GI symptoms.<sup>6</sup> Similarly, SARS-CoV and

<sup>1</sup>Department of Internal Medicine, Gölhisar State Hospital, Burdur, Turkey

<sup>2</sup>Department of Gastroenterology, Hacettepe University Faculty of Medicine, Ankara, Turkey

**Corresponding Author:** Abdullah Tarık Aslan, Department of Internal Medicine, Gölhisar State Hospital, Burdur, Turkey, Phone: +905346754889, e-mail: aslanabdullahtarik@gmail.com

**How to cite this article:** Aslan AT, Şimşek H. Clinical Features and Pathophysiological Mechanisms of COVID-19-associated Gastrointestinal Manifestations. *Euroasian J Hepato-Gastroenterol* 2021;11(2):81–86.

**Source of support:** Nil

**Conflict of interest:** None

Middle East respiratory syndrome coronavirus (MERS-CoV) could lead to respiratory and the GI involvement, with an incidence of the GI symptoms exceeding 20%.<sup>1</sup>

All coronaviruses produce a surface spike protein that is a crucial part of cross-species transmission. Like SARS-CoV-2, SARS-CoV yields angiotensin-converting enzyme 2 (ACE2) for binding to host cells. However, a different receptor named dipeptidyl peptidase 4 (DPP4) mediates cell entrance of MERS-CoV.<sup>7,8</sup> Wrapp et al.<sup>9</sup> proved that the binding affinity of SARS-CoV-2 to ACE2 is considerably higher than (~10–20 folds) of SARS-CoV to ACE2. The entrance of SARS-CoV-2 into the host cells via ACE2 receptors is strictly

controlled by a serine protease called transmembrane protease serine protease (TMPRSS2).<sup>10</sup> On the contrary, soluble ACE2 blocks the binding of SARS-CoV-2 to this receptor.<sup>6,9</sup> In lung tissue, ACE2 is primarily expressed in cell surfaces of ciliated cells and type II alveolar epithelial cells.<sup>11</sup> However, the most prevalent expression of ACE2 is seen in the brush borders of enterocytes.<sup>11</sup> Furthermore, SARS-CoV-2 can be isolated in rectal swab samples even after viral RNA has disappeared in nasopharyngeal samples, suggesting GI infection and a potential risk for fecal–oral transmission.<sup>12</sup> Although viral copy numbers in fecal samples are generally lower than respiratory samples, preventive measures may be required when there is a risk of contact with fecal materials.

By searching the current data in the literature dealing with GI involvement of COVID-19, we purpose to overview the GI manifestations of COVID-19 and presumptive biological mechanisms of the GI symptoms.

## REVIEW RESULTS

### Clinical Features of Gastrointestinal Involvement

Accumulating evidence has shown that COVID-19 may be associated with diverse GI symptoms, most commonly diarrhea, nausea/vomiting, and abdominal pain.<sup>13–17</sup> Consistently, a recent meta-analysis involving 10,890 participants reported the prevalence of the GI symptoms as 7.7, 7.8, and 2.7% for diarrhea, nausea and/or vomiting, and abdominal pain, respectively.<sup>18</sup> As firstly reported in a case from the USA, where the presented case had vomiting and diarrhea for 2 days prior to hospitalization,<sup>12</sup> the patients infrequently display solitary GI symptoms without accompanying respiratory symptoms.<sup>19,20</sup> Another study found the prevalence of the GI symptoms to be 10–21%, and these symptoms mostly consisted of nausea/vomiting, diarrhea, and loss of appetite. Additionally, among all patients, approximately 10% presented with the GI symptoms without concomitant respiratory manifestations.<sup>21</sup> Similarly, a large-scale study underlined that 16% (183/1,141) of the patients suffering from COVID-19 had solely GI features at initial presentation.<sup>22</sup> Moreover, the patients presenting solely with the GI symptoms tend to be diagnosed late, which may facilitate viral dissemination among persons with whom they have a close contact.<sup>21,23</sup> This situation requires awareness among clinicians since these patients can be hospitalized for their GI features in a non-COVID-19 inpatient unit, and this could arise a potential risk for dissemination.<sup>23</sup>

In another meta-analysis, the prevalence of diarrhea was in the range of 4.3–12.2%, while the prevalence of nausea/vomiting was between 2.6 and 8.0%. SARS-CoV-2 RNA on feces was tested in 8 of 29 studies included, and viral RNA positivity rate was 40.5% [95% confidence interval (CI), 27.4–55.1%].<sup>24</sup> In parallel with these findings, among 9 of 17 patients (52.9%) with detectable viral RNA in respiratory samples, fecal RNA positivity was confirmed by polymerase chain reaction (PCR) analysis up to 11 days of initial presentation. However, titers of viral RNA in fecal materials were markedly lower when compared to respiratory samples (ranged  $550\text{--}1.21 \times 10^5$  vs  $641\text{--}1.34 \times 10^{11}$  copies/mL).<sup>25</sup> Consistently, Ling et al. demonstrated that 11 out of 66 patients (16.7%) who recovered with COVID-19 treatment still carried viral genomic RNA in their stools for a median 11 days after symptom onset.<sup>26</sup> Furthermore, fecal PCR test detected SARS-CoV-2 positivity in 23.3% of the patients, despite respiratory samples of these patients did not harbor any viral genomic material.<sup>27</sup> It is also noteworthy to mention that the interrelation between viral RNA positivity in

stool and GI manifestations was reported quite heterogeneous in different studies. Some studies reported that the GI symptoms particularly diarrhea had a close correlation with higher probability of viral RNA carriage in fecal samples, higher SARS-CoV-2 viral load, and longer duration of fecal viral shedding.<sup>20</sup> On the contrary, in another study, the presence of the GI manifestations was claimed not to be associated with viral RNA positivity in stool. Furthermore, the disease severity did not parallel with prolonged duration of viral shedding in stool.<sup>28</sup>

In contrast to patients without the GI symptoms, those with the GI symptoms are more prone to cough, fatigue, and headache.<sup>15</sup> Routine laboratory tests reveal higher levels of neutrophils and acute phase reactants, like C-reactive protein (CRP) among patients with the GI symptoms, suggesting that systemic inflammation occurs more severely in these patients.<sup>15</sup> Furthermore, abnormalities of liver function tests were observed in up to 17.5% of the patients with the GI symptoms compared with 8.8% of the patients without the GI symptoms. The prevalence of ARDS was significantly higher in the patients with the GI symptoms (6.7%) compared with those not having any GI symptom (2.08%).<sup>15</sup> Similarly, the rates of recovery and hospital discharge were significantly higher in those without the GI symptoms than in the patients having the GI symptoms.<sup>5</sup> In contrast, according to another systematic review, only abdominal pain was a predictor of severe COVID-19 and death. In this study, it was clearly stated that neither nausea/vomiting nor diarrhea were harbingers of more severe disease.<sup>29</sup> This can be explained by possible association with secondary involvement of the digestive tract through dysregulated inflammatory response developing in severe cases.

Among patients with COVID-19, diarrhea is typically mild and characterized by loose to watery stools that are not bloody. Its recovery generally takes more than a median of 5 days. Endoscopy undertaken on such a patient usually does not demonstrate major mucosal changes, but microscopic evaluation detected infiltration of large numbers of lymphocytes into the lamina propria.<sup>27</sup> These findings are similar to what we are used to see in viral gastroenteritis.

### Other Rare Gastrointestinal Manifestations

#### *Gastrointestinal Ischemia*

Several studies asserted a possible association between acute hemorrhagic colitis or GI bleeding and COVID-19.<sup>5</sup> In an Italian study, seven patients with intestinal ischemia were reported. All patients have GI symptoms possibly caused by the intestinal ischemia. Of these seven patients, two had findings of ischemic colitis and four had evidence of ischemia affecting either the small bowel or the right transverse colon. The remaining one patient had ischemic colitis diagnosed by endoscopic examination. Pronounced elevation in D-dimer level was detected in six patients, except for one patient whose D-dimer level was not checked. A thoracic computed tomography (CT) scan was carried out in six of seven patients, and pulmonary thromboembolism was diagnosed in only one patient. Among all patients, 57% (4/7) have died during the hospitalization.<sup>30</sup> In a systematic literature review, 22 studies including 31 patients with COVID-19 related GI ischemic complications were evaluated. Nine patients (29%) presented with arterial hypoperfusion and ensuing bowel ischemia due to superior mesenteric thromboembolism. Additionally, portal system and superior mesenteric vein thrombosis were detected in six patients (19.3%). Almost two-thirds of patients underwent laparotomy

and bowel resection. In consequence, 12 patients were (38.7%) died during hospitalization.<sup>31</sup> Despite these reports, it remains elusive whether arterial thromboembolism is directly related with COVID-19 or simply a coincidental event. Several mechanisms are asserted to play an important role in the pathophysiology of COVID-19 related venous or arterial thrombosis. Endothelial inflammation, complement activation, thrombin formation, and untamed immune response can be considered as main culprit mechanisms leading to thrombotic complications.<sup>32</sup> Additionally, in the COVID-19 patients, positive pressure ventilation, shock, intensive care unit (ICU) admissions, and viral enteritis should be kept in mind as contributing factors leading to intestinal ischemia. Among critically ill persons, the COVID-19 associated coagulopathy was demonstrated to be responsible for microangiopathy, severe thromboses, and related complications in various studies.<sup>16,20</sup>

In summary, physicians should always consider COVID-19 as a possible diagnosis of the patients with the GI symptoms. They need to be encouraged to perform cross-sectional imaging studies and clinical screenings as progression of the GI ischemia, and resulting complications can lead to mortality and emergent surgical intervention.

### *Pancreatitis*

Viral infections are among the well-established causes of acute pancreatitis (AP) as several reports described AP due to hepatitis viruses, coxsackieviruses, and herpesviruses.<sup>33</sup> ACE2 is found in both exocrine and endocrine pancreas with a higher intensity than pulmonary cells.<sup>34</sup> However, pancreatic involvement was rarely described. Abdominal pain, albeit relatively rare, has been reported as one of the GI manifestations seen in COVID-19.<sup>22</sup> However, in studies published up to now, further investigations are generally not conducted or reported to confirm the diagnosis of AP. Conversely, in two SARS-CoV-2 infected patients with imaging evidence that definitively excluded other etiologies of acute pancreatitis, AP was identified with multiple organ failure, abdominal pain, and elevated serum amylase level.<sup>35</sup> Similarly, in the USA, a case of COVID-19 having a complaint of severe epigastric pain was considered AP. This patient had high pancreatic enzyme levels, unremarkable findings on pancreatic imaging, and no other risk factors.<sup>36</sup> In a systematic review, the data of eleven COVID-19 patients with AP from two retrospective cohorts and six case reports were analyzed. In accordance with the Atlanta classification, only five patients had AP. Although well-known etiological factors were not investigated in many cases, most patients were evaluated as AP caused by SARS-CoV-2.<sup>37</sup> Therefore, a causative linkage between COVID-19 and AP cannot be established precisely by relying on current literature.

In severe cases, AP can be a consequence of direct viral invasion of pancreatic acinar cells or an exaggerated immune response leading to multiorgan injury. Furthermore, severely ill patients who require mechanical ventilation or in shock may develop AP due to systemic hypoperfusion. The crucial role of adherence to the guideline in the diagnosis and etiological examination of AP should be emphasized since specific treatment options are available according to the etiology of AP.

In the current literature, autopsy studies evaluating pancreatic pathology of deceased COVID-19 patients are scant. The examinations of pancreatic tissue samples from three deceased patients showed mild islet cell injury and did not detect any abnormalities in exocrine cells. Additionally, in this study, SARS-CoV-2 could not be demonstrated in pancreatic samples.<sup>38</sup> In contrast, SARS-CoV had been identified in vast majority of four

patients' pancreatic autopsy specimens.<sup>39</sup> Hence, further autopsy studies in COVID-19 patients are needed to understand the changes in pancreatic tissue caused by this disease.

As a conclusion, contemporary data supporting pancreatic involvement of COVID-19 are not yet sufficient and more research is needed to uncover the effects of SARS-CoV-2 infection on both endocrine and exocrine pancreas.

### **Pathogenesis of Gastrointestinal Manifestations of COVID-19**

Although target receptor of SARS-CoV-2 is found in lung parenchymal cells, this receptor is more abundantly expressed in enterocytes and cholangiocytes.<sup>27</sup> In fact, the ACE2 expression level of the GI tract is nearly 100 times higher than in airway epithelial cells.<sup>40</sup> The viral particles of SARS-CoV-2 have been shown to be present throughout the digestive tract, including epithelial cells of the stomach, duodenum, and rectum. Other studies searched the presence of the viral particles in human small intestine organoids and found that this novel coronavirus has tropism for several organs, including the GI tract.<sup>41</sup> In humans, the GI tract infection was also proved by endoscopic biopsies on patients who had the viral RNA in their stools.<sup>27</sup> Strikingly, the expression of ACE2 receptors along the gut appears to be dependent on the age of the patients. This expression was investigated in duodenal biopsy specimens from 43 healthy adults. In consequence, there was more abundant ACE2 mRNA expression through the GI tract of older patients as compared with younger individuals. This can shed on light the reason of propensity of elderly individuals to develop the GI symptoms.<sup>42</sup>

ACE2 has a crucial task in regulating inflammation and diarrhea. ACE2 does not carry out its function through the renin-angiotensin-aldosterone system (RAAS) in the GI tract, but instead exerts its effect by regulating the uptake of gut amino acids, production of antimicrobial peptides, and composition of the GI tract microbiota.<sup>43</sup> Notably, ACE2 is a regulator of B0AT1 (transporter of neutral amino acids) that promotes the uptake of tryptophan into the enterocytes. Tryptophan is in turn utilized in the synthesis of antimicrobial peptides. Therefore, expression of antimicrobial peptides is inhibited by the attachment of SARS-CoV-2 to ACE2 receptors. Blockage in antimicrobial peptide expression results in an abnormal homeostasis of intestinal microbiota. In turn, these changes may lead to systemic inflammation and dysregulation in the innate immune system of the GI tract.<sup>43</sup> In line with previous findings, some studies verified that SARS-CoV-2 causes absorptive dysfunction, increased GI secretion, and activation of the enteric nervous system via interacting with ACE2 receptor.<sup>19</sup>

Furthermore, alterations in the structure and function of the intestinal microbial flora may have an impact on the respiratory system by acting on common mucosal immune system. Similarly, changes in the respiratory flora can have detrimental effects on the GI system by the mechanism called as "gut-lung axis".<sup>44</sup> In consistent with this hypothesis, SARS-CoV-2 is often undetectable in feces of COVID-19 patients with GI symptoms. Hence, we may consider that the GI manifestations of some patients may not be a ramifications of viral invasion-mediated mucosal damage.

Effector CD4 (+) T cells located in the intestinal mucosa are necessary for mucosal immunity. One study reported that C-C chemokine receptor type 9 (CCR9) mediates the entry of CD4 (+) T cells into the small bowel and the expression of lung-derived CCR9 (+) CD4 (+) T cells was significantly increased as a consequence of viral infections.<sup>45</sup> The recruitment of these T cells into the intestinal tissue is promoted by CCL25, which

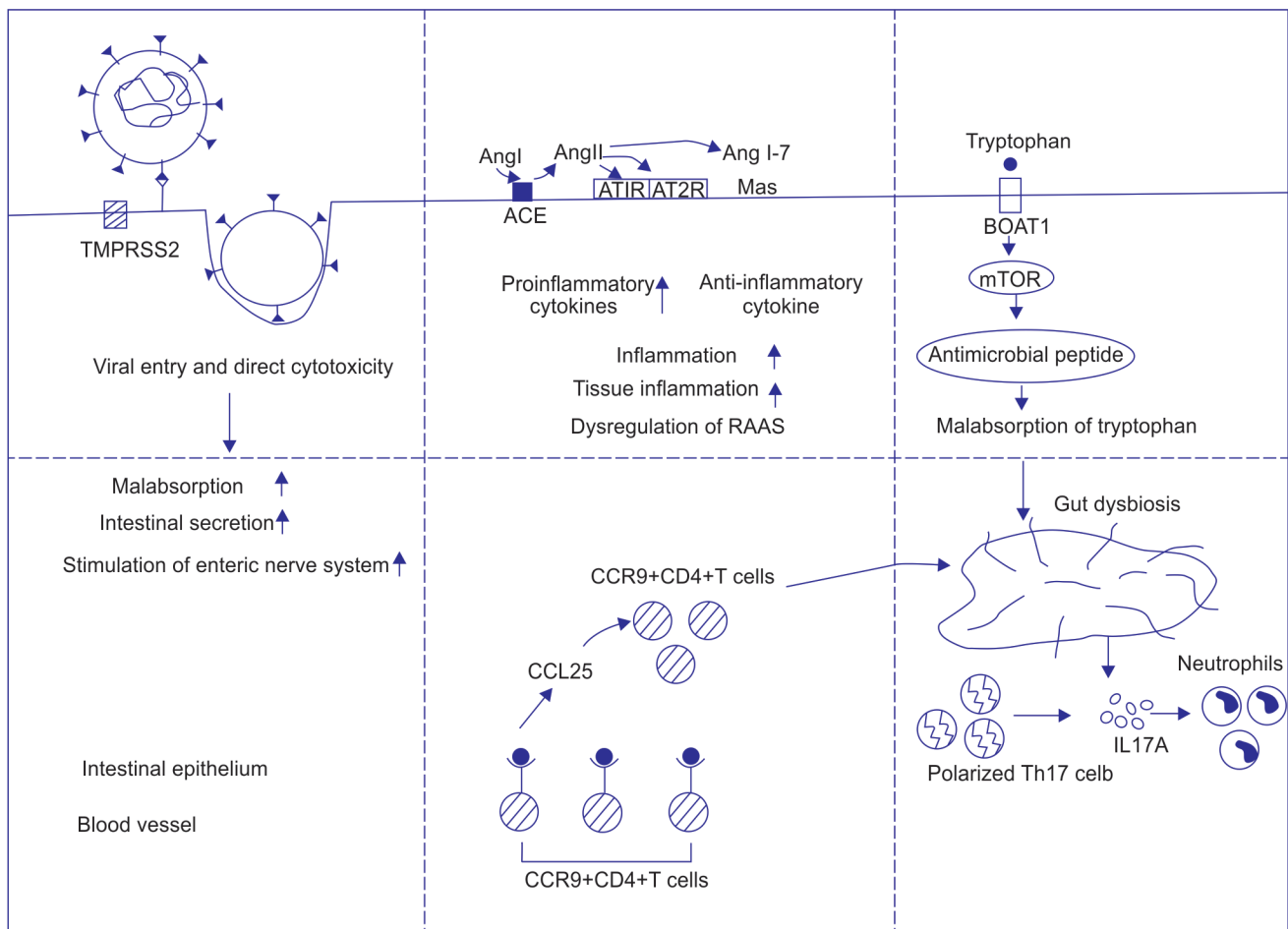
is expressed by the small intestinal epithelium. Eventually, this leads to immune system-mediated intestinal injury and ensuing destruction of the homeostasis of the intestinal flora.<sup>46</sup> Disruption of the gut microbiome will stimulate the polarization of Th17 cells and IL-17A produced from these cells will lead to the recruitment of neutrophils into the lamina propria of gut.<sup>47</sup> Consistently, histopathological examinations verified the plasmacytic and lymphocytic infiltration of the gastric, duodenal, and rectal epithelium as well as more patchy infiltration in the esophagus.<sup>48</sup>

Given the virus has a tropism on the intestinal cells, the case of inflammatory bowel diseases (IBD) is particularly striking as ACE2 and TMPRSS2 were shown to be expressed more intensely in intestinal tissues of these patients specifically in Chron's disease.<sup>49</sup> The findings might imply an increased propensity of these patients for SARS-CoV-2 infection. In contrast, the serum concentrations

of soluble form of ACE2 are elevated in these patients due to proteolytic cleavage mediated by a protease (ADAM17).<sup>50</sup> This might display a competitive inhibitory role against the attachment of SARS-CoV-2 to its target receptor. In summary, there is no convincing high-quality data supporting an increased risk of SARS-CoV-2 infection or severe COVID-19 among patients with IBD. The schematic presentation of pathogenesis of COVID-19 associated GI manifestations is provided in Figure 1.

## DISCUSSION

Although clinical importance of the GI manifestations for COVID-19 patients is currently debated, the GI involvement of COVID-19 appears to be crucial not only for its clinical consequences but also for its impacts on public health and prevention. Considering widespread expression of ACE2 and TMPRSS2 in the GI tract and



**Fig. 1:** Proposed pathophysiological mechanisms of gastrointestinal symptoms in patients with coronavirus disease-2019 (COVID-19). Far left part demonstrates the viral entry to host cells via binding of its spike protein with ACE2 receptor in the presence of TMPRSS2. Viral invasion and ensuing direct viral cytotoxicity result in malabsorption, stimulation of both intestinal secretion and enteric nervous system. The middle part depicts consequences of accumulation of Ang II and the decrease of Ang 1–7 due to dysregulation of RAAS system. Ang II promotes proinflammatory cytokine release and tissue inflammation by binding to AT1R. The rightmost part shows the blockage of tryptophan uptake and inhibition of BOAT1/ACE2 transport pathway that is mediated by attaching of SARS-CoV-2 to ACE2 receptor. This blockage affects the activation of mTOR to mitigate the antimicrobial peptide synthesis. Disturbance in antimicrobial peptide expression leads to gut microbiota dysbiosis, and the changed intestinal flora promotes the polarization of Th17 cells. The bottom part schematizes the recruitment of CCR9 + CD4 + T cells into the small intestine that is promoted by CCL25. SARS-CoV-2, severe acute respiratory syndrome coronavirus 2; ACE, angiotensin-converting enzyme; TMPRSS2, transmembrane protease serine protease 2; Ang II, angiotensin II; Ang 1–7, angiotensin 1–7; AT1R, angiotensin type 1 receptor; AT2R, angiotensin type 2 receptor; RAAS, renin-angiotensin-aldosterone system; mTOR, mammalian target of rapamycin; CCL25, chemokine (C–C motif) ligand 25

isolation of viral RNA in stools of the patients, the fecal–oral transmission seems to be plausible. In the literature, some studies have explored the mechanisms of the GI involvement in COVID-19 and they reported various mechanisms leading to local and systemic inflammatory responses, including alterations to B0AT1/ACE2 complex, disruption of tryptophan transport system and antimicrobial peptide synthesis, effects of gut–lung axis, and GI tract microbiome dysbiosis. Nevertheless, the pathophysiological mechanisms connecting GI manifestations to SARS-CoV-2 infections remain unclear.

## CONCLUSION

During the pandemic, it has been observed that the patients might present or develop various GI symptoms during the course of COVID-19. However, detailed understanding of pathogenesis of the GI symptoms remains imperative. Future studies are warranted to appreciate the mechanisms of the GI system involvement, which will be pivotal to develop novel therapeutic methods against GI injury in COVID-19.

## ORCID

Abdullah Tarik Aslan  <https://orcid.org/0000-0001-9804-0972>

Halis Şimşek  <https://orcid.org/0000-0002-9306-557X>

## REFERENCES

- Guan WJ, Ni ZY, Hu Y, et al. Clinical characteristics of coronavirus disease 2019 in China. *N Engl J Med* 2020;382:1708–1720. DOI: 10.1056/NEJMoa2002032.
- World Health Organization. Naming the coronavirus disease (COVID-19) and the virus that causes it. Technical guidance. 2020. Available from: [https://www.who.int/emergencies/diseases/novel-coronavirus-2019/technical-guidance/naming-the-coronavirus-disease-\(covid-2019\)-and-the-virus-that-causes-it](https://www.who.int/emergencies/diseases/novel-coronavirus-2019/technical-guidance/naming-the-coronavirus-disease-(covid-2019)-and-the-virus-that-causes-it).
- Perlman S, Netland J. Coronaviruses post SARS: update on replication and pathogenesis. *Nat Rev Microbiol* 2009;7(6):439–450. DOI: 10.1038/nrmicro2147.
- Wang D, Hu B, Hu C, et al. Clinical characteristics of 138 hospitalized patients with 2019 novel coronavirus-infected pneumonia in Wuhan, China. *JAMA* 2020;323(11):1061–1069. DOI: 10.1001/jama.2020.1585.
- Pan L, Mu M, Yang P, et al. Clinical characteristics of COVID-19 patients with digestive symptoms in Hubei, China: a descriptive, cross-sectional, multicenter study. *Am J Gastroenterol* 2020;115(5):766–773. DOI: 10.14309/ajg.0000000000000620.
- Walls AC, Park YJ, Tortorici MA, et al. Structure, function, and antigenicity of the SARS-CoV-2 spike glycoprotein. *Cell* 2020;183(6):1735. DOI: 10.1016/j.cell.2020.11.032.
- Raj VS, Mou H, Smits SL, et al. Dipeptidyl peptidase 4 is a functional receptor for the emerging human coronavirus- EMC. *Nature* 2013;495(7440):251–254. DOI: 10.1038/nature12005.
- Li F. Structure, function, and evolution of coronavirus spike proteins. *Annu Rev Virol* 2016;3(1):237–261. DOI: 10.1146/annurev-virology-110615-042301.
- Wrapp D, Wang N, Corbett KS, et al. Cryo-EM structure of the 2019-nCoV spike in the prefusion conformation. *Science* 2020;367(6483):1260–1263. DOI: 10.1126/science.abb2507.
- Hoffmann M, Kleine-Weber H, Schroeder S, et al. SARS-CoV-2 cell entry depends on ACE2 and TMPRSS2 and is blocked by a clinically proven protease inhibitor. *Cell* 2020;181(2):271–280. DOI: 10.1016/j.cell.2020.02.052.
- Qi F, Qian S, Zhang S, et al. Single cell RNA sequencing of 13 human tissues identify cell types and receptors of human coronaviruses. *Biochem Biophys Res Commun* 2020;526(1):135–140. DOI: 10.1016/j.bbrc.2020.03.044.
- Holshue ML, DeBolt C, Lindquist S, et al. First case of 2019 novel coronavirus in the United States. *N Engl J Med* 2020;382(10):929–936. DOI: 10.1056/NEJMoa2001191.
- Lin L, Jiang X, Zhang Z, et al. Gastrointestinal symptoms of 95 cases with SARS-CoV-2 infection. *Gut* 2020;69(6):997–1001. DOI: 10.1136/gutjnl-2020-321013.
- Chen T, Wu D, Chen H, et al. Clinical characteristics of 113 deceased patients with coronavirus disease 2019: retrospective study. *BMJ* 2020;368:m1091. DOI: 10.1136/bmj.m1091.
- Jin X, Lian JS, Hu JH, et al. Epidemiological, clinical and virological characteristics of 74 cases of coronavirus-infected disease 2019 (COVID-19) with gastrointestinal symptoms. *Gut* 2020;69(6):1002–1009. DOI: 10.1136/gutjnl-2020-320926.
- Zhang JJ, Dong X, Cao YY, et al. Clinical characteristics of 140 patients infected with SARS-CoV-2 in Wuhan, China. *Allergy* 2020;75(7):1730–1741. DOI: 10.1111/all.14238.
- Chen N, Zhou M, Dong X, et al. Epidemiological and clinical characteristics of 99 cases of 2019 novel coronavirus pneumonia in Wuhan, China: a descriptive study. *Lancet* 2020;395(10223):507–513. DOI: 10.1016/S0140-6736(20)30211-7.
- Sultan S, Altayar O, Siddique SM, et al. AGA Institute rapid review of the gastrointestinal and liver manifestations of COVID-19, meta-analysis of international data, and recommendations for the consultative management of patients with COVID-19. *Gastroenterology* 2020;159(1):320–334. DOI: 10.1053/j.gastro.2020.05.001.
- Liang W, Feng Z, Rao S, et al. Diarrhoea may be underestimated: a missing link in 2019 novel coronavirus. *Gut* 2020;69(6):1141–1143. DOI: 10.1136/gutjnl-2020-320832.
- Cheung KS, Hung IFN, Chan PPY, et al. Gastrointestinal manifestations of SARS-CoV-2 infection and virus load in fecal samples from a Hong Kong cohort: systematic review and meta-analysis. *Gastroenterology* 2020;159(1):81–95. DOI: 10.1053/j.gastro.2020.03.065.
- Mao R, Qiu Y, He JS, et al. Manifestations and prognosis of gastrointestinal and liver involvement in patients with COVID-19: a systematic review and meta-analysis. *Lancet Gastroenterol Hepatol* 2020;5(7):667–678. DOI: 10.1016/S2468-1253(20)30126-6.
- Luo S, Zhang X, Xu H. Don't overlook digestive symptoms in patients with 2019 novel coronavirus disease (COVID-19). *Clin Gastroenterol Hepatol* 2020;18(7):1636e7. DOI: 10.1016/j.cgh.2020.03.043.
- Zhang C, Shi L, Wang FS. Liver injury in COVID-19: management and challenges. *Lancet Gastroenterol Hepatol* 2020;5(5):428–430. DOI: 10.1016/S2468-1253(20)30057-1.
- Parasa S, Desai M, Thoguluva Chandrasekar V, et al. Prevalence of gastrointestinal symptoms and fecal viral shedding in patients with coronavirus disease 2019: a systematic review and meta-analysis. *JAMA Netw Open* 2020;3(6):e2011335. DOI: 10.1001/jamanetworkopen.2020.11335.
- Pan Y, Zhang D, Yang P, et al. Viral load of SARS-CoV-2 in clinical samples. *Lancet Infect Dis* 2020;20(4):411–412. DOI: 10.1016/S1473-3099(20)30113-4.
- Ling Y, Xu SB, Lin YX, et al. Persistence and clearance of viral RNA in 2019 novel coronavirus disease rehabilitation patients. *Chin Med J (Engl)* 2020;133(9):1039–1043. DOI: 10.1097/CM9.0000000000000774.
- Xiao F, Tang M, Zheng X, et al. Evidence for gastrointestinal infection of SARS-CoV-2. *Gastroenterology* 2020;158(6):1831–1833. DOI: 10.1053/j.gastro.2020.02.055.
- Yang L, Tu L. Implications of gastrointestinal manifestations of COVID-19. *Lancet Gastroenterol Hepatol* 2020;5(7):629–630. DOI: 10.1016/S2468-1253(20)30083-2.
- Deidda S, Tora L, Firinu D, et al. Gastrointestinal Coronavirus disease 2019: epidemiology, clinical features, pathogenesis, prevention and management. *Expert Rev Gastroenterol Hepatol* 2020;15(1):41–50. DOI: 10.1080/17474124.2020.1821653.
- Norsa L, Bonaffini PA, Indriolo A, et al. Poor outcome of intestinal ischemic manifestations of COVID-19. *Gastroenterology* 2020;159(4):1595–1597. DOI: 10.1053/j.gastro.2020.06.041.

31. Keshavarz P, Rafiee F, Kavandi H, et al. Ischemic gastrointestinal complications of COVID-19: a systematic review on imaging presentation. *Clin Imaging* 2020;73:86–95. DOI: 10.1016/j.clinimag.2020.11.054.
32. McFadyen JD, Stevens H, Peter K. The emerging threat of (micro) thrombosis in COVID-19 and its therapeutic implications. *Circ Res* 2020;127(4):571–587. DOI: 10.1161/CIRCRESAHA.120.317447.
33. Liu F, Long X, Zhang B, et al. ACE2 expression in pancreas may cause pancreatic damage after SARS-CoV-2 infection. *Clin Gastroenterol Hepatol* 2020;18(9):2128–2130. DOI: 10.1016/j.cgh.2020.04.040.
34. Rawla P, Bandaru SS, Vellipuram AR. Review of infectious etiology of acute pancreatitis. *Gastroenterol Res* 2017;10(3):153–158. DOI: 10.14740/gr858w.
35. Hadi A, Werge M, Kristiansen KT, et al. Coronavirus disease-19 (COVID-19) associated with severe acute pancreatitis: case report on three family members. *Pancreatol* 2020;20(4):665–667. DOI: 10.1016/j.pan.2020.04.021.
36. Aloysius MM, Thatti A, Gupta A, et al. COVID-19 presenting as acute pancreatitis. *Pancreatol* 2020;20(5):1026–1027. DOI: 10.1016/j.pan.2020.05.003.
37. Juhász MF, Ocskay K, Kiss S, et al. Insufficient etiological workup of COVID-19 associated acute pancreatitis: a systematic review. *World J Gastroenterol* 2020;26(40):6270–6278. DOI: 10.3748/wjg.v26.i40.6270.
38. Yao XH, Li TY, He ZC, et al. A pathological report of three COVID-19 cases by minimally invasive autopsies. *Zhonghua Bing Li Xue Za Zhi* 2020;49(5):411–417. DOI: 10.3760/cma.j.cn112151-20200312-00193.
39. Ding Y, He L, Zhang Q, et al. Organ distribution of severe acute respiratory syndrome (SARS) associated coronavirus (SARS-CoV) in SARS patients: implications for pathogenesis and virus transmission pathways. *J Pathol* 2004;203(2):622–630. DOI: 10.1002/path.1560.
40. Ma C, Cong Y, Zhang H. COVID-19 and the digestive system. *Am J Gastroenterol* 2020;115(7):1003–1006. DOI: 10.14309/ajg.0000000000000691.
41. Dickson I. Organoids demonstrate gut infection by SARS-CoV-2. *Nat Rev Gastroenterol Hepatol* 2020;17:383. DOI: 10.1038/s41575-020-0317-5.
42. Vuille-Dit-Bille RN, Liechty KW, Verrey F, et al. SARS-CoV-2 receptor ACE2 gene expression in small intestine correlates with age. *Amino Acids* 2020;52(6–7):1063–1065. DOI: 10.1007/s00726-020-02870.
43. van Doremalen N, Bushmaker T, Morris DH, et al. Aerosol and surface stability of SARS-CoV-2 as compared with SARS-CoV-1. *N Engl J Med* 2020;382(16):1564–1567. DOI: 10.1056/NEJMc2004973.
44. Budden KF, Gellatly SL, Wood DL, et al. Emerging pathogenic links between microbiota and the gut-lung axis. *Nat Rev Microbiol* 2017;15(1):55–63. DOI: 10.1038/nrmicro.2016.142.
45. Wang J, Li F, Wei H, et al. Respiratory influenza virus infection induces intestinal immune injury via microbiota-mediated Th17 cell-dependent inflammation. *J Exp Med* 2014;211(12):2397–2410. DOI: 10.1084/jem.20140625.
46. Papadakis KA, Prehn J, Nelson V, et al. The role of thymus-expressed chemokine and its receptor CCR9 on lymphocytes in the regional specialization of the mucosal immune system. *J Immunol* 2000;165(9):5069–5076. DOI: 10.4049/jimmunol.165.9.5069.
47. Crowe CR, Chen K, Pociask DA, et al. Critical role of IL-17RA in immunopathology of influenza infection. *J Immunol* 2009;183(8):5301–5310. DOI: 10.4049/jimmunol.0900995.
48. Tian Y, Rong L, Nian W, et al. Review article: gastrointestinal features in COVID-19 and the possibility of faecal transmission. *Aliment Pharmacol Ther* 2020;51(9):843–851. DOI: 10.1111/apt.15731.
49. Garg M, Royce SG, Tikellis C, et al. Imbalance of the renin-angiotensin system may contribute to inflammation and fibrosis in IBD: a novel therapeutic target? *Gut* 2020;69(5):841–851. DOI: 10.1136/gutjnl-2019-318512.
50. Garg M, Burrell LM, Velkoska E, et al. Upregulation of circulating components of the alternative renin-angiotensin system in inflammatory bowel disease: a pilot study. *J Renin Angiotensin Aldosterone Syst* 2015;16(3):559–569. DOI: 10.1177/1470320314521086.