

# Finger Abscess Caused by a Black Fungus, *Exophiala xenobiotica*

Takeshi Nomura, MD\*  
Yoshio Yamawaki, MD, PhD†

**Summary:** *Exophiala xenobiotica* is a relatively new species of black fungi that can cause infection that primarily affects the skin and soft tissues in humans. Black fungal infection is challenging to diagnose and often needs surgery. However, few studies have reported black fungal and *E. xenobiotica* infections in the field of plastic surgery. Herein, we report the case of a 79-year-old man who presented with a finger abscess, later identified via rDNA sequencing as *E. xenobiotica* infection. He did not have a history of immunosuppression. We resected the lesion and performed skin grafting. No recurrence was observed, even without antifungal medications. We compared this case with six previously reported cases and examined their similarities and differences. Surgical removal emerged as the most effective treatment option. Additional reports of successfully treated *E. xenobiotica* infections are needed to establish the best treatment strategy. Plastic surgeons should improve their awareness of black fungal infections. (*Plast Reconstr Surg Glob Open* 2022;10:e4565; doi: 10.1097/GOX.0000000000004565; Published online 7 October 2022.)

*Exophiala xenobiotica* is a species of black fungi that mainly infects the skin and soft tissue in humans. Black fungal infections are relatively rare and occasionally challenging to diagnose. Moreover, unlike bacterial abscesses, they cannot be cured by drainage or antibiotics. Lack of appropriate treatment can cause life-threatening systemic infections.<sup>1</sup> However, few studies have reported black fungal infections in the field of plastic surgery. These infections mainly affect the hand or face, and surgery is a radical treatment approach. If the defect after surgery is large, reconstruction can be challenging in terms of avoiding deformity or functional disorders. Plastic surgeons can play a crucial role in treating black fungal infection and should be well aware of this disease. Herein, we report a rare case of black fungal infection treated surgically.

## CASE REPORT

A 79-year-old man was referred to our hospital with a 25×20 mm subcutaneous dorsal mass on the right hand, described as red and firm yet movable (Fig. 1). He noticed the mass a month before presenting at our hospital and

was asymptomatic. He did not have pets and had not been in contact with animals. His medical history included hypertension, osteoarthritis, and hyperuricemia, but no immunosuppression.

Magnetic resonance imaging showed a low-density area on T1-weighted image and a double cystic high-density area on T2-weighted image. Laboratory findings were as follows: RBC, 3.9×10<sup>6</sup>/μl; Hb, 12.8 g/dl; WBC, 5900/μl (neutrophils, 58.9%; lymphocytes, 26.6%; monocytes 8.7%); CD3, 58.6%; CD4, 42.4%; CD8, 15.4%; Alb, 4.3 g/dl; T-Bil, 0.6 mg/dl; AST, 36 U/l; ALT, 44 U/l; ALP, 224 U/l; γ-GTP, 37 U/l; BUN, 25.4 mg/dl; Cre, 1.27 mg/dl; CRP, 0.21 mg/dl; IgG, 1,213 mg/dl; IgA, 260 mg/dl; IgM, 88 mg/dl; and β-D-glucan, 10.2 pg/ml.

We initially suspected a bacterial abscess, especially a ganglion infection. However, culturing the aspirated content from the mass on Sabouraud dextrose agar at 30°C for 14 days confirmed the presence of black fungus. Pathological examination revealed septate hyphae (Fig. 2). The patient was diagnosed with phaeohyphomycosis, which is the infection of black fungi showing melanized septate hyphae and yeast-like cells of *E. xenobiotica* based on pathological findings and rDNA sequencing. The sequences of internal transcribed spacer (ITS) and D1/D2 regions were fully identical to those of *E. xenobiotica* strain, PW2482, from Mycobank.

The mass was resected with a 5 mm margin above the paratenon. Although the cyst was in contact with the extensor tendon, there were no adhesions. A 0.025 inch skin graft was transplanted from the lower abdomen, and the patient's finger joints were fixed using Kirschner wire. Two cavities were formed, and pathological examination

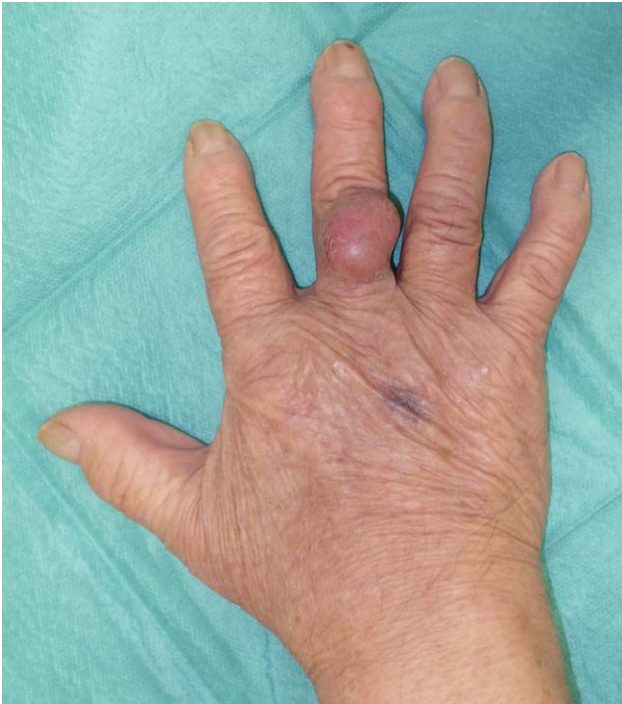From the \*Department of Plastic and Reconstructive Surgery, Osaka Saiseikai Nakatsu Hospital, Osaka, Japan; and †Department of Plastic and Reconstructive Surgery, Hyogo Prefectural Amagasaki General Medical Center, Hyogo, Japan.

Received for publication May 26, 2022; accepted August 11, 2022.

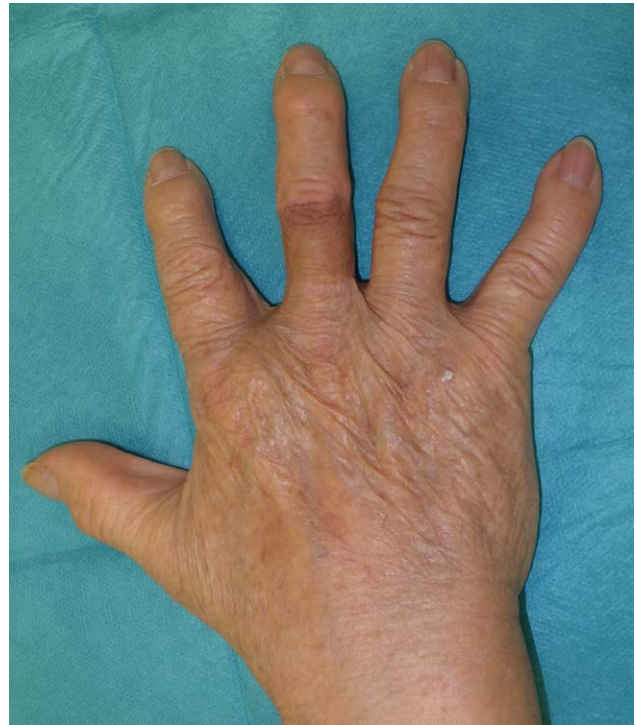
Copyright © 2022 The Authors. Published by Wolters Kluwer Health, Inc. on behalf of The American Society of Plastic Surgeons. This is an open-access article distributed under the terms of the Creative Commons Attribution-Non Commercial-No Derivatives License 4.0 (CCBY-NC-ND), where it is permissible to download and share the work provided it is properly cited. The work cannot be changed in any way or used commercially without permission from the journal.

DOI: 10.1097/GOX.0000000000004565

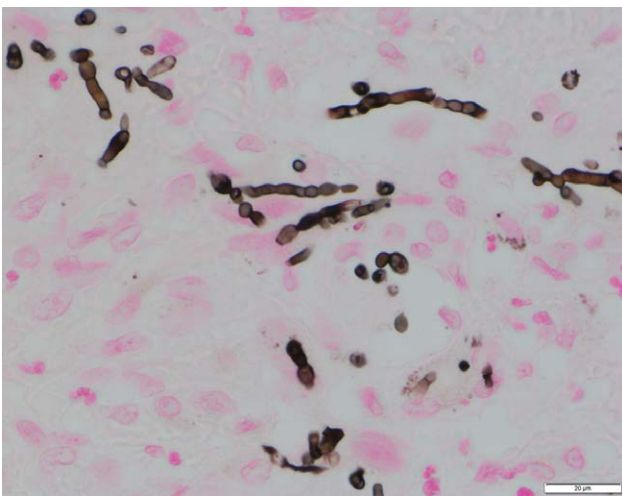
**Disclosure:** The authors have no financial interests to declare in relation to the content of this article.



**Fig. 1.** Preoperative findings of the subcutaneous right-hand dorsum mass.



**Fig. 3.** Postoperative findings: there has been no recurrence in 1 year and 4 months.



**Fig. 2.** Black hyphae are seen (Fontana-Masson).

revealed a fibrotic capsule with inflammatory cell infiltration. No recurrence was observed in 1 year and 4 months (Fig. 3), and the patient continues to demonstrate a good range of motion.

### DISCUSSION

Black fungi, comprising many genera and species, appear black owing to the melanin in their cell wall. *Exophiala* is one of the most frequent genera of black fungi and prefers moist and hot environments like bathing areas

and dishwashers.<sup>2,3</sup> Over half of the 121 case reports of *Exophiala* infection identified in the last 10 years were from Asian countries, with the highest number of cases in Japan, followed by China and India. The *Exophiala* genus has 29 species, 18 of which can cause infections.<sup>4</sup> Previously, species were identified morphologically and physiologically; however, rDNA sequencing of the ITS region can now identify causative species precisely<sup>4</sup>, allowing clinicians to assess prognosis. For example, *Exophiala dermatitidis* can cause fatal systemic infections. Hiruma et al reviewed 11 cases of *E. dermatitidis* infection that resulted in death of young patients (age: 5–30 years).<sup>1</sup> However, the same is not true for other species.<sup>2</sup> Consequently, species identification is crucial for treatment and follow-up.

In 2006, De Hoog et al used rDNA to distinguish *E. xenobiotica* as a new species from *Exophiala jeanselmei*.<sup>5</sup> *E. xenobiotica* is found in places with monoaromatic hydrocarbons and alkanes, such as soil polluted by gasoline, and on moist bathroom floors.<sup>5</sup> Our literature review showed only six reports of *E. xenobiotica* infection in humans (Table 1).<sup>3,6–10</sup> All were localized in the patients' limbs, and five out of six cases showed multiple lesions. The absence of lymph node or internal organ lesions indicates that these lesions are caused by contact infection rather than lymphatic or hematogenous infection. Most documented lesions were 10 to 30 mm in size, and the largest lesion was 80 mm. Therefore, surgery would be the preferred option for almost all lesions.

Black fungi flourish in the context of immunosuppression.<sup>4</sup> Although patients in the six cases we reviewed were

**Table 1. Case Reports of *Exophiala xenobiotica* Infections**

	Author, Year, Country	Age, Gender	Part	Maximum Size (mm)	Immunosuppression	Histological features	Treatment	Follow-up (mo)	Recurrence
1	Aoyama et al <sup>6</sup> 2009 Japan	77 F	Hand (multiple)	30	PSL, chemotherapy (non-Hodgkin- lymphoma)	Phaeohyphomycosis	Surgical removal ITCZ (3.5 mo)	2	No
2	Morio et al <sup>5</sup> 2012 France	53 M	Forearm arm knee	Not written	HIV infection	Phaeohyphomycosis	Surgical removal	6	No
3	Hasei et al <sup>7</sup> 2013 Japan	90 F	Finger hand forearm	80	PSL (polyarthritis) DM	Phaeohyphomycosis	Surgical removal (only finger) TERB (2 months) local hyperther- mia	30 (finger) 2 (other parts)	No (fin- ger), Improved (other parts) No
4	Palmisano et al <sup>8</sup> 2015 Italy	65 F	Finger forearm leg	Not written	PSL, TAC, MMF (renal transplant)	Phaeohyphomycosis	Surgical removal VRCZ (6 mo) AMPB (3 mo) PSCZ (8 mo) ITCZ (6 mo)	20	No
5	Ogawa et al <sup>9</sup> 2016 Brazil	75 M	Hands arms legs	Not written	PSL, TAC (renal transplant) DM	Not decided (features of both phaeohyphomycosis and chromoblastomycosis)	Surgical removal ITCZ (3 months)	6	Not written
6	Espanhol et al <sup>10</sup> 2020 Brazil	45 M	Leg (single)	Not written	PSL, TAC, MMF (renal transplant)	Phaeohyphomycosis	Surgical removal ITCZ (3 months)	4	No
7	This case 2022 Japan	79 M	Finger (single)	25	None	Pheophyphomycosis	Surgical removal	16	No

AMPB, amphotericin B; DM, diabetes mellitus; F, feminine; ITCZ, itraconazole; M, masculine; MMF, mycophenolate mofetil; PSCZ, posaconazole; PSL, prednisolone; TAC, tacrolimus; TERB, terbinafine; VRCZ, voriconazole.

all immunosuppressed, the patient in the present study did not appear to be immunocompromised considering his medical history and laboratory data. This suggests that *E. xenobiotica* infections occur in patients with normal immunity as well.

Black fungal infections comprise phaeohyphomycosis, chromoblastomycosis, and eumycotic mycetoma as histological manifestations. *Exophiala* usually causes phaeohyphomycosis.<sup>2</sup> Although one of the seven cases (including the present case) had features of both phaeohyphomycosis and chromoblastomycosis, the remaining were diagnosed with phaeohyphomycosis. Takenaka et al<sup>2</sup> reviewed 128 cases of phaeohyphomycosis, and surgery was performed in 59 out of 119 cases (excluding unknown cases). Of the 59 cases, 53 (89.8%) had good prognosis. Of the other 60 cases, 47 (78.3%) were treated with antifungals, hyperthermia, drainage, or combined methods, and experienced good outcomes. Thus, surgery appears to be more effective. Among the 128 reviewed cases, 92 had infected arms, 53 had infection at the back of the hand and finger, and five had facial lesions. Operations in these areas are sometimes challenging due to cosmetic and functional reasons and, thus, involve plastic surgery.

In addition to our case, five published cases of *E. xenobiotica* infection suggest surgery as the preferred treatment. Although medication was administered for 2 to 17 months in five cases, drug resistance and side effects should also be considered. We did not prescribe antifungal drugs to our patient because the lesion margin was clear, and he also had mild renal and liver dysfunction. While surgery is preferred, it does not always provide a definitive resolution. Antifungal therapy may be considered to treat systemic infection or small lesions that cannot be detected. Lastly, considering the rare incidence of *E. xenobiotica* infections

and lack of consensus on definitive therapy, more reports are needed to establish treatment strategies.

## CONCLUSIONS

Cases of *E. xenobiotica* are rare, especially in the field of plastic surgery. We report a case of a finger abscess caused by *E. xenobiotica*, a rare black fungus, for which surgery was effective. More reports should be published to increase clinicians' awareness of these infections.

Takeshi Nomura, MD

2-10-39, Shibata, Kita-ku  
Osaka-shi, Osaka 530-0012  
Japan

E-mail: 0813564m@gmail.com

## ACKNOWLEDGMENTS

The authors gratefully thank Hiroo Matsuo (Amagasaki general medical center) and Makoto Niki (Osaka city university) for identifying the fungal species, and Konomi Muro (Amagasaki general medical center) for pathological diagnosis.

## REFERENCES

- Hiruma M, Kawada A, Ohata H, et al. Systemic phaeohyphomycosis caused by *Exophiala dermatitidis*. *Mycoses*. 1993;36:1-7.
- Takenaka M, Murota H, Nishimoto K. Subcutaneous phaeohyphomycosis due to *Exophiala jeanselmei* following renal transplantation: a case report with a published work review of phaeohyphomycosis in Japan. *J Dermatol*. 2020;47:1050-1053.
- Morio F, Berre JY, Garcia-Hermoso D, et al. Phaeohyphomycosis due to *Exophiala xenobiotica* as a cause of fungal arthritis in an HIV-infected patient. *Med Mycol*. 2012;50:513-517.
- Zeng JS, Sutton DA, Fothergill AW, et al. Spectrum of clinically relevant *Exophiala* species in the United States. *J Clin Microbiol*. 2007;45:3713-3720.

5. De Hoog GS, Zeng JS, Harrak MJ, et al. *Exophiala xenobiotica* sp. nov., an opportunistic black yeast inhabiting environments rich in hydrocarbons. *Antonie Van Leeuwenhoek*. 2006;90:257–268.
6. Aoyama Y, Nomura M, Yamanaka S, et al. Subcutaneous phaeohyphomycosis caused by *Exophiala xenobiotica* in a non-Hodgkin lymphoma patient. *Med Mycol*. 2009;47:95–99.
7. Hasei M, Takeda K, Anzawa K, et al. Case of phaeohyphomycosis producing sporotrichoid lesions. *J Dermatol*. 2013;40:638–640.
8. Palmisano A, Morio F, Le Pape P, et al. Multifocal phaeohyphomycosis caused by *Exophiala xenobiotica* in a kidney transplant recipient. *Transpl Infect Dis*. 2015;17:297–302.
9. Ogawa MM, Peternelli MP, Enokihara MM, et al. Spectral manifestation of melanized fungal infections in kidney transplant recipients: report of six cases. *Mycopathologia*. 2016;181:379–385.
10. Espanhol CM, Recuero JK, Pagani DM, et al. Cutaneous phaeohyphomycosis caused by *Exophiala xenobiotica*: a case report. *Med Mycol Case Rep*. 2020;27:39–41.