




## STANDARD ARTICLE

# Abdominal ultrasound and clinicopathologic findings in 22 cats with exocrine pancreatic insufficiency

Mylène Auger<sup>1,2</sup>  | Constance Fazio<sup>2</sup>  | Joerg M. Steiner<sup>3</sup>  |  
Dominique G. Penninck<sup>4</sup> | Gwendolyn J. Levine<sup>5</sup> | John F. Griffin IV<sup>5</sup> |  
Cary M. Springer<sup>6</sup>

<sup>1</sup>Animages, Longueuil, Quebec, Canada

<sup>2</sup>Department of Small Animal Clinical Sciences, College of Veterinary Medicine, University of Tennessee, Knoxville, Tennessee, USA

<sup>3</sup>Gastrointestinal Laboratory, College of Veterinary Medicine and Biomedical Sciences, Texas A&M University, College Station, Texas, USA

<sup>4</sup>Foster Hospital for Small Animals, Department of Clinical Sciences, Cummings School of Veterinary Medicine, Tufts University, North Grafton, Massachusetts, USA

<sup>5</sup>Department of Large Animal Clinical Sciences, College of Veterinary Medicine & Biomedical Sciences, Texas A&M University, College Station, Texas, USA

<sup>6</sup>Research Computing Support, University of Tennessee, Knoxville, Tennessee, USA

## Correspondence

Constance Fazio, Department of Small Animal Clinical Sciences, College of Veterinary Medicine, University of Tennessee, Knoxville, TN, USA.

Email: cfazio@utk.edu

## Abstract

**Background:** Awareness of exocrine pancreatic insufficiency (EPI) in cats has increased since the development of an assay for feline trypsin-like immunoreactivity (fTLI). Ultrasound findings in cats with EPI have only been reported rarely and described as nonspecific.

**Hypothesis/Objectives:** To describe the ultrasonographic findings, clinical signs, and concurrent diseases in cats with EPI.

**Animals:** Twenty-two client-owned cats with EPI.

**Methods:** Multicenter retrospective descriptive study including cats with serum fTLI concentration  $\leq 8$   $\mu\text{g/L}$  and an abdominal ultrasound examination performed within 6 weeks of fTLI measurement. Sonographic measurements of maximal pancreatic thickness and maximal pancreatic duct diameter as well as ratios of pancreatic duct diameter to pancreatic thickness were obtained. Additional sonographic findings, concurrent conditions, and clinical signs were recorded.

**Results:** The most common clinical sign was weight loss (15/22 cats). Chronic enteropathy was the most common concurrent disease (13/22 cats). In 39% of cats, the pancreas had minimal or no sonographic alterations. Pancreatic duct dilatation ( $>2.5$  mm), pancreatic duct tortuosity with variable diameter, or both were seen in 6/13 cats. The pancreatic parenchyma was subjectively thin in 6 cats. A significant relationship was found between subjectively thin pancreatic parenchyma and increased pancreatic duct size : pancreatic thickness ratio ( $P = .004$ ). Diffuse gastrointestinal dilatation with echogenic content was observed in 8/22 cats.

**Conclusion:** Exocrine pancreatic insufficiency often causes minimal to no sonographic pancreatic changes. Nonetheless, the findings of thin pancreatic parenchyma, pancreatic duct dilatation, or diffuse small intestinal dilatation with echogenic contents in cats with unexplained weight loss or unformed feces should raise clinical suspicion for EPI.

## KEYWORDS

diarrhea, EPI, feline, fTLI, pancreatic duct, pancreatitis, weight loss

**Abbreviations:** EPI, exocrine pancreatic insufficiency; fPLI, feline pancreatic lipase immunoreactivity; fTLI, feline trypsin-like immunoreactivity; IBD, inflammatory bowel disease.

This is an open access article under the terms of the Creative Commons Attribution-NonCommercial-NoDerivs License, which permits use and distribution in any medium, provided the original work is properly cited, the use is non-commercial and no modifications or adaptations are made.

© 2021 The Authors. *Journal of Veterinary Internal Medicine* published by Wiley Periodicals LLC on behalf of American College of Veterinary Internal Medicine.

## 1 | INTRODUCTION

Exocrine pancreatic insufficiency (EPI) is caused by insufficient production of pancreatic digestive enzymes by acinar cells, leading to nutrient malassimilation.<sup>1,2</sup> Although historically considered rare in cats, the diagnosis of EPI in cats has increased since the development of the feline trypsin-like immunoreactivity (fTLI) assay, where serum concentrations  $\leq 8$   $\mu\text{g/L}$  are considered diagnostic for EPI.<sup>1,2</sup> This disease has been reported to affect cats of a wide age range, from 3 months to 19 years in a recent case series of 150 affected cats.<sup>2</sup> Previous studies have suggested that EPI is likely a consequence of chronic pancreatitis in most cases.<sup>2,3</sup> Other, far less common, causes for EPI in cats include pancreatic acinar atrophy, pancreatic hypoplasia or aplasia, and *Eurytrema procyonis* infestation.<sup>2</sup> The most common clinical sign of EPI in cats has been reported to be weight loss, present in  $>90\%$  of the cats in 1 study.<sup>2</sup> In addition, diarrhea was seen in 62% of cats in that study, which is lower than that reported in dogs with EPI, where diarrhea was seen in up to 95% of affected dogs.<sup>2,4</sup> Other reported clinical signs in cats with EPI include polyphagia and greasy soiling of the perineal hair. Lethargy, anorexia, and vomiting also have been reported, possibly associated with concurrent disease processes that have been reported to occur in up to 58% of cats with EPI.<sup>1,2</sup> Abdominal radiographic and ultrasonographic imaging findings have been described as nonspecific in cats with EPI, but findings pertaining to concomitant diseases have been reported.<sup>1</sup> One report described nonhomogeneous pancreatic parenchyma and pancreatic nodules in 2 cats with EPI.<sup>1,5</sup> Another report described a normal pancreas in some cats, but pancreatic hyperechogenicity in another.<sup>6</sup> The purpose of our retrospective study was to describe the ultrasound findings, clinical signs, and concurrent diseases in cats diagnosed with EPI. Our hypothesis was that the sonographic appearance of the pancreas would be normal in most cats, but some ultrasound features such as small pancreatic size, dilatation and tortuosity of the pancreatic duct, and diffuse dilatation of the gastrointestinal tract (small intestine with or without gastric dilatation) with echogenic contents may be seen in some cats with EPI. Furthermore, we hypothesized that most cats would have concomitant diseases such as diabetes mellitus, inflammatory bowel disease (IBD), or chronic pancreatitis, and that the most common clinical signs would be similar to those previously reported, with weight loss being the most common.

## 2 | MATERIALS AND METHODS

The database of the Gastrointestinal Laboratory at the College of Veterinary Medicine and Biomedical Sciences at Texas A&M University (TAMU) was searched from January 2008 to April 2020 for cats with a diagnosis of EPI based on a serum fTLI concentration  $\leq 8$   $\mu\text{g/L}$ , the current recommended cutoff for diagnosing EPI in cats.<sup>1,2,7</sup> Medical records at the University of Tennessee College of Veterinary Medicine (UTCVM), Tufts University Cummings school of Veterinary Medicine (TUCSVM), Veterinary Specialty Center of Seattle (VSC), and DMV Veterinary Center (DMV) also were searched for cats with

serum fTLI concentration  $\leq 8$   $\mu\text{g/L}$  during the same time period. Of these, cats with an ultrasound study of the abdomen performed within 6 weeks of the fTLI result  $\leq 8$   $\mu\text{g/L}$  were included.

Two board-certified veterinary radiologists retrieved the following information from the medical records: age, sex, breed, presenting complaint, concurrent conditions, results of tissue sampling, and results of serum concentrations of fTLI, cobalamin, folate, feline pancreatic lipase immunoreactivity (fPLI), and total bilirubin, as well as any available results at re-evaluations. The reference interval used for statistical analysis for fPLI was 0.1 to 3.5  $\mu\text{g/L}$ ; for cobalamin, 290 to 1500 ng/L; and for folate, 9.7 to 21.6  $\mu\text{g/L}$ . The results of each were categorized as decreased, normal, or increased for statistical analysis. The reference interval for total bilirubin concentration was 0 to 0.6 mg/dL.

Ultrasound images were acquired using multiple ultrasound machines and transducers. The UTCVM patients were scanned using a Philips Epiq 5 machine with a 12 to 18 MHz high-frequency linear transducer. The TAMU patients were scanned using a Siemens Antares machine with a 13.5 MHz high-frequency linear transducer (5/6) and a Siemens Acuson S2000 machine with a 5.5 to 18 MHz high-frequency linear transducer (1/6). The DMV patients were scanned with an Esaote MyLab Twice machine using a 6-10 MHz microconvex transducer. The VSC patients were scanned using a Sonoscape S9 machine with a 4-13 MHz microconvex transducer (1/2) and a GE Logic S8 machine with a 4-12 MHz microconvex transducer and a 3-11 MHz high-frequency linear transducer (1/2). The TUCSVM patients were scanned using a Phillips Epic 7G and a Phillips iU22 with curvilinear 8-5 MHz and linear 12-5 or 18-5 MHz transducers.

Ultrasound images and cine-loops were evaluated by 3 board-certified radiologists. The following information was recorded when images of the pancreas were available: pancreatic echogenicity compared to liver, pancreatic echotexture (categorized as normal/homogeneous or mildly, moderately, or markedly heterogeneous), and presence of pancreatic nodules or cysts; subjectively thinned or nearly absent pancreatic parenchyma; pancreatic duct dilatation (defined as pancreatic duct diameter size  $>2.5$  mm)<sup>5,8</sup>; pancreatic duct tortuosity with variable diameter; debris or calculi within the pancreatic duct; and hyperechogenicity of peripancreatic fat. Maximum thickness of the pancreatic parenchyma was obtained for the left limb, body, and right limb (when visible) by obtaining the measurement at the thickest visible portion of each section. Maximum pancreatic duct diameter measurements were obtained by measuring its widest diameter within the pancreatic left limb, body, and right limb, when visible. The measurement of the maximum overall pancreatic duct diameter was the largest of all obtained pancreatic duct measurements. The ratio of pancreatic duct size to overall pancreatic thickness was calculated for the left limb, body, and right limb, when possible, using measurements of maximum pancreatic parenchymal thickness and maximum pancreatic duct diameter for each pancreatic section.

Additional recorded information for the hepatobiliary system included subjective liver size and echogenicity, hepatic focal lesions, cholelithiasis or choledocholithiasis or both, common bile duct dilatation ( $>4$  mm) or tortuosity, subjective dilatation of intrahepatic bile

ducts, gallbladder wall thickening (defined as wall thickness >1 mm), and gallbladder sludge.

Additional recorded information for the gastrointestinal tract included wall layer alteration, including subjective thickening of the muscularis, measurements of gastrointestinal wall thickness, presence of diffuse dilatation of the gastrointestinal tract with echogenic contents without mechanical ileus, a small intestinal fine linear hyper-echoic mucosal band, small intestinal corrugation, and subjective gastrointestinal hyperperistalsis (when cineloops were available for review). Normal reference values used for mean gastrointestinal wall thickness were 2 to 4 mm for stomach, 2.2 mm for duodenum, 2.2 mm for jejunum, 2.8 mm for ileum, and 1.5 mm for colon.<sup>9</sup>

Recorded information for each visible abdominal lymph node included size, echogenicity, and margination. Splenic findings included measurement of size, with splenomegaly defined as splenic thickness > 10 mm,<sup>9</sup> evaluation of echogenicity and echotexture, and presence or absence of focal lesions. Recorded urinary tract findings included presence of degenerative renal changes, pyelectasia, and urinary bladder debris. Finally, if peritoneal effusion was present, it was subjectively graded as scant, mild, moderate, or marked.

## 2.1 | Statistical analyses

Statistical analyses were performed by a statistician (C.M. Springer) and all analyses were conducted using a commercially available statistical software package (IBM SPSS Statistics for Windows, version 26, IBM Corp., Armonk, New York). Categorical data were described using frequencies and proportions. Quantitative data were described using median, mean, range, and SD. Ratios between maximal pancreatic duct size and maximal pancreatic thickness were performed for the left limb, body, and right limb of the pancreas. A Mann-Whitney *U* test was used to evaluate for a relationship between pancreatic duct size : pancreatic thickness ratios and subjectively thinned or absent pancreatic parenchyma for the left pancreatic limb. Pearson correlation was used to determine if an association was present between maximum pancreatic duct diameter and age. Spearman's rho correlation was used to evaluate for an association between pancreatic size and serum fTLI concentrations, and between pancreatic duct size and serum TLI concentrations. Significance for all statistical analyses was set at  $P < .05$ .

## 3 | RESULTS

Twenty-two cats were included. Breeds included were domestic shorthair (10), domestic longhair (4), Maine Coon (3), domestic medium hair (1), Korat (1), Norwegian Forest (1), Siamese (1), and Sphinx (1). Ages ranged between 8 months and 19 years, with a mean of  $7.8 \pm 5.2$  years. Seventeen (77%) were male castrated, and 5 (23%) were female spayed.

Serum fTLI concentrations ranged from 0.1 to 7.2  $\mu\text{g/L}$  with a mean of  $3.1 \pm 2.6$   $\mu\text{g/L}$ . The fTLI concentration was re-evaluated in 1 cat, a 5-year-old Maine Coon with an initial fTLI concentration of 2.9  $\mu\text{g/L}$ , which was 0.6  $\mu\text{g/L}$  at re-evaluation 15 months later. Serum

fPLI concentration was normal in 12/14 (86%) and increased in 2/14 cats (14%). For cats with normal fPLI concentrations, fPLI concentrations varied between 0.4 and 1.7  $\mu\text{g/L}$ . For cats with increased fPLI concentrations, fPLI concentrations were 6.3  $\mu\text{g/L}$  and 17.4  $\mu\text{g/L}$ , respectively. Serum folate concentrations were decreased in 2/17 (12%), normal in 12/17 (70%), and increased in 3/17 (18%) cats. Serum cobalamin concentrations were decreased in 10/17 (59%), normal in 3/17 (18%), and increased in 4/17 (23%) cats.

Total bilirubin concentration was increased in 2/22 (9%) cats. Both cats were diagnosed with hepatic lipidosis, the first using a combination of ultrasound findings and cytology of ultrasound-guided fine needle liver aspirates, and the second, presumptively, using a combination of clinical, laboratory, and ultrasound findings. In the first cat, total bilirubin concentration was 0.9 mg/dL, which returned to normal (0.4 mg/dL) 1 month later. In the second cat, total bilirubin concentration was 4.3 mg/dL. Neither cat had evidence of extrahepatic biliary obstruction on ultrasound examination.

The most common clinical sign was weight loss, noted in 15/22 cats (68%). In 12/15 cats (80%) with weight loss, information pertaining to appetite was available, and appetite was normal or increased in 8/12 (67%). Furthermore, in 2/22 cats (9%), weight loss was the only clinical sign. Hyporexia or anorexia was noted in 10/18 (56%), vomiting in 8/22 (36%), diarrhea in 7/22 (32%), lethargy or weakness in 6/22 (27%), polyphagia in 4/18 (22%), and abdominal discomfort in 2/22 (9%) cats.

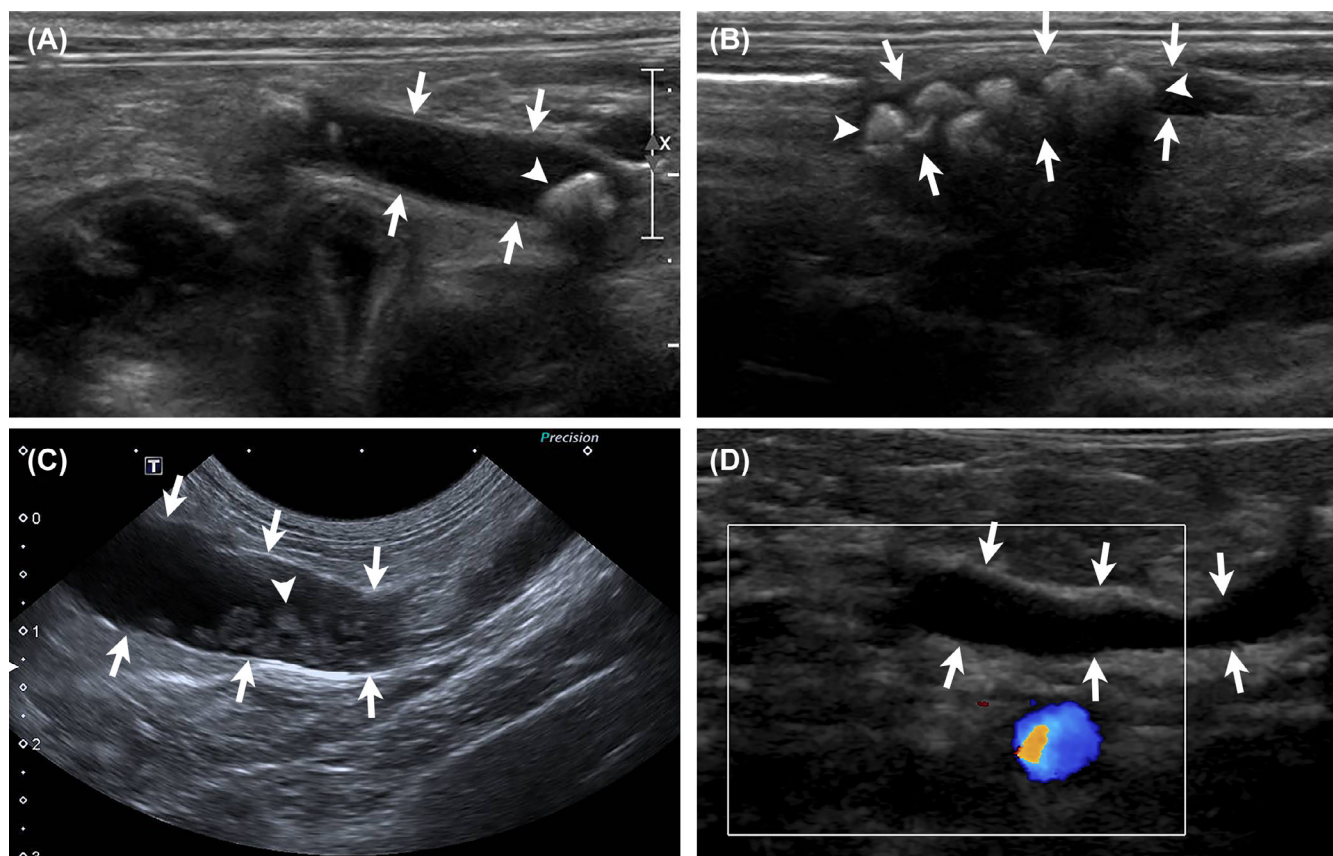
Concurrent conditions were diagnosed in 18/22 cats (82%) and 6/18 (33%) were diagnosed with >1 condition. A chronic enteropathy, such as IBD, was diagnosed in 13/22 cats (59%) based on ultrasound findings, gastrointestinal biopsy results, or both. Pancreatitis, based on current or previously increased serum fPLI concentration or cytology results from ultrasound-guided fine needle aspiration, was diagnosed in 4/22 (18%), diabetes mellitus in 3/22 (14%), chronic kidney disease in 2/22 (9%), cardiomyopathy in 1/22 (5%), asthma in 2/22 (9%), and hepatic lipidosis in 2/22 (9%) cats. Additionally, 1 cat was diagnosed with disseminated histoplasmosis, 1 cat had acute gastritis with ulceration, and 1 cat was diagnosed with eosinophilic gastritis and infection with a helicobacter-like organism.

## 3.1 | Ultrasound examination

The majority of cats (19/22) had measurement of serum fTLI concentration performed concurrently with abdominal ultrasound examination. In 2/22 cats, EPI was diagnosed 2 weeks before ultrasound examination. In 1/22 cats, EPI was diagnosed 4 weeks before ultrasound examination.

## 3.2 | Ultrasound findings—Pancreas

Of the 22 included cats, 18 had images of the pancreas and 13/18 of the pancreatic duct available for review. Ultrasonographic findings included pancreatic duct dilatation, pancreatic duct tortuosity with variable diameter, or both in 6/13 (46%) and debris or calculi within



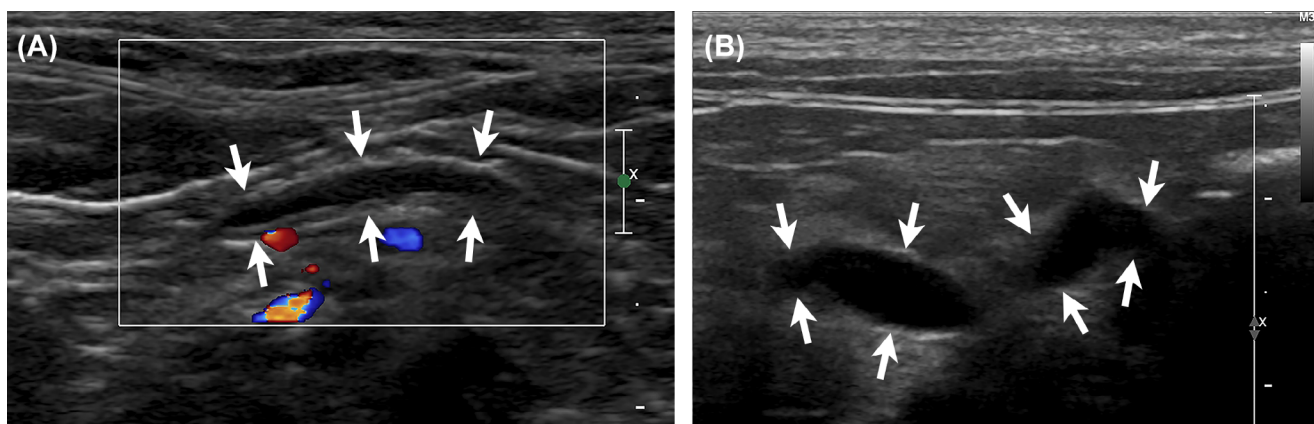
**FIGURE 1** Ultrasound images of the left (A) and right (B) pancreatic limbs in a 12-year-old male castrated domestic shorthair cat with EPI. There is diffuse dilatation of the pancreatic duct (between white arrows), with numerous shadowing intraluminal calculi (white arrowheads). (C) Ultrasound image of the right pancreatic limb in a 16-year-old male castrated domestic shorthair cat with EPI. There is marked, slightly irregular, dilatation of the pancreatic duct (between white arrows), with a moderate amount of gravity-dependent, echogenic intraluminal debris (white arrowhead). (D) Ultrasound image of the left pancreatic limb in a 4-year-old male castrated Maine Coon with EPI. There is irregular dilatation and slight tortuosity of the pancreatic duct (between white arrows). EPI, exocrine pancreatic insufficiency

the pancreatic duct in 3/13 (23%; Figure 1). The pancreas was isoechoic in 14/18 (78%), hypoechoic in 2/18 (11%), and hyperechoic to liver in 2/18 (11%) cats. Pancreatic echotexture was mildly heterogeneous in 12/18 (67%), moderately heterogeneous in 2/18 (11%), and homogeneous in 4/18 (22%) cats. In 3/18 cats (17%), the pancreas had an overall subjectively normal ultrasound appearance, with normal size and echogenicity, homogeneous parenchyma, and without pancreatic duct abnormalities. In an additional 4/18 (22%) cats, mild pancreatic heterogeneity was the only abnormality noted. A few small ( $\leq 4$  mm), ill-defined hypoechoic pancreatic nodules were seen in 1 cat. A small anechoic pancreatic cyst was seen in 1 cat. The pancreatic parenchyma was subjectively thin to nearly absent in 6/18 (33%) cats (Figure 2). Hyperechoic and hyperattenuating peripancreatic fat was seen in only 1 cat diagnosed with acute pancreatitis on cytological analysis, with normal peripancreatic fat in the remaining 17/18 (94%) cats.

Table 1 illustrates thickness measurements for each section of the pancreas for 18 cats as well as previously reported mean measurements in healthy cats.<sup>5,8,10,11</sup> Table 2 illustrates pancreatic duct measurements for the left limb, body, and right limb of the pancreas.

The mean ratios of pancreatic duct size : pancreatic thickness were 0.39 ( $n = 12$ ) for the left limb, 0.27 ( $n = 5$ ) for the body, and 0.69 ( $n = 5$ ) for the right limb, whereas median ratios were 0.25 for the left limb, 0.14 for the body, and 0.62 for the right limb.

Results of a Mann-Whitney *U* test indicated a significant relationship between subjectively absent or thin pancreatic parenchyma and the ratio of pancreatic duct size : pancreatic thickness for the left limb ( $P = .004$ ). When a subjectively absent or thinned parenchyma was noted, the median ratio was 0.67. When the pancreatic parenchyma was not subjectively absent or thinned, the median ratio was 0.18. A positive correlation ( $r = 0.538$ ) was found between cat age and pancreatic duct size, but it did not reach statistical significance ( $P = .14$ ). A significant negative correlation was found between pancreatic duct size and serum fTLI concentration for the left limb ( $\rho = -0.597$ ,  $P = .04$ ); as fTLI decreased, duct size increased. A significant correlation was found between pancreatic body size and serum fTLI concentration; as serum fTLI decreased, pancreatic body size also decreased ( $\rho = 0.829$ ,  $P = .04$ ). No significant correlation was identified between serum fTLI concentration and left limb ( $P = .37$ ) or right limb ( $P = .88$ ) pancreatic size.



**FIGURE 2** Subjectively thinned to nearly absent pancreatic parenchyma in cats with EPI. (A) Ultrasound image of the left pancreatic limb (between white arrows) with color Doppler interrogation in a 4-year-old female spayed Norwegian Forest cat. The pancreas is small, measuring a maximum of 2.9 mm in thickness and the pancreatic duct is mildly diffusely dilated, with markedly thinned to almost absent surrounding pancreatic parenchyma. (B) Ultrasound image of the left pancreatic limb (between white arrows) in a 4-year-old male castrated Maine Coon. There is irregular dilatation and mild tortuosity of the pancreatic duct with subjectively markedly thinned to almost absent surrounding pancreatic parenchyma. EPI, exocrine pancreatic insufficiency

**TABLE 1** Pancreatic thickness in cats with EPI and reported mean measurements in healthy cats<sup>5,8,10,11</sup>

	Mean (mm)	Median (mm)	SD (mm)	Range (mm)		Etue et al, 2001 (mm)	Larson et al, 2005 (mm)	Hecht et al, 2006 (mm)	Diana et al, 2015 (mm)
Left limb (n = 18 cats)	5.9	6.5	1.7	2.9-8.1	Left limb	5.4	5.4	6.5	5.5
Body (n = 6 cats)	7.0	7.7	1.5	4.9-8.3	Body	6.6	5.6	6.4	
Right limb (n = 7 cats)	5.3	5.2	1.4	2.7-6.7	Right limb	4.5		4.3	

Abbreviation: EPI, exocrine pancreatic insufficiency.

	Mean (mm)	Median (mm)	SD (mm)	Range (mm)
Left limb (n = 12 cats)	2.4	1.4	2.3	0.5-8.2
Body (n = 6 cats)	2.9	1.3	3.0	0.8-8.2
Right limb (n = 5 cats)	4.3	4.1	4.1	0.8-11.0

Abbreviation: EPI, exocrine pancreatic insufficiency.

**TABLE 2** Pancreatic duct diameter measurements in cats with EPI

### 3.3 | Ultrasound findings—Hepatobiliary

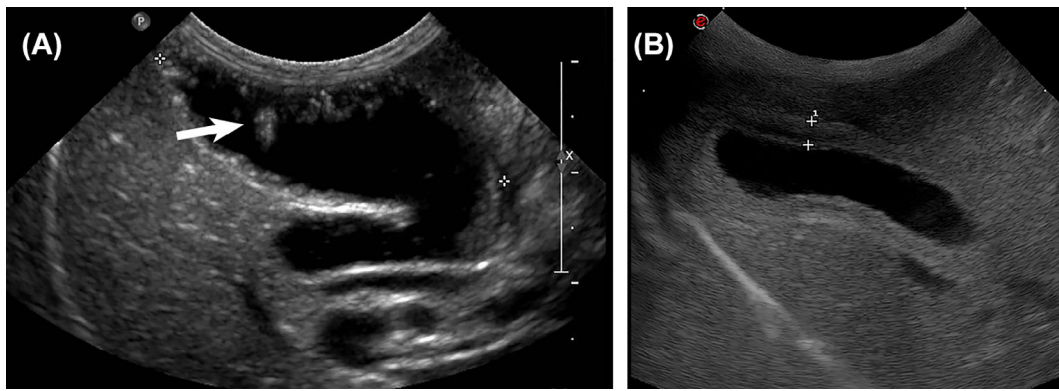
Hepatomegaly subjectively was seen in 4/22 cats (18%), whereas in 18/22 (82%), liver size was normal. The liver was hyperechoic in 3/22 (14%), hypoechoic in 3/22 (14%), and of normal echogenicity in 16/22 (73%) cats. In 1/22 cats (1 of the cats diagnosed with hepatic lipidosis), the liver was hyperechoic and hyperattenuating. Focal hepatic lesions were seen in 3/22 (14%) cats. Gallbladder sludge was noted in 12/19 cats (63%), cholelithiasis in 2/19 (11%), calculi in the intrahepatic bile ducts in 1/10, and gallbladder wall thickening in 3/19 (16%; Figure 3). The common bile duct was dilated in 1/12 cats. The common bile duct, cystic duct, or both was tortuous in 2/11 cats (18%). No cats had intrahepatic bile duct dilatation.

### 3.4 | Ultrasound findings—Spleen

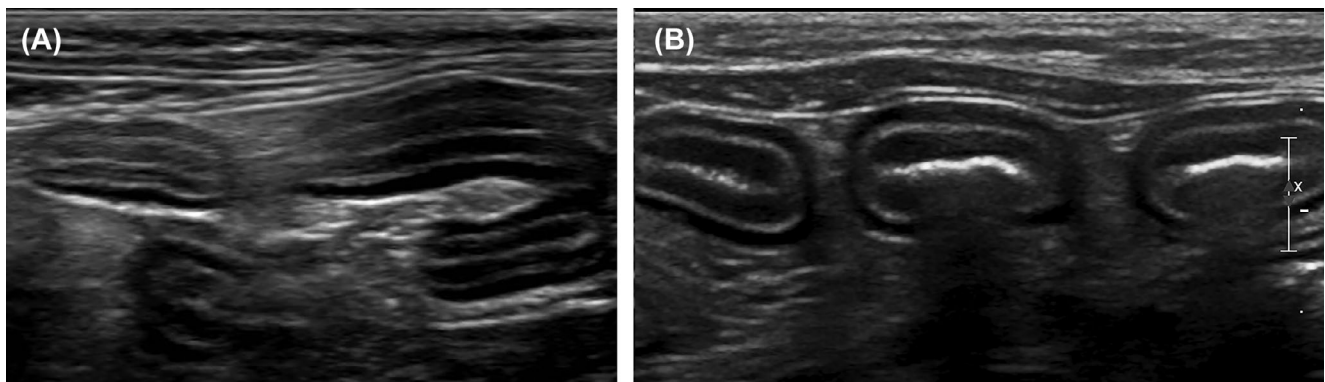
Splenomegaly was present in 7/22 (32%) cats. A mottled echotexture was seen in 4/22 (18%) cats. Splenic nodules were present in 1/22.

### 3.5 | Ultrasound findings—Gastrointestinal

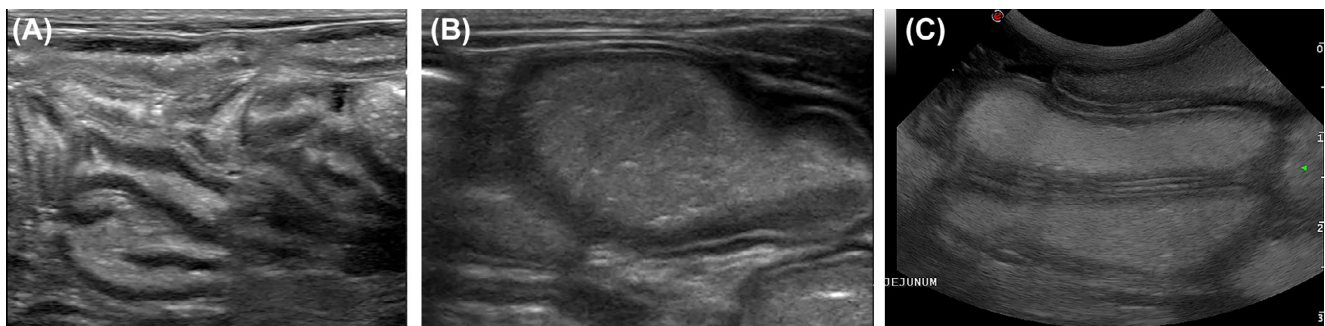
Thickening of the gastric wall was noted in 1 of 22 cats. Wall thickening was observed in at least 1 intestinal segment in 21/22 cats (95%). Duodenal, jejunal, and ileal wall thickening was seen in 18/20 (90%), 18/21 (86%), and 6/12 (50%) cats, respectively. Colonic wall thickening was seen in 1/18 cats. Altered wall layering, notably thickening of



**FIGURE 3** (A) Gallbladder wall thickening and a small amount of biliary sludge, some of which is gravity-dependent and some of which is adherent to the ventral gallbladder wall (white arrow), in a 14-year-old male castrated Maine Coon. (B) Gallbladder wall thickening (between cursors) in a 14-year-old male castrated domestic longhair cat. This patient was suspected to have cholecystitis



**FIGURE 4** (A) Jejunal wall thickening, measuring up to 3.9 mm, and mainly associated with muscularis thickening in a 13-year-old female spayed Korat. Eosinophilic enteritis was diagnosed by histopathologic analysis of small intestinal surgical biopsies. (B) Mild jejunal wall thickening, measuring up to 2.9 mm in thickness and mainly associated with muscularis thickening in a 4-year-old female spayed Norwegian Forest cat



**FIGURE 5** Diffuse dilatation of the small bowel with echogenic contents in cats with EPI. (A) Eight-month-old male castrated Siamese cat, (B) 12-year-old male castrated domestic shorthair cat, and (C) 14-year-old male castrated domestic shorthair cat. EPI, exocrine pancreatic insufficiency

the muscularis layer of the small intestine, was observed in 11/22 cats (50%; Figure 4). A fine, linear hyperechoic band in the intestinal mucosa, parallel to the submucosa, suggestive of mucosal fibrosis, was noted in 9/22 (41%) cats. No cats had loss of gastrointestinal wall layering.

Diffuse dilatation of the gastrointestinal tract with echogenic contents was observed in 8/22 cats (36%) with hyperperistalsis in 3/22 (14%; Figure 5). No cause of mechanical ileus was identified. Small intestinal corrugation was present in 3/22 (14%) cats. Mean  $\pm$  SD jejunal lymph node size was  $5.8 \pm 3.2$  mm.

**TABLE 3** Clinical signs in cats with EPI<sup>2,6,7</sup>

	Auger et al, 2021	Xenoulis et al, 2016	Thompson et al, 2009	Steiner and Williams, 2000
Weight loss	15/22 (68%)	137/150 (91%)	15/16 (94%)	19/20 (95%)
Weight loss with normal to increased appetite	9/12 (67%)			
Weight loss, increased appetite, unformed feces	5/12 (42%)	48/149 (32%)		
Weight loss as only clinical sign	2/22 (9%)	8/150 (5.3%)	3/16 (19%)	
Hyporexia/anorexia	10/18 (56%)	68/150 (45%)	4/16 (25%)	Present in some
Vomiting	8/22 (36%)	29/150 (19%)	5/16 (31%)	Present in some
Diarrhea or loose stool	7/22 (32%)	93/149 (62%)	12/16 (75%)	10/20 (50%)
Lethargy/weakness	6/22 (27%)	60/149 (40%)	4/16 (25%)	Present in some
Polyphagia	4/18 (22%)	63/150 (42%)	5/16 (31%)	8/20 (40%)
Abdominal discomfort	2/22 (9%)			

Abbreviation: EPI, exocrine pancreatic insufficiency.

### 3.6 | Ultrasound findings—Urogenital

Chronic degenerative renal changes were seen in 8/22 cats (36%). Hyper-echogenicity of the renal cortices was seen in 11/22 (50%), cortical cysts in 2/22 (9%), chronic renal infarcts in 2/22 (9%), and pyelectasia in 1/22 cats. Urinary bladder debris in suspension was present in 14/22 cats (64%) and gravity-dependent debris was observed in 2/22 (9%).

### 3.7 | Ultrasound findings—Peritoneal cavity

Peritoneal effusion was observed in 8/22 cats (36%), and was subjectively categorized as scant in 3/8 (38%), mild in 3/8 (38%), and moderate in 2/8 (25%).

## 4 | DISCUSSION

### 4.1 | Clinical signs

The most common clinical signs previously reported in cats with EPI were weight loss, unformed feces, poor hair coat, and polyphagia, with weight loss most commonly reported.<sup>2</sup> These findings are similar to what was seen in cats of our study, with weight loss being most common, seen in 68% of cats, and the only clinical sign in 9% of cats. Furthermore, in 75% of cats with weight loss, appetite was reported to be normal or increased. Similarly, in a previous study of cats with EPI, weight loss was the only reported clinical sign in 5% of cats.<sup>2</sup> Diarrhea or unformed feces also was common, seen in 32% of cats in our study. Other than weight loss and diarrhea, the most common clinical signs in cats of our study included hyporexia or anorexia,

vomiting, and lethargy or weakness, possibly a reflection of concurrent diseases. Table 3 lists the common clinical signs observed in our study, compared with previous studies. Additionally, male cats were overrepresented in our study population, representing 77% of cats with EPI. This finding is similar to 2 previous reports, in which 63% and 59%, respectively, of affected cats were males.<sup>2,6</sup> Additional studies are required to determine if a sex predilection exists for EPI in cats.

### 4.2 | Concurrent diseases

Concurrent diseases were identified in 18/22 cats (82%), higher than previously reported (58%).<sup>2</sup> This finding may in part, represent selection bias, given that all cats were required to have an abdominal ultrasound examination for inclusion. This requirement may have led to identification of more concurrent diseases than previously reported, where cats were included based on an fTLI concentration  $\leq 8$   $\mu\text{g/L}$  without required additional evaluation.<sup>2</sup> The most common concurrent disease in cats diagnosed with EPI was chronic enteropathy, present in 59% of cats.

As in humans, EPI in cats has been reported to be a sequela to chronic pancreatitis.<sup>2,3</sup> In the present study, evidence of pancreatitis was only identified in 4/22 cats (18%). Similarly, a previous report identified evidence of pancreatitis in only 11% of 150 cats with EPI.<sup>2</sup> This finding may be because active pancreatic inflammation is no longer present in many cats presented for EPI, but also may reflect the difficulty in diagnosing mild chronic pancreatitis in cats, although there may occasionally be other causes of EPI. With chronic pancreatitis, destruction of pancreatic tissue may not be limited to acinar cells, and diabetes mellitus also has been reported to commonly occur in

these patients.<sup>2</sup> In our study, 3/22 cats (14%) were diagnosed with diabetes mellitus, and 1 of the 3 had evidence of concurrent pancreatitis. In the other 2 cats, measurement of serum fPLI was not performed, and underlying pancreatitis may have been missed or may no longer have been active at the time of evaluation. Nevertheless, in 1 of these cats, the pancreatic duct was dilated with variable diameter, and contained debris and calculi, a feature previously described in cats with chronic pancreatitis.<sup>12</sup> In cats with chronic pancreatitis or diabetes mellitus or both that have unexplained weight loss, the possibility of EPI should be considered and serum fTLI concentration should be measured.

Serum cobalamin and folate concentrations were available in 17/22 cats. Hypocobalaminemia is commonly identified in cats with EPI, reported in 77% of cats in a previous study.<sup>2</sup> In our study, hypocobalaminemia was identified in only 59% of cats, lower than described in previous reports. However, in 2/4 patients with increased serum cobalamin concentrations at the time of imaging, vitamin B12 injections had been administered before testing, and concentrations before the injection were unknown. Given that these patients had received vitamin B12 injections, hypocobalaminemia may have been more prevalent in our study population than our data reflected. In most cats (70%), serum folate concentrations were normal, whereas they were increased in 18% and decreased in 12% of cats. This finding is similar to a previous report, where serum folate concentrations were less commonly abnormal than were serum cobalamin concentrations, and when they were abnormal, they more commonly were increased than decreased.<sup>2</sup>

Interestingly, 1 cat was diagnosed with disseminated histoplasmosis. This cat, a 5-year-old female spayed domestic shorthair, presented for evaluation of hyporexia and weight loss, with uveitis, glaucoma, and retinal detachment. On ultrasound examination, this cat had mild pancreatic hypoechogenicity with mildly heterogeneous echotexture without pancreatic duct dilatation. Additional ultrasound findings included an enlarged hypochoic liver, an enlarged mottled spleen, diffuse small intestinal muscularis thickening and mild corrugation, and moderate peritoneal effusion. In this cat, EPI was presumed to be secondary to fungal destruction of the pancreas. The cat was treated with antifungal drugs and pancreatic enzyme supplementation, which were eventually discontinued once the cat improved clinically. Serum fTLI concentration, however, was not re-evaluated after resolution of histoplasmosis, and it is unknown if pancreatic acinar function returned to normal. To our knowledge, this case is the first reported example of EPI in a cat with systemic histoplasmosis, but a clear causal relationship was not established. Whether histoplasmosis led to acinar cell destruction or, less likely, pancreatic duct obstruction with secondary pancreatic atrophy is unknown.

Additional concurrent diseases included chronic kidney disease, asthma, cardiomyopathy, and hepatic lipidosis, but any direct association with EPI is currently undetermined.

### 4.3 | Ultrasound examination findings

Images of the pancreas were available for review in the majority (82%) of cats in our study. In 39% of cats with available images, the pancreas

had very minimal or no alterations, with normal appearance in 17% and mild pancreatic heterogeneity as the only abnormality in an additional 22% of cats. Nonetheless, pancreatic heterogeneity was common, varying from mild to moderate, and was seen in most (79%) cats. In most cats, pancreatic echogenicity was normal, but pancreatic hyperechogenicity, as previously described with EPI, was noted in a small number of cats. Pancreatic hypoechogenicity, more commonly associated with acute pancreatitis, also was seen in a small number (11%) of cats.

Previously described pancreatic ultrasonographic findings in cats with EPI include pancreatic hyperechogenicity, nonhomogeneity, and nodules, all nonspecific findings, although a normal pancreatic appearance also has been described.<sup>1,5,6</sup> Given that EPI is most commonly reported to be a consequence of chronic pancreatitis in cats, it can be presumed that, in some cases, ultrasound findings may be suggestive of pancreatitis.<sup>2</sup> Previously reported ultrasound findings in cats with chronic pancreatitis included decreased or increased pancreatic size, pancreatic hyperechogenicity or mixed echogenicity, irregular pancreatic margins, pancreatic nodules or cysts, mineralization, irregular widening of the pancreatic ducts, and pancreaticolithiasis, although an ultrasonographically normal pancreas does not exclude pancreatic disease.<sup>12-14,16</sup> In fact, the sensitivity of ultrasound examination for the diagnosis of pancreatitis in cats has been reported to range between 11% and 67%.<sup>12</sup> Furthermore, pancreatic duct dilatation also has been reported as a normal aging change in cats.<sup>5</sup> In that study, mean pancreatic duct size in healthy older cats (mean age,  $13 \pm 3$  years) was 1.3 mm, ranging between 0.06 and 2.4 mm, with a significant association between increased pancreatic duct width and age.<sup>5</sup> Nevertheless, a recent study using computed tomography to evaluate the pancreatic duct in healthy cats and in cats with pancreatitis found that pancreatic duct diameter was significantly larger in cats with increased fPLI concentration than in healthy cats.<sup>15</sup> Pancreatic duct dilatation (>2.5 mm), or pancreatic duct tortuosity with variable diameter, or both were seen in 6/13 (46%) cats in our study, with mean pancreatic duct diameter measurements of 2.4 mm, 2.9 mm, and 4.3 mm for the left limb, body, and right limb, respectively, and with measurements up to 11 mm, higher than previously reported normal values, even in older cats. Additionally, despite a high correlation coefficient, a significant correlation between age and pancreatic duct size was not identified in our study; however, this result may have been because of our small sample size and lack of statistical power. The most commonly observed pancreatic ultrasound abnormalities in cats of our study were nonhomogeneity, pancreatic duct dilatation, or pancreatic duct tortuosity with variable diameter (or both). These changes may reflect EPI, chronic pancreatitis, or both, but may also, to some extent, represent a normal aging change.

Markedly thin to nearly absent pancreatic parenchyma was noted in 6/18 cats (33%) with a significant relationship between this finding and the ratio of pancreatic duct size to pancreatic thickness. An increased ratio, indicative of the pancreatic duct occupying a larger proportion of overall pancreatic size, was associated with subjective assessment of decreased to nearly absent pancreatic parenchyma, further supporting our impression. Additionally, a significant negative association was found between pancreatic duct size and serum fTLI concentration for the left pancreatic limb, where as serum fTLI



concentration decreased, duct size increased, suggesting that as the pancreatic duct increases in size, there is less functional pancreatic tissue. Although a decrease in pancreatic parenchymal thickness may be indicative of chronic pancreatitis, in young cats this finding also may be the result of pancreatic atrophy or hypoplasia.<sup>6</sup> The finding of subjectively thin or absent pancreatic parenchyma could warrant further testing for EPI, particularly in cats with unexplained weight loss or unformed feces.

Measurements of pancreatic thickness were similar to previously reported mean measurements, which likely, at least in part, can be explained by the normal sonographic appearance of the pancreas in many of the cats. However, in some cases (5/13; 38%), pancreatic duct dilatation associated with subjectively decreased pancreatic parenchymal thickness likely caused the overall pancreatic thickness to be normal, but with a higher proportion of the pancreatic width occupied by the pancreatic duct. This hypothesis is further supported by the significant association between the subjectively thin or nearly absent pancreatic parenchyma and an increased ratio of pancreatic duct to pancreatic thickness.

Small intestinal wall thickening was very common in our study, most commonly affecting the duodenum (18/20; 90%) and jejunum (18/21; 86%). In 52% of cats, the normal ratio of wall layers was altered, notably thickening of the small intestinal muscularis layer. This finding is indicative of small intestinal disease, such as IBD or infiltrative neoplasia such as small cell lymphoma.<sup>17,18</sup> Inflammatory bowel disease is commonly associated with pancreatitis and cholangitis in cats, and the high frequency of intestinal wall thickening in our study may reflect an increased prevalence of pancreatic disease in our population.<sup>19</sup> In fact, “triaditis,” the term used to describe concurrent inflammation of the pancreas, liver, and small intestine, has been reported in 50% to 56% of cats with pancreatitis, and is thought to be, at least in part, associated with the Y-shaped junction of the common bile duct and main pancreatic duct in this species.<sup>19,20</sup>

Cats with cholangitis or cholangiohepatitis may have a sonographically normal liver, but hepatic hypoechogenicity, hyperechogenicity, or heterogeneity are also possible, as well as biliary abnormalities, such as biliary sludge, gallbladder wall thickening, and cholelithiasis.<sup>9</sup> Gallbladder sludge was seen in 63% of the cats of our study, and although this finding may be incidental in some cats, it also may reflect underlying inflammatory disease. Gallbladder wall thickening was seen in 3/19 cats (16%), suggestive of cholecystitis or cholangitis in these cats. In 2 of 3 cats with gallbladder wall thickening, cholelithiasis, choledocholithiasis, or both also was present. In 1 cat, the common bile duct was mildly dilated (approximately 5 mm), as was the pancreatic duct (up to 5 mm), which contained echogenic debris and calculi. This cat also had mineral foci within the intrahepatic bile ducts, which were not dilated. Although common bile duct dilatation  $\geq 5$  mm has been reported in association with extrahepatic biliary obstruction in cats, this cat did not have increased serum total bilirubin concentration, was not icteric, and did not have intrahepatic bile duct dilatation, and therefore extrahepatic biliary obstruction was not suspected.<sup>21</sup> The echogenic debris and calculi within the pancreatic duct and within the nondilated intrahepatic bile

ducts, however, may have been secondary to chronic inflammation, either pancreatic, biliary, or both, which could have contributed to ductal dilatation in this cat. This conclusion is supported by a recent study that evaluated the association between biliary morphology and pancreatic enzyme activity in the bile of healthy cats.<sup>20</sup> This study found that a dilated cystic duct was associated with reflux of pancreatic juice in the bile, which could possibly eventually damage the bile duct epithelium and lead to cholangitis.<sup>20</sup> However, additional studies are needed to determine the clinical relevance of this finding.<sup>20</sup>

Finally, in 36% of cats, diffuse dilatation of the gastrointestinal tract with echogenic contents was observed, and evidence of hyperperistalsis was found in some cats. This finding has been previously described in cats with EPI, possibly secondary to intestinal malabsorption associated with EPI, leading to an often markedly increased fecal volume.<sup>9</sup> When diffuse dilatation of the gastrointestinal tract with echogenic contents is seen in cats with weight loss, unformed feces, or both, and without evidence of an obstructive cause, EPI should be considered.

#### 4.4 | Limitations

Our study had some limitations. The first limitation was its retrospective design. Ultrasound image acquisition was performed by several different ultrasonographers at various timepoints using different ultrasound equipment, which likely affected subjective image evaluation, such as for echogenicity and echotexture. In addition, not all ultrasound studies included images of the pancreas, and when pancreatic images were available, the entire pancreas or pancreatic duct were not always imaged. Possible causes include small pancreatic size, or the pancreas may have been obscured by the gastrointestinal tract. Statistical analysis therefore could not be performed on all pancreatic measurements because of low numbers for some. The low numbers also may have resulted in failure of our study to detect differences between groups (ie, type II statistical error). Histopathology was not available for any of the included cats, and thus the underlying etiology for EPI in our patients is unknown. Additionally, although the majority of cats had imaging and testing for EPI performed concurrently, in 3 cats, the ultrasound examination was performed 2 to 4 weeks after the EPI diagnosis. It is possible that clinical signs or concurrent diseases may have changed in that time. Finally, clinical data and follow-up information were incomplete for some patients.

#### 5 | CONCLUSION

Clinical signs in cats with EPI can be much more subtle than in dogs, with weight loss being the most commonly reported. In cats, EPI is most often the consequence of chronic pancreatitis, and can be seen in cats of all ages, often with minimal to no sonographic changes suggestive of pancreatic disease. Nonetheless, some findings were fairly common in cats of our study, and in cats with unexplained weight loss or unformed feces, the findings of subjectively thin or absent

pancreatic parenchyma, pancreatic duct dilatation with or without tortuosity with variable diameter, or diffuse dilatation of the gastrointestinal tract with echogenic contents should increase clinical suspicion for EPI, and measurement of serum fTLI concentration should be considered. Furthermore, in cats diagnosed with chronic pancreatitis or diabetes mellitus with chronic weight loss or diarrhea, EPI should be considered.

#### ACKNOWLEDGMENT

No funding was received for this study.

#### CONFLICT OF INTEREST DECLARATION

Authors declare no conflict of interest.

#### OFF-LABEL ANTIMICROBIAL DECLARATION

Authors declare no off-label use of antimicrobials.

#### INSTITUTIONAL ANIMAL CARE AND USE COMMITTEE (IACUC) OR OTHER APPROVAL DECLARATION

Authors declare no IACUC or other approval was needed.

#### HUMAN ETHICS APPROVAL DECLARATION

Authors declare human ethics approval was not needed for this study.

#### ORCID

Mylène Auger  <https://orcid.org/0000-0002-5915-7710>

Constance Fazio  <https://orcid.org/0000-0002-2296-763X>

Joerg M. Steiner  <https://orcid.org/0000-0003-3336-2086>

#### REFERENCES

- Steiner JM. Exocrine pancreatic insufficiency in the cat. *Top Companion Anim Med.* 2012;27:113-116.
- Xenoulis PG, Zoran DL, Fosgate GT, et al. Feline exocrine pancreatic insufficiency: a retrospective study of 150 cases. *J Vet Intern Med.* 2016;30:1790-1797.
- Xenoulis PG, Suchodolski JS, Steiner JM. Chronic pancreatitis in dogs and cats. *Compend Contin Educ Vet.* 2008;30:166.
- Batchelor DJ, Noble PJ, Taylor RH, et al. Prognostic factors in canine exocrine pancreatic insufficiency: prolonged survival is likely if clinical remission is achieved. *J Vet Intern Med.* 2007;21:54-60.
- Hecht S, Penninck D, Mahony O, et al. Relationship of pancreatic duct dilation to age and clinical findings in cats. *Vet Radiol Ultrasound.* 2006;47:287-294.
- Thompson KA, Parnell NK, Hohenhaus AE, et al. Feline exocrine pancreatic insufficiency: 16 cases (1992-2007). *J Feline Med Surg.* 2009;11:935-940.
- Steiner JM, Williams DA. Serum feline trypsin-like immunoreactivity in cats with exocrine pancreatic insufficiency. *J Vet Intern Med.* 2000;14:627-629.
- Larson MM, Panciera DL, Ward DL, et al. Age-related changes in the ultrasound appearance of the normal feline pancreas. *Vet Radiol Ultrasound.* 2005;46:238-242.
- Penninck D, d'Anjou M-A. Chapter 9: pancreas. *Atlas of Small Animal Ultrasonography.* 2nd ed. Hoboken, NJ: Wiley; 2015:309-330.
- Etue SM, Penninck DG, Labato MA, et al. Ultrasonography of the normal feline pancreas and associated anatomic landmarks: a prospective study of 20 cats. *Vet Radiol Ultrasound.* 2001;42:330-336.
- Diana A, Linta N, Cipone M, et al. Contrast-enhanced ultrasonography of the pancreas in healthy cats. *BMC Vet Res.* 2015;11:64-64.
- Hecht S, Henry G. Sonographic evaluation of the normal and abnormal pancreas. *Clin Tech Small Anim Pract.* 2007;22:115-121.
- Saunders HM, VanWinkle TJ, Drobatz K, et al. Ultrasonographic findings in cats with clinical, gross pathologic, and histologic evidence of acute pancreatic necrosis: 20 cases (1994-2001). *J Am Vet Med Assoc.* 2002;221:1724-1730.
- Forman MA, Steiner JM, Armstrong PJ, et al. ACVIM consensus statement on pancreatitis in cats. *J Vet Intern Med.* 2021;35:703-723. <https://doi.org/10.1111/jvim.16053>
- Park JY, Bugbee A, Sharma A, et al. Feline pancreatic ducts are consistently identified on CT and more likely to be dilated in the body of pancreas in cats with elevated feline pancreatic lipase immunoreactivity. *Vet Radiol Ultrasound.* 2020;61:255-260.
- Williams JM, Panciera DL, Larson MM, et al. Ultrasonographic findings of the pancreas in cats with elevated serum pancreatic lipase immunoreactivity. *J Vet Intern Med.* 2013;27:913-918.
- Daniaux LA, Laurenson MP, Marks SL, et al. Ultrasonographic thickening of the muscularis propria in feline small intestinal small cell T-cell lymphoma and inflammatory bowel disease. *J Feline Med Surg.* 2014;16:89-98.
- Tucker S, Penninck DG, Keating JH, et al. Clinicopathological and ultrasonographic features of cats with eosinophilic enteritis. *J Feline Med Surg.* 2014;16:950-956.
- Simpson KW. Pancreatitis and triaditis in cats: causes and treatment. *J Small Anim Pract.* 2015;56:40-49.
- Fujimoto S, Torisu S, Kaneko Y, et al. Pancreatic enzyme activity in the bile of healthy cats and its association with biliary morphology. *J Vet Intern Med.* 2021. 35(4):1780-1788. <https://doi.org/10.1111/jvim.16196>
- Gaillot HA, Penninck DG, Webster CR, et al. Ultrasonographic features of extrahepatic biliary obstruction in 30 cats. *Vet Radiol Ultrasound.* 2007;48:439-447.

**How to cite this article:** Auger M, Fazio C, Steiner JM, et al. Abdominal ultrasound and clinicopathologic findings in 22 cats with exocrine pancreatic insufficiency. *J Vet Intern Med.* 2021; 35(6):2652-2661. doi:10.1111/jvim.16267