

Underwater endoscopic mucosal resection for gastric neoplasms



Authors

Shunsuke Yamamoto¹, Yoji Takeuchi^{2,3}, Noriya Uedo², Yushi Kawakami², Naoko Hayata¹, Eiji Mita¹

Institutions

- 1 Department of Gastroenterology and Hepatology, National Hospital Organization Osaka National Hospital, Osaka, Japan
- 2 Department of Gastrointestinal Oncology, Osaka International Cancer Institute, Osaka, Japan
- 3 Department of Genetic Oncology, Division of Hereditary Tumors, Osaka International Cancer Institute, Osaka, Japan

submitted 8.2.2022

accepted after revision 12.5.2022

Bibliography

Endosc Int Open 2022; 10: E1155–E1158

DOI 10.1055/a-1854-3373

ISSN 2364-3722

© 2022. The Author(s).

This is an open access article published by Thieme under the terms of the Creative Commons Attribution-NonDerivative-NonCommercial License, permitting copying and reproduction so long as the original work is given appropriate credit. Contents may not be used for commercial purposes, or adapted, remixed, transformed or built upon. (<https://creativecommons.org/licenses/by-nc-nd/4.0/>)

Georg Thieme Verlag KG, Rüdigerstraße 14,
70469 Stuttgart, Germany

Corresponding author

Shunsuke Yamamoto, MD, PhD, 2-1-14 Houenzaka, Chuo-ku,
Osaka 540-0006, Japan

Fax: +46313421000

shun0515suke@gmail.com

Underwater endoscopic mucosal resection (UEMR) is widely used to treat colonic lesions. However, reports of its application for gastric lesions are scarce. This study aimed to evaluate the efficacy and safety of UEMR for gastric lesions (G-UEMR). In this retrospective study, patients with definite or suspicious gastric neoplasms who underwent G-UEMR between January 2014 and June 2021 were identified in the databases of two tertiary hospitals. Procedure time, R0 resection rate, (AE) rates were assessed. The 32 lesions (32 patients) included 15 adenocarcinomas, seven adenomas, five hyperplastic polyps, and two submucosal lesions. Of them, three were non-neoplastic mucosa despite suspicion of neoplasm on prior endoscopy. The median lesion size was 10 mm (range 2–50 mm). The median procedure time was 4 minutes (range 1–20 minutes). R0 resections were achieved in all (n=15 [100%]) early gastric cancer patients. There were no immediate AEs except one case of aspiration pneumonia. G-UEMR appears to be a safe, easy, and effective method for removing small gastric lesions.

Introduction

Endoscopic mucosal resection (EMR) and endoscopic submucosal dissection (ESD) are widely performed to remove gastric neoplasms, including early gastric cancer (EGC). In countries in which gastric ESD has been established, it is performed as

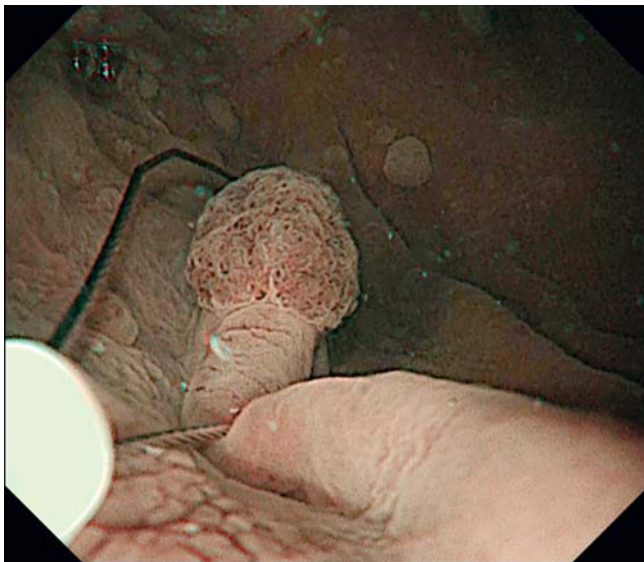
standard practice because it has greater ability to achieve R0 resection (resection without lesion involvement on lateral and vertical margins) compared to EMR. Nevertheless, ESD is time-consuming, costly, and requires proficiency. For small lesions, such as those <20 mm, ESD may not always be necessary, and as the European Society of Gastrointestinal Endoscopy (ESGE) guidelines recommend, “EMR is an acceptable option for lesions smaller than 10 to 15 mm with a very low probability of advanced histology (Paris 0-IIa)” [1].

Underwater EMR (UEMR), first developed by Binmoeller et al, has become a new standard of endoscopic resection for colorectal polyps. For colorectal polyps, UEMR achieves higher en bloc and R0 resection rates than conventional EMR [2]. At present, only a few studies have reported the use of UEMR for gastric neoplasms [3–6]. Here we evaluate the efficacy and safety of gastric UEMR (G-UEMR).

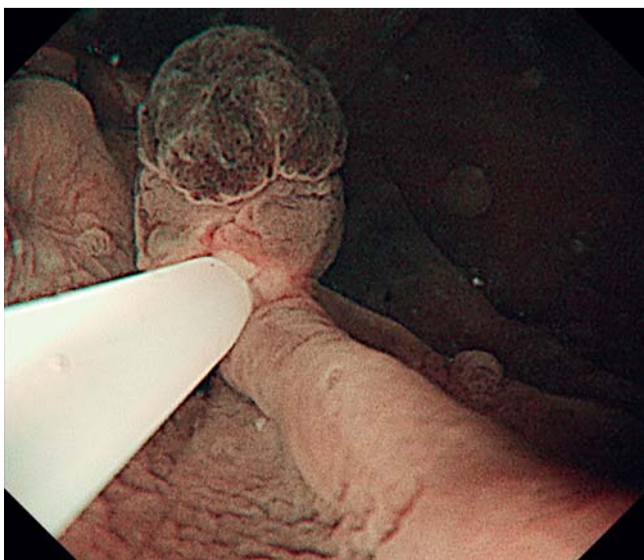
Patients and methods

Patients

Between January 2014 and July 2021, patients who had confirmed or suspected gastric neoplasms were treated with G-UEMR in two tertiary hospitals (Osaka National Hospital and Osaka International Cancer Institute). For indications, all cases were discussed at the pretreatment conference, considering le-



► **Fig. 1** Polypectomy snares (10 to 33 mm) were used depending on lesion size.



► **Fig. 2** The lesion and a sufficient surrounding margin were captured with the snare.

sion morphology, size, and location as well as patient background. In principle, protruding lesions <20 mm and located at the greater curvature were indicated for UEMR, which facilitates achieving R0 resection for such lesions. In addition, UEMR is considered preferable for patients at high risk of complications, such as old age or severe comorbidity. All patients were followed up after discharge. Written informed consent for endoscopic treatment was obtained preoperatively from all patients. This study was reviewed and approved by each institutional review board. Informed consent for participation to this study was obtained in the form of an opt-out on the website.

Gastric underwater endoscopic mucosal resection

Before resection, each lesion was evaluated using magnifying narrow band imaging and was diagnosed as cancerous or non-cancerous based on a vessel plus surface classification system. Briefly, a well-delineated lesion with irregular microvascular or microsurface is diagnosed as cancerous. If both the microvasculature and the microsurface are regular, the lesion is diagnosed as non-cancerous. In case of indistinct delineation, markings were made using snare tip coagulation just outside the lesion margin. Therapeutic gastroscopes (H290T and Q260J [Olympus]) were mainly used. Also, other types of endoscopes (H290Z, 2T240 and 2TQ260M [Olympus]) were used in some cases. Biopsy was taken after endoscopic evaluation. Resection was indicated for lesions about which there was a strong suspicion of neoplasia even though biopsy revealed no definite result. Indications for resection of hyperplastic polyps were tumor growth, suspicion of cancer, and resolution of anemia despite a pretreatment diagnosis as non-cancerous. An over tube was not used routinely. First, the gastric lumen was deflated and irrigation with normal saline was done using the endoscope's water jet function. A 10- to 33-mm polypectomy snare (Olympus) was used depending on lesion size. The lesion was captured with a snare along with a sufficient margin and cut using a VIO 300D (ERBE, Tübingen, Germany) set to Endo Cut Q mode (effect 3) combined with Forced Coag mode (effect 2) at the physician's discretion (► **Fig. 1**, ► **Fig. 2**). After resection, the stump was inspected, and clips or coagulation were used in cases of a bleeding point.

Outcome measures

Procedure time, R0 resection rate, and adverse events (AEs) were assessed using medical record review. The procedure time was defined as the time from introduction of irrigating water to the end of resection.

Results

Thirty-two patients were included in the analysis. Their clinical outcomes are shown in ► **Table 1** and ► **Table 2**. Median patient age was 73.5 years (range, 36–88 years). The median diameter of the lesions was 10 mm (range, 2–50 mm). Overall, 56% of lesions (18/32) were located at the greater curvature. Biopsy was taken after endoscopic evaluation in 94% of the patients included (30/32). Biopsy revealed that 11 cases were suspicious for or definitively diagnosed as adenocarcinoma. In seven lesions with an endoscopic pre-diagnosis as hyperplastic polyps, biopsy was performed and showed that in six cases, that diagnosis was correct. One of two cases diagnosed as Group 1 with biopsy was diagnosed submucosal gastric heterotopia and the another was adenocarcinoma after resection. The morphology of the 50-mm lesion was Paris 0-Isp. It was diagnosed as a hyperplastic polyp with both endoscopy and histology of the biopsy. It was indicated for endoscopic resection as possibly cancerous, given its size. G-UEMR was indicated because the lesion was shaped like a cylinder and its base was narrow although its size was huge. One case was a submucosal tumor

► **Table 1** Preoperative patients and lesion information.

Patients, N		32
Age, years (median)		73.5
Sex, n (%)	▪ Male	15 (47)
	▪ Female	17 (53)
Median size, mm (range)		10 (2–50)
Location	▪ U	11
	▪ M	16
	▪ L	5
Circumferential location	▪ Greater curvature	18
	▪ Lesser curvature	2
	▪ Anterior wall	6
	▪ Posterior wall	6
Pretreatment diagnosis	▪ EGC	17
	▪ Adenoma	6
	▪ Lymphoma	1
	▪ Hyperplastic polyp	7
	▪ SMT	1

L, lower; M, middle; U, upper; EGC, early gastric cancer; SMT, submucosal tumor.

with a diameter of 15 mm. Gastric heterotopia was strongly suspected at the pretreatment endoscopic examination. We could not obtain the submucosal tissue despite biopsy, so we performed G-UEMR to confirm the diagnosis. It was pathologically gastric heterotopia. Twenty-two lesions were neoplastic, including adenoma and adenocarcinoma, five were hyperplastic polyps, and one was a submucosal heterotopic gland. Three patients did not have pathological lesions despite pretreatment suspicion of neoplasia on endoscopy. Three cases were proven to be no tumor after resection. The R0 resection rate for the other 29 cases was 72.4% (21/29). All adenocarcinomas were removed en bloc without endoscopic evidence of tumor residue. There were no technical difficulties. Neither post-procedural hemorrhage nor perforation occurred. Aspiration pneumonia occurred in one patient the evening after the procedure. The median procedure time was 4 minutes (range 1–20 minutes). Histologic examination of the lesions revealed tubular adenocarcinoma in 15, for which R0 resection was performed for 100% (15/15). Of the seven adenomas, three (42.9%) were pathologically R1 on the lateral margin. Follow-up endoscopy (median, 243; range 50–2233 days) showed no residue or recurrence of the tumor in any of the cases.

Discussion

This is the first case series study that investigated the feasibility of underwater EMR in the stomach. EMR has been the choice for endoscopic resection of small gastric neoplasms because in the

► **Table 2** Intraoperative and postoperative information.

Patients, N		32
Pathological diagnosis	▪ Adenocarcinoma	15
	▪ Adenoma	7
	▪ Hyperplastic polyp	5
	▪ IFP	1
	▪ Submucosal heterotopia	1
	▪ No pathological lesion	3
Median procedure time, min (range)		4 (1–20)
Antithrombotic therapy-positive, n (%)		9 (28)

IFP, inflammatory fibroid polyp.

guideline for gastric ESD/EMR provided by the Japanese Gastrointestinal Endoscopy Society, differentiated mucosal gastric cancer <2 cm without ulceration is designated as an absolute indication for EMR or ESD [7]. In Japan, however, most of these lesions are treated with ESD instead of conventional EMR. One reason is that the injection skills necessary for conventional EMR are technically difficult, and the reliability of en bloc resection with conventional EMR is low. With UEMR, the lifting technique is not required and snaring is much easier than in conventional EMR because the mucosa and submucosa are naturally contracted and float into the snare. Another reason is that ESD has a clear advantage in enabling R0 resection of EGC. Nevertheless, gastric ESD can be difficult and time-consuming for lesions in certain locations such as the greater curvature, due to bleeding and approach difficulty. In contrast, G-UEMR can be easier to perform in that location in the stomach, as we achieved an R0 resection rate of 82% (11/13) of the neoplastic lesions in the greater curvature in a mean acceptable short procedure time of 6.3 minutes. We achieved a 100% R0 resection rate in cases of EGC (n = 15) with various sizes as follows: <6 mm (n = 6), 6 to 10 mm (n = 3), 11 to 15 mm (n = 4), and > 15 mm (n = 2). These data differ from those of the study by Nakamoto et al., which showed that EMR was comparable to ESD in terms of complete resection rate only in millimeter-size gastric cancers [8]. Compared to the present study, the EMR used in their study was conventional EMR. G-UEMR might be better than conventional EMR for achieving R0 resection as shown in the colorectal lesions, although the firmer gastric submucosal layer might not float as well in the colonic wall. Because we carefully evaluated each lesion's morphology, size, and location, we performed G-UEMR instead of ESD only when a lesion was considered to be suitable, which is very important to procedure success. It is unclear why the R0 rate was lower in adenoma cases compared to adenocarcinoma cases. We think that the physician might have been more careful in identifying the margins of lesions that were strongly suspected of being cancer. We included one SMT case. UEMR is reported to be safe and effective for rectal neuroendocrine tumors [9]. We consider that UEMR may not

be effective for SMT arising from muscle layer because the procedure is suitable for mucosal and submucosal lesions.

The incidence of AEs associated with UEMR is reportedly similar to that for conventional EMR in the colon. In the present analysis, there was one case of aspiration pneumonia but no AEs such as bleeding or perforation, although 28% of patients (9/32) were on antiplatelet therapy. One patient experienced aspiration pneumonia after G-UEMR. This AE can occur with EMR or ESD of the upper gastrointestinal tract. Preoperative assessment of swallowing and respiratory function also may be beneficial for elderly patients. Suction of excess saliva in the oral cavity during the procedure, refraining from excess air inflation, and a head-up position may be helpful to prevent pneumonia. Although the effect of an over tube for preventing aspiration pneumonia is currently unknown, it might be useful in elderly patients or individuals who have trouble swallowing.

G-UEMR may be applicable to various types of gastric lesions, including hyperplastic polyps, adenomas, and EGC as in the present analysis. In contrast, regarding morphology, we performed G-UEMR for elevated lesions but not depressed lesions. In the duodenum, a depressed type is reportedly an independent predictor of conversion from EMR to ESD [10]. Regarding the fact that the majority of EGC cases have a depressed morphology, expansion of the application of G-UEMR to gastric depressed-type lesions is expected; however, ESD is currently performed with its established effect for R0 resection of depressed lesions. One reason is the difference in the “floating” effect in the stomach versus the colon. Another reason is that depressed lesions sometimes harbor ulceration (pathological fibrosis), in which case, the “floating” effect might not appear as expected.

Because the 15 cases of EGC that were included in the present study all were elevated type <20 mm, and generally en bloc snare resection may be suitable for lesions of that size, we suggest that for elevated-type EGC <2 cm, UEMR would be preferable. G-UEMR was technically easier to perform on lesions at the greater curvature because retroflex positioning of the scope is not required. ESD may be more difficult in this circumferential location. Thus, from our limited data, an elevated-type EGC <2 cm at the greater curvature would be the best candidate for G-UEMR. For lesions with other morphologies and that measure >2 cm, ESD may result in a better R0 resection. UEMR is less time-consuming than ESD and less technically demanding than conventional EMR.

Some limitations inherent in the present study are the small number of included patients and the lack of generalizability of its results. Because this study was conducted at tertiary institutions, with all procedures performed by endoscopists experienced with ESD and UEMR, it is unclear whether the results can be extrapolated to all endoscopists.

Conclusions

In conclusion, our results suggest that G-UEMR may be a good alternative to ESD or conventional EMR for small elevated-type

gastric lesions because it is safe and easy to perform. We believe that the favorable outcomes, including a high R0 resection rate and few complications, were attributable to careful lesion selection for G-UEMR.

Acknowledgments

The authors thank Editage (www.editage.com) for English language editing.

Competing interests

Dr. Yamamoto received lecture honoraria from Fujifilm (Japan). Dr. Takeuchi received lecture honoraria from Olympus (Tokyo, Japan), Daiichi-Sankyo, Miyarisan Pharmaceutical, Asuka Pharmaceutical, AstraZeneca, EA Pharma, Zeria Pharmaceutical, Fujifilm, Kaneka Medix, and Kyorin Pharmaceutical. Dr. Uedo received lecture honoraria from Olympus, FUJIFILM, Boston Scientific Japan, 3-D Matrix, Ltd, Daiichi-Sankyo, Takeda Pharmaceutical, EA Pharma, Otsuka Pharmaceutical, AstraZeneca, Top Cooperation, Miyano Medical Machine, and Miyarisan Pharmaceutical.

References

- [1] Pimentel-Nunes P, Dinis-Ribeiro M, Ponchon T et al. Endoscopic submucosal dissection: European Society of Gastrointestinal Endoscopy (ESGE) Guideline: European Society of Gastrointestinal Endoscopy (ESGE) Guideline. *Endoscopy* 2015; 47: 829–854
- [2] Yamashina T, Uedo N, Akasaka T et al. Comparison of underwater vs conventional endoscopic mucosal resection of intermediate-size colorectal polyps. *Gastroenterology* 2019; 157: 451–461.e2
- [3] Kono Y, Sakae H, Okada H. Underwater endoscopic mucosal resection for gastric polyp. *Dig Endosc* 2018; 30: 525
- [4] Iwagami H, Kanesaka T, Ishihara R et al. Underwater endoscopic mucosal resection for remaining early gastric cancer after endoscopic submucosal dissection. *Endoscopy* 2019; 51: E229–E230
- [5] Uemura H, Kono Y, Nakagawa M. Intramucosal gastric cancer on the prepylorus completely resected by underwater endoscopic mucosal resection. *Dig Endosc* 2019; 31: 332
- [6] Kim DH, Park SY, Park CH et al. Underwater endoscopic mucosal resection for neoplasms in the pyloric ring of the stomach: four case reports. *World J Clin Cases* 2020; 8: 3050–3056
- [7] Ono H, Yao K, Fujishiro M et al. Guidelines for endoscopic submucosal dissection and endoscopic mucosal resection for early gastric cancer. *Dig Endosc* 2016; 28: 3–15
- [8] Nakamoto S, Sakai Y, Kasanuki J et al. Indications for the use of endoscopic mucosal resection for early gastric cancer in Japan: a comparative study with endoscopic submucosal dissection. *Endoscopy* 2009; 41: 746–750
- [9] Park SS, Han KS, Kim B et al. Comparison of underwater endoscopic mucosal resection and endoscopic submucosal dissection of rectal neuroendocrine tumors (with videos). *Gastrointest Endosc* 2020; 91: 1164–1171
- [10] Kiguchi Y, Kato M, Nakayama A et al. Feasibility study comparing underwater endoscopic mucosal resection and conventional endoscopic mucosal resection for superficial non-ampullary duodenal epithelial tumor < 20 mm. *Dig Endosc* 2020; 32: 753–760