

# Rebleeding of Ruptured Intracranial Aneurysms in the Immediate Postoperative Period after Coil Embolization

Se Hun Chang, Hee Sup Shin, Seung Hwan Lee, Hak Cheol Koh, Jun Seok Koh

Department of Neurosurgery, Kyung Hee University Hospital at Gangdong, Kyung Hee University School of Medicine, Seoul, Korea

**Objective :** Early rebleeding after coil embolization of ruptured intracranial aneurysms is rare, however serious and fatal results of rebleeding have been reported. We studied the incidence and angiographic and clinical characteristics of rebleeding of ruptured aneurysms occurring in the immediate postoperative period after coil embolization.

**Materials and Methods :** We analyzed patients who had aneurysmal subarachnoid hemorrhage and underwent coil embolization. Patients with dissecting aneurysms, blood blister-like aneurysms, fusiform aneurysms, and pseudoaneurysms were excluded. This study included 330 consecutive patients. The clinical and radiological data of 7 of these patients with acute rebleeding after coil embolization were reviewed.

**Results :** The incidence of rebleeding of ruptured aneurysms after coil embolization was 2.1% (7/330), and all cases of rebleeding occurred in the immediate postoperative period within 3 days after coiling. The radiological characteristics were as follows: anterior communicating artery (ACoA) aneurysm (71.4%, 5/7); presence of intracerebral hemorrhage (ICH, 71.4%, 5/7); dome-to-neck ratio < 2 (42.9%, 3/7); presence of bleb (42.9%, 3/7); and subtotal occlusion of aneurysm after coiling (14.3%, 1/7). A thrombolytic agent was administered in 1 patient and continued anticoagulation was performed in 2 patients. Rebleeding patients showed a very poor outcome (Glasgow Outcome Scale 1, 85.7%, 6/7).

**Conclusion :** The prognosis of early rebleeding was very poor. Location of aneurysms on ACoA, the unilateral hypoplasia of A1 segment, presence of ICH and bleb, and adverse events during the procedure were probably associated with early rebleeding of ruptured intracranial aneurysms in the immediate postoperative period after coil embolization.

J Cerebrovasc Endovasc Neurosurg.  
2015 September;17(3):209-216

Received : 26 June 2015

Revised : 1 August 2015

Accepted : 24 August 2015

**Correspondence to Hee Sup Shin**

Department of Neurosurgery, Kyung Hee University Hospital at Gangdong, 892 Dongnam-ro, Gangdong-gu, Seoul 05278, Korea

Tel : 82-2-440-6090

Fax : 82-2-440-8404

E-mail : realeponym@hanmail.net

ORCID : <http://orcid.org/0000-0002-5286-8448>

## Previous presentation

This article had been presented at "2014 Annual Meeting of Society of Korean Endovascular Neurosurgeon" under the title of "Rebleeding of ruptured intracranial aneurysms at immediate postoperative period after coil embolization". We certify that the contents of this manuscript, in all or in part, has not been published and is not being considered for publication elsewhere, unless otherwise specified herein.

**Keywords** Coil embolization, Intracranial aneurysm, Rebleeding; subarachnoid hemorrhage

This is an Open Access article distributed under the terms of the Creative Commons Attribution Non-Commercial License (<http://creativecommons.org/licenses/by-nc/3.0>) which permits unrestricted non-commercial use, distribution, and reproduction in any medium, provided the original work is properly cited.

## INTRODUCTION

Coil embolization is a safe and effective treatment for unruptured and ruptured intracranial aneurysms. Some studies comparing coil embolization to clip ligation for ruptured aneurysms have reported more fa-

vorable outcomes for patients treated with coil embolization compared with those treated with surgical clipping, with low rates of procedure-related complications, ischemic infarction, vasospasm, and shunt-dependent hydrocephalus.<sup>12)13)</sup> Despite these good clinical results, rebleeding and recanalization requiring

further treatment remain major concerns of coil embolization. Although the rebleeding rate after coil embolization of ruptured intracranial aneurysms may seem low at 1.0-3.6%,<sup>6,8,16)</sup> poor and fatal outcomes of rebleeding patients have been reported. We reviewed the clinical data of patients with rebleeding after coil embolization and evaluated the risk factors and possible mechanisms of rebleeding in these patients.

## MATERIALS AND METHODS

### Patient population

Between July 2006 and October 2014, 391 consecutive patients with spontaneously ruptured intracranial aneurysms were treated using the endovascular method at our institution. Patients with dissecting aneurysms, blood blister-like aneurysms, and pseudoaneurysms and those with absolute evidence of intra-procedural rupture were excluded. Finally, 330 consecutive patients with saccular aneurysms treated using conventional coil embolization were included in this study. Presence of subarachnoid hemorrhage (SAH) was confirmed by brain computed tomography (CT), brain magnetic resonance imaging, or cerebrospinal fluid tapping. Ruptured aneurysms were identified using digital subtraction angiography (DSA) and three-dimensional rotational angiography (3 DRA), and coil embolization was performed within 24 h from hospital admission. Postprocedural brain CT was performed immediately after coil embolization. Patients underwent follow-up brain CT immediately after occurrence of at least one of the following symptoms or signs: neurological deterioration, sudden severe headache, and sudden fluctuation of vital signs. Rebleeding of intracranial aneurysms was defined as a significant increase in amount of SAH on follow-up brain CT compared with immediate postprocedural brain CT. In patients with combined intracerebral hemorrhage (ICH), cases of increased or newly developed ICH without increased SAH were not considered as rebleeding cases. The reason we did not consider this situation as rebleeding of a coiled aneurysm

was due to a possible mechanism reported by Cho et al., who hypothesized that delayed hemorrhage or propagation of initial ICH may be caused by vulnerability of parenchyma adjacent to the ICH rather than rebleeding of a coiled aneurysm.<sup>4)</sup>

Radiological changes observed between brain CT scans performed immediately after embolization and those performed during follow-up were analyzed by an experienced neuroradiologist. Each patient's clinical condition at admission was evaluated according to the Hunt-Hess grading system, and SAH conditions were examined using the Fisher grading system. The radiological characteristics of the aneurysms and the coiling procedures were reviewed carefully on the basis of DSA and 3 DRA findings. The outcomes were classified using the Glasgow Outcome Scale (GOS).

### Endovascular treatment

Coil embolization was performed immediately after diagnostic DSA, which was typically on the day of ictus. This procedure was performed under general anesthesia, except in patients with poor neurologic condition. A bolus of heparin was administered intravenously according to patient body weight after femoral artery sheath placement, and additional boluses of 1,000 IU of heparin were administered every hour for maintenance of an activated clotting time of 250-300 s during the procedure. In the majority of cases, coil embolization using detachable coils was performed using the classic single-catheter method. Various methods including stent-assisted, balloon-assisted, double-catheter, and catheter protection were used in cases of necessitating neck protection. A loading dose of dual antiplatelet medication (100 mg aspirin and 300 mg clopidogrel) was administered orally before or just after intervention, and a continued maintenance dose (100 mg aspirin and 75 mg clopidogrel, daily) was administered thereafter. If thromboembolic complications occurred, various rescue therapy regimens such as intraarterial or intravenous infusions of urokinase, abciximab, tirofiban, or low-

Table 1. Clinical and angiographic characteristics of patients with rebleeding of ruptured intracranial aneurysms after coil embolization

No.	Sex	Age (years)	HHG	FG	ICH	Aneurysm location	D/N ratio	Maximal aneurysm diameter	Bleb	Thrombolytics or anticoagulants	R-R scale	Rebleeding time	Mental status before rebleeding	Mental status after rebleeding	Note	GOS
1	F	78	III	IV	Y	DACA	2.32	10.19	Y	-	III	10 h	Drowsy	Stupor	On the neck	1
2	M	43	III	IV	Y	ACoA	2.24	3.1	Y	IA UK (intraop)	II	5 h	Drowsy	Stupor	Thrombus formation	1
3	F	79	IV	IV	Y	MCA	2.10	7.97	N	-	II	65 h	Drowsy	Deep drowsy	-	4
4	F	59	IV	IV	Y	ACoA	2.52	6.2	Y	-	I	10 h	Deep drowsy	Coma	-	1
5	M	53	II	III	N	ACoA	1.93	1.64	N	IV LMWH (postop)	II	25 h	Deep drowsy	Stupor	Coil protrusion	1
6	M	51	IV	IV	Y	ACoA	1.84	1.99	N	-	I	8 h	Semicoma	Coma	Size discrepancy byt CTA and DSA	1
7	M	58	III	III	N	ACoA	1.23	2.51	N	IV LMWH (postop)	I	52 h	Alert	Coma	Coil protrusion	1

HHG = Hunt-Hess grade; FG = Fisher grading system; ICH = intracerebral hemorrhage; D/N = dome/neck; R-R = Raymond-Roy; GOS = Glasgow Outcome Scale; F = female; M = male; Y = yes; N = no; DACA = distal anterior cerebral artery aneurysm; ACoA = anterior communicating artery; MCA = middle cerebral artery; IA = intraarterial; IV = intravenous; UK = urokinase; intraop = intraoperative; LMWH = low-molecular-weight heparin; postop = postoperative; b/t = between; CTA = computed tomography angiography; DSA = digital subtraction angiography

molecular-weight heparin (LMWH) were used during or after the procedure. Aneurysm occlusion was classified using the Raymond-Roy scale, as follows: grade I, complete occlusion; grade II, neck remnant; grade III, residual aneurysm flow.<sup>14)</sup>

## RESULTS

Rebleeding after coil embolization occurred in 7 (2.1%) of the 330 consecutive patients, whose clinical and radiological data are summarized in Tables 1 and 2. All cases of rebleeding occurred in the immediate postoperative period within 72 h (5-65 h) after coil embolization. The mean patient age was  $60.0 \pm 20.0$  years (mean  $\pm$  SD, range: 43-79 years), and there were 4 male patients. Three patients (42.9%) had poor clinical grades (Hunt-Hess grade [HHG] IV), and 5 patients (71.4%) had ICH. Of the 7 patients, 5 (71.4%) had anterior communicating artery (ACoA) aneurysms, 1 had a middle cerebral artery aneurysm, and 1 had a distal anterior cerebral artery aneurysm. The angiographic characteristics were as follows: aneurysm size  $< 4$  mm (57.1%, 4/7); dome-to-neck ratio  $< 2$  (42.9%, 3/7); presence of bleb (42.9%, 3/7); good treatment results for total or near-total occlusion of the aneurysm (85.7%, 6/7).

In one interesting case a size and morphological discrepancy of the aneurysm was observed between

computed tomography angiography (CTA) and DSA in patient No. 6. Brain CT showed a large amount of SAH (Fig. 1A), and CTA showed an elongated aneurysm (Fig. 1B) with a dome-to-neck ratio of 2.47 (neck diameter, 1.44 mm; neck-to-dome diameter, 3.57 mm). However, 3 DRA performed after CTA showed a small saccular aneurysm (Fig. 1C, D) with a dome-to-neck ratio of 1.83 (neck diameter, 1.22 mm; neck-to-dome diameter, 2.24 mm). The aneurysm was treated successfully using 3 detachable coils with no neck and lumen remnants (Fig 1E). Unfortunately, sudden deterioration of mental status occurred after 8 h from coil embolization, and brain CT showed an increased amount of SAH and newly developed intraventricular hemorrhage.

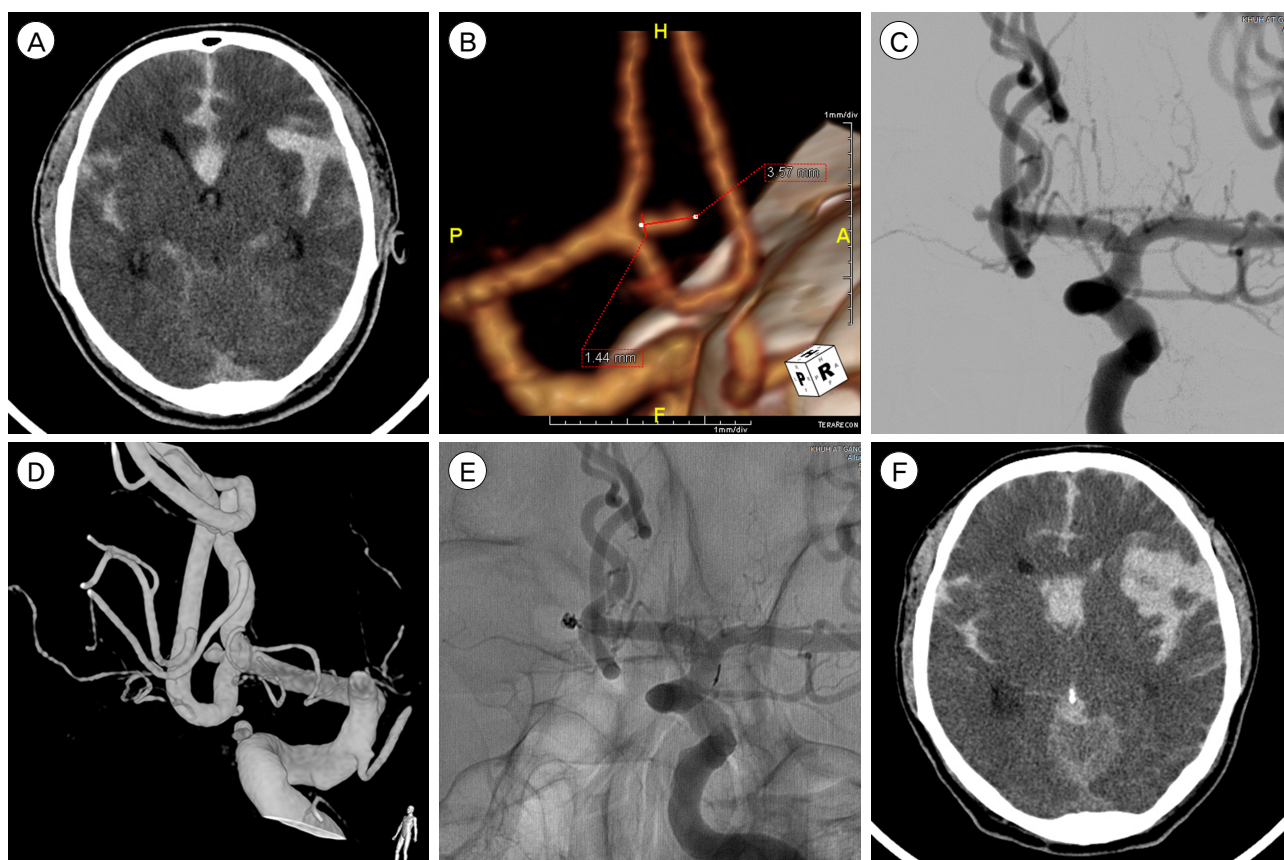
Thrombolytics or anticoagulants were administered to 3 patients (42.9%). Urokinase was administered in 1 patient because of thrombus formation on the distal artery of the aneurysm, and continued anticoagulation using LMWH was performed in 2 patients to prevent thrombus formation caused by coil protrusion into the parent artery. Of the rebleeding patients, 2 underwent additional coil embolization and decompressive surgery, 1 underwent surgical clipping, 2 underwent only decompressive surgery, and 2 patients could not be treated. In all patients, mental status after rebleeding was worse than that before rebleeding. Six patients were in poor condition and presented with stuporous

**Table 2. Summary of the characteristics of patients with rebleeding of ruptured intracranial aneurysms after coil embolization**

Clinical characteristics	
Initial HHG	II: 1, III: 3, IV: 3
Use of thrombolytics or anticoagulants	3/7 (42.9%)
GOS	I: 6, IV: 1
Radiologic characteristics	
Presence of ICH	5/7 (71.4%)
Anterior communicating artery aneurysm	5/7 (71.4%)
Dome/neck ratio $< 2$	3/7 (42.9%)
Aneurysm size $< 5$ mm	4/7 (57.1%)
Presence of bleb	3/7 (42.9%)
Subtotal occlusion after coil embolization	1/7 (14.3%)

HHG = Hunt-Hess grade; GOS = Glasgow Outcome Scale; ICH = intracerebral hemorrhage





**Fig. 1.** A case with discrepancies in the aneurysm size and morphology between computed tomography angiography (CTA) and three-dimensional rotational angiography (3DRA) findings. (A) Brain CT shows a large amount of subarachnoid hemorrhage (SAH) in the basal cistern, interhemispheric fissure, and both Sylvian fissures. (B) CTA shows an elongated anterior communicating artery aneurysm with a small neck diameter of 1.44 mm and a large neck-to-dome diameter of 3.57 mm. The dome-to-neck ratio of the aneurysm is 2.47. (C, D) Digital subtraction angiography and 3DRA performed after CTA show a small saccular aneurysm with a dome-to-neck ratio of 1.83 (neck diameter, 1.22 mm; neck-to-dome diameter, 2.24 mm). (E) The aneurysm is secured by coil embolization using 3 detachable coils, with no neck and lumen remnants. (F) Compared to immediate postoperative brain CT, brain CT performed 8 h after coil embolization shows increased SAH in the left Sylvian fissure, interhemispheric fissure, and basal cistern with newly developed intraventricular hemorrhage.

mentality or worse symptoms, and 3 of these patients were in a coma. Although we tried to secure the aneurysms and stabilize the brain condition, rebleeding patients showed a very poor outcome (GOS 1, 85.7%, 6/7).

#### Illustrative case (patient no. 7)

A 58-year-old male presented with decreased consciousness after a sudden headache (HHG III). Brain CT showed a dense SAH (Fig. 2A), and CTA showed a saccular aneurysm of the ACoA (Fig. 2B). Emergency cerebral DSA was performed, and 3DRA showed 2 ACoA aneurysms located in the superior (Fig. 2C, D) and anterior (Fig. 2E, F) directions. Under general an-

esthesia, the 2 ACoA aneurysms were embolized using detachable coils, with no evidence of neck remnants (Fig. 2G, H), and the patient recovered well with a nearly alert mental status. However, there was a risk of thrombus formation because a coil loop protruded into the ACoA (Fig. 2H), and therefore, LMWH was administered intravenously in the postoperative period. Eight hours after coil embolization, the patient presented with a comatose mentality, and brain CT showed increased SAH in the basal cistern. Follow-up DSA performed immediately showed contrast leakage from the ACoA aneurysm in the anterior direction (Fig. 2I). The aneurysm was secured by per-

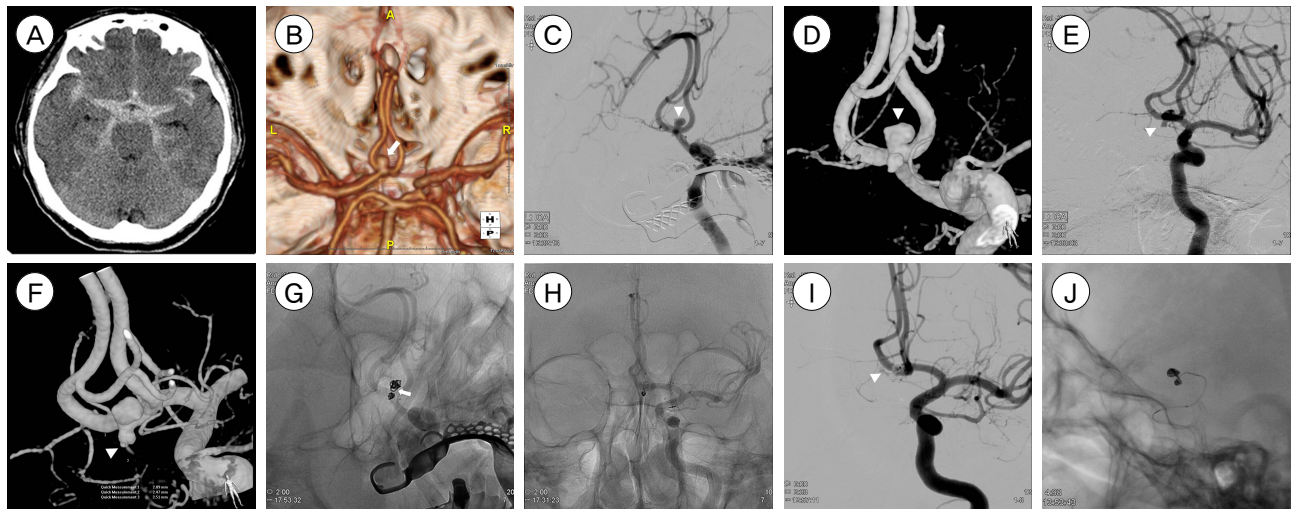
forming additional coil embolization (Fig. 2J) and decompressive hemicraniectomy. Unfortunately, the patient died 6 days after rebleeding.

## DISCUSSION

In this study, the incidence of rebleeding after coil embolization for ruptured intracranial aneurysms was 2.1% of 7 patients among 330 patients. This incidence rate was similar to those reported in previous studies. The Cerebral Aneurysm Rerupture After Treatment study reported a 1.9% incidence rate of rebleeding after aneurysm treatment using coiling and clipping.<sup>7</sup> In that study, the risk of rebleeding after coil embolization was greater than that after clipping (3.4% after coiling vs. 1.3% after clipping), and the median time to rebleeding was 3 days.<sup>7</sup> Recently, 2 large retrospective studies evaluated the incidence of rebleeding after coiling of ruptured intracerebral aneurysms.<sup>4,8</sup> Kang et al.<sup>8</sup> reported the incidence of rebleeding as 1.0% (6 of 591 patients) and reported that rebleeding

occurred within 24 h in all cases and no further episodes of rebleeding occurred after the first 24 h. In another study the rebleeding rate was 1.1% (13 patients), and of the 13 patients, 10 experienced rebleeding within 3 days after coil embolization.<sup>4</sup> Similarly, in the current study, all rebleeding cases occurred within 3 days after coiling. Our study confirmed that recurrent hemorrhage after coiling occurred most often within 3 days after coil embolization, and careful management and neurological workup should be performed during this period.

The risk factors known to influence rebleeding are incomplete embolization, anticoagulant or thrombolytic agent use, coil compaction, and coil migration.<sup>1)2)7)10)15)16</sup> Coil compaction and coil migration were reported to show association with delayed rebleeding,<sup>4</sup> whereas incomplete embolization of ruptured aneurysms is a strong risk factor associated with early rebleeding.<sup>6)7)13</sup> However, complete occlusion of aneurysms does not always guarantee prevention of rerupture. Rebleeding may occur after successful embolization with sat-



**Fig. 2.** A case of rebleeding of anterior communicating artery (ACoA) aneurysms after successful coil embolization. (A) Brain computed tomography (CT) of a 58-year-old male shows dense subarachnoid hemorrhage. (B) Computed tomography angiography (CTA) shows a saccular aneurysm of the ACoA (arrow). Cerebral digital subtraction angiography (DSA) and three-dimensional rotational angiography (3DRA) show 2 ACoA aneurysms. (C, D) A large aneurysm in the superior direction (arrowhead), and (E, F) a small aneurysm in the anterior direction (arrowhead). (G, H) Both aneurysms are successfully obliterated with detachable coils, and there is no definite evidence of neck and lumen remnants. Because a coil loop protrudes into the ACoA (arrow), continued anticoagulation therapy with intravenous low-molecular-weight heparin is performed. After the sudden presentation of comatose mentality, brain CT shows increased subarachnoid hemorrhage (SAH) in the basal cistern. (I) Contrast leakage from the ACoA aneurysm in the anterior direction is confirmed on follow-up DSA (arrowhead). (J) Additional coil embolization secures the reruptured aneurysm.

isfactory occlusion on angiography because uneven distribution of the coil masses may cause a channel of blood stream to the ruptured point of the aneurysm, and early recanalization may occur with spontaneous resolution of the thrombi through the inserted coil loops.<sup>8)</sup> In our study, subtotal occlusion of the aneurysm was observed in only 1 patient; however, other risk factors including the use of thrombolytics or anticoagulants, presence of ICH, and presence of bleb were also identified. Use of anticoagulants and thrombolytics was a risk factor for rebleeding, because spontaneous resolution of thrombi or disturbances in thrombus formation inside the coiled aneurysm could occur. Coexistence of ICH was another risk factor for rebleeding. Some studies have reported that ICH is an important risk factor for rebleeding and that thrombosed pseudoaneurysms inside the ICH may cause rebleeding.<sup>6)16)</sup>

The most common location of reruptured aneurysms was the ACoA (71.4%, 5/7). An ACoA aneurysm was considered a risk factor for rebleeding in some previous studies.<sup>4)</sup> Sluzewski and van Rooij<sup>16)</sup> suggested that ruptured ACoA aneurysms were more often associated with ICH. An interesting finding of the current study was related to ACoA aneurysms. Four of the 5 reruptured ACoA aneurysms had unilateral hypoplasia of the A1 segment of the anterior cerebral artery. Unilateral hypoplasia of the A1 segment is not a rare vascular variation, and frequency of this variation up to 13% was reported in an autopsy series.<sup>11)</sup> Chen and Li<sup>3)</sup> reported that the prevalence of ACoA aneurysms with A1 segment hypoplasia patients was 14%, and 43-57% of patients with ACoA aneurysms had unilateral hypoplasia of the A1 segment. Strong association of hemodynamic stress caused by unilateral hypoplasia of the A1 segment with ACoA aneurysms has been reported.<sup>3)9)</sup> In this series, the incidence of A1 hypoplasia in rebleeding patients was relatively high (80.0%) compared with previous reports, and we hypothesized a possible association of rebleeding with early minor compaction of the coils owing to hemo-

dynamic stress caused by unilateral hypoplasia of the A1 segment. In addition, these ACoA aneurysms in our series with unilateral A1 hypoplasia were small-sized aneurysms with a maximal diameter of < 4 mm (patient nos. 2, 5, 6, and 7 in Table 1). Small aneurysm size has been reported as a risk factor for rebleeding.<sup>16)</sup> Overestimated coil packing density and masking of contrast filling into the aneurysm after coil embolization could explain the reason why small size was a risk factor. Hemodynamic stress due to A1 segment hypoplasia and small aneurysm could lead to some synergic effect on rebleeding after coil embolization.

In this study, rebleeding patients showed a very poor outcome. Only 1 patient showed a good outcome (GOS 4), and the remaining 6 patients showed poor outcomes (GOS 1). Most previous studies have reported very poor outcomes in rebleeding patients.<sup>1)2)4-6)8)16-18)</sup> In particular, the outcomes of early rebleeding were worse than those of delayed rebleeding.<sup>4)</sup> Our study has some limitations. This was a retrospective study and was subject to selection bias and deviations. In addition, the sample size was small, and statistical analysis was not possible.

## CONCLUSION

Rebleeding of ruptured intracerebral aneurysms after coil embolization is rare, but the outcomes of rebleeding are serious or fatal. In this study, we suggested the risk factors of rebleeding, including the presence of ICH, presence of bleb, use of anticoagulants or thrombolytics, and occurrence of ACoA aneurysms. In cases of small ACoA aneurysms, unilateral hypoplasia of the A1 segment may influence rebleeding owing to hemodynamic stress.

## Disclosure

We declare that the authors have no financial or other conflicts of interest in relation to this research and its publication. The authors have no funding sources to declare.

## REFERENCES

1. Asgari S, Wanke I, Schoch B, Stolke D. Recurrent hemorrhage after initially complete occlusion of intracranial aneurysms. *Neurosurg Rev.* 2003 Oct;26(4):269-74.
2. Bavinszki G, Killer M, Gruber A, Reinprecht A, Gross CE, Richling B. Treatment of basilar artery bifurcation aneurysms by using Guglielmi detachable coils: a 6-year experience. *J Neurosurg.* 1999 May;90(5):843-52.
3. Chen H, Li MH. A1 segment hypoplasia accompanied by AcomA aneurysms assessed with magnetic resonance angiography. *Surg Radiol Anat.* 2014 May;36(4):353-7.
4. Cho YD, Lee JY, Seo JH, Kang HS, Kim JE, Kwon OK, et al. Early recurrent hemorrhage after coil embolization in ruptured intracranial aneurysms. *Neuroradiology.* 2012 Jul;54(7):719-26.
5. Hayashi K, Takahata H, Kitagawa N. Ruptured cerebral aneurysm complicated with rebleeding following thrombolysis during endovascular embolization: two case reports. *Neurol Med Chir (Tokyo).* 2007 Jun;47(6):261-4.
6. Jartti P, Isokangas JM, Karttunen A, Jartti A, Haapea M, Koskelainen T, et al. Early rebleeding after coiling of ruptured intracranial aneurysms. *Acta Radiol.* 2010 Nov;51(9):1043-9.
7. Johnston SC, Dowd CF, Higashida RT, Lawton MT, Duckwiler GR, Gress DR, et al. Predictors of re-hemorrhage after treatment of ruptured intracranial aneurysms: the Cerebral Aneurysm Rerupture After Treatment (CARAT) study. *Stroke.* 2008 Jan;39(1):120-5.
8. Kang DH, Kim YS, Baik SK, Park SH, Park J, Hamm IS. Acute serious rebleeding after angiographically successful coil embolization of ruptured cerebral aneurysms. *Acta Neurochir (Wien).* 2010 May;152(5):771-81.
9. Kluytmans M, van der Grond J, van Everdingen KJ, Klijn CJ, Kappelle LJ, Viergever MA. Cerebral hemodynamics in relation to patterns of collateral flow. *Stroke.* 1999 Jul;30(7):1432-9.
10. Makoui AS, Smith DA, Evans AJ, Cahill DW. Early aneurysm recurrence after technically satisfactory Guglielmi detachable coil therapy: is early surveillance needed? Case report. *J Neurosurg.* 2000 Feb;92(2):355-8.
11. Maurer J, Maurer E, Perneczky A. Surgically verified variations in the A1 segment of the anterior cerebral artery. Report of two cases. *J Neurosurg.* 1991 Dec;75(6):950-3.
12. McDougall CG, Spetzler RF, Zabramski JM, Partovi S, Hills NK, Nakaji P, et al. The Barrow Ruptured Aneurysm Trial. *J Neurosurg.* 2012 Jan;116(1):135-44.
13. Molyneux A, Kerr R, Stratton I, Sandercock P, Clarke M, Shrimpton J, et al. International Subarachnoid Aneurysm Trial (ISAT) of neurosurgical clipping versus endovascular coiling in 2143 patients with ruptured intracranial aneurysms: a randomised trial. *Lancet.* 2002 Oct 26;360(9342):1267-74.
14. Roy D, Milot G, Raymond J. Endovascular treatment of unruptured aneurysms. *Stroke.* 2001 Sep;32(9):1998-2004.
15. Sinson G, Bagley LJ, Flamm ES, Hurst RW. Fatal rebleeding following coil embolization of cerebral aneurysms: the role of long-term systemic anticoagulation. *Neuroradiology.* 2001 May;43(5):398-404.
16. Sluzewski M, van Rooij WJ. Early rebleeding after coiling of ruptured cerebral aneurysms: incidence, morbidity, and risk factors. *AJNR Am J Neuroradiol.* 2005 Aug;26(7):1739-43.
17. Vanninen R, Koivisto T, Saari T, Hernesniemi J, Vapalahti M. Ruptured intracranial aneurysms: acute endovascular treatment with electrolytically detachable coils-a prospective randomized study. *Radiology.* 1999 May;211(2):325-36.
18. Willinsky RA, Peltz J, da Costa L, Agid R, Farb RI, terBrugge KG. Clinical and angiographic follow-up of ruptured intracranial aneurysms treated with endovascular embolization. *AJNR Am J Neuroradiol.* 2009 May;30(5):1035-40.