

CORRECTION

Open Access



Correction to: Treatment of the mandibular shift in an adult woman and the diagnostic value of joint space index: a case report

Kai Xia^{1,2†}, Wentian Sun^{1,2†}, Liyuan Yu^{1,2}, Xinqi Huang^{1,2}, Zhihe Zhao^{1,2} and Jun Liu^{1,2*}

Correction to: Eur J Med Res (2020) 25:50

<https://doi.org/10.1186/s40001-020-00451-0>

In the original version of the article, the pretreatment TMJ images demonstrated in Fig. 12a had been shown in Fig. 3. Therefore, the pretreatment TMJ images were deleted in Fig. 12a.

The revised Fig. 12 and legend is given below.

The original article can be found online at <https://doi.org/10.1186/s40001-020-00451-0>.

*Correspondence: junliu@scu.edu.cn[†]

¹ State Key Laboratory of Oral Diseases & National Clinical Research Center for Oral Diseases, West China Hospital of Stomatology, Sichuan University, No. 14, 3rd Section, South Renmin Road, Chengdu 610041, Sichuan, China
Full list of author information is available at the end of the article



© The Author(s) 2020. This article is licensed under a Creative Commons Attribution 4.0 International License, which permits use, sharing, adaptation, distribution and reproduction in any medium or format, as long as you give appropriate credit to the original author(s) and the source, provide a link to the Creative Commons licence, and indicate if changes were made. The images or other third party material in this article are included in the article's Creative Commons licence, unless indicated otherwise in a credit line to the material. If material is not included in the article's Creative Commons licence and your intended use is not permitted by statutory regulation or exceeds the permitted use, you will need to obtain permission directly from the copyright holder. To view a copy of this licence, visit <http://creativecommons.org/licenses/by/4.0/>. The Creative Commons Public Domain Dedication waiver (<http://creativecommons.org/publicdomain/zero/1.0/>) applies to the data made available in this article, unless otherwise stated in a credit line to the data.

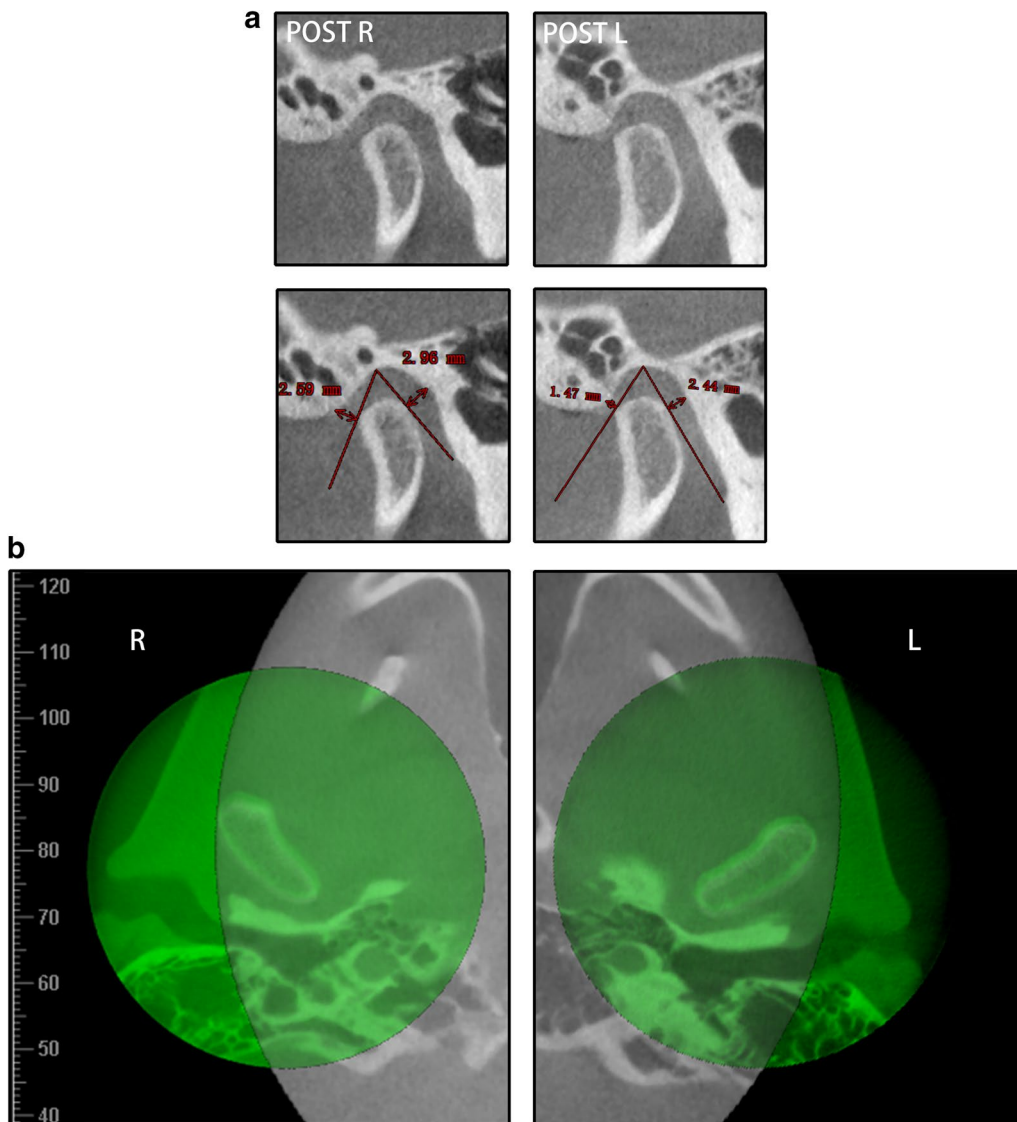


Fig. 12 **a** The post-treatment bilateral TMJ JSIs. **b** CBCT superimposition of the pretreatment (gray) and post-treatment (green) bilateral TMJs

Author details

¹ State Key Laboratory of Oral Diseases & National Clinical Research Center for Oral Diseases, West China Hospital of Stomatology, Sichuan University, No. 14, 3rd Section, South Renmin Road, Chengdu 610041, Sichuan, China.

² Department of Orthodontics, West China Hospital of Stomatology, Sichuan University, No. 14, 3rd Section, South Renmin Road, Chengdu 610041, Sichuan, China.

Reference

1. Xia K, Sun W, Yu L, Huang X, Zhao Z, Liu J. Treatment of the mandibular shift in an adult woman and the diagnostic value of joint space index: a case report. *Eur J Med Res.* 2020;25(1):50.

Publisher's Note

Springer Nature remains neutral with regard to jurisdictional claims in published maps and institutional affiliations.

Published online: 12 November 2020