

Contents lists available at [ScienceDirect](http://www.sciencedirect.com)

International Journal of Surgery Case Reports

journal homepage: www.casereports.com

Laparoscopic resection of a huge retroperitoneal cystic lymphangioma after successful reduction of tumor size with a double balloon catheter



Yusuke Ishibashi, Hironori Tsujimoto*, Keita Kouzu, Hiroyuki Horiguchi, Shinsuke Nomura, Nozomi Ito, Kyohei Kanematsu, Kenji Yamazaki, Shuichi Hiraki, Suefumi Aosasa, Takuji Noro, Junji Yamamoto, Kazuo Hase

Department of Surgery, National Defense Medical College, 3-2 Namiki, Tokorozawa, Saitama 359-8513, Japan

ARTICLE INFO

Article history:

Received 16 March 2015

Received in revised form 8 April 2015

Accepted 8 April 2015

Available online 11 April 2015

Keywords:

Double balloon catheter

Laparoscopic surgery

Lymphangioma

ABSTRACT

INTRODUCTION: Retroperitoneal cystic lymphangiomas are rare. We report a case of retroperitoneal huge cystic lymphangioma that was successfully aspirated the cyst's contents with double balloon catheter and excised laparoscopically.

PRESENTATION OF CASE: A 34-year-old man was admitted to our hospital with low-grade fever and abdominal pain that had lasted for 1 week. Abdominal computed tomography and magnetic resonance imaging showed a fluid-filled multilocular mass measuring 13.5 cm in diameter around the tail of the pancreas, which was diagnosed as a retroperitoneal cystic lymphangioma. We successfully excised the tumor by laparoscopic distal pancreateosplenectomy. We punctured and aspirated the tumor with a double-balloon catheter to decrease the tumor's size without spilling the tumor content. Cytology showed no malignant cells, and histopathological examination confirmed cystic lymphangioma. No recurrence was noted on radiographic imaging 10 months postoperatively.

DISCUSSION AND CONCLUSION: Laparoscopic treatment for retroperitoneal huge cystic lymphangioma is feasible, and the double balloon catheter is useful for reducing the tumor volume.

© 2015 The Authors. Published by Elsevier Ltd. on behalf of Surgical Associates Ltd. This is an open access article under the CC BY-NC-ND license (<http://creativecommons.org/licenses/by-nc-nd/4.0/>).

1. Introduction

Cystic lymphangiomas are congenital benign tumors of the lymphatic system. More than 95% of cystic lymphangiomas occur in the head, neck, and axilla, with only 1% occurring in the retroperitoneum. Laparotomy was selected in previous cases for treating huge retroperitoneal cystic lymphangiomas [1,2]. However, this open procedure often results in greater postoperative pain and poor cosmetic appearance. With recent advances in surgical equipment and techniques, more minimally invasive procedures with laparoscopy for the treatment of large tumors are indicated [3].

In this paper, we describe a case in which laparoscopic treatment was used for a huge retroperitoneal cystic lymphangioma, and we also describe the usefulness of the double balloon catheter (SAND balloon catheter) for reducing the tumor's volume. Written informed consent was obtained from the patient.

2. Case presentation

A 34-year-old man without any relevant medical history was admitted to our hospital with an abdominal tumor with a low-grade fever and abdominal pain that had lasted for 1 week. The tumor, located in the upper abdomen, could be palpated on physical examination. Routine laboratory and hematologic investigations showed normal parameters, except for white blood cell count, which was 9100/mm³ (normal range, 4000–8000/mm³). Abdominal computed tomography showed a fluid-filled multilocular mass measuring 13.5 cm in diameter around the tail of the pancreas without obvious infiltration (Fig. 1A). A T2-weighted magnetic resonance image showed a high signal-intensity tumor without a solid component, and the wall of the mass was thin and smooth (Fig. 1B). Thus, the radiological diagnosis of retroperitoneal lymphangioma was established and laparoscopic excision was performed.

After the induction of general anesthesia, the patient was placed in a supine position. A camera port was inserted into an umbilical incision. A pneumoperitoneum of 12 mm Hg was created, and 4 additional ports (1 port with a diameter of 12 mm and 3 with a diameter of 5 mm) were inserted into the left upper, right lower, left lower, and right upper quadrants, under laparoscopic imaging. The tumor was located on the pancreatic tail; however, detailed laparoscopic observation of the lesion site was difficult due to the

* Corresponding author: Tel.: +81 4 2995 1637; fax: +81 4 2996 5205.
E-mail address: tsujihi@ndmc.ac.jp (H. Tsujimoto).

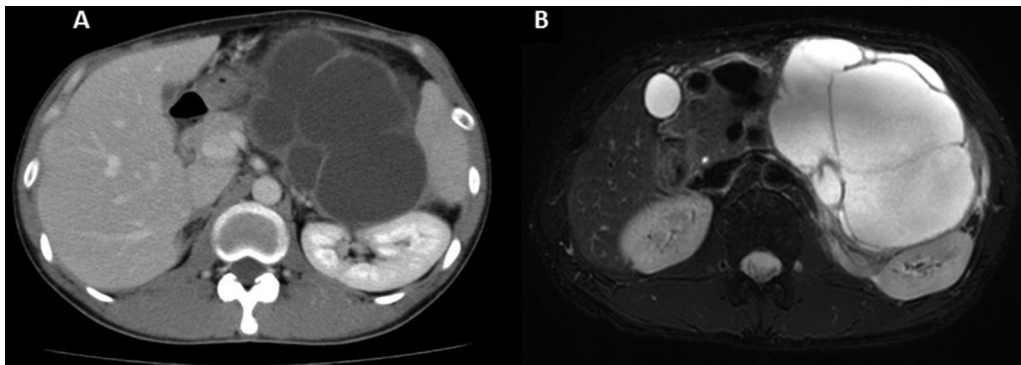


Fig. 1. Abdominal computed tomography and magnetic resonance imaging of the present case. (A) Abdominal computed tomography showed a fluid-filled multilocular mass measuring 13.5 cm in diameter around the tail of the pancreas. (B) A T2-weighted magnetic resonance image showed a high signal-intensity tumor without a solid component.

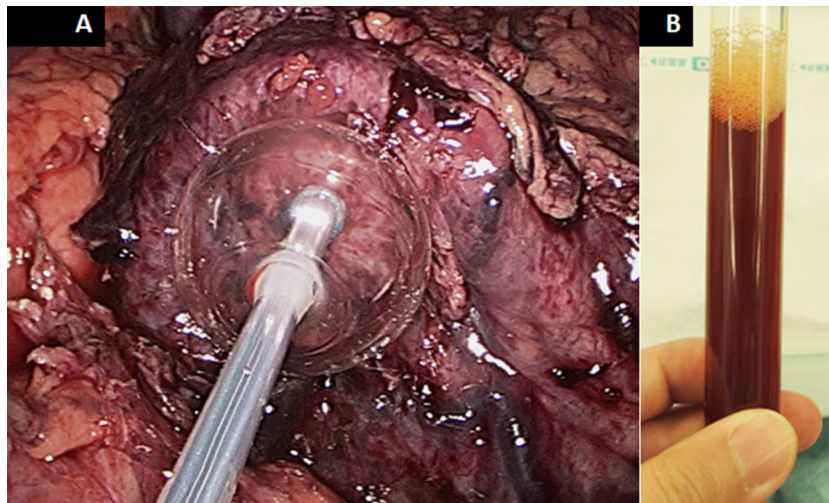


Fig. 2. Laparoscopic view of the SAND balloon catheter and contents of the cyst. (A) A SAND balloon catheter was utilized to decrease the tumor’s volume and to obtain a good exposure of the lesion. (B) The tumor was aspirated carefully under laparoscopy using the catheter without spilling any of the tumor contents. The cyst contained a brownish serous fluid.

huge tumor size. A double balloon catheter (SAND balloon catheter, Hakko Medical, Tokyo, Japan) was then utilized to decrease the tumor’s volume and to obtain a good exposure of the lesion. The tumor was aspirated carefully under laparoscopy using the SAND balloon catheter without spilling any of the tumor content (Fig. 2). About 1 L of brownish serous fluid was removed from the cyst. After fluid aspiration, the entry hole was sutured with 3.0 monocryl (Ethicon, Tokyo, Japan). The tumor was tightly adherent to the

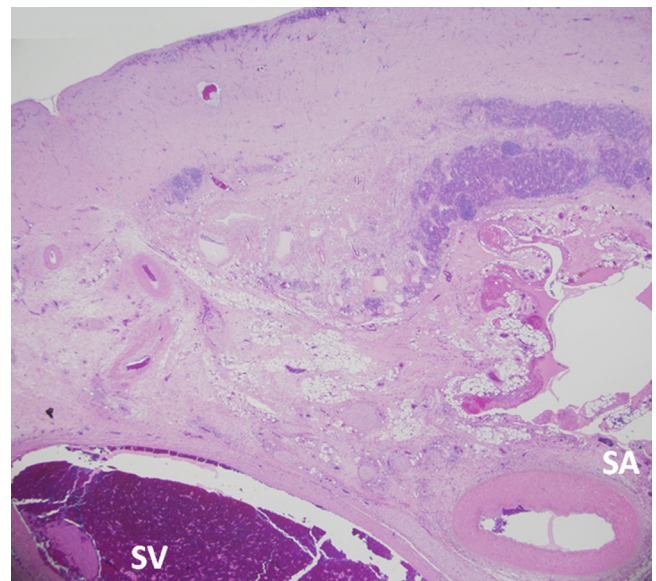


Fig. 4. Photomicrograph of the wall of the cyst and the splenic artery and vein. The photomicrograph shows that the wall of the cyst is tightly adherent to the splenic artery and vein through the fibrous tissue (hematoxylin and eosin staining, $\times 20$).

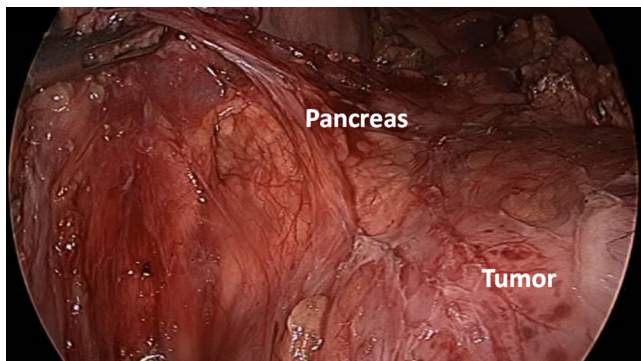


Fig. 3. Laparoscopic view of the tumor, which was tightly adherent to the pancreas. Because of the tight adhesions to the pancreas, splenic artery, and splenic vein, the tumor was not able to be dissected, and thus pancreateosplenectomy was performed.

pancreas, splenic artery, and splenic vein and was not able to be dissected (Fig. 3); thus, distal pancreateosplenectomy was performed. Surgical duration was 254 min and the estimated blood loss was 293 mL. Cytology of cyst's contents showed no malignant cells and histopathological examination confirmed a cystic lymphangioma (Fig. 4). No recurrence was noted on radiographic imaging 10 months postoperatively.

3. Discussion

Cystic lymphangiomas are rare benign tumors of the lymphatic system that are more common in the pediatric population. Lymphangiomas are typically asymptomatic, but if patients have symptoms that necessitate therapeutic intervention, surgical resection is the best choice [4]. In spite of its benign nature, retroperitoneal lymphangioma can rarely recur in young patients [5]; therefore, complete resection is necessary for reducing the risk of recurrence.

Laparoscopic or retroperitoneal laparoscopic resections have sometimes been chosen to reduce postoperative pain and cosmetic issues [6–10]. However, to manage a huge tumor, decreasing the tumor volume by aspirating cystic contents without spillage is required to permit mobilization and removal of the tumor. In this case, we used a specially designed SAND balloon catheter for aspiration to minimize spilling the cyst's contents into the retroperitoneal cavity. SAND balloon catheter has two balloons, namely a distal balloon and a proximal transparent one near its tip. After the entire distal balloon is inserted into the cyst, the distal balloon is then inflated with 10 mL of saline solution. The proximal balloon is inflated in the same way while the inflated distal balloon is retracted. The punctured cyst wall is sandwiched between the two inflated balloons, which can minimize spilling the cyst's contents. This balloon catheter was developed primarily for laparoscopic cystectomy of benign ovarian cysts [11]. Yagihashi et al. previously successfully used a SAND balloon catheter to resect a cystic lymphangioma [3].

The laparoscopic approach for the retroperitoneal cystic lymphangioma was technically feasible through careful separation of the cyst from adjacent structures. The use of the SAND balloon catheter to decrease tumor volume prior to resection was associated with no complications. This minimally invasive technique also improves patient comfort, with less postoperative pain, rapid recovery after surgery, and minimal scar formation. Laparoscopic excision should therefore, be considered as a therapeutic option to treat retroperitoneal huge cystic lymphangiomas.

Conflicts of interest

All authors certify that they have no commercial associations that might pose a conflict of interest in connection with submitted article.

Funding

All authors certify that they have no sponsors regarding submitted article.

Ethical approval

Ethics Committee's approval is unnecessary for this case report, and written informed consent was obtained from the patient.

Consent

A written informed consent was obtained from the patient.

Author contribution

YI, HT, HH, NI, KK and SN helped to draft the manuscript. KY, SH, SA, TN, JY and KH have revised the manuscript critically. All authors read and approved the final manuscript.

Acknowledgment

All authors certify that they have no commercial associations that might pose a conflict of interest in connection with submitted article.

References

- [1] M. de Perrot, O. Rostan, P. Morel, et al., Abdominal lymphangioma in adults and children, *Br. J. Surg.* 85 (1998) 395–397.
- [2] B. Baseskioglu, C.Y. Bilen, I. Erkan, Laparoscopic management of giant hygroma renalis, *Int. J. Urol.* 19 (2012) 484–485.
- [3] Y. Yagihashi, K. Kato, K. Nagahama, M. Yamamoto, H. Kanamaru, A case of laparoscopic excision of a huge retroperitoneal cystic lymphangioma, *Case Rep. Urol.* 2011 (2011) 1–3.
- [4] A.S. Fattahi, G. Maddah, M. Motamedolshariati, et al., Chronic low back pain due to retroperitoneal cystic lymphangioma, *Arch. Bone Joint Surg.* 2 (2014) 72–74.
- [5] H. Ozdemir, E. Kocakoc, Z. Bozgeyik, et al., Recurrent retroperitoneal cystic lymphangioma, *Yonsei Med. J.* 46 (2005) 715–718.
- [6] A. Celia, G. Breda, Laparoscopic excision of a retroperitoneal cystic lymphangioma: an insidious case, *J. Laparoendosc. Adv. Surg. Tech. A* 17 (2007) 315–316.
- [7] R.R. Singh, K.K. Govindarajan, C. Bowen, et al., Retroperitoneal cystic lymphangioma: a rare presentation in childhood, treated laparoscopically, *J. Laparoendosc. Adv. Surg. Tech. A* 19 (2009) 249–250.
- [8] E.N. Trindade, M.R. Trindade, J.C. Boza, et al., Laparoscopic excision of a retroperitoneal cystic lymphangioma in an elderly patient, *Minerva Chir.* 62 (2007) 145–147.
- [9] T. Tsukamoto, S. Tanaka, T. Yamamoto, et al., Laparoscopic excision of a retroperitoneal cystic lymphangioma: report of a case, *Surg. Today* 33 (2003) 142–144.
- [10] B.E. Wildhaber, C. Chardot, C. Le Coultre, et al., Total laparoscopic excision of retroperitoneal cystic lymphangioma, *J. Laparoendosc. Adv. Surg. Tech. A* 16 (2006) 530–533.
- [11] A. Takeda, S. Imoto, M. Mori, et al., Management of large adnexal tumors by isobaric laparoendoscopic single-site surgery with a wound retractor, *Eur. J. Obstet. Gynecol. Reprod. Biol.* 166 (2013) 185–189.

Open Access

This article is published Open Access at scimedirect.com. It is distributed under the [IJSCR Supplemental terms and conditions](#), which permits unrestricted non commercial use, distribution, and reproduction in any medium, provided the original authors and source are credited.