



Original research article

Effects of dietary nanocrystalline cellulose supplementation on growth performance, carcass traits, intestinal development and lipid metabolism of meat ducks



Haoyue Han, Keying Zhang, Xuemei Ding, Shiping Bai, Yueheng Luo, Jianping Wang, Huanwei Peng, Qiufeng Zeng*

Institute of Animal Nutrition, Key Laboratory for Animal Disease-Resistance Nutrition of China, Ministry of Education, Sichuan Agricultural University, Chengdu 611130, China

ARTICLE INFO

Article history:

Received 26 April 2016

Received in revised form

20 June 2016

Accepted 20 June 2016

Available online 5 July 2016

Keywords:

Carcass traits

Growth performance

Lipid metabolism

Meat duck

Nanocrystalline cellulose

ABSTRACT

The influence of nanocrystalline cellulose (NCC) supplementation on growth performance, carcass traits, intestinal development, and lipid metabolism was assessed in 600 one-day-old male meat ducks (Cherry Valley ducks) from 1 to 35 d of age. Diets were supplemented with 0, 200, 500, 800 and 1,500 mg/kg NCC during both the starter (1–14 d) and grower (15–35 d) phases. Each dietary treatment consisted of 8 replicate cages of 15 birds. Supplementation of NCC was associated with dose dependent increases in BW gain and feed intake ($P < 0.01$) during 1–14 d of age and in BW at 35 d of age. As NCC content increased, the percentage of breast meat weight ($P < 0.05$) and leg (with bone) weight ($P < 0.05$) linearly increased, while the percentage of abdominal fat weight ($P < 0.01$) linearly decreased in ducks at 35 d of age. Supplementation of NCC resulted in a dose-dependent increase in the weight ($P < 0.05$) and density ($P < 0.01$) of the cecum. The percentage of total hepatic lipid content ($P < 0.01$) at 14 d of age and serum triglyceride (TG) concentration ($P = 0.052$) at 35 d of age linearly decreased with increasing of dietary NCC addition. In conclusion, inclusion of 1,500 mg/kg NCC in feed resulted in the greatest improvements in duck performance, intestinal development and lipid deposition.

© 2016, Chinese Association of Animal Science and Veterinary Medicine. Production and hosting by Elsevier B.V. on behalf of KeAi Communications Co., Ltd. This is an open access article under the CC BY-NC-ND license (<http://creativecommons.org/licenses/by-nc-nd/4.0/>).

1. Introduction

Dietary fiber has been included in experimental diets for monogastric animals for many years, which has been shown to promote gut health and microflora in monogastric animals (Barry et al., 2001). There are 3 main groups of fiber: cellulose, non-cellulosic polymers, and pectic polysaccharides (Bailey and Macrae, 1973). In contrast to pectin, crystalline cellulose is a non-fermentable fiber commonly used as an inert ingredient or bulk agent in monogastric diets (Montagne et al., 2003; Hetland

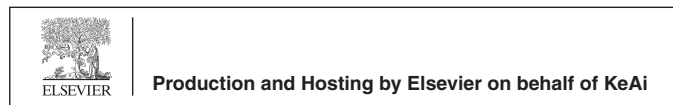et al., 2004). Wils-Plotz and Dilger (2013) verified that cellulose contributed no nutritive value to birds. However, some studies observed that supplementation of 3% cellulose, sugar beet pulp, and oat hulls to poultry diets resulted in better litter quality and a lower moisture content of the excreta (Jiménez-Moreno et al., 2009a).

The physicochemical characteristics of fiber (i.e., chemical composition, solubility, and particle size) have been shown to influence intestinal physiology and function (Figuerola et al., 2005). Jiménez-Moreno et al. (2010) observed that particle size of the fiber source did not affect performance, but a reduction in particle size of the oat hull and sugar beet pulp improved total tract apparent retention of DM, nitrogen, and soluble ash as well as the AMEn of the diet. Supplementation with micronized insoluble fiber particles, which had an average length and width of 250 and 25 μm , respectively, led to an increase in growth performance, ileal villus height to crypt depth ratio, and the number of goblet cells in broilers throughout the experimental period (Rezaei et al., 2011). Nanocrystalline cellulose (NCC), a by-product of the paper industry that is smaller in size than micronized insoluble particles, was obtained from the Center for Nanoscience and Technology (Beijing,

* Corresponding author.

E-mail address: zqf@sicau.edu.cn (Q. Zeng).

Peer review under responsibility of Chinese Association of Animal Science and Veterinary Medicine.



China). The geometric diameter and length of the NCC particle were 3 to 5 nm and 100 to 300 nm, respectively. This product is 99.0% cellulose on dry matter basis. To the best of our knowledge, there is no available information on the nutritional effects of NCC supplementation for monogastric animals.

There is a growing interest in evaluating the effects of fiber inclusion of the diets on lipid metabolism. Several studies reported that dietary cellulose depresses lipid accumulation in the liver of growing chicks fed *ad libitum* or reduces abdominal fat content and liver weight with effects being more pronounced with 3% cellulose than with 3% inulin (Jiménez-Moreno et al., 2010; Mohiti-Asli et al., 2012). Also, the weight and lipid content of the liver increased in force-fed chicks, but the values of all these parameters were reduced by the addition of 4% cellulose to the diet (Akiba and Matsumoto, 1978). Although the effects of dietary fiber on lipid metabolism of broilers have been investigated, little is known about the effects of dietary fiber on lipid metabolism of meat ducks. Therefore, this study determined the effects of dietary NCC supplementation on growth performance, carcass traits, intestinal development, and lipid metabolism in meat ducks from 1 to 35 d of age.

2. Materials and methods

This study was approved by the Institutional Animal Care and Use Committee of Sichuan Agricultural University.

2.1. Experimental design, birds and diets

Six hundred 1-d-old male Cherry Valley ducks were randomly assigned to 5 dietary treatment groups. There were 8 cages with 15 ducks per cage for each group. The 5 diets contained 0, 200, 500, 800, and 1,500 mg NCC per kg diet, respectively. The feeding program consisted of 2 diets: starter diets supplied from d 1 to 14, followed by a grower diet from d 15 to 35. The basal starter (d 1 to 14) and grower (d 15 to 35) experimental diets were formulated to meet or exceed the nutrient requirements for meat ducks in NRC (1994) (Table 1). The different levels of NCC in the experimental diets were produced by mixing a control diet (treatment 1) and 1,500 mg/kg of NCC to the diet (treatment 5) at a ratio of 13:2 (treatment 2), 2:1 (treatment 3), or 7:8 (treatment 4) to produce diets containing 200, 500, or 800 mg/kg of NCC, respectively. Feed was steam-pelleted and the diameters of the pellets in the starter and growers diet were 2 and 3 mm, respectively.

2.2. Bird housing and management

All ducks were reared in cages (2.2 m × 1.2 m × 0.9 m) in a temperature and humidity controlled room with a 24 h constant light schedule and free access to water and feed throughout the experimental period.

2.3. Sampling and measurement

At d 14 and 35, after feed withdrawal for 12 h, the ducks and feed in each cage were weighed. Body weight gain (BWG), cumulative feed intake (FI), and feed-to-gain ratio (FCR) were calculated. Then, one duck with a weight closest to the cage average was selected and bled through the jugular vein. The blood samples were immediately placed on ice, transported to the laboratory within 3 h of collection, and centrifuged at 2,000 × g for 15 min in a refrigerated centrifuge at about 4°C. Serum was collected and stored at -20°C until certain biochemical parameters were assayed. Serum triglyceride (TG), total cholesterol (TC), high-density lipoprotein (HDL), and low-density lipoprotein (LDL) concentrations, as well as alanine aminotransferase (ALT) and aspartate

Table 1

Ingredients and chemical composition of the basal diets (dry matter basis).

| Item | Starter (1–14 d) | Grower (15–35 d) |
|----------------------------------|------------------|------------------|
| Ingredient, % | | |
| Corn | 62.4 | 72.6 |
| Soybean meal | 33.5 | 23.29 |
| L-Lysine-HCL | 0 | 0.131 |
| DL-Methionine | 0.185 | 0.165 |
| Limestone | 1.072 | 1.071 |
| Dicalcium phosphate | 1.696 | 1.615 |
| Bentonite | 0.107 | 0.088 |
| Sodium chloride | 0.35 | 0.35 |
| Choline chloride | 0.15 | 0.15 |
| Premix ¹ | 0.54 | 0.54 |
| Total | 100.00 | 100.00 |
| Calculated value, % | | |
| ME, kcal/kg | 2,850 | 2,900 |
| CP | 19.5 | 16.0 |
| Calcium | 0.90 | 0.85 |
| Available phosphorus | 0.42 | 0.40 |
| Digestible lysine | 0.94 | 0.81 |
| Digestible methionine | 0.45 | 0.39 |
| Digestible methionine + cysteine | 0.78 | 0.64 |
| Digestible threonine | 0.67 | 0.54 |
| Digestible tryptophan | 0.09 | 0.15 |
| Crude fiber ² | 2.97 | 2.54 |

¹ Premix provided per kilogram of diet: vitamin A, 8,000 IU; cholecalciferol, 2,000 IU; vitamin E, 5 IU; vitamin K₃, 1 mg; thiamine, 0.4 mg; riboflavin, 3.2 mg; pyridoxine, 1.2 mg; vitamin B₁₂, 6 µg; folic acid, 100 µg; niacin, 7 mg; calcium pantothenate, 5 mg; Fe (FeSO₄·H₂O) 80 mg; Cu (CuSO₄·5H₂O) 8 mg; Mn (MnSO₄·H₂O) 70 mg; Zn (ZnSO₄·H₂O) 90 mg; I (KI) 0.4 mg, Se (Na₂SeO₃) 0.3 mg.

² The crude fiber (CF) in starter diet (1–14 d): 2.99% for treatment 2 (200 mg/kg nanocrystalline cellulose [NCC]), 3.02% for treatment 3 (500 mg/kg NCC), 3.05% for treatment 4 (800 mg/kg NCC), 3.12% for treatment 5 (1,500 mg/kg NCC); the CF in grower diet (15–35 d): 2.55% for treatment 2, 2.58% for treatment 3, 2.61% for treatment 4, 2.68% for treatment 5.

aminotransferase (AST) activities, which were important indices to evaluate lipid metabolism and liver function, were analyzed using a commercial biochemistry analyzer (Yellow Springs Instrument Co., Inc., Yellow Springs, OH, USA).

After blood collection, the birds were euthanized by cervical dislocation. Samples of liver tissues were removed and weighed, and the left lobes of the livers were stored in 10% neutral formalin solution. Then, the tissues were trimmed, fixed, and embedded in paraffin. Thin (5 µm) sections of the tissues were prepared and mounted on slides, stained with hematoxylin and eosin for lipid deposition, and examined by a histologist. Morphological images of the liver sections were captured to determine the degree of lipid accumulation. The right lobe of the livers were collected into sample bags and immediately frozen at -20°C, freeze-dried, and ground through a 0.5 mm screen for later analysis of total hepatic lipid concentrations, as determined by ether extraction of moisture-free samples (Cherry and Jones, 1982).

Moreover, at 35 d of age, another duck from each replicate was randomly selected for evaluation of carcass traits and intestinal development. Feed was withdrawn 4 h before processing, and then the birds were weighed, slaughtered, defeathered, and weighed to obtain carcass weights (with feet and head attached), breast meat (including the pectoralis major and pectoralis minor muscles), leg (with bone), and abdominal fat weight. Carcass yield was determined as the percentage of carcass weight in relation to total body weight, whereas the yield of the eviscerated carcass with giblet (including the heart, liver, proventriculus, gizzard, and abdominal fat), eviscerated carcass, breast meat, leg (with bone), and abdominal fat were expressed as percentages of the carcass weight. The weight and length of each segment of the intestinal tract, including the duodenum, jejunum (defined as the region from the pancreas tail to Meckel's diverticulum), ileum, cecum, and rectum

were measured. The ratio of weight to length of each intestinal tract segment was calculated to determine the intestinal density (Applegate et al., 1999).

2.4. Statistical analysis

The effects of dietary NCC supplementation on growth performance, carcass traits, intestinal development, and lipid metabolism in ducks among treatments were analyzed as one-way ANOVA using the GLM procedure in SAS software (SAS Institute Inc., Cary, NC). Treatments effects (i.e., different concentrations of NCC) were partitioned into linear and quadratic components by the CONTRAST statement of the GLM procedure (SAS Institute Inc., Cary, NC). Data are expressed as means and standard error of the mean (SEM). $P \leq 0.05$ was considered statistically significant.

3. Results

3.1. Growth performance

The results for growth performance are presented in Table 2. The BWG ($P < 0.01$), FI ($P < 0.01$) during 1–14 d and BW ($P < 0.01$) at d 35 increased in a linear manner with the increase of NCC supplementation. No significant differences were found in FCR among treatment groups ($P > 0.05$).

3.2. Carcass traits

The weight of the eviscerated carcass with giblet ($P < 0.05$), eviscerated carcass ($P < 0.05$), breast meat ($P < 0.05$), and leg (with

bone) ($P < 0.05$) linearly increased with increasing NCC supplementation. In contrast, the weight and yield of abdominal fat linearly decreased ($P < 0.01$) with the increasing of dietary NCC (Table 3).

3.3. Intestinal development

The indices of intestinal development in ducks are shown in Tables 4–6. The weight ($P < 0.05$) and density ($P < 0.01$) of the ceca, the weight ($P < 0.05$) and percentage ($P < 0.05$) of the rectum linearly increased with increasing NCC supplementation in diet.

3.4. Lipid metabolism

Serum parameters of ducks fed diets containing different levels of NCC are presented in Table 7. Nanocrystalline cellulose supplementation had no effect on the activities of serum ALT and AST, and the content of serum TC, HDL, and LDL of ducks at 14 and 35 d of age. However, serum TG concentrations at d 35 tended to decrease linearly ($P = 0.052$) with increasing NCC supplementation.

The weight ($P < 0.05$) and percentage ($P < 0.01$) of the liver, and the percentage of total lipid content in the liver ($P < 0.01$) of ducks at 14 d linearly decreased with increasing NCC inclusion, but no differences were observed between dietary groups at the age of 35 d (Table 8). The lipid accumulation in livers at 14 or 35 d was directly observed from Figs. 1 and 2, respectively. At 14 d of age, the diffused fatty degeneration of livers in ducks fed diets containing 0, 200, and 800 mg/kg NCC was more severe compared with ducks fed 500 and 1,500 mg/kg of NCC diets, which was in line with the hepatic lipid content. The same

Table 2
The effect of nanocrystalline cellulose (NCC) supplementation on the growth performance of ducks.

| Item | BW ¹ , g | | | BWG, g | | FI, g | | FCR | |
|----------------------------|---------------------|-------------------|-------|-------------------|---------|-------------------|---------|--------|---------|
| | 1 d | 14 d | 35 d | 1–14 d | 15–35 d | 1–14 d | 15–35 d | 1–14 d | 15–35 d |
| NCC supplementation, mg/kg | | | | | | | | | |
| 0 | 55.8 | 597 ^d | 2,051 | 541 ^d | 1,454 | 831 ^c | 3,132 | 1.54 | 2.16 |
| 200 | 55.8 | 617 ^{bc} | 2,080 | 561 ^{bc} | 1,463 | 846 ^{bc} | 3,278 | 1.51 | 2.28 |
| 500 | 55.8 | 607 ^{cd} | 2,075 | 551 ^{cd} | 1,468 | 844 ^{bc} | 3,074 | 1.53 | 2.12 |
| 800 | 55.8 | 627 ^{ab} | 2,103 | 571 ^{ab} | 1,477 | 877 ^a | 3,159 | 1.54 | 2.17 |
| 1,500 | 55.8 | 638 ^a | 2,167 | 582 ^a | 1,529 | 873 ^{ab} | 3,246 | 1.50 | 2.13 |
| SEM | 0.06 | 6.64 | 29.0 | 6.64 | 28.1 | 10.5 | 52.5 | 0.01 | 0.04 |
| <i>P</i> -value | | | | | | | | | |
| AVONA | 0.912 | 0.001 | 0.076 | 0.001 | 0.292 | 0.017 | 0.057 | 0.057 | 0.084 |
| Linear | 0.597 | 0.000 | 0.006 | 0.000 | 0.053 | 0.003 | 0.374 | 0.097 | 0.200 |
| Quadratic | 0.976 | 0.706 | 0.674 | 0.706 | 0.294 | 0.252 | 0.220 | 0.198 | 0.964 |

BWG = body weight gain, FI = cumulated feed intake, FCR = feed-to-gain ratio.

^{a–d} Within a column, means without common superscripts are significantly different ($P < 0.05$).

¹ Data are means of 8 cages with 15 or 14 ducks per cage at 1, 14 or 35 d of age.

Table 3
The effect of nanocrystalline cellulose (NCC) supplementation on the carcass traits of ducks at 35 d of age.¹

| Item | Carcass | | Eviscerated carcass with giblet | | Eviscerated carcass | | Breast meat | | Leg (with bone) | | Abdominal fat | |
|----------------------------|-----------|--------------|---------------------------------|--------------|---------------------|--------------|-------------|--------------|-------------------|--------------|--------------------|-------------------|
| | Weight, g | % Of live BW | Weight, g | % Of carcass | Weight, g | % Of carcass | Weight, g | % Of carcass | Weight, g | % Of carcass | Weight, g | % Of carcass |
| NCC supplementation, mg/kg | | | | | | | | | | | | |
| 0 | 1,787 | 87.3 | 1,649 ^b | 92.4 | 1,499 ^b | 84.0 | 105 | 5.86 | 332 ^{bc} | 18.6 | 18.2 ^a | 1.01 ^a |
| 200 | 1,834 | 87.1 | 1,707 ^{ab} | 93.1 | 1,552 ^{ab} | 84.6 | 125 | 6.77 | 359 ^{ab} | 19.6 | 15.7 ^{ab} | 0.87 ^a |
| 500 | 1,790 | 86.3 | 1,657 ^b | 92.6 | 1,511 ^b | 84.4 | 109 | 6.07 | 318 ^c | 17.8 | 18.5 ^a | 1.03 ^a |
| 800 | 1,791 | 86.6 | 1,660 ^b | 92.7 | 1,514 ^b | 84.5 | 124 | 6.90 | 359 ^{ab} | 20.1 | 16.4 ^{ab} | 0.91 ^a |
| 1,500 | 1,892 | 87.5 | 1,780 ^a | 94.1 | 1,627 ^a | 86.0 | 135 | 7.10 | 373 ^a | 19.8 | 12.0 ^b | 0.63 ^b |
| SEM | 33.5 | 0.63 | 33.6 | 0.87 | 31.3 | 0.88 | 8.46 | 0.40 | 10.81 | 0.55 | 1.54 | 0.08 |
| <i>P</i> -value | | | | | | | | | | | | |
| AVONA | 0.146 | 0.628 | 0.049 | 0.652 | 0.042 | 0.562 | 0.110 | 0.149 | 0.006 | 0.032 | 0.036 | 0.009 |
| Linear | 0.061 | 0.805 | 0.020 | 0.202 | 0.014 | 0.121 | 0.035 | 0.056 | 0.014 | 0.125 | 0.009 | 0.003 |
| Quadratic | 0.193 | 0.144 | 0.146 | 0.583 | 0.156 | 0.636 | 0.864 | 0.807 | 0.346 | 0.888 | 0.219 | 0.124 |

^{a–c} Within a column, means without common superscripts are significantly different ($P < 0.05$).

¹ Means represent 8 ducks per treatment of 1 duck per replicate.

Table 4The effect of nanocrystalline cellulose (NCC) supplementation on the intestinal weight of ducks at 35 d of age.¹

| Item | Duodenum | | Jejunum | | Ileum | | Cecum | | Rectum | |
|----------------------------|-----------|--------------|-----------|--------------|-----------|--------------|--------------------|--------------|--------------------|--------------------|
| | Weight, g | % Of carcass | Weight, g | % Of carcass | Weight, g | % Of carcass | Weight, g | % Of carcass | Weight, g | % Of carcass |
| NCC supplementation, mg/kg | | | | | | | | | | |
| 0 | 5.76 | 0.32 | 14.6 | 0.81 | 15.0 | 0.84 | 2.69 ^b | 0.15 | 2.83 ^b | 0.16 ^{ab} |
| 200 | 6.28 | 0.34 | 15.1 | 0.82 | 17.3 | 0.94 | 2.89 ^{ab} | 0.16 | 2.83 ^b | 0.15 ^b |
| 500 | 6.91 | 0.39 | 13.5 | 0.75 | 16.0 | 0.90 | 2.53 ^b | 0.14 | 2.74 ^b | 0.15 ^{ab} |
| 800 | 6.24 | 0.35 | 14.5 | 0.81 | 14.9 | 0.83 | 2.61 ^b | 0.15 | 2.90 ^{ab} | 0.16 ^{ab} |
| 1,500 | 6.01 | 0.32 | 14.4 | 0.77 | 16.2 | 0.86 | 3.39 ^a | 0.18 | 3.46 ^a | 0.19 ^a |
| SEM | 0.57 | 0.03 | 0.79 | 0.04 | 0.68 | 0.03 | 0.19 | 0.01 | 0.21 | 0.01 |
| P-value | | | | | | | | | | |
| AVONA | 0.687 | 0.574 | 0.713 | 0.684 | 0.110 | 0.146 | 0.020 | 0.125 | 0.136 | 0.233 |
| Linear | 1.000 | 0.738 | 0.802 | 0.410 | 0.991 | 0.433 | 0.018 | 0.066 | 0.023 | 0.038 |
| Quadratic | 0.261 | 0.170 | 0.540 | 0.818 | 0.777 | 0.784 | 0.028 | 0.074 | 0.198 | 0.297 |

^{a,b} Within a column, means without common superscripts are significantly different ($P < 0.05$).¹ Means represent 8 ducks per treatment of 1 duck per replicate.**Table 5**The effect of nanocrystalline cellulose (NCC) supplementation on the intestinal length of ducks at 35 d of age.¹

| Item | Duodenum | | Jejunum | | Ileum | | Cecum | | Rectum | |
|----------------------------|------------|--------------|------------|--------------|------------|--------------|------------|--------------|------------|--------------|
| | Length, cm | % Of carcass | Length, cm | % Of carcass | Length, cm | % Of carcass | Length, cm | % Of carcass | Length, cm | % Of carcass |
| NCC supplementation, mg/kg | | | | | | | | | | |
| 0 | 29.6 | 1.66 | 71.9 | 4.02 | 71.2 | 3.99 | 15.6 | 0.88 | 10.2 | 0.57 |
| 200 | 29.4 | 1.61 | 74.9 | 4.08 | 75.2 | 4.09 | 15.8 | 0.86 | 10.9 | 0.60 |
| 500 | 32.3 | 1.81 | 67.7 | 3.78 | 69.2 | 3.87 | 15.7 | 0.88 | 9.75 | 0.55 |
| 800 | 32.0 | 1.79 | 74.3 | 4.16 | 71.6 | 4.00 | 15.5 | 0.87 | 10.7 | 0.60 |
| 1,500 | 31.0 | 1.65 | 74.1 | 3.94 | 74.7 | 3.97 | 16.1 | 0.86 | 11.7 | 0.62 |
| SEM | 1.15 | 0.07 | 2.20 | 0.12 | 2.32 | 0.12 | 0.58 | 0.04 | 0.59 | 0.03 |
| P-value | | | | | | | | | | |
| AVONA | 0.292 | 0.195 | 0.146 | 0.241 | 0.343 | 0.755 | 0.946 | 0.996 | 0.194 | 0.532 |
| Linear | 0.268 | 0.809 | 0.504 | 0.725 | 0.503 | 0.722 | 0.596 | 0.774 | 0.086 | 0.250 |
| Quadratic | 0.106 | 0.047 | 0.485 | 0.950 | 0.325 | 0.723 | 0.661 | 0.880 | 0.326 | 0.610 |

¹ Means represent 8 ducks per treatment of 1 duck per replicate.

pattern of lipid droplets deposition in the liver of ducks at 35 days of age was observed among treatment groups.

4. Discussion

In our study, supplementation of 1,500 mg/kg NCC in diet improved performance, carcass traits and the development of the ceca in ducks. These results agreed with previous studies, which found diets containing 3% fiber (oat hulls and soy hulls) improved BW, feed conversion, and the total retention of nutrients in the gastrointestinal tract of broilers suggesting that young broilers

required a minimal amount of dietary fiber to maximize growth performance (Bailey and Macrae, 1973; Jiménez-Moreno et al., 2009b). One reason may be that the particle size of NCC as a nano particle had an important effect on its function. A reduction in particle size of dietary fiber could improve the digestibility of nutrients by increasing the available surface area of the particles to digestive enzymes (Amerah et al., 2007). One study indicated that supplementation of 0.5% micronized insoluble fiber altered the morphology of the small intestinal by increasing ileal villus height and decreasing ileal crypt depth (Rezaei et al., 2011). The other reason may be that NCC as insoluble dietary fiber can incorporate water into the matrix and then swell to a variable extent during passage through the gastrointestinal tract, resulting in a bulkier digesta and a larger gastrointestinal tract. An increased content of digesta might stimulate HCl production (Duke, 1986). Furthermore, a low gizzard pH could improve pepsin activity and nitrogen retention.

Meanwhile, in the present study, we observed that supplementation of NCC could reduce lipid deposition of meat duck. This result was in agreement with previous studies, which reported that the addition of 3% inulin and 3% cellulose to the diet reduced abdominal fat deposition and hepatic lipid accumulation in broiler breeder hens (Mohiti-Asli et al., 2012). Velasco et al. (2010) also found that the inclusion of 1% inulin in diets decreased lipid concentration in the liver of broilers, and linearly reduced serum TG without affecting serum cholesterol, HDL-C, or LDL-C concentrations. Laying hens fed a diet supplemented with 10% cellulose exhibited significantly decreased serum lipids and liver lipids, which were accompanied by a significant increase in excreta lipid (Cherry and Jones, 1982). Dietary fiber reducing lipid

Table 6The effect of nanocrystalline cellulose (NCC) supplementation on the intestinal density¹ of ducks at 35 d of age.²

| Item | Duodenum | Jejunum | Ileum | Cecum | Rectum |
|----------------------------|----------|---------|-------|-------------------|--------|
| NCC supplementation, mg/kg | | | | | |
| 0 | 0.20 | 0.20 | 0.21 | 0.17 ^b | 0.27 |
| 200 | 0.21 | 0.20 | 0.23 | 0.18 ^b | 0.26 |
| 500 | 0.21 | 0.20 | 0.23 | 0.16 ^b | 0.28 |
| 800 | 0.19 | 0.20 | 0.21 | 0.17 ^b | 0.27 |
| 1,500 | 0.20 | 0.20 | 0.22 | 0.21 ^a | 0.30 |
| SEM | 0.01 | 0.01 | 0.01 | 0.01 | 0.02 |
| P-value | | | | | |
| AVONA | 0.793 | 0.968 | 0.198 | 0.010 | 0.550 |
| Linear | 0.609 | 0.512 | 0.659 | 0.005 | 0.162 |
| Quadratic | 0.741 | 0.827 | 0.568 | 0.005 | 0.751 |

^{a,b} Within a column, means without common superscripts are significantly different ($P < 0.05$).¹ Intestinal density (g/cm) = intestinal weight (g)/intestinal length (cm).² Means represent 8 ducks per treatment of 1 duck per replicate.

Table 7
The effect of nanocrystalline cellulose (NCC) supplementation on serum parameters of ducks at 14 and 35 d of age.¹

| Item | 14 d | | | | | | 35 d | | | | | |
|----------------------------|----------|----------|------------|------------|-------------|-------------|----------|----------|--------------------|------------|-------------|-------------|
| | ALT, U/L | AST, U/L | TG, mmol/L | TC, mmol/L | HDL, mmol/L | LDL, mmol/L | ALT, U/L | AST, U/L | TG, mmol/L | TC, mmol/L | HDL, mmol/L | LDL, mmol/L |
| NCC supplementation, mg/kg | | | | | | | | | | | | |
| 0 | 63.8 | 51.8 | 0.54 | 6.29 | 3.64 | 2.41 | 41.5 | 95.8 | 0.92 ^a | 4.87 | 2.67 | 1.78 |
| 200 | 52.5 | 50.8 | 0.65 | 7.62 | 4.20 | 3.12 | 33.0 | 57.5 | 0.65 ^b | 4.47 | 2.59 | 1.59 |
| 500 | 41.8 | 44.3 | 0.55 | 7.30 | 4.01 | 3.05 | 32.8 | 53.0 | 0.84 ^a | 4.36 | 2.41 | 1.57 |
| 800 | 60.8 | 58.8 | 0.70 | 7.19 | 4.16 | 2.72 | 38.3 | 73.8 | 0.79 ^{ab} | 5.04 | 2.74 | 1.95 |
| 1,500 | 43.8 | 64.3 | 0.64 | 6.67 | 3.60 | 2.77 | 44.3 | 73.0 | 0.64 ^b | 4.14 | 2.26 | 1.59 |
| SEM | 6.62 | 8.41 | 0.05 | 0.51 | 0.30 | 0.26 | 4.47 | 21.6 | 0.06 | 0.36 | 0.18 | 0.20 |
| <i>P</i> -value | | | | | | | | | | | | |
| AVONA | 0.117 | 0.520 | 0.130 | 0.403 | 0.489 | 0.358 | 0.315 | 0.663 | 0.033 | 0.407 | 0.360 | 0.608 |
| Linear | 0.147 | 0.183 | 0.180 | 0.847 | 0.594 | 0.903 | 0.264 | 0.837 | 0.052 | 0.344 | 0.186 | 0.844 |
| Quadratic | 0.755 | 0.573 | 0.321 | 0.165 | 0.150 | 0.318 | 0.157 | 0.368 | 0.708 | 0.562 | 0.554 | 0.650 |

ALT = alanine aminotransferase, AST = aspartate aminotransferase, TG = triglycerides, TC = total cholesterol, HDL = high-density lipoprotein, LDL = low-density lipoprotein.
^{a,b} Within a column, means without common superscripts are significantly different ($P < 0.05$).

¹ Means represent 8 ducks per treatment of 1 duck per replicate.

Table 8
The effect of NCC supplementation on liver and hepatic lipid content of ducks.¹

| Item | 14 d | | | 35 d | | |
|----------------------------|-----------------|--------------------|--------------------------|-----------------|----------------|--------------------------|
| | Liver weight, g | Liver, % of BW | Hepatic lipid content, % | Liver weight, g | Liver, % of BW | Hepatic lipid content, % |
| NCC supplementation, mg/kg | | | | | | |
| 0 | 21.7 | 3.67 ^a | 15.5 ^a | 38.7 | 1.89 | 4.60 |
| 200 | 20.9 | 3.37 ^{ab} | 12.3 ^{ab} | 38.8 | 1.87 | 4.22 |
| 500 | 18.7 | 3.07 ^{bc} | 9.36 ^{bc} | 38.7 | 1.87 | 4.18 |
| 800 | 19.8 | 3.13 ^{bc} | 13.7 ^{ab} | 38.2 | 1.82 | 4.29 |
| 1,500 | 18.2 | 2.87 ^c | 6.03 ^c | 38.9 | 1.80 | 4.45 |
| SEM | 0.99 | 0.17 | 1.99 | 1.09 | 0.06 | 0.36 |
| <i>P</i> -value | | | | | | |
| AVONA | 0.096 | 0.018 | 0.021 | 0.990 | 0.731 | 0.911 |
| Linear | 0.018 | 0.002 | 0.007 | 0.986 | 0.185 | 0.996 |
| Quadratic | 0.414 | 0.229 | 0.778 | 0.683 | 0.867 | 0.435 |

^{a-c} Within a column, means without common superscripts are significantly different ($P < 0.05$).

¹ Means represent 8 ducks per treatment of 1 duck per replicate.

deposition may be due to increased bile acid secretion, facilitating the emulsification of the dietary lipids in chicks (Garrett and Young, 1975; Krögdahl, 1985). Cellulose has little or no bile acid-binding capacity (Vahouny et al., 1980), suggesting that the recycling of bile acids and the absorption of fat would be more

complete in birds fed cellulose than in birds fed more soluble fiber source.

In conclusion, supplementation of 1,500 mg/kg NCC in duck diets had a positive effect on growth performance, carcass yield, cecum development, and lipid metabolism such as reducing

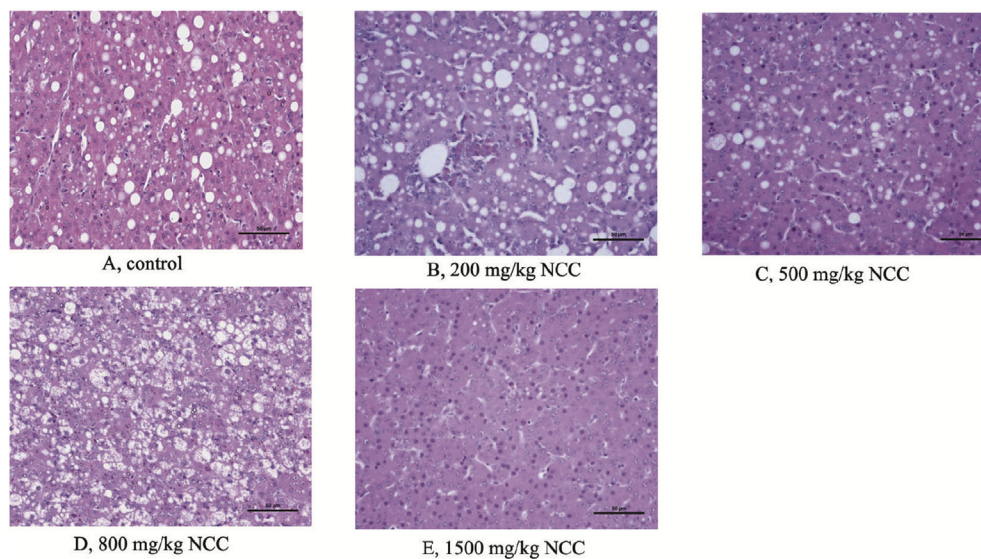


Fig. 1. The hepatic morphology of ducks at 14 d of age. NCC = nanocrystalline cellulose. (A), (B), (D): diffuse fatty degeneration was observed in hepatocytes; (C): hepatic steatosis was recognizable in a particle of liver cell; (E): normal histological structure.

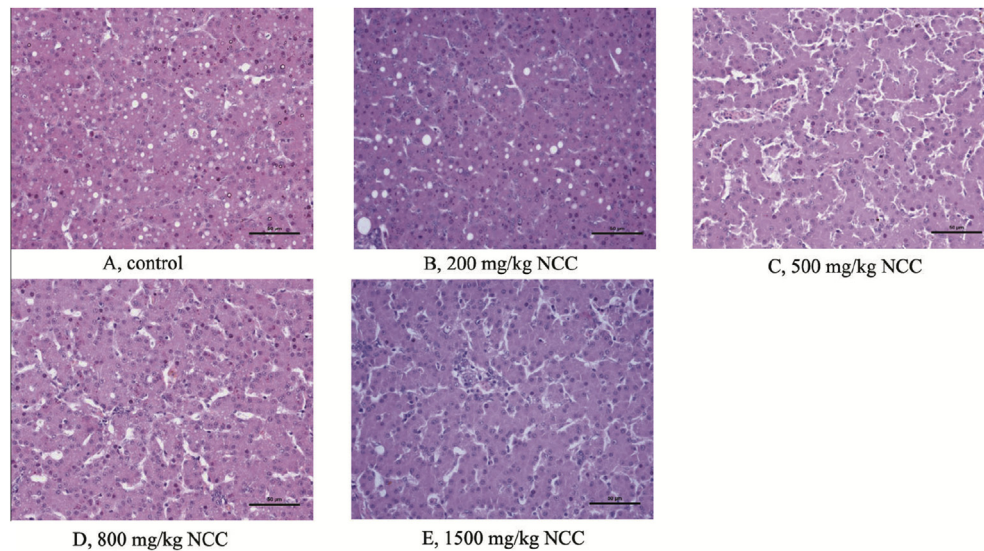


Fig. 2. The hepatic morphology of ducks at 35 d of age. NCC = nanocrystalline cellulose. (A), (B), (C), (D): hepatic steatosis was recognizable in a particle of liver cell; (E): normal histological structure.

abdominal fat, hepatic lipid deposition, and serum TG concentrations.

Conflict of interest statement

The authors declare that they have no competing interests.

Acknowledgments

This research was supported by grants from the National Scientific and Technical Supporting Program (2014BAD13B02), Meat Duck Industry Chain in Sichuan Province (2014NZ0030), Academy of Kechuang Feed Industry in Sichuan and Sichuan Agricultural University 211 Foundation of China.

References

- Applegate TJ, Ladwig E, Weissert L, Lilburn MS. Effect of hen age on intestinal development and glucose tolerance of the Pekin duckling. *Poult Sci* 1999;78:1485–92.
- Akiba Y, Matsumoto T. Effects of force-feeding and dietary cellulose on liver lipid accumulation and lipid composition of liver and plasma in growing chicks. *J Nutr* 1978;112:1577–85.
- Amerah AM, Ravindran V, Lentle RG, Thomas DG. Feed particle size: implications on the digestion and performance of poultry. *World's Poult Sci* 2007;63:439–55.
- Bailey RW, Macrae JC. Hydrolysis of intact leaf starch grains by glucamylase and α -amylase. *FEBS Lett* 1973;31:203–4.
- Barry V, McCleary B, Prosky L. *Advanced dietary fiber technology*. Oxford, UK: Blackwell Science Press; 2001.
- Cherry JA, Jones DE. Dietary cellulose, wheat bran, and fish meal in relation to hepatic lipids, serum lipids, and lipid excretion in laying hens. *Poult Sci* 1982;61:1873–8.
- Duke GE. Alimentary canal: secretions and digestion, special digestion functions and absorption. In: Sturkie PD, editor. *Avian physiology*. New York: Springer-Verlag; 1986. p. 289–302.
- Figuerola F, Hurtado ML, Estévez AM, Chiffelle I, Asenjo F. Fibre concentrates from apple pomace and citrus peel as potential fibre sources for food enrichment. *Food Chem* 2005;91:395–401.
- Garrett RL, Young J. Effect of micelle formation on the absorption of neutral fat and fatty acids by the chicken. *J Nutr* 1975;105:827–38.
- Hetland H, Choct M, Svihus B. Role of insoluble non-starch polysaccharides in poultry nutrition. *World Poult Sci J* 2004;60:415–22.
- Jiménez-Moreno E, González-Alvarado JM, de Coca-Sinova A, Lázaro R, Mateos GG. Effects of source of fiber on the development and pH of the gastrointestinal tract of broilers. *Anim Feed Sci Technol* 2009a;154:93–101.
- Jiménez-Moreno E, González-Alvarado JM, González-Sánchez D, Lázaro R, Mateos GG. Effects of type and particle size of dietary fiber on growth performance and digestive traits of broilers from 1 to 21 days of age. *Poult Sci* 2010;89:2197–212.
- Jiménez-Moreno E, González-Alvarado JM, Lázaro R, Mateos GG. Effects of type of cereal, heat processing of the cereal, and fiber inclusion in the diet on gizzard pH and nutrient utilization in broilers at different ages. *Poult Sci* 2009b;88:1925–33.
- Krögdahl A. Digestion and absorption of lipids in poultry. *J Nutr* 1985;115:675–85.
- Montagne L, Pluske JR, Hampson DJ. A review of interactions between dietary fiber and the intestinal mucosa, and their consequences on digestive health in young non-ruminant animals. *Anim Feed Sci Technol* 2003;108:95–117.
- Mohiti-Asli M, Shivazad M, Zaghari M, Aminzadeh S, Rezaian M, Mateos GG. Dietary fibers and crude protein content alleviate hepatic fat deposition and obesity in broiler breeder hens. *Poult Sci* 2012;91:3107–14.
- NRC. *Nutrient requirements of poultry*. 9th ed. Washington, DC, USA: National Research Council; 1994.
- Rezaei M, Karimi Torshizi MA, Rouzbehan Y. The influence of different levels of micronized insoluble fiber on broiler performance and litter moisture. *Poult Sci* 2011;90:2008–12.
- SAS. *SAS/STAT user's guide*. Cary, NC: SAS Institute, Inc., SAS Press; 2006.
- Velasco S, Ortiz LT, Alzueta C, Rebolé A, Treviño J, Rodríguez ML. Effect of inulin supplementation and dietary fat source on performance, blood serum metabolites, liver lipids, abdominal fat deposition, and tissue fatty acid composition in broiler chickens. *Poult Sci* 2010;89:1651–62.
- Vahouny GV, Tombes R, Cassidy MM, Kritchevsky D, Gallo LL. Dietary fibers: V. Binding of bile salts, phospholipids and cholesterol from mixed micelles by bile acid sequestrants and dietary fibers. *Lipids* 1980;15:1012–8.
- Wils-Plotz EL, Dilger RN. Combined dietary effects of supplemental threonine and purified fiber on growth performance and intestinal health of young chicks. *Poult Sci* 2013;92:726–34.