

Ashy dermatosis-like hyperpigmentation in a patient taking hydroxyurea



Stephen Li, PhD,^{a,b} Simone Arvisais-Anhalt, MD,^c Travis Vandergriff, MD,^{a,c} and Lu Q. Le, MD, PhD^a
Dallas, Texas

Key words: ashy dermatosis; drug-induced hyperpigmentation; drug reaction; erythema dyschromicum perstans; hemosiderin; hydroxyurea; lichenoid; lichen planus pigmentosus; macular pigmentation of uncertain etiology; melanin.

INTRODUCTION

Ashy dermatosis is a pigmentary disorder on the spectrum of acquired macular pigmentation of uncertain etiology.¹ It is most prevalent in patients from Central and South America and is characterized by widespread blue-gray macules with predilection for the face, neck, trunk, and upper extremities. Dermoscopy may show gray-blue dots corresponding to melanophages in the dermis, and histology demonstrates pigmentary incontinence of the papillary dermis. The etiology of ashy dermatosis is unknown but may involve a CD8⁺ T-lymphocyte-mediated antigen response at the basement membrane.²

Drug-induced hyperpigmentation is a side effect of several medications. One of these medications, hydroxyurea, has been largely implicated in the hyperpigmentation of nail beds and oral mucosa.³ Here we describe a case of a woman in whom hydroxyurea treatment resulted in the development of widespread blue-gray macules resembling ashy dermatosis.

CASE REPORT

A 56-year-old woman with Fitzpatrick type 3 skin and a history of essential thrombocythemia (ET) presented to the dermatology clinic for evaluation of a rash 9 months after onset. Her ET was previously managed with increasing doses of hydroxyurea. She started on 500 mg of hydroxyurea in 2016 for 1 year, which was subsequently increased to 1000 mg for another year. In September of 2018, her dose was

Abbreviations used:

ET: essential thrombocythemia
FM: Fontana-Masson

further increased to 1500 mg. Nine months later, she transitioned to anagrelide because of elevated liver function tests and the development of an erythematous lichenoid rash (Fig 1, A). The rash began on her face but progressed caudally toward her legs over the course of a few months. It subsequently developed blue-gray pigmentation but remained otherwise asymptomatic. She had no history of cutaneous manifestations of ET, thrombotic events, or concurrent usage of medications known to cause hyperpigmentation. Prior workup with other physicians failed to identify any medical causes of her hyperpigmentation.

Physical examination found an otherwise healthy woman with widespread gray-blue macules coalescing into patches with faint hypopigmented borders on the forehead, neck, chest, arms, hands, back, and legs (Fig 1, B to D). There was sparing of the palmar, ungual, perioral, and mucocutaneous surfaces. Lesions were most prominent on the upper extremities and back, with gradual tapering toward the bilateral legs. Dermoscopy found small gray granules present within the lesions.

Punch biopsies obtained from her left upper extremity and right upper back (Fig 1, B and C) found melanophages and melanin pigment in the superficial reticular dermis with subtle vacuolar

From the Departments of Dermatology^a and Pathology^c and the Medical Scientist Training Program,^b University of Texas Southwestern Medical Center.

Funding sources: None.

Conflicts of interest: None disclosed.

Correspondence to: Lu Q. Le, MD, PhD, Professor of Dermatology, Simmons Comprehensive Cancer Center, Hamon Center for Regenerative Science and Medicine, UT Southwestern Medical Center, 5323 Harry Hines Blvd., Dallas, Texas 75390-9069. E-mail: lu.le@utsouthwestern.edu.

JAAD Case Reports 2020;6:797-800.

2352-5126

© 2020 by the American Academy of Dermatology, Inc. Published by Elsevier, Inc. This is an open access article under the CC BY-NC-ND license (<http://creativecommons.org/licenses/by-nc-nd/4.0/>).

<https://doi.org/10.1016/j.jdc.2020.06.030>

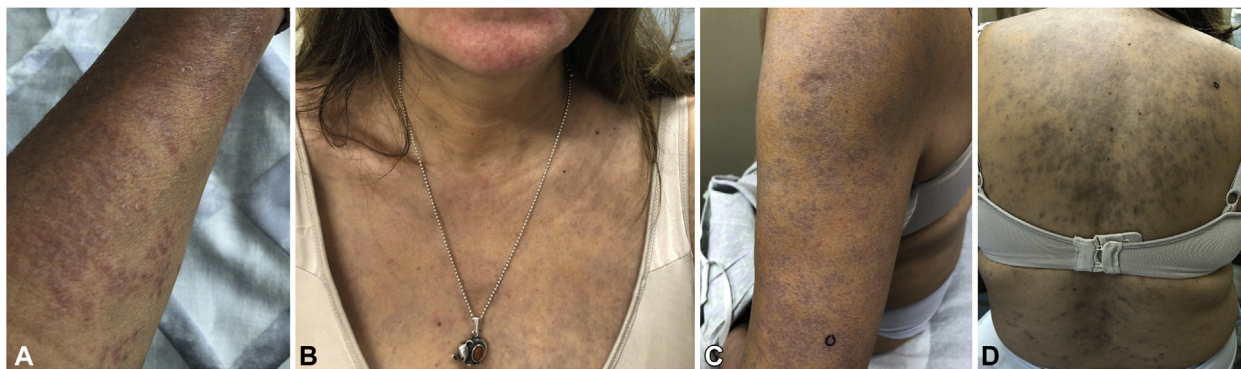

Fig 1. Clinical images. **A**, Photo from early in the course of the rash. Numerous violaceous papules and plaques resembling a lichenoid eruption. **B to D**, Numerous scattered coalescing blue-gray macules on the chest, left arm, and back of a patient with hydroxyurea-induced ashy dermatosis. Biopsy sites were marked with a surgical pen (**C** and **D**).

degeneration and mild lymphocytic infiltration (Fig 2, A and B). The pigment stained positive for melanin with Fontana-Masson (FM) but not for hemosiderin with Perls Prussian blue (Fig 3, A and B), compatible with a late presentation of ashy dermatosis. After a discussion of the biopsy results and treatment options, the patient declined further treatment and opted to monitor the lesion.

DISCUSSION

Ashy dermatosis shares similar and distinct features with erythema dyschromicum perstans and lichen planus pigmentosa. These disorders were recently classified together within the spectrum of acquired macular pigmentation of uncertain etiology by a global consensus forum because of their significantly overlapping features.¹ Although subtle variations in clinical presentation exist among these entities, they share histologic features of lichenoid changes,¹ suggesting the role of the immune system in precipitating the classic hyperpigmentation. Consistent with these histopathologic features, ashy dermatosis has been associated with infections by parasites, enterovirus, hepatitis C, and HIV.¹ These viruses may result in infiltration of CD8⁺ T cells into the dermoepidermal junction, where they persist as a stable population.⁴ Subsequent exposure of CD8⁺ T cells to exogenous stimuli such as medications or self-antigens may trigger an autoimmune reaction resulting in pigment incontinence that is characteristic of lichenoid diseases.⁴

The 3 classical types of drug-induced hyperpigmentation have been described in the context of minocycline-induced hyperpigmentation. Clinically, type 1 presents as a blue-black rash on areas of prior inflammation, type 2 as a blue-gray rash on normal skin, and type 3 as a brown rash on sun-exposed

areas.⁵ Further histologic classification of these forms is dependent on their positivity for FM (representing melanin) and Perls staining (representing iron deposition and hemosiderin). Type 1 lesions are FM negative/Perls positive, type 2 lesions are FM positive/Perls positive, and type 3 lesions are FM positive/Perls negative.⁵ In the case of our patient, her rash presented clinically as a type 2 but histologically as a type 3. Coexistence of clinical and histopathologic features from 2 different types has been reported in context of minocycline-induced hyperpigmentation in the treatment of leprosy.⁶

Hydroxyurea-induced skin changes have classically presented as skin atrophy, blue-gray nail hyperpigmentation, and oral mucosal hyperpigmentation.³ In the context of nail hyperpigmentation, histology shows pigment that is FM positive/Perl negative,⁷ similar to our patient. However, our patient did not exhibit nail hyperpigmentation consistent with classical hydroxyurea-induced pigmentary changes. A more recent case identified a patient who had well-demarcated confluent patches of the distal lower extremities after taking hydroxyurea.⁸ Histopathologic analysis found that the pigment was FM negative/Perl positive, indicating iron deposition.⁸ In contrast, the pigment from our patient's lesion was FM positive/Perl negative, implicating melanin as the source of hyperpigmentation. Our patient's early photos showed a lichen planus–like eruption with later biopsy finding additional histologic features consistent with late-presenting ashy dermatosis, suggesting that hydroxyurea can cause a drug-induced lichenoid reaction. Several other drugs have also been associated with an ashy dermatosis–like reaction.^{9,10} Although the exact mechanism and etiology of ashy dermatosis is unknown, the presence of

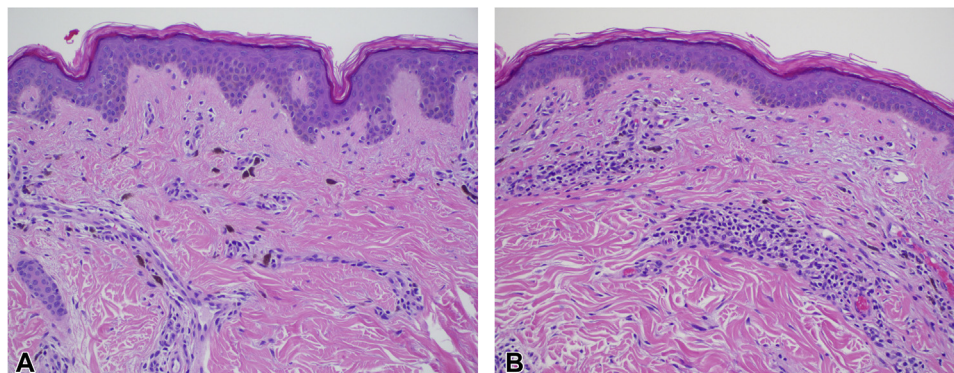


Fig 2. Hematoxylin-eosin histology of punch biopsies. **A** and **B**, Unremarkable epidermis with orthokeratosis overlying orderly keratinocyte maturation. The papillary dermis has subtle vacuolar degeneration and melanin pigment with mild lymphocytic infiltrate and mild solar elastosis. (Hematoxylin-eosin stain; original magnification: $\times 200$.)

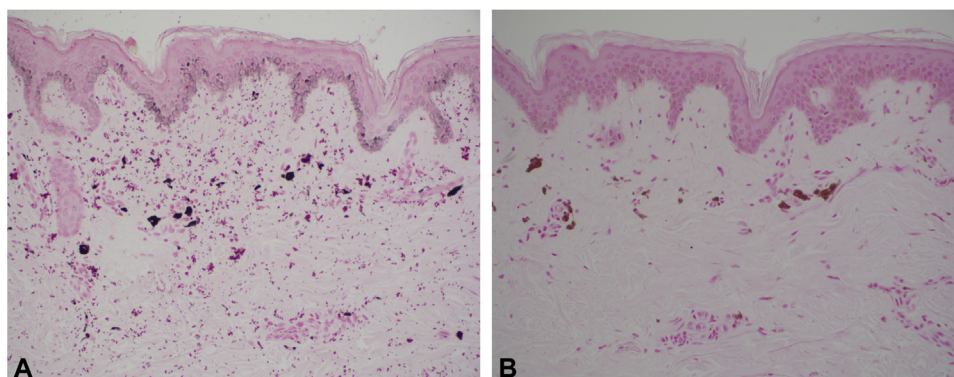


Fig 3. Histologic staining for melanin and hemosiderin. **A**, FM staining is positive for melanin pigment. **B**, Perls iron staining is negative for hemosiderin. (Original magnifications: **A** and **B**, $\times 200$.)

pigmentary incontinence, dermal melanophages, and $CD8^+$ T lymphocytes^{2,4} suggests that drug-induced antigen sensitization plays an important role.

Ashy dermatosis is classically asymptomatic, with cosmesis being the primary concern. In the case of our patient, further treatment outside of discontinuing hydroxyurea was declined. For patients who do seek treatment, clofazimine appears most successful.⁹ Additional treatment options include tacrolimus, dapsone, narrow-band ultraviolet B light, and isotretinoin.⁹ In summary, we report the case of an ashy dermatosis-like reaction in the context of hydroxyurea treatment. This case highlights a unique presentation and mechanism of hydroxyurea-induced pigmentary changes with the corresponding histopathologic correlates. Furthermore, our case adds further evidence to the growing body of literature suggesting a drug-induced autoimmune reaction may be one of the

inciting events for the development of ashy dermatosis.

We thank the patient for allowing us to publish this information.

REFERENCES

1. Kumarasinghe SPW, Pandya A, Chandran V, et al. A global consensus statement on ashy dermatosis, erythema dyschromicum perstans, lichen planus pigmentosus, idiopathic eruptive macular pigmentation, and Riehl's melanosis. *Int J Dermatol*. 2019;58:263-272.
2. Vasquez-Ochoa LA, Isaza-Guzman DM, Orozco-Mora B, Restrepo-Molina R, Trujillo-Perez J, Tapia FJ. Immunopathologic study of erythema dyschromicum perstans (ashy dermatosis). *Int J Dermatol*. 2006;45:937-941.
3. Kennedy BJ, Smith LR, Goltz RW. Skin changes secondary to hydroxyurea therapy. *Arch Dermatol*. 1975;111:183-187.
4. Shiohara T, Mizukawa Y. The immunological basis of lichenoid tissue reaction. *Autoimmun Rev*. 2005;4:236-241.
5. Geria AN, Tajirian AL, Kihiczak G, Schwartz RA. Minocycline-induced skin pigmentation: an update. *Acta Dermatovenerol Croat*. 2009;17:123-126.

6. Hu SW, Robinson MR, Newlove T, Meehan S, Levis WR, Patel RR. Minocycline-induced hyperpigmentation in multibacillary leprosy. *Am J Dermatopathol*. 2012;34:e114-e118.
7. Gropper CA, Don PC, Sadjadi MM. Nail and skin hyperpigmentation associated with hydroxyurea therapy for polycythemia vera. *Int J Dermatol*. 1993;32:731-733.
8. Lee KP, Vangipuram RK, Klimas NK, Sanyal S, Koshelev MV. Hydroxyurea-induced hyperpigmentation with iron deposition. *Dermatol Online J*. 2019;25:9.
9. Nguyen K, Khachemoune A. Ashy dermatosis: a review. *Dermatol Online J*. 2019;25.
10. Lertpichitkul P, Wititsuwannakul J, Asawanonda P, Rerknimitr P. Osimertinib-associated ashy dermatosis-like hyperpigmentation. *JAAD Case Rep*. 2020;6:86-88.