

Giant cemento-ossifying fibroma of the mandible

**Raghavendra
Mahadev Naik,
Yadavalli Guruprasad¹,
Sujatha D,
Shubha Gurudath,
Anuradha Paj²,
Suresh KV³**

Department of Oral Medicine and Radiology, Vishnu Dental College and Hospital, Bhimavaram, Andhra Pradesh, ²Oxford Dental College and Hospital, Bangalore, Karnataka, ³Krishna School of Dental Sciences, Karad, Maharashtra, ¹Department of Oral and Maxillofacial Surgery, AME'S Dental College Hospital and Research Centre, Raichur, Karnataka, India

Address for correspondence:

*Dr. Yadavalli Guruprasad, Department of Oral and Maxillofacial Surgery AME'S Dental College Hospital and Research Centre Raichur - 584 103, Karnataka, India.
Email: guru_omfs@yahoo.com*

Abstract

Cemento-ossifying fibroma (COF) is classified as a fibro-osseous neoplasm and included among the non-odontogenic tumors derived from the mesenchymal blast cells of the periodontal ligament, with a potential for forming fibrous tissue, cementum and bone, or a combination of such elements. These are slow-growing lesions, and are more frequent in women between the third and fourth decades of life. Case reports of massive expansile COF, measuring more than 10 cm are rarely reported in the literature. We report a case of giant cemento-ossifying fibroma of the mandible in a 34 year old female patient.

Key words: Cemento-ossifying fibroma, computed tomography, expansile lesion, fibro-osseous lesions, mandible

INTRODUCTION

In 1872, Menzal described a variant of ossifying fibroma, calling it a cemento-ossifying fibroma (COF).^[1] COF is a well-demarcated and occasionally encapsulated neoplasm

that contains fibrous tissue and varying amounts of calcified tissue resembling bone, cementum, or both. Ossification of this material is rare and woven bone is predominant. This neoplasm occurs in patients of a wide age range of third and fourth decades of life. Female-to-male ratio as high as

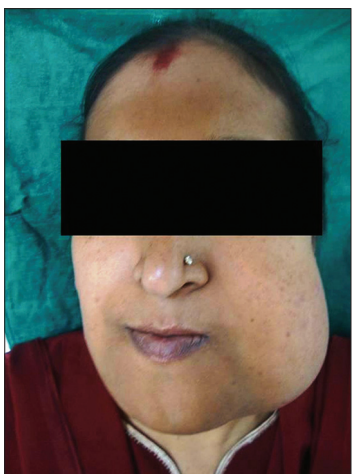

Figure 1: Frontal view of the patient showing a well defined swelling on left side and diffuse swelling on the right side of the mandible

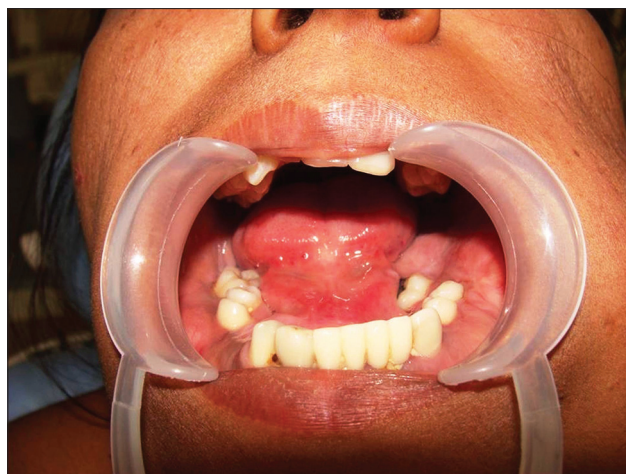

Figure 2: Intra-oral photograph shows an expansile swelling of the mandible with complete bucco-lingual cortical plate expansion and lingually displaced teeth

5:1, indicates a definite female proclivity. The mandibular premolar-molar area is the most common site.^[2]

In 1971 the World Health Organization (WHO) classified four types of cementum containing lesions: Fibrous dysplasia, ossifying fibroma, cementifying fibroma and cemento-ossifying fibroma. The second WHO classification, divided benign fibro-osseous lesions in the oral and maxillofacial regions into two categories; osteogenic neoplasm and non-neoplastic bone lesions. COF belongs to the former category.^[3]

Clinically, certain characteristics are true for entire group of fibro-osseous lesions. Slow growth and lack of symptoms are the cardinal features; pain or paraesthesia may be elicited if pressure on an adjacent nerve ensues. Large lesions may exhibit buccal and lingual plate expansion. Teeth in association with the lesion retain their vitality and as a rule, there is no associated root resorption.^[4] The term 'giant ossifying fibroma' is used for large lesions increasing in size to over 80 mm in their greatest diameter.^[5] Although some cases of COF have been reported with massive expansile lesions, lesions measuring more than 10 cm are rare. This case report details a remarkable massive expansile lesion involving the mandible in a 34 year old female patient.

CASE REPORT

A 34 year old female patient reported to Department of Oral Medicine and Radiology, with a chief complaint of swelling of the lower jaw since six years. She stated that a small swelling on the left side of jaw was noticed six years ago, measuring about 1cm in diameter, which gradually increased to the present size, involving both sides of the face. There were no subjective symptoms, except for difficulty in chewing food.

Gross facial asymmetry was noticed due to a swelling involving the middle and lower one third region of the face [Figure 1]. Bilaterally fullness of the cheeks and lower lip with obliteration of the mentolabial sulcus and nasolabial fold was noticed. A well demarcated swelling was noticed over the left cheek region and a diffuse swelling over the right side, which extended from the left ramus of the mandible to the right body of the mandible with obliteration of inferior border of the mandible. Swelling on the left side was roughly ovoid in shape, measuring about $8 \times 6 \times 5$ cm^[3]. Skin over the swelling was stretched. On palpation the swelling is hard in consistency, lobulated and nontender; with no accompanying cervical lymphadenopathy.

On intraoral examination [Figure 2], a diffuse swelling was seen extending from the left to right retromolar region. Bilaterally, vestibular obliteration was noticed due to buccal labial and lingual cortical plate expansion with normal appearing mucosa. Swelling was hard, lobulated and nontender. Correlating the history and clinical findings, a provisional diagnosis of benign fibro-osseous lesion of mandible was given and differential diagnosis of fibrous dysplasia, ossifying/cementifying fibroma and central giant cell granuloma (non-aggressive lesion) was given. Patient was further subjected to hematological, radiological and histopathological investigations. Routine hematological examination, serum protein, calcium, phosphorus and alkaline phosphatase levels were estimated and the values obtained were within the normal range.

Panoramic radiograph [Figure 3] revealed a well defined mixed radiopaque and radiolucent lesion, extending from left ramus region to the right angle of the mandible, measuring about 11×7 cms. Internal architecture exhibited a cotton-wool pattern of calcification. Centrifugal growth

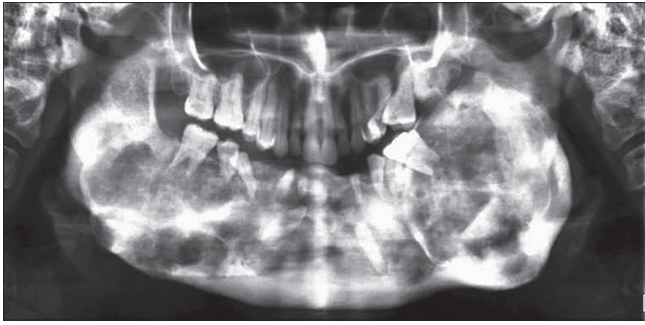


Figure 3: Orthopantomogram reveals a massive high density, mixed radiopaque-radiolucent lesion exhibiting cotton –wool appearance. Demarcation between the lesion and normal bone with bowing of the inferior border of mandible is appreciable

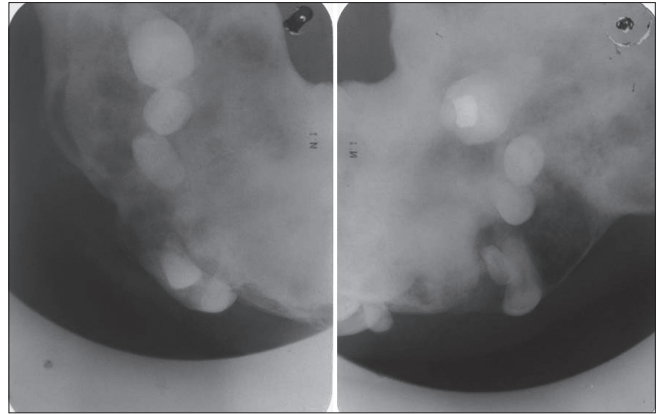


Figure 4: Lower occlusal radiograph shows irregular bucco- lingual cortical plate expansion

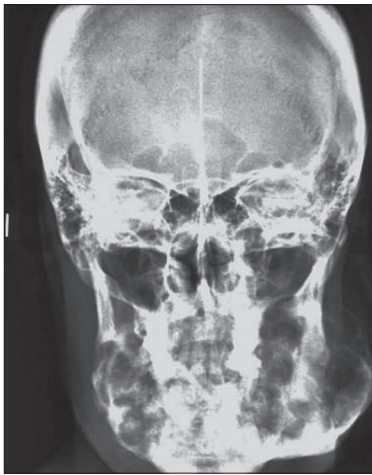


Figure 5: Posterior Anterior mandible view reveals an expansile mixed radiolucent radiopaque lesion extending from the ramus of left side to the right angle of the mandible

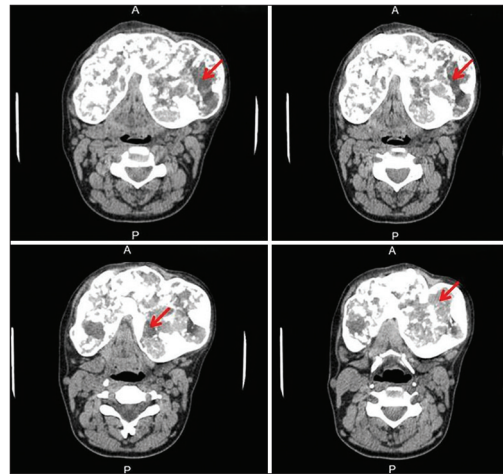


Figure 6: Axial CT scan view shows a large lobulated bone density mass involving both right and left body and left ramus of mandible, which exhibits mixed sclerotic and lucent areas. Central low-density areas (arrow) are seen

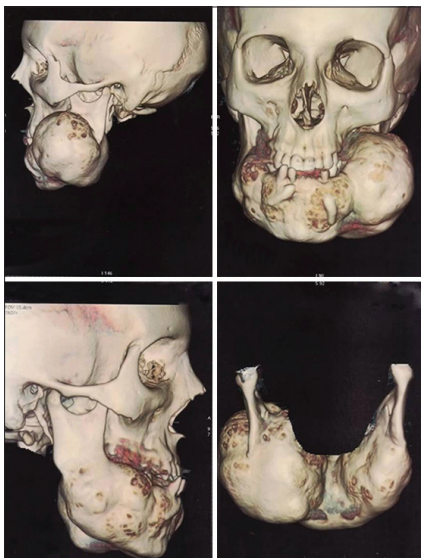

Figure 7: Image of 3D-CT scan shows a large expansile swelling within the mandible, which involves both right and left body and left ramus of mandible, which exhibits mixed sclerotic and lucent areas measuring 11.8 × 7.0 × 7.3 cm³

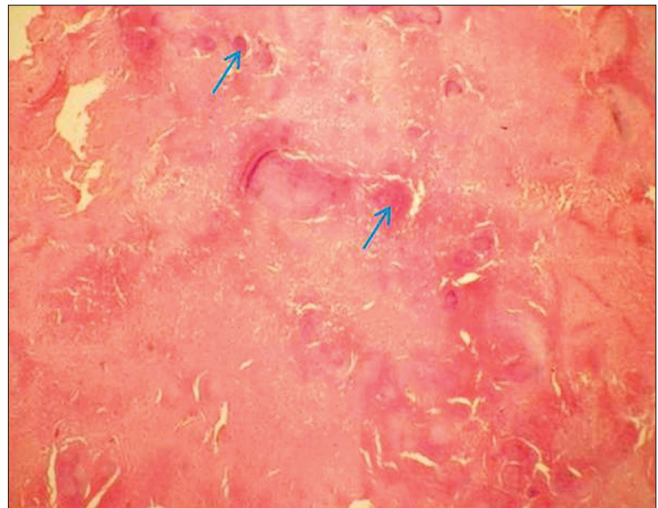


Figure 8: Photomicrography shows several spherical masses of a cellular calcified material resembling cementum were seen throughout the fibrous tissue (H and E stain x250)

fashion is appreciable, which causes a ball-like circular lesion and bowing of the inferior border of mandible. The inferior cortex is parallel to the tumor mass above with no evidence of erosion. Occlusal radiograph [Figure 4], revealed irregular expansion of both bucco-lingual cortical plates and lingual displacement of involved teeth. Posterior-Anterior (PA) mandible view [Figure 5] revealed a mixed radiopaque, radiolucent lesion involving the left ramus region and extending up to the right angle of the mandible.

Plain axial view and 3D-CT scan [Figures 6 and 7] revealed a large expansile lesion within the mandible, which involves right and left body and left ramus of mandible, which exhibits mixed sclerotic and lucent areas measuring $11.8 \times 7.0 \times 7.3$ cm.^[3]

An incisional biopsy was performed and the tissue was sent for histopathological evaluation [Figure 8] which irregularly shaped bony trabeculae interspersed in connective tissue stroma which is fibrocellular. Trabeculae contains osteocytes in lacunae within them. Several spherical masses of a cellular calcified material resembling cementum were seen through the fibrous tissue. Fibroblasts in the stroma are numerous and spindle shaped with prominent nuclei which were suggestive of cemento- ossifying fibroma. Based on clinical, radiographic and histopathological findings a final diagnosis of giant cemento-ossifying fibroma of the mandible was made.

DISCUSSION

The origin of COF is thought to be the periodontal membrane which harbors the potential for elaboration of both bone and cementum. Bernier and Thompson speculated that infection with resulting inflammation and fibrosis of the periapical area might stimulate the periodontal membrane. After trauma, such as tooth extraction, the remaining periodontal tissue that is attached to the wall of the alveolus may serve as the origin of COF. Several rare cases outside the mandible and maxilla have been reported. The current theories regarding their origin include traumatic and developmental causes.^[2,3] Cakir and Karadayi suggested that nasopharyngeal COF originated from embryologic nests.^[6] Brademann *et al.* explained that ectopic periodontal membrane differentiated from primitive mesenchymal cells in the petrous bone may serve as a cause of development of COF in this area and that trauma such as severe whiplash may be a factor in the induction of proliferation of COF.^[7]

Cytogenic and cario typing analysis on COF was performed by Gollin *et al.* 1992 and discovered three translocations

responsible for it. His research showed G protein mutation; located in chromosome number 13 and was further investigated for three types of fibro- osseous lesions (FD, COF, and FCOD) to see if this mutation has a diagnostic value. The pathologic nature of COF is not yet clearly understood. A close histogenetic relationship exists between the central COF and the central ossifying fibroma. The only difference between the two is that, in COF, there is cementum formation along with bony trabeculae; this cementum is not seen in ossifying fibroma.^[8]

The late Charles Waldron wrote “In absence of good clinical and radiologic information a pathologist can only state that a given biopsy is consistent with a FOL”. Therefore, the diagnosis of the majority of histopathologically proven FOLs affecting the jaws is made upon clinical and radiological features.^[9] Radiologically, depending on degree of mineralization these tumors may present a number of patterns. Two basic patterns are, one characterized by the presence of a unilocular or multilocular radio transparent image and another showing mixed density due to a variable internal amount of radiopaque material. Margins of the lesion are relatively well defined with peripheral osteocondensation zone. The appearance of fibroma is concentric within the medullary zone of the bone and the cortical layers are preserved. Root reabsorption and displacement of the roots of the neighboring teeth is seen in some cases.^[10]

Slootweg and Muller described an objective of marginal definition; a lesion with zone of transition of less than 1 mm can be considered to be well defined. This can be quickly and cheaply appreciated on plain film radiographs. The first edition of the WHO classification was clear that FD and COF can be distinguished by radiology, in which the former has a poorly defined margin, whereas the latter has a well defined margin. The well-defined border of the COF helps differentiate it from the aggressive sarcomas and carcinomas.^[10,11]

Treatment of COF generally is conservative enucleation/ curettage or radical surgery. Conservative surgery is recommended even if the tumor is large with bowing and erosion of the inferior border of the mandible. En bloc resection of the tumor should only be considered as radical treatment, if there are recurrences due to its aggressive nature. Advantages for treating large COF conservatively are, there is minimal morbidity after surgery, good bone formation and consolidation, no loss of sensation and no bone graft required from a second surgical site. In long term follow-up cases where bowing or contours formed by these large lesions do not disappear completely with time, surgical intervention such as aesthetic re-contouring of the bone

may then be taken into consideration.^[5,10] In the current case, total mandibulectomy without disarticulation was performed and reconstructed with the tibial graft from tibia was placed. Considering the patient's young age, aesthetic facial features and to improve the contour of the mandible, a further cosmetic operation was considered after resection of the mandible. A good result in regard to cosmetic and functional deformity was achieved by using this approach for a large ossifying fibroma, resulting in a fair prognosis. Recurrence rate of COF after surgical removal seems to be unusual. Radiotherapy is contraindicated because of its radioresistance and post radiation complications.^[5,10]

CONCLUSION

Cemento-ossifying fibroma of the jaw is a benign fibro-osseous lesion with a significant growth potential. They are generally asymptomatic and may be present for years before discovery. Thus, it is not always easy to diagnose and manage these lesions because of their clinical, radiographic and histological criteria's, which often overlap causing confusion to clinicians, radiologists, pathologists and oral surgeons.

REFERENCES

1. Sarwar HG, Jindal MK, Ahmad SS. Cemento-ossifying fibroma-a rare case. *J Indian Soc Pedod Prevent Dent* 2008;26:128-31.
2. So Lyung Jung, Kyu Ho Choi, Young Ha Park, Hyun Chul Song, Mi Seon Kwon. Cemento-Ossifying Fibroma Presenting as a Mass of the Parapharyngeal and Masticator Space. *Am J Neuroradiol* 1999;20:1744-6.
3. Y Liu¹, M You¹, H Wang, Z Yang¹, J Miao, K Shimizutani, *et al.* Ossifying fibromas of the jaw bone: 20 cases. *Dentomaxillofacial Rad* 2010;39:57-63.
4. Y Liu¹, M You¹, H Wang, Z Yang¹, J Miao, K Shimizutani, *et al.* Ossifying fibromas of the jaw bone: 20 cases. *Dentomaxillofacial Rad* 2010;39:57-63.
5. Godhi S, Goyal S, Giraddi G, Goyal S. Cementifying Fibroma of the mandible- A Case Report. *J Oral Health Comm Dent* 2008;2:42-5.
6. Ong AH, Siar CH. Cemento-ossifying fibroma with mandibular fracture-Case report in a young patient. *Aus Dent J* 1998;4:229-33.
7. Cakir B, Karadayi N. Ossifying fibroma in the nasopharynx. A case report. *Clin Imag* 1991;15:290-2.
8. Brademann G, Werner JA, Janig U, Mehdorn HM, Rudert H. Cemento-ossifying fibroma of the petromastoid region. Case report and review of the literature. *J Laryngol Otol* 1997;111:152-5.
9. Desai D, Arathi K, Ahmed S, Rai N. Bilateral Cemento Ossifying Fibroma of Mandible. *Ind J Dent Adv* 2010;2:371-4.
10. MacDonald-Jankowski DS, Li TK. Ossifying fibroma in a Hong Kong community: Clinical and radiological features and outcomes of treatment. *Dentomaxillofacial Rad* 2009;38:514-23.
11. JavierSilvestre-Rangil, FranciscoJavierSilvestre, JuanRequeni-Bernal. Cemento-ossifying fibroma of the mandible: Presentation of a case and review of the literature. *J Clin Exp Dent* 2011;3:e66-9.

How to cite this article: Naik RM, Guruprasad Y, Sujatha D, Gurudath S, Pai A, Suresh KV. Giant cemento-ossifying fibroma of the mandible. *J Nat Sc Biol Med* 2014;5:190-4.

Source of Support: Nil. **Conflict of Interest:** None declared.

Access this article online

Quick Response Code:



Website:

www.jnsbm.org

DOI:

10.4103/0976-9668.127326