



Case Report

A Case Report: Neonatal Torsional Ovarian Cyst

Duygu Besnili Acar,¹ Evrim Kıray Baş,¹ Ali Bülbül,¹ Mesut Demir,² Sinan Uslu¹

¹Department of Neonatal, Istanbul Health Sciences University, Sariyer Hamidiye Etfal Training and Research Hospital, Istanbul, Turkey

²Department of Pediatric Surgery, Istanbul Health Sciences University, Sariyer Hamidiye Etfal Training and Research Hospital, Istanbul, Turkey

Abstract

The majority of abdominal masses detected in the neonatal period are benign (85%) and usually originate in the urinary tract (50%), genital system (15%), gastrointestinal system (15%), or the hepatobiliary tract (5%). Ovarian cysts comprise one-third of the masses with a genital origin. Presently described is a case of an ovarian cyst that developed during the antenatal period and transformed into a hemorrhagic cystic mass as a result of torsion. A female infant born at 37 weeks of gestation with the prediagnosis of nephroma was admitted to the neonatal intensive care unit. Abdominal ultrasonography revealed a smooth cystic mass approximately 50x45x35 mm in size in the left upper quadrant that was not associated with the kidney. Magnetic resonance imaging revealed a 55x44x49-mm cystic mass in the left adnexal region containing multiple septations that were not enhanced with contrast material, and the mass was then interpreted as a hemorrhagic fetal ovarian cyst. The left ovary, compromised by 2 full torsions, was removed during a laparoscopy performed on the postnatal seventh day. The infant was subsequently discharged without complications. It should be kept in mind that cystic masses detected in the prenatal period may be of ovarian origin. An appropriate follow-up and treatment should be planned according to the size of the ovarian cyst and the clinical findings.

Keywords: Complication; newborn; ovarian cyst.

Please cite this article as "Besnili Acar D, Kıray Baş E, Bülbül A, Demir M, Uslu S. A Case Report: Neonatal Torsional Ovarian Cyst. Med Bull Sisli Etfal Hosp 2019;53(4):430-432".

The majority of abdominal masses detected in the neonatal period are benign and related to the renal, genital, gastrointestinal, or hepatobiliary system, with decreasing frequency. Approximately 30% of genital masses are fetal ovarian cysts. Ovarian cysts are usually unilateral and represent the most common abdominal mass lesion in female fetuses.^[1] Fetal ovarian cysts are usually small and may be spontaneously resorbed without any complications. However, large ovarian cysts can develop torsion during the intrauterine period and may cause intra-abdominal hematoma.

The diagnosis of intra-abdominal masses in the early pe-

riod has been facilitated by the increase in routine ultrasonographic (US) follow-up in the prenatal period. Rupture of the ovary after torsion and conversion into a cystic hemorrhagic mass in the abdomen is a very rare condition. Presently described is a case of an abdominal cystic mass observed on prenatal ultrasonography (US) that was subsequently discovered to be a torsioned ovarian cyst in a postnatal examination.

Case Report

A female infant was born by cesarean section in the 37th gestational week to a healthy, 36-year-old father and a

Address for correspondence: Duygu Besnili Acar, MD. Istanbul Saglik Bilimleri Universitesi, Sariyer Hamidiye Etfal Egitim ve Arastirma Hastanesi, Yenidogan Kliniği, Istanbul, Turkey

Phone: +90 506 367 21 89 **E-mail:** dbesnili@hotmail.com

Submitted Date: October 31, 2018 **Accepted Date:** December 03, 2018 **Available Online Date:** November 26, 2019

©Copyright 2019 by The Medical Bulletin of Sisli Etfal Hospital - Available online at www.sislietfaltip.org

OPEN ACCESS This is an open access article under the CC BY-NC license (<http://creativecommons.org/licenses/by-nc/4.0/>).



healthy, 29-year-old mother (G1P1). The birth weight was 3250 g (50th-75th percentile), the length was 50 cm (50th-75th percentile), and the head circumference was 35 cm (50th-75th percentile). Due to a diagnosis of intra-abdominal cystic mass and nephroma made based on a prenatal US image, the patient was hospitalized in the neonatal intensive care unit for examination and treatment. The vital signs observed in the physical examination were stable, there was no pathology other than a soft palpable mass in the left lower quadrant of the abdomen. Laboratory examinations revealed hematological and biochemical test results within normal limits. An abdominal US revealed a well-circumscribed cystic mass, approximately 50x45x35 mm in size in the left upper quadrant not associated with the kidney. Magnetic resonance imaging (MRI) performed for a more detailed examination revealed a mass of 55x44x49 mm in the left adnexal region with a smooth contour and multiple septations. It was thought to be an antenatal hemorrhagic torsional ovarian cyst that did not demonstrate contrast enhancement (Fig. 1). Alfa-fetoprotein and beta-human chorionic gonadotropin levels, which were measured for possible ovarian tumor pathologies, were normal. A laparoscopic examination performed on the postnatal seventh day for further examination and treatment revealed that the right ovary was normal, but the left ovary was torsioned for 2 full turns, had no circulation, and the interior was hemorrhagic. Therefore, the mass was excised (Fig. 2). Pathological examination revealed full-thickness hemorrhagic infarction, a necrotic ovary, and tubal tissue. The infant was discharged on the 15th postnatal day without any complications observed during follow-up with good nutrition and maternal compliance. The patient was followed up in the neonatal outpatient clinic. Informed consent was obtained from the patient's family for presentation of this case.

Discussion

Fetal ovarian cysts may be revealed with US. They are typically simple cysts, thought to develop due to fetal gonadotropins, maternal estrogen, and placental human chorionic gonadotropins. They can go into spontaneous regression in the postnatal period and usually do not require surgical intervention.^[2, 3] The frequency has been reported to be 1 in 2500 live births.^[4]

Ovarian cysts are the most common cause of abdominal masses detected in female fetuses. It can, however, be confused with other intra-abdominal cystic masses. In a study of 29 patients with prenatal follicular ovarian cysts, postnatal US evaluation revealed 68.9% ovarian cysts, 13.7% urogenital sinus anomalies, 6.8% multicystic dysplastic kidney, 3.4% mesenteric cyst, 3.4% intestinal duplication, and 3.4% lymphangioma.^[5]

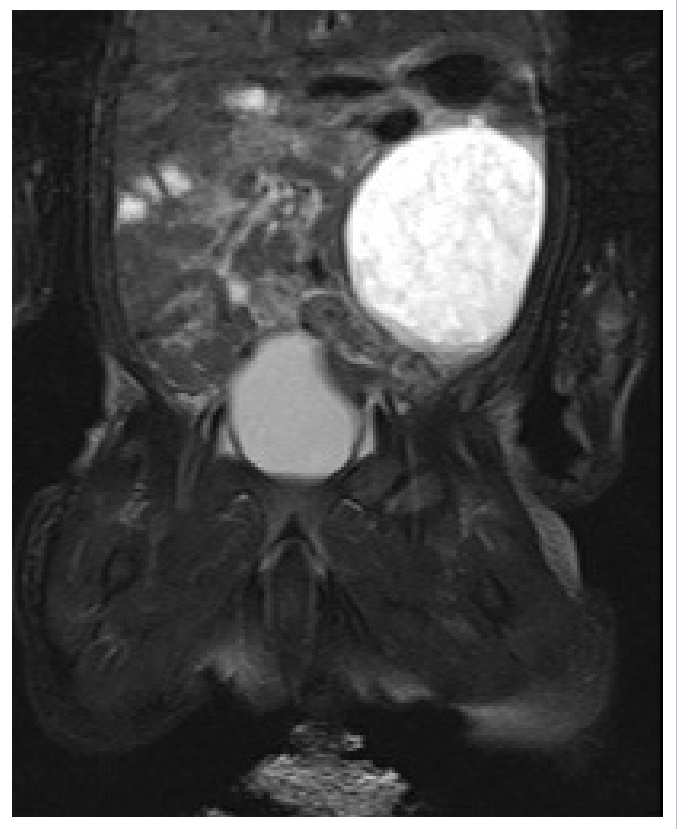


Figure 1. Magnetic resonance image of the mass.

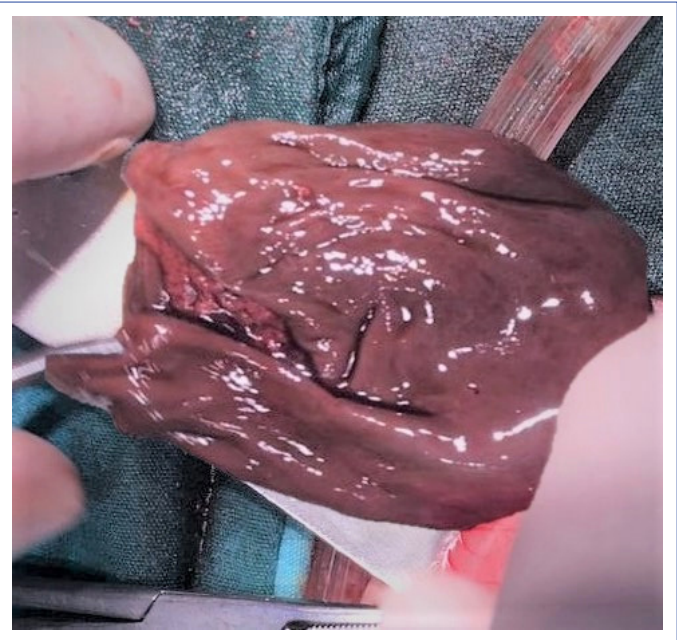


Figure 2. Image of the mass as seen during surgery.

In a meta-analysis examining the prognosis of ovarian cysts, it was reported that of 346 prenatally diagnosed ovarian cysts, 10% were spontaneously resorbed in the prenatal period and 36% in the postnatal period, for a total of 46% spontaneous resorption. In the same meta-analy-

sis it was reported that 90% of the spontaneous-resorbing cysts were <30 mm in size.^[6] In the present case, fetal US performed at 32 and 36 weeks of gestation revealed a 40x50x42 mm cystic mass that was thought to be of primarily renal origin and not ovarian origin. There was no decrease in the size of the cystic mass.

Follicular ovarian cysts are common in fetuses and newborns; however, in the presence of advanced maternal age, maternal diabetes, preeclampsia, or Rh isoimmunization, they may be seen more frequently.^[2, 7] The mother of our patient was 29 years old and did not have any concomitant disease.

In addition, rare cases of neonatal hypothyroidism have been reported in the literature.^[8] Thyroid function tests in the present case were within normal limits.

In ovarian cyst cases, complications such as intra-cystic hemorrhage, gastrointestinal obstruction, urinary tract compression, torsion and necrosis, and in cases of very large cysts, difficult delivery due to abdominal dystocia and respiratory distress due to diaphragm compression may be seen.^[9, 10] When an ovarian cyst becomes twisted during intrauterine life, it can develop necrosis and become a calcified free mass, or it may completely disappear. The frequency of torsion in fetal ovarian cysts with a size of >5 cm has been reported as 31%.^[11] In our patient, fetal ovarian torsion occurred and the ovary became a cystic mass with hemorrhage.

Close follow-up of antenatal ovarian cysts with US is important. It has been reported that large cysts between 40 and 60 mm in size can be aspirated during the intrauterine period and potential complications can be prevented.^[11] Although the cyst in our case was large during the antenatal period, aspiration was not performed because the mass was thought to be associated with the kidney.

Ovarian cysts should be followed up in the postnatal period at 4 to 6 week intervals with serial US until they are resorbed or symptomatic. Surgical removal is recommended for complex cysts, ovarian torsion, symptomatic patients, and cysts that do not regress in size by the sixth month. Our patient underwent surgery on postnatal day 7 to manage torsion that had developed in the intrauterine period.

Although antenatal ovarian cysts are located in the adnexal region, larger cysts can extend to the kidneys and may be confused with cystic kidney lesions. When an US image cannot be evaluated clearly, MRI may contribute to the differential diagnosis. In the prenatal follow-up of our case, cystic kidney pathology was the preliminary diagnosis and

MRI was performed for confirmation after the birth.

It should be kept in mind that cystic masses detected in the prenatal period may be ovarian cysts, and the appropriate follow-up and treatment should be planned according to the size of the ovarian cyst and the clinical findings.

Disclosures

Informed Consent: Written informed consent was obtained from the patient for the publication of the case report and the accompanying images.

Peer-review: Externally peer-reviewed.

Conflict of Interest: None declared.

Authorship Contributions: Concept – D.B.A., E.K.B.; Design – D.B.A.; Supervision – A.B., S.U.; Materials – D.B.A., M.D.; Data collection &/or processing – D.B.A., M.D.; Analysis and/or interpretation – E.K.B., A.B.; Literature search – E.K.B., D.B.A.; Writing – D.B.A., E.K.B.; Critical review – S.U., A.B.

References

1. Meizner I, Levy A, Katz M, Maresh AJ, Glezerman M. Fetal ovarian cysts: prenatal ultrasonographic detection and postnatal evaluation and treatment. *Am J Obstet Gynecol* 1991;164:874–8.
2. Bryant AE, Laufer MR. Fetal ovarian cysts: incidence, diagnosis and management. *J Reprod Med* 2004;49:329–37.
3. Özdilek B, Nalbantoğlu B, Donma MM, Çelik C, Paketçi C, Karasu E, et al. Yenidoğanda over kisti. *Çocuk Dergisi* 2013;13:36–9.
4. Sakala EP, Leon ZA, Rouse GA. Management of antenatally diagnosed fetal ovarian cysts. *Obstet Gynecol Surv* 1991;46:407–14.
5. Turgal M, Ozyuncu O, Yazicioglu A. Outcome of sonographically suspected fetal ovarian cysts. *J Matern Fetal Neonatal Med* 2013;26:1728–32.
6. Tyraskis A, Bakalis S, David AL, Eaton S, De Coppi P. A systematic review and meta-analysis on fetal ovarian cysts: impact of size, appearance and prenatal aspiration. *Prenat Diagn* 2017;37:951–8.
7. deSa DJ. Follicular ovarian cysts in stillbirths and neonates. *Arch Dis Child* 1975;50:45–50.
8. Jafri SZ, Bree RL, Silver TM, Ouimette M. Fetal ovarian cysts: sonographic detection and association with hypothyroidism. *Radiology* 1984;150:809–12.
9. Siegel MJ. Pediatric gynecologic sonography. *Radiology* 1991;179:593–600.
10. Armentano G, Dodero P, Natta A, Magillo P, Sugliano GC. Fetal ovarian cysts: prenatal diagnosis and management. Report of two cases and review of literature. *Clin Exp Obstet Gynecol* 1998;25:88–91.
11. Bagolan P, Giorlandino C, Nahom A, Bilancioni E, Trucchi A, Gatti C, et al. The management of fetal ovarian cysts. *J Pediatr Surg* 2002;37:25–30.