

## Oncology

# Primary Squamous Cell Carcinoma of Kidney Associated With Large Calculus in Non-functioning Kidney: A Case Report



Sanjay Kumar\*, Vinay Tomar, Sher S. Yadav, Hema Udawat, Shivam Priyadarshi, Nachiket Vyas, Neeraj Agarwal

S.M.S Medical College, Jaipur, Rajasthan, India

## ARTICLE INFO

## Article history:

Received 6 April 2016  
Accepted 13 April 2016

## Keywords:

Pyelolithotomy  
Squamous cell carcinoma  
Kidney  
Calculus

## ABSTRACT

Primary squamous cell carcinoma (SCC) of renal pelvis is a rare neoplasm. A 75-year old male presented with history of chronic dull aching pain in left flank region for last 10-years with history of left pyelolithotomy about 30-years back. After proper workup, large calculus with heterogeneous density mass detected in nonfunctioning left kidney. After radical nephrectomy, histopathological examination revealed squamous cell carcinoma of renal pelvis. SCC should be suspected in a patient with long history of renal calculus and associated mass in non functioning kidney.

© 2016 The Authors. Published by Elsevier Inc. This is an open access article under the CC BY-NC-ND license (<http://creativecommons.org/licenses/by-nc-nd/4.0/>).

## Introduction

Primary squamous cell carcinoma (SCC) of renal pelvis is a rare neoplasm, accounting for 0.5–0.8% of malignant renal neoplasm.<sup>1</sup> SCC of urinary tract is more frequently reported in urinary bladder and male urethra. Risk factors are renal calculi, infection, endogenous and exogenous chemicals, hormonal imbalance, radiotherapy and vitamin A deficiency.<sup>2</sup> We report a case of SCC of left renal pelvis associated with long standing large calculus and recent literature was reviewed.

## Case report

A 75-year old male presented with history of chronic dull aching pain in left flank region for last 10-years. There was a past history of left pyelolithotomy about 30-years back. There was no history of hematuria, significant weight loss or fever. General physical examination was unremarkable. All routine blood investigations were normal except serum creatinine (2 mg/dL). X-ray and ultrasonography (USG) of KUB region were suggestive of around 4 cm calculus in left kidney with hetero echoic mass in lower pole. NCCT of KUB region was suggestive of large 3.6 cm calculus in left renal pelvis and 1.2 cm calculus in left upper pole calyx along with large heterogeneous density lesion involving mid and lower pole of the kidney with perinephric fat stranding (Fig. 1). DTPA scan was suggestive of left non-

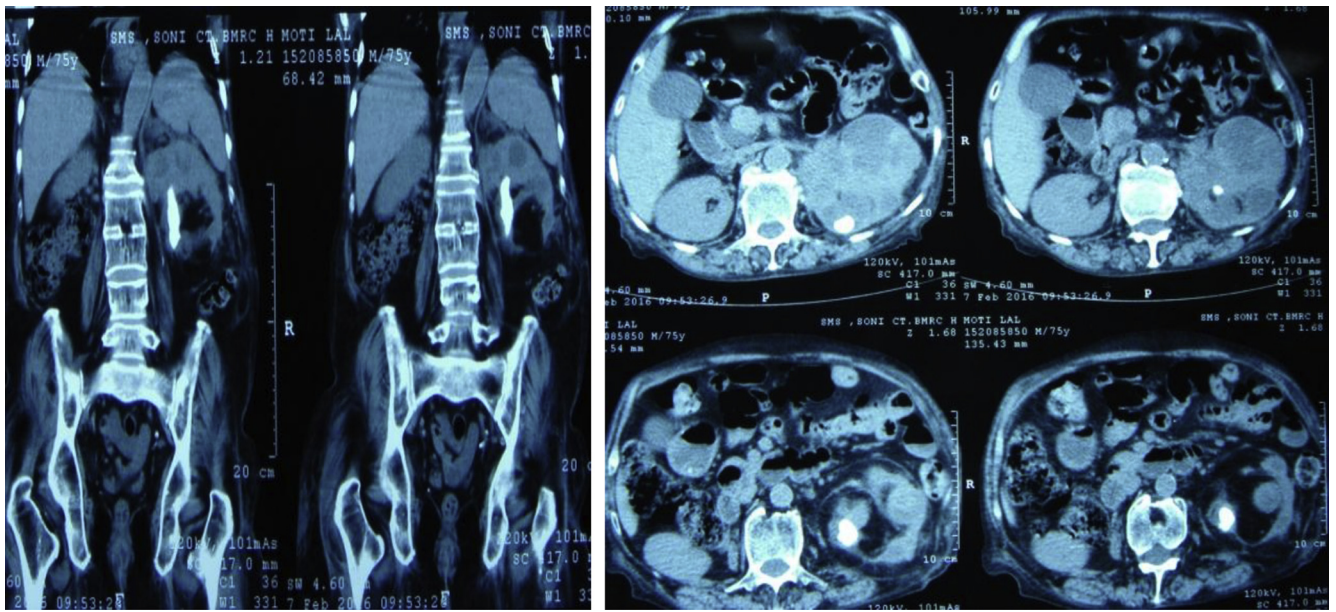
functioning kidney (GFR = 9 mL/min/1.73 m<sup>2</sup>). He underwent left radical nephrectomy. On cut section of the specimen, there were gray white solid growth involving the whole of renal parenchyma and stone in calyceal system noted (Fig. 2). Histopathological examination of the specimen revealed features of squamous cell carcinoma of renal pelvis with extensive involvement of renal parenchyma (Fig. 3). Sections from proximal and mid ureter were free from tumor. Patient was discharge on day 7 and kept on follow up. The patient remained disease free for 3 month post surgery and was lost to follow up then.

## Discussion

Squamous cell carcinoma of pelvicalyceal system with involvement of kidney is a very rare entity, however this diagnosis should be included in the differential diagnosis when evaluating a renal mass that is associated with renal calculi. In comparison to other upper urinary tract malignancies, these tumors are highly aggressive in nature and are usually present at an advanced stage when detected and have a poor prognosis.<sup>3</sup> The predisposing factors which play in the genesis of this rare malignancy are renal calculi, infections, exogenous and endogenous chemicals (eg.-arsenic), prior history of renal stone surgery, analgesic abuse, radiotherapy and vitamin A deficiency.<sup>2</sup> There is development of urothelial metaplasia resulting from a reaction to chronic irritation, which further progresses to dedifferentiation, dysplasias, and in the end to an SCC. In our case, we have speculated that the tumor has arisen in a chronically inflamed hydronephrotic pelvis with long term irritation by large calculi.

\* Corresponding author. Tel.: +91 9958873573.

E-mail addresses: [sankum10@yahoo.co.in](mailto:sankum10@yahoo.co.in), [drsanjay19kumar@gmail.com](mailto:drsanjay19kumar@gmail.com) (S. Kumar).



**Figure 1.** NCCT KUB showing hydronephrotic kidney with calculus in left renal pelvis and upper pole calyx along with ill defined heterogeneous density lesion involving mid and lower pole.

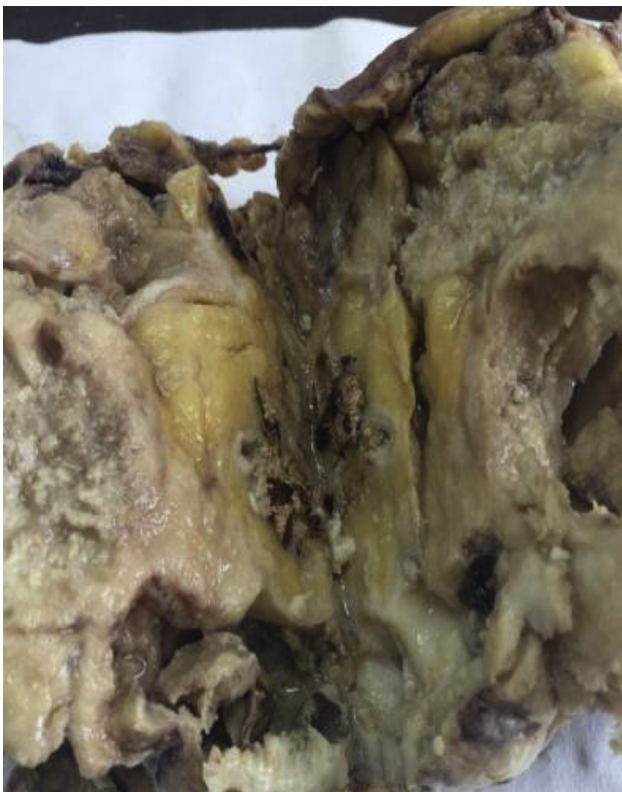Mode of presentation in patients with renal SCC is usually dull aching flank pain, hematuria, fever, weight loss or with paraneoplastic syndrome.<sup>2</sup> In our patient the only presenting feature is dull aching left flank pain.

There is relatively equal gender distribution and most common age of presentation is late adulthood.<sup>4</sup>

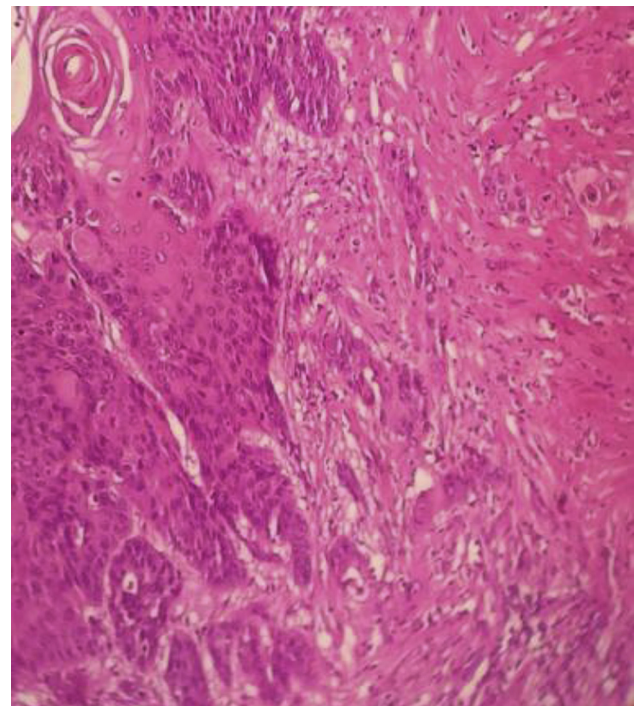
Diagnosis of SCC by current available imaging modality is difficult due to lack of any specific radiological feature. Therefore diagnosis

of the renal SCC is usually made after surgical resection and histological analysis of resected specimen as was seen in present case.<sup>5</sup>

Due to extreme rarity of the tumor, there is no any standard guideline for the management, however radical nephrectomy may be curative if the disease is localized.<sup>4</sup> Renal SCC is aggressive tumor, most cases usually present at an advanced stage. Therefore, for the treatment of advanced disease, a multidisciplinary approach including surgical treatment along with adjuvant chemotherapy and radiotherapy should be applied, but poor response to surgery, radiotherapy and chemotherapy is the norm, resulting in short survival periods for the most of the cases.<sup>5</sup>



**Figure 2.** Showing cut section of kidney with stone in calyceal system with gray white solid growth involving whole renal parenchyma.



**Figure 3.** Section showing nests and pearl of squamous cell carcinoma (SCC), H&E (50 $\times$ ).

## Conclusion

Any patient presenting with long history of renal calculus with solid component in non-functioning kidney should undergo careful diagnostic workup. Surgical management should be done as early as possible and during surgery possibility of SCC should always be kept in mind.

## Conflict of interest

No conflict of interest.

## References

1. Li MK, Cheung WL. Squamous cell carcinoma of the renal pelvis. *J Urol*. 1987;138(2):269–271.
2. Bandyopadhyay R, Biswas S, Nag D, et al. Squamous cell carcinoma of the renal pelvis presenting as hydronephrosis. *J Cancer Res Ther*. 2010;6:537–539.
3. Berz D, Rizack T, Weitzen S, et al. Survival of patients with squamous cell malignancies of the upper urinary tract. *Clin Med Insights Oncol*. 2012;6:11–18.
4. Holmang S, Lele SM, Johansson SL, et al. Squamous cell carcinoma of the renal pelvis and ureter: incidence, symptoms, treatment and outcome. *J Urol*. 2007;178(1):51–56.
5. Jiang P, Wang C, Chen S, et al. Primary renal squamous cell carcinoma mimicking the renal cyst: a case report and review of the recent literature. *BMC Urol*. 2015. <http://dx.doi.org/10.1186/S12894-015-0064-Z>.