

Available online at www.sciencedirect.com

ScienceDirect

journal homepage: www.elsevier.com/locate/radcr

Case Report

Acute necrotizing encephalopathy in an infant: A case report ☆,☆☆

Elisamia Ngowi^{a,b,*}, Zeenat Juneja^{a,b}, Jacqueline Gabone^c, Maria Bulimba^{a,b},
Mohamedraza Ebrahim^{a,b}, Yaser Abdallah^{a,b}

^a Department of Paediatrics and Child Health, Aga Khan Hospital Tanzania, Dar Es Salaam 2289, Tanzania

^b Department of Paediatrics and Child Health, Aga Khan University, Dar Es Salaam 38129, Tanzania

^c Department of Radiology, Aga Khan Hospital, Dar Es Salaam 2289, Tanzania

ARTICLE INFO

Article history:

Received 18 September 2024

Revised 27 September 2024

Accepted 28 September 2024

Keywords:

Acute necrotizing encephalopathy

Case report

ABSTRACT

Acute necrotizing encephalopathy is a rare, severe neurological condition, characterized by symmetrical necrotic brain lesions affecting the thalamus, cerebral white matter, brain stem, and cerebellum. Diagnosis relies on characteristic clinical and radiological features. We describe a 10-month-old female infant presenting with multiple seizures following a brief febrile upper respiratory illness. MRI of the brain showed bilateral symmetrical abnormal signal intensities involving both thalamic and caudate nucleus, consistent with ANE. Management of ANE is symptom-related but high-dose steroids and IVIG have been used. This case highlights the importance of recognizing ANE beyond its usual geographic distribution. Early recognition and prompt management help improve outcomes.

© 2024 The Authors. Published by Elsevier Inc. on behalf of University of Washington.

This is an open access article under the CC BY-NC-ND license

(<http://creativecommons.org/licenses/by-nc-nd/4.0/>)

Introduction

Acute necrotizing encephalopathy (ANE) was described in Japanese children by Mizuguchi et al in 1995. It is characterized typically by symmetrical necrotic brain lesions affecting the thalamus, cerebral white matter, brain stem, and cerebellum [1].

ANE is rare and it has mostly been described in Asian population with very few cases reported in Africa [2–4]. The highest incidence is among children between 6 and 11 months, but the age range of reported patients is from 5 months to 11 years. A few cases in adults have been reported in some parts of the world [2,5].

There is no specific etiology for ANE, but it has been linked to viral infections [6–9]. Although most cases are sporadic,

Abbreviations: ANE, Acute necrotizing encephalopathy; MRI, Magnetic resonance imaging; PCR, Polymerase chain reaction; CSF, Cerebrospinal fluid; CT, Computed tomography scan; IVIG, Intravenous immunoglobulin; SARS-CoV-2, Severe acute respiratory syndrome coronavirus 2; CPT2, Carnitine palmitoyl transferase 2; RANBP, RAN binding protein 2; HHV-6, human herpesvirus-6.

☆ Competing Interests: The authors declare that they have no known competing financial interests or personal relationships that could have appeared to influence the work reported in this paper.

☆☆ Acknowledgments: Not applicable. No funds were needed to publish this case.

* Corresponding author.

E-mail address: elingowi80@gmail.com (E. Ngowi).

<https://doi.org/10.1016/j.radcr.2024.09.149>

1930-0433/© 2024 The Authors. Published by Elsevier Inc. on behalf of University of Washington. This is an open access article under the CC BY-NC-ND license (<http://creativecommons.org/licenses/by-nc-nd/4.0/>)

specific genetic mutations encoding the nuclear pore protein RANBP2 (RANBP2) as well as thermolabile polymorphisms in the CPT2 gene have been linked to familial susceptibility [10].

Based on genetic predisposition and infectious triggers, as well as evidence of elevated cytokines that respond to high-dose steroids and immunoglobulin, ANE may be autoimmune in origin [11].

The most common clinical manifestations are new-onset seizures and altered mental status, within 72 hours following an acute febrile viral illness, especially respiratory diseases [10,12–14]. Most common laboratory findings include increased serum liver transaminases and elevated cerebrospinal fluid (CSF) proteins [7,9,14]. Radiological findings on magnetic resonance imaging (MRI) mostly show increased T2 signal density in both thalami, with or without the involvement of the tegmentum, putamen of basal ganglia, periventricular white matter, cerebellar medulla, and mammillary bodies [2,12].

The diagnosis of ANE is solely based on characteristic clinical and radiological features as proposed by Mizuguchi et al. [1,2].

Management of ANE is nonspecific and mainly tailored to the symptoms of the patient. There are several reports of successful use of steroids and intravenous immunoglobulins [7,9].

ANE's prognosis remains guarded but has improved due to modernized diagnostic tools and advances in intensive care. The neurologic sequelae are mild or nonexistent in patients over 4 years old presenting with normal or mild liver enzymes [2].

We report a case of ANE in an infant of East African origin following a mixed bacterial and viral infection. It is important for physicians in this region to promptly recognize ANE for early imaging and management to minimize neurological complications.

Case presentation

We received a female infant, who arrived after a 2-week admission at a referring hospital. She initially presented with fevers, cough, and a runny nose, which were treated as pharyngitis. On the second day of her illness, she experienced multiple seizures and loss of consciousness. CSF analysis was reported to have high protein levels. She was treated for meningitis and received 1 dose of Intravenous immunoglobulin (IVIG) during her illness. After 2 weeks of treatment, she was brought to our hospital by her parents.

She was born at full term by elective caesarean section as the first of a set of twins. Her antenatal and postnatal history were unremarkable. She was not exclusively breastfed but was adequately immunized according to the national program. The Measles-Rubella vaccine was received 2 weeks before the onset of symptoms. She had normal developmental milestones before the onset of seizures. Her female twin sibling is alive and well. There is no history of similar illness in the family, nor is there a history of consanguinity.

On examination, she had an initial Modified Glasgow Coma Score of 7 (Eye - 2, Verbal - 2, Motor - 3), rigid upper and lower

limbs, and weight for length and age were above 50th centile. She had hypertonicity of lower limbs with brisk reflexes on the left lower limb and clonus of the right lower limb.

At admission, laboratory investigations revealed leucocytes (white blood cell count) of 6.3×10^9 (normal $<16 \times 10^9$), with hemoglobin count of 12.0 g/dL (normal 10.7–131 g/dL), platelet count 694 (normal 150–450), a C-reactive protein concentration of 0.11 mg/L (normal 0.5–5 mg/L), elevated Aspartate Transaminase /AST of 81 IU/L (normal 0–32 IU/L), slightly elevated Alanine Transaminase of 38.01 IU/L (normal 0–33 IU/L), normal Blood Urea Nitrogen, normal Serum Creatinine, normal sodium, potassium and chloride levels in serum. Arterial Blood Gas was normal with a pH of 7.42 and Lactate of 1.6 mmol/L. CSF Lactate Dehydrogenase was 21 U/L (normal range: <40 U/L). Serum Organic Acid panel was done which was negative for all the amino acids tested. Urine analysis was normal. CSF analysis showed normal protein and glucose levels, no bacteria or yeast seen on gram staining, and no acid-fast bacilli on Acid-fast bacilli staining. Blood, Urine, and CSF cultures were done which all did not grow any pathogen. A FilmArray Meningoencephalitis Panel analysis was done which detected *Streptococcus Agalactiae* and Human Parechovirus (A nested multiplexed nucleic acid test for qualitative detection and identification of multiple bacterial, viral, and fungal pathogens from CSF).

MRI with contrast of the brain was then done which showed bilateral symmetrical abnormal signal intensities involving both thalami and caudate nucleus. There were bilateral cystic areas at the centrum semiovale and superior white matter, bilateral parasagittal areas and left cerebellum. A more detailed description of the images has been shown as in Figs. 1–4.

The patient's neurologic function slowly improved with regular physiotherapy and was discharged after 2 weeks of treatment. However, at discharge, she had not regained the ability to sit, control her neck, or speak comprehensibly. She was scheduled for regular rehabilitation clinic follow-up with regular physiotherapy.

Discussion

ANE of childhood is a disease that occurs mostly, but not limited to, children under 2 years who were previously healthy with no neurological conditions but have a preceding mild viral illness. It has an insidious onset and rapid progression [1,6]. Our patient was thriving well prior to the disease. She had a prodromal phase with a febrile respiratory illness and a sudden onset of seizures within 48 hours which is characteristic of cases reported with ANE.

Common viral infections associated with ANE reported include influenza A and B, severe acute respiratory syndrome coronavirus 2 (SARS-CoV-2), herpes simplex virus, human herpesvirus-6 (HHV-6) and enteroviruses. Very few cases have reported bacterial infections with *Mycoplasma pneumoniae* preceding ANE [8,9,11]. Our case was diagnosed with *Streptococcus agalactiae* and parecho virus infection in the CSF analysis, which were possible triggers to the ANE.

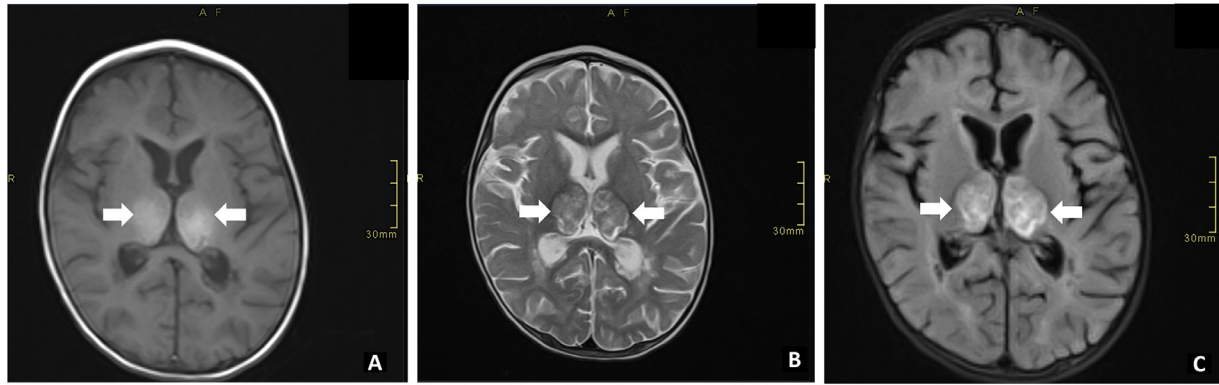


Fig. 1 – Unenhanced axial brain MRI images T1W (A), T2W(B) and FLAIR (C) show bilateral abnormal signal intensities involving both the thalami which appear relatively symmetrical. The signals appear hyperintense on T1W, heterogeneously hypointense with areas of hyperintensity on T2W and hyperintense on FLAIR (Arrows).

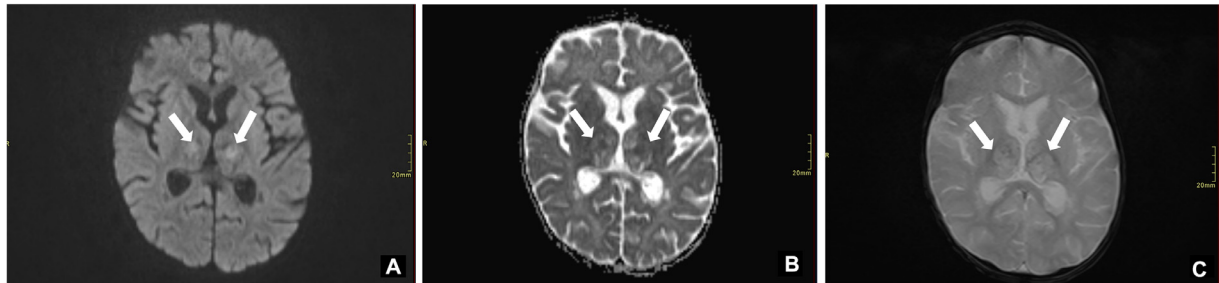


Fig. 2 – Bilateral abnormal signal intensities involving both the thalami. Axial images of the brain DWI (A), ADC (B), and GRE (C). These signals show restricted diffusion on DWI/ADC and areas of blooming on GRE sequences in keeping with blood products (Arrows).

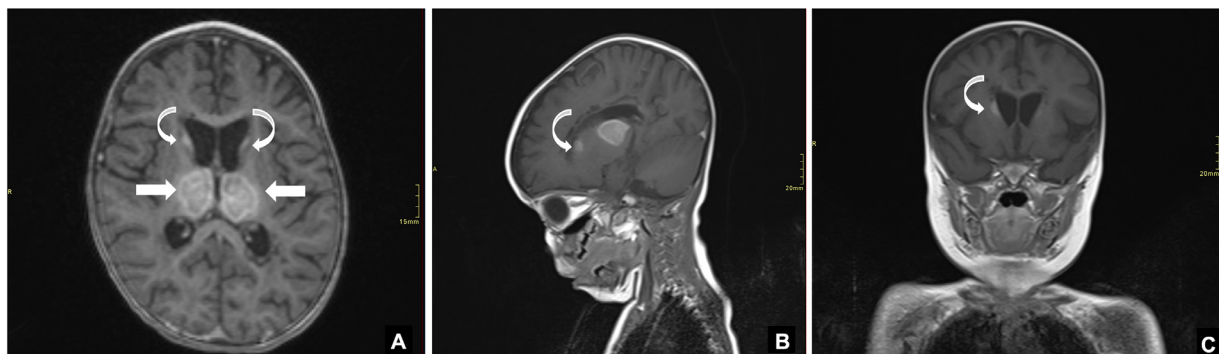


Fig. 3 – Enhanced brain MRI images axial (A), Sagittal (B) and coronal (C) Bilateral abnormal signal intensities involving both the thalami which appear relatively symmetrical. These areas show heterogeneous but avid enhancement post contrast (straight arrows). Note these signal abnormalities are also demonstrated at the bilateral head of caudate (curved arrows)

ANE may exhibit symptoms similar to those of metabolic and immune-mediated disorders due to a triggering environmental factor, but its pathophysiology remains unknown [3]. Our patient had an inciting illness, but the radiological findings did not indicate widespread encephalitis typically seen in autoimmune conditions. Patients usually present with fulminant neurological deterioration and intractable seizures. Mizuguchi proposed specific criteria to diagnose ANE [1,2]. Our

patient met the criteria for diagnosis. However, it is not uncommon for patients to have normal CSF values and meet the typical clinical and radiological features of ANE [3,7]. Our patient had elevated Protein on CSF analysis and other parameters normal.

There is genetic and epigenetic predisposition to ANE, which is explained by the geographical differences in incidence of the disease and associated mutations in RANBP2 and

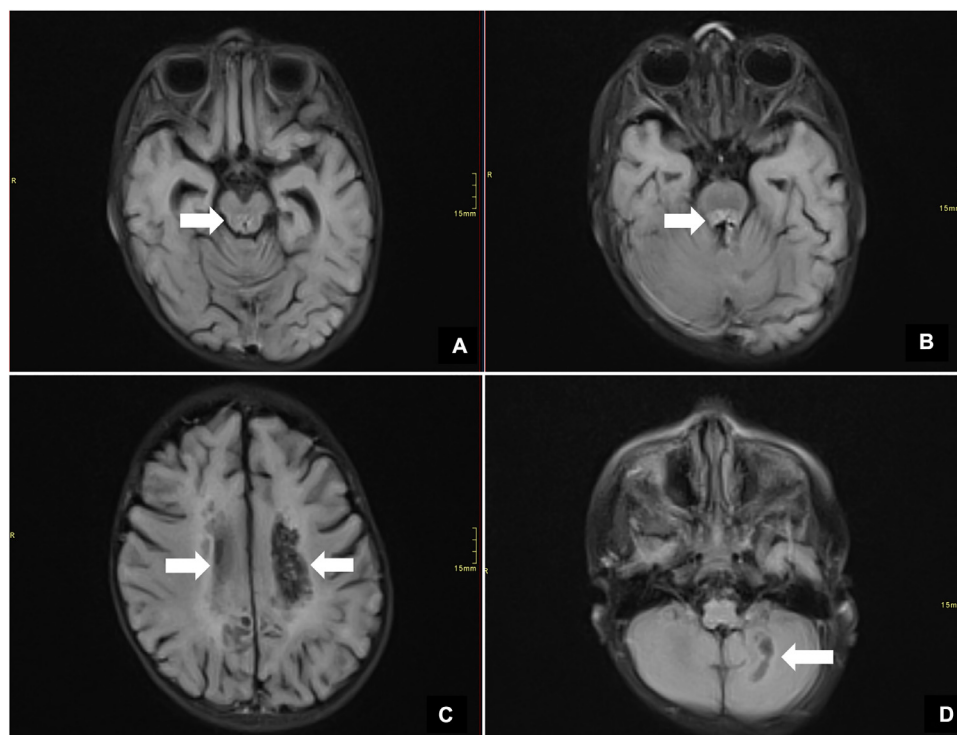


Fig. 4 – Axial FLAIR images of the brain. Focal areas of increased signal on FLAIR midbrain and pons (A) AND (B) with cystic areas adjacent (Arrows) which could represent cavitation. Bilateral cystic changes (arrows) were noted at the bilateral centrum semiovale and superior white matter (C) bilateral parasagittal areas and left cerebellum (D).

CPT2 genes. Racial predilection has been suggested as it is more common in Asian children than other parts of the world. There is 1 case reported from Tanzania, East Africa. History of consanguinity is postulated to play a role and there has been cases reported of familial presentation with recurrent ANE [2–4,10,12,15]. However, further studies are recommended to identify the genetic predispositions of ANE. Our patient was born to an East African parent; hence it is a rare occurrence in this geographical area.

Typical neuroimaging features in ANE in the acute phase are symmetrical bilateral gray matter lesions in the thalamus, brainstem tegmentum and cerebellar dentate nucleus with edema that causes necrosis of the neurons and glial cells. There are also oedematous white matter lesions. No inflammatory cells are present, distinguishing this from other inflammatory encephalitides [2,12]. Our patient exhibited symmetrical thalamic and caudate signal intensities on T2W, T1W, and Flair images, consistent with typical findings in ANE.

Patients with ANE have been treated with steroids and IVIG. However, addressing the underlying disease with appropriate antibiotics and antiviral medications is also part of the treatment approach [4,12,16]. Our patient received 1 dose of IVIG (1 g/kg), antibiotics, and acyclovir.

Long term outcome is variable. About 30% of patients die, 40% will have moderate to severe neurological sequelae and 30% will have none or mild sequelae. Most apparent neurodeficits are motor abnormalities like intentional tremors, ataxic gait, scanning or slurred speech, athetosis or choreoathetosis, hemiparesis, abducens palsy and extraocular dysmotility and

muscle rigidities. All these features are attributable to focal lesions in the thalamus, cerebellum and brainstem tegmentum [2,11,12]. Patients with near-complete resolution of neuro-radiological findings have better prognosis with none or mild long term deficits while patients with hemorrhage and necrosis will have poorer prognosis [16]. Our patient had improvement in limb rigidity, ability to swallow and responsiveness to touch and pain stimuli. She was scheduled for continued physiotherapy and neurology clinic follow-ups.

Conclusions

This case report brings forth awareness of this condition in our geographic location which is not common. Our patient had mixed pathogen exposure of streptococcus agalactiae and parechovirus which is a rare cause of ANE. It is important for physicians to consider the typical history of this condition, so that prompt management and appropriate neuroimaging can be done to arrive to a correct diagnosis.

Author contributions

Elisamia Ngowi was involved in the conception, study design, acquisition, and interpretation of data, and drafting of the manuscript.

Maria Bulimba, Zeenat Juneja and Mohamedraza Ebrahim were involved in literature review of the manuscript.

Jacqueline Gabone was involved in interpretation of radiological data and reviewed the literature of the research work.

Yaser Abdallah was involved in interpretation of clinical data and literature review.

All authors read and approved the final manuscript.

Patient consent

I, the corresponding author, declare that informed consent was obtained from the patient's legal guardian who is the biological mother for publication of this case report. In case it may be required, I will provide evidence of the copies of the consent form.

Ethical approval

Not required for case reports at our hospital for single case reports.

Guarantor

Elisamia Ngowi is the main guarantor of this research work. elingowi80@gmail.com.

Data availability

The datasets of the present study are available from the corresponding author upon request.

Declaration of generative AI and AI-assisted technologies in the writing process

During the preparation of this work, the author(s) used Grammarly to correct sentence grammar and spelling. After using this tool/service, the author(s) reviewed and edited the content as needed and take(s) full responsibility for the content of the publication.

REFERENCES

- [1] Mizuguchi M, Abe J, Mikkaichi K, Noma S, Yoshida K, Yamanaka T, et al. Acute necrotising encephalopathy of childhood: a new syndrome presenting with multifocal, symmetric brain lesions. *J Neurol Neurosurg Psychiatry* 1995;58(5):555–61.
- [2] Mizuguchi M. Acute necrotizing encephalopathy of childhood: a novel form of acute encephalopathy prevalent in Japan and Taiwan. *Brain Dev* 1997;19(2):81–92.
- [3] Bashiri FA, Al Johani S, Hamad MH, Kentab AY, Alwadei AH, Hundallah K, et al. Acute necrotizing encephalopathy of childhood: a multicenter experience in Saudi Arabia. *Front Pediatr* 2020;8:526.
- [4] Chipongo H, Rajan S, Sarkar A, McLarty R, Sangey E. Acute necrotizing encephalopathy of childhood from Eastern Africa. *Clin Case Rep* 2023;11:e7454.
- [5] Narra R, Mandapalli A, Kamaraju SK. Acute necrotizing encephalopathy in an adult. *J Clin Imaging Sci* 2015;5:20.
- [6] Skelton BW, Hollingshead MC, Sledd AT, Phillips CD, Castillo M. Acute necrotizing encephalopathy of childhood: typical findings in an atypical disease. *Pediatr Radiol* 2008;38(7):810–13.
- [7] Vanaki R, Diwanmal S, Pol R, Yelamali B, Kulkarni M, Brahmandbher S. Acute necrotizing encephalopathy of childhood: an under-recognized and diverse clinico-radiological syndrome. *Int J Contempor Pediatr* 2020;7:2106.
- [8] Wang PY, Yang MT, Liang JS. Acute necrotizing encephalopathy caused by SARS-CoV-2 in a child. *Pediatr Neonatol* 2022;63(6):642–4.
- [9] Park S, Oh S, Eun B-L, Byeon J. Acute necrotizing encephalopathy secondary to mycoplasma pneumoniae infection in a 4-Year-Old Boy. *Ann Child Neurol* 2020;29(1):51–3.
- [10] Ohashi E, Hayakawa I, Murofushi Y, Kawai M, Suzuki-Muromoto S, Abe Y, et al. Recurrent acute necrotizing encephalopathy in a boy with RANBP2 mutation and thermolabile CPT2 variant: the first case of ANE1 in Japan. *Brain Developm* 2021;43(8):873–8.
- [11] Kansagra SM, Gallentine WB. Cytokine storm of acute necrotizing encephalopathy. *Pediatr Neurol* 2011;45(6):400–2.
- [12] Lee YJ, Hwang SK, Kwon S. Acute necrotizing encephalopathy in children: a long way to go. *J Korean Med Sci* 2019;34(19):e143.
- [13] Salehiomran MR, Nooreddini H, Baghdadi F. Acute necrotizing encephalopathy of childhood: a case report. *Iran J Child Neurol* 2013;7(2):51–4.
- [14] San Millan B, Teixeira S, Penin C, Garcia JL, Navarro C. Acute necrotizing encephalopathy of childhood: report of a Spanish case. *Pediatr Neurol* 2007;37(6):438–41.
- [15] Marco EJ, Anderson JE, Neilson DE, Strober JB. Acute necrotizing encephalopathy in 3 brothers. *Pediatrics* 2010;125(3):e693–e698.
- [16] Hauptfleisch M, Scher L, Pillay T, Kilborn T. Acute necrotising encephalopathy: a rare but important differential diagnosis. *South African J Child Health* 2021;15:118.