

Arthroscopic Excision of an Osteoid Osteoma of the Lesser Trochanter of the Femoral Neck



Byung-Ho Yoon, M.D., Jung Gon Kim, M.D., and Yong-Chan Ha, M.D.

Abstract: Osteoid osteoma frequently requires surgical treatment, especially among young, active patients. However, surgeons are reluctant to perform open surgery for an osteoid osteoma of the femoral neck area because the conventional surgical approach requires a large incision in muscular patients, and percutaneous resection with a trephine has the attendant risk of subsequent fracture. Recently, arthroscopic excision of an osteoid osteoma has been reported as a less invasive, safer procedure than traditional open curettage. Hip arthroscopy using the burr-down technique under C-arm guidance to locate and remove the lesion of the femur neck has also shown promise. The presented technique minimizes muscle damage around the femur and enables surgeons to confirm complete resection of the lesion through direct, detailed visualization. Furthermore, early return to previous activity can be achieved after excising the lesion located at the calcar femorale, which is an area with a heavy weight-bearing load. The objective of this Technical Note was to describe our preferred technique for the surgical excision of osteoid osteoma located at the base of the femoral neck through the use of arthroscopy.

An osteoid osteoma usually affects the lower extremities in young men, with half the cases involving the femur or tibia.¹ Osteoid osteoma presents as a pathognomic lesion that consists of a distinctive small, rounded area of osteolysis, the nidus, with surrounding bony sclerosis.¹ Osteoid osteoma is initially treated nonoperatively with medications, but most patients are unable to continue as a result of their intolerance for ongoing pain.² Surgical treatment has traditionally been aimed at nidus removal using various methods such as open surgical resection or drilled resection.³⁻⁵

Surgeons are reluctant to perform conventional surgery for an osteoid osteoma of the femoral neck area because of the morbidity associated with the surgical approach or risk of subsequent fracture, especially in

young, active male patients. To date, successful arthroscopic treatment of an osteoid osteoma of the femoral neck has been reported, but the most inferior portion of the femoral neck is more difficult to access arthroscopically than the midcervical area.^{6,7} Here, we introduce an arthroscopic excision technique that was used to remove an osteoid osteoma located just above the lesser trochanter of the femoral neck and associated with periosteal reaction.

Surgical Technique

Preoperative Assessment and Patient Position

The computed tomography (CT) scan demonstrated focal cortical thickening along the medial cortex and a small osteolytic lesion just at the anteromedial aspect of the lesser trochanter (Fig 1). Adjacent intramedullary bone marrow edema was observed on magnetic resonance imaging, which was also performed to differentiate the osteoid osteoma from a stress reaction or another tumor lesion. These radiologic findings strongly suggested an osteoid osteoma.

The patient was placed in supine position on a fracture traction table, and both lower extremities were fixed to the table. Traction was adjusted under C-arm guidance to obtain a slightly flexed position, and the contralateral hip joint was abducted to permit easy intraoperative fluoroscopic assistance.

From the Department of Orthopaedic Surgery, Inje University College of Medicine, Seoul Paik Hospital (B-H.Y., J.G.K.); and Department of Orthopaedic Surgery, Chung-Ang University College of Medicine (Y-C.H.), Seoul, Republic of Korea.

The authors report that they have no conflicts of interest in the authorship and publication of this article. Full ICMJE author disclosure forms are available for this article online, as [supplementary material](#).

Received December 22, 2016; accepted May 21, 2017.

Address correspondence to Byung-Ho Yoon, M.D., Department of Orthopaedic Surgery, Inje University College of Medicine, Seoul Paik Hospital, Seoul, Republic of Korea. E-mail: cragy0215@naver.com

© 2017 by the Arthroscopy Association of North America

2212-6287/161286/\$36.00

<http://dx.doi.org/10.1016/j.eats.2017.05.017>

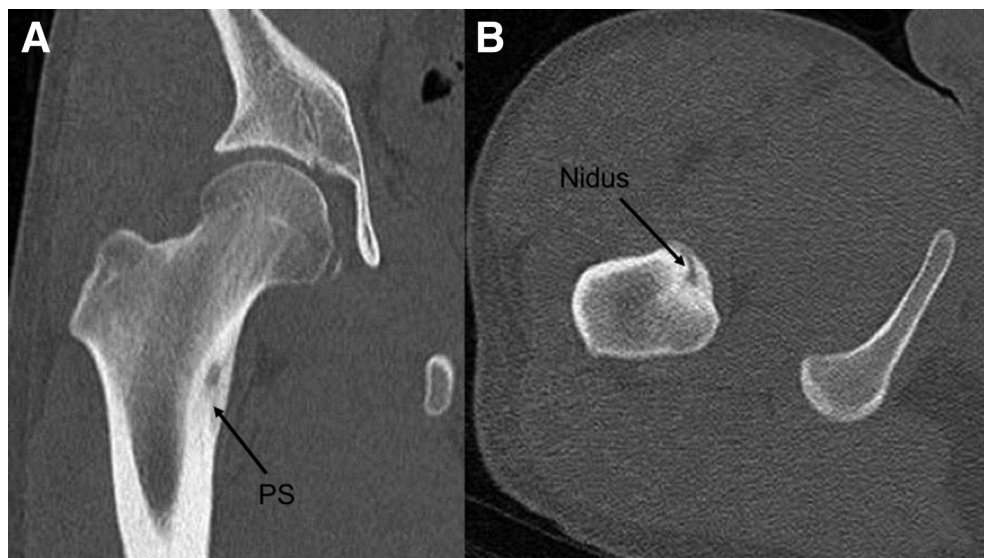


Fig 1. Computed tomography imaging of the reported case. Coronal (A) and axial (B) images showing an 8 mm × 7 mm × 5 mm lesion with a central osteolytic lesion (nidus) and perinidal sclerosis (PS) in just the anteromedial area of the lesser tuberosity of the right femur.

Portal Placement

We performed hip arthroscopy by starting in the peripheral compartment using anatomic surface landmarks. First, in the anteroposterior view under an image intensifier, a guidewire was inserted from a greater trochanter tip to the midcervical area (Fig 2). After confirming an adequate position of the guidewire, a proximal anterolateral portal was made. Then a 4.5-mm, 30° arthroscope delivered normal saline solution by a pressure-controlled pump that was inserted

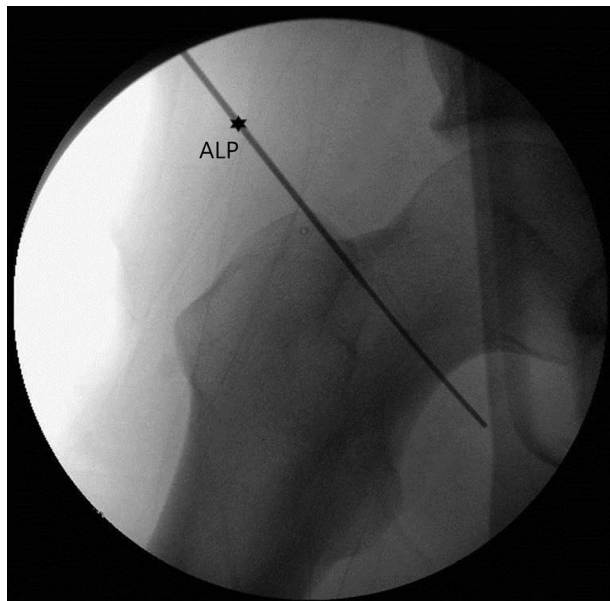


Fig 2. The patient is in the supine position with contralateral hip abducted. C-arm image demonstrating the arthroscopic approach to the peripheral compartment of the hip joint using a 2.0-mm flexible guidewire which was introduced into the right proximal anterolateral portal (ALP).

through the portal into the joint cavity. Next, a guidewire was inserted from a greater trochanter to the lesser trochanter and the distal anterolateral portal was made in a similar fashion. This portal was in line with the proximal anterolateral portal and approximately 3 to 4 cm distally.

Access to Lesion (Synovectomy and Release of Capsule)

During the initial visualization, the joint capsule was filled with hyperemic synovium, which was edematous and thickened (Fig 3). The hyperemic synovium was removed, and the joint capsule was released from the level of the intertrochanteric line by using a coblation device (ArthroWand; ArthroCare, Sunnyvale, CA) to obtain the surgical view (Video 1).

Identify and Isolate Nidus Under Image Intensifier

Once the synovectomy and capsular release were complete, we tried to identify the lesion under an image intensifier. Complete visualization of the lesion was not feasible because overlying cortical bone disturbed the arthroscopic view. Therefore, we started to remove the slightly elevated periosteal area to expose the cortical bone of the lesion under an image intensifier (Fig 4). Using a mechanized high-speed bone burr (ClearCut; Arthrex, Naples, FL), the periosteal reaction area of the cortical bone was gradually removed, enabling access to the nidus of the osteoid osteoma.

Complete Excision and Postoperative Care

A margin of 10 mm in diameter and 8 mm in depth was identified in the nidus. The burr approached the nidus, and the location was reconfirmed using the C-arm guide. To completely remove the nidus, periosteal reaction around the tumor was also cut down using the

Fig 3. Key steps to obtaining the surgical view and sufficient work space (viewed from the proximal anterolateral portal with 30° arthroscope, with instrumentation through the proximal anterolateral portal). (A) Arthroscopic image showing the femoral neck (FN) surrounded by hyperemic synovium (HS, white arrow). (B) After synovectomy, the joint capsule was released from the level of the intertrochanteric line of the right femur neck.

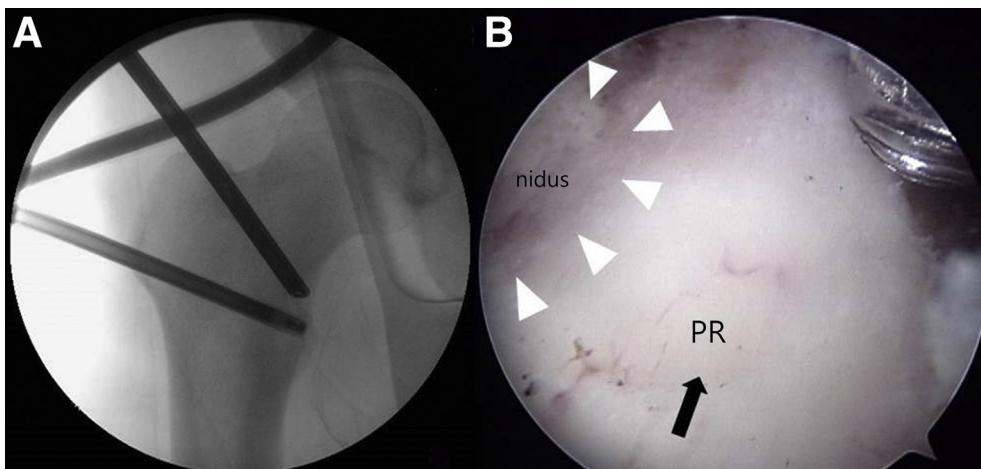
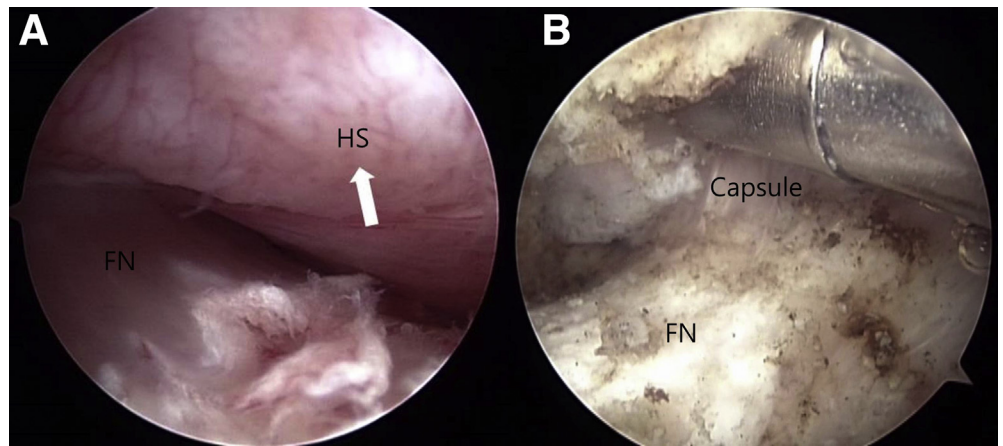


Fig 4. Identification of the lesion under C-arm guide of right femur neck. (A) The lesion cannot be clearly identified because of the periosteal reaction, so the location is confirmed under an image intensifier. (B) The periosteal hypertrophic area (PH, black arrow) of the cortical bone is removed gradually, and the nidus (white arrowheads) starts to become visible.

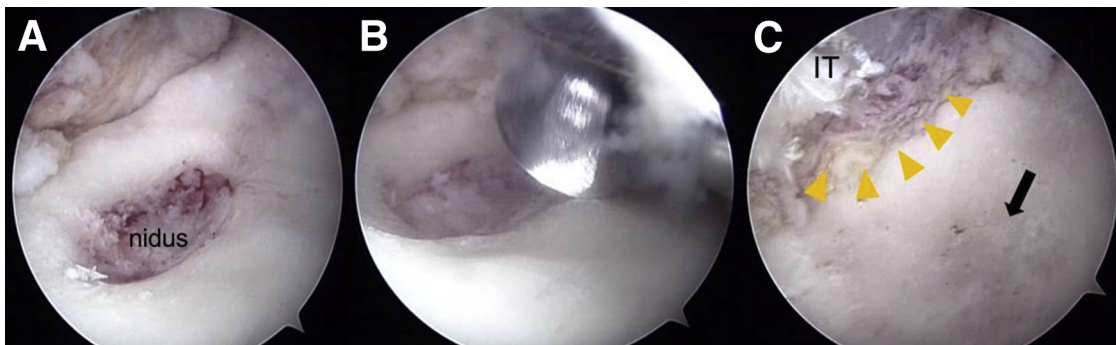


Fig 5. Arthroscopic resection of an osteoid osteoma of the right femur neck. (A) A grossly reddish, dense nidus of the osteoid with interconnected trabeculae is observed after removing the sclerotic rim. (B) Arthroscopic image showing removal of the nidus using the burr-down technique. (C) Arthroscopic image obtained after total excision of the nidus (black arrow), confirming the precise location of the lesion through the observation of a partial tear of the iliopsoas muscle (IT, yellow arrowheads) at its insertion site near the lesser trochanteric area.

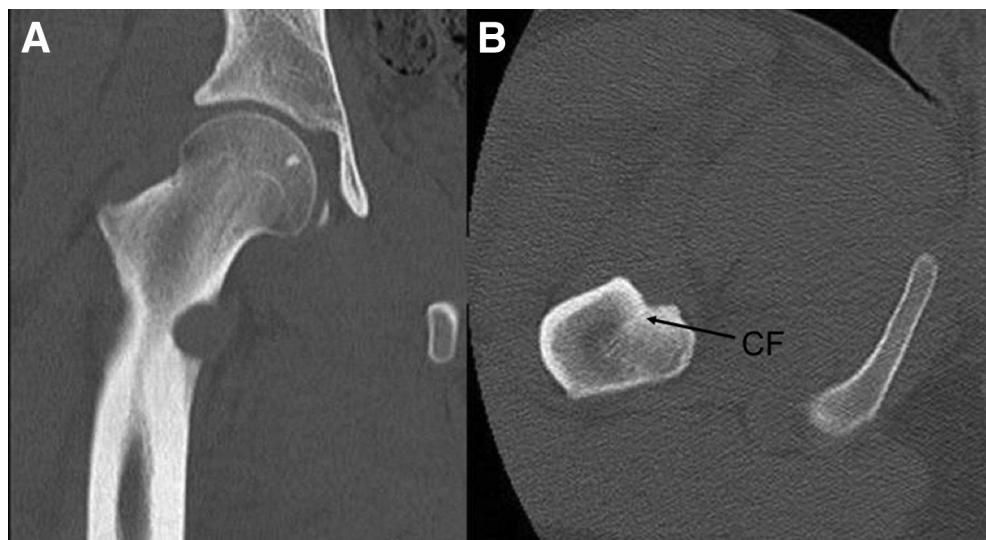

Fig 6. Postoperative computed tomography of the patient can be compared with the preoperative images in Figure 1. (A) Anteroposterior and (B) axial images of the right proximal femur postoperatively showing complete resection of the lesion and preservation of the calcar femorale (CF).

burr (Video 1). Otherwise, we could not remove the margin of the tumor precisely. Subsequently, complete excision of the hypertrophic change and osteoid osteoma lesion was achieved (Fig 5 A and B). After confirming complete excision on endoscopy, we performed meticulous coagulation (Fig 5C). The total surgical time was 90 minutes; there were no complications postoperatively, and the lesion completely disappeared on the postoperative CT scan (Fig 6). Partial weight-bearing was allowed the day after the operation, and full weight-bearing, including jogging, was allowed 2 weeks later.

Discussion

Symptomatic relief of an osteoid osteoma can be achieved after 3 years of conservative treatment.^{3,8} However, osteoid osteomas that cause persistent, unbearable pain after long-term medication require surgical treatment.^{3,8} The most common cause of recurrence after surgical treatment is incomplete removal of the nucleus, so complete resection of the nucleus is essential; en-bloc excision, which completely removes the surrounding bone, including

the nucleus, is a universal treatment method.^{3,8,9} There are multiple techniques for excising a lesion: the conventional open operation, drilled resection, and arthroscopic removal.

However, if there is a lesion in the medial cortical bone of the femoral neck, the conventional surgical approach requires a large incision in a muscular patient; thus, this method has not been widely used recently. Percutaneous resection with a trephine or drill requires relatively large-caliber instruments, so ensuring complete removal is very difficult and there is a risk of subsequent fracture after complete resection.¹⁰ In one study, 5 targeting errors (11.9%) and 2 subsequent fractures (4.7%) occurred among 42 patients after percutaneous resection of osteoid osteoma of the proximal femur.¹¹

Arthroscopically assisted excision techniques are becoming increasingly popular for the diagnosis and treatment of intra-articular osteoid osteomas, and they have produced satisfactory results for lesions of many sites, including the hip.^{5,12-15} This technique has several

Table 1. Advantages and Limitations of Arthroscopic Excision Technique

Advantages	Limitations
Minimally invasive and minimum muscle damage around femur	Physician should be familiar with hip arthroscopy techniques
The lesion is accurately confirmed and the complete excision can be confirmed through direct visualization	Use of arthroscopy results in increased cost
A smaller skin incision	
Early recovery by preserving calcar femorale and removal as little bone as possible	

Table 2. Pearls and Pitfalls

Pearls	Pitfalls
The affected limb should be secured with the hip at 40° flexion to obtain sufficient space.	Inaccurate placement of portals may lead to cartilage damage or visual disturbance.
The iliopsoas tendon can be used as a landmark to confirm that you are operating on a target lesion.	Bloody periosteal lesion can be misdiagnosed as an osteoid osteoma. Make sure the surgeon has removed all lesions under an image intensifier.
It is very helpful to use an acromial or small burr during removal of periosteal thickening as needed.	

Table 3. Key Steps of Arthroscopic Excision of Osteoid Osteoma

-
1. Routine arthroscopic peripheral compartment inspection
 2. Synovectomy and capsular release under the appropriate situation
 3. Identify cortical thickening of the osteoid osteoma under an image intensifier
 4. Remove periosteal thickening by sweeping the cutter from tumor margin to nidus and progressing centrally
 5. Complete mass excision by burr-down technique and confirm via direct visualization
-

advantages over other conventional surgical options, such as a smaller skin incision and early postoperative recovery. The lesser trochanter is the anteromedial portion of the femoral neck where the weight-bearing load is heavy. We believe that arthroscopy can be extremely beneficial in assisting in the treatment of an osteoid osteoma of the lesser trochanter of the femur. Total synovectomy and capsular release were performed to obtain a surgical field and enough workspace to manipulate the instruments (Table 1).

An image intensifier had to be used during the procedure, as the lesion could not be visualized because of an overlying cortical reaction. A concern regarding this technique is that surgeons should be familiar with hip arthroscopy. If bleeding cannot be controlled, the operation may be difficult, because the lesion cannot be accurately identified during initial visualization. We used the burr-down technique to remove sclerotic bone. The shank of the burr rested against the periosteal thickening of the nidus, which acts as a poller. Periosteal thickening is resected by sweeping the cutter from the tumor margin to the nidus and progressing centrally (Table 2). Consequently, the appropriate amount of bone is resected, resulting in complete excision with minimal removal of the surrounding reactive bone and smooth, normal bone continuity (Table 3). Additionally, this method is minimally invasive and associated with little bleeding and a low probability of infection.

References

1. Karpik M, Wojnar J, Skowronski J, Reszec J. Osteoid osteoma—Diagnostic and therapeutic difficulties. A. Single-centre experience. *Ortop Traumatol Rehabil* 2016;18:131-140.
2. Outani H, Hamada K, Takenaka S, et al. Radiofrequency ablation of osteoid osteoma using a three-dimensional navigation system. *J Orthop Sci* 2016;21:678-682.
3. Campanacci M, Ruggieri P, Gasbarrini A, Ferraro A, Campanacci L. Osteoid osteoma. Direct visual identification and intralesional excision of the nidus with minimal removal of bone. *J Bone Joint Surg Br* 1999;81:814-820.
4. Sluga M, Windhager R, Pfeiffer M, Dominkus M, Kotz R. Peripheral osteoid osteoma. Is there still a place for traditional surgery? *J Bone Joint Surg Br* 2002;84:249-251.
5. Kang S, Kim YS, Lee HM, Lee MY, Kim JP. Arthroscopic excision of an intraarticular osteoid osteoma in the distal femur. *Clin Orthop Surg* 2016;8:475-480.
6. Nehme AH, Bou Ghannam AG, Imad JP, Jabbour FC, Moucharafieh R, Wehbe J. Arthroscopic excision of intra-articular hip osteoid osteoma: A report of 2 cases. *Case Rep Orthop* 2012;2012:820501.
7. Said HG, Abdulla Babaqi A, Abdelsalam El-Assal M. Hip arthroscopy for excision of osteoid osteoma of femoral neck. *Arthrosc Tech* 2014;3:e145-e148.
8. Aiba H, Hayashi K, Inatani H, et al. Conservative treatment for patients with osteoid osteoma: A case series. *Anticancer Res* 2014;34:3721-3725.
9. Gao K, Hua Y, Chen S, Li Y, Xin Q. Arthroscopic excision of juxtaarticular cancellous osteoid osteoma in the talar neck. *Knee Surg Sports Traumatol Arthrosc* 2013;21:1300-1303.
10. El-Mowafi H, El-Hawary A, Hegazi M. Intra- and peri-articular osteoid osteoma: Percutaneous destruction and alcoholisation. *Acta Orthop Belg* 2015;81:47-51.
11. Raux S, Abelin-Genevois K, Canterino I, Chotel F, Kohler R. Osteoid osteoma of the proximal femur: Treatment by percutaneous bone resection and drilling (PBRD). A report of 44 cases. *Orthop Traumatol Surg Res* 2014;100:641-645.
12. Khapchik V, O'Donnell RJ, Glick JM. Arthroscopically assisted excision of osteoid osteoma involving the hip. *Arthroscopy* 2001;17:56-61.
13. Banerjee D, Eriksson K, Morris H. Arthroscopically treated intraarticular osteoid osteoma in the ankle—A report of 3 cases. *Acta Orthop* 2005;76:721-724.
14. Trebse R, Poberaj B, Cor A, Levasic V. Arthroscopic removal of an osteoid osteoma in the radial head: A case report. *Arthroscopy* 2007;23:1361.e1361-1361.e1363.
15. Nourissat G, Kakuda C, Dumontier C. Arthroscopic excision of osteoid osteoma of the elbow. *Arthroscopy* 2007;23:799.e791-799.e794.