



## *Oxyspirura petrowi* infection leads to pathological consequences in Northern bobwhite (*Colinus virginianus*)



Nicholas R. Dunham <sup>a</sup>, Scott Reed <sup>b</sup>, Dale Rollins <sup>c</sup>, Ronald J. Kendall <sup>a,\*</sup>

<sup>a</sup> The Wildlife Toxicology Laboratory, The Institute of Environmental and Human Health, Texas Tech University, Box 43290, Lubbock, TX, 79409-3290, USA

<sup>b</sup> Texas A&M Veterinary Medical Diagnostic Laboratory, 6610 W. Amarillo Blvd, Amarillo, TX, 79106, USA

<sup>c</sup> Rolling Plains Quail Research Ranch, 1262 U.S. Highway 180 W., Rotan, Texas, 79546, USA

### ARTICLE INFO

#### Article history:

Received 2 September 2016

Received in revised form

22 September 2016

Accepted 27 September 2016

#### Keywords:

*Colinus virginianus*

Eyeworm

Northern bobwhite

*Oxyspirura petrowi*

Parasitism

Pathology

### ABSTRACT

Debilitating ocular diseases are often reported in avian species. By and large, helminth parasites have been overlooked in avian diseases and regarded as inconsequential. The decline of Northern bobwhite quail (*Colinus virginianus*) in the Rolling Plains ecoregion of Texas has prompted an investigation of the factors influencing their disappearance. Infection by the eyeworm (*Oxyspirura petrowi*) has been documented in many avian species; however, the effect it has on its host is not well understood. Heavy eyeworm infection has been documented in Northern bobwhites throughout this ecoregion, leading to eye pathology in this host species. The present study further documents and supports the pathological changes associated with *O. petrowi* in bobwhites.

© 2016 The Authors. Published by Elsevier Ltd on behalf of Australian Society for Parasitology. This is an open access article under the CC BY-NC-ND license (<http://creativecommons.org/licenses/by-nc-nd/4.0/>).

### 1. Introduction

Ocular diseases are commonly reported in avian species with one of the most common being primary or secondary inflammatory diseases of the eyelids and conjunctiva (Bayón et al., 2007). Parasitic infection of the eye may lead to ocular disease which may be very debilitating to the host. Visual function in birds is essential for flying, surviving in the wild, and reproduction (Jezler et al., 2010; Korbelt and Habel, 2011). Even partial impairment of vision caused by eye disease may have far-reaching consequences because compensation by other senses is mostly insufficient and/or impossible (Korbelt and Habel, 2011).

Recently, a parasitic eyeworm (*Oxyspirura petrowi*) has received increased attention due to the high prevalence detected in native galliforme populations in the United States (Robel et al., 2003; Villarreal et al., 2012; Dunham et al., 2016). Specifically, the decline of the Northern bobwhite (*Colinus virginianus*) in west Texas has prompted an investigation of the factors influencing the disappearance of these birds. Quail populations are a substantial part of west Texas hunting culture, and consequently are of economic importance for many rural communities throughout the

Rolling Plains (Johnson et al., 2012). With the quail decline impacting many communities in Texas, researchers began looking at every possible factor that could be influencing these populations.

Helminth parasites have been overlooked historically (Lehman, 1984), but eyeworm infections are now considered a possible factor contributing to the decline of Northern bobwhites in Texas (Dunham et al., 2014, 2016; Bruno et al., 2015). *Oxyspirura petrowi* is a heteroxenous parasitic nematode reported to infect the eyes of many avian hosts (Dunham and Kendall, 2016) with species of this genus being documented in >80 avian species worldwide (Addison and Anderson, 1969). Eyeworms inhabit the eyelids, nictitating membrane, nasolacrimal duct, lacrimal gland, Harderian gland, and intraorbital tissues of its host (Cram, 1937; Addison and Anderson, 1969; Robel et al., 2003; Dunham et al., 2014; Bruno et al., 2015).

There has been interest in studying eyeworm infection in Northern bobwhite (*Colinus virginianus*) since recent research discovered that this parasite is endemic to the Rolling Plains ecoregion of Texas and Oklahoma (Dunham et al., 2016). Over the past few years, eyeworm infection has been documented extensively in bobwhites throughout the ecoregion and led researchers to examine the potential influence that parasites have on their decline (Villarreal et al., 2012; Xiang et al., 2013; Dunham et al., 2014). The impact(s) of eyeworms on the host itself is unclear. A few studies have shown that these parasites do not cause pathological effects or

\* Corresponding author.

E-mail address: [ron.kendall@ttu.edu](mailto:ron.kendall@ttu.edu) (R.J. Kendall).

gross lesions (McClure, 1949; Pence, 1972; Ruff and Norton, 1997); however, Saunders (1935) observed ocular irritation caused by eyeworm infections. Recently, *O. petrowi* infections were reported to cause severe inflammation and edema (Dunham et al., 2014, 2015). Bruno et al. (2015) first reported lesions associated with eyeworm infection in Northern bobwhites found in the Rolling Plains of Texas. Eye inflammation progressing to destruction of the eye has been noted in a related eyeworm species (*Oxyspirura mansoni*) found commonly in poultry (Ruff and Norton, 1997).

The purpose of this study was to (1) examine the host response to infection with *O. petrowi*, (2) determine the extent and incidence of lesions associated with *O. petrowi* and (3) discuss the possible contribution that *O. petrowi*-associated pathology has on the decline of Northern bobwhites in the Rolling Plains ecoregion of Texas and Oklahoma.

## 2. Materials and methods

### 2.1. Ethics statement

Animal experiments were approved by Texas Tech University Animal Care and Use Committee under protocol 13066-08. All quail were trapped and handled according to Texas Parks and Wildlife permit SRP-1098-984 and SRP-0715-095.

### 2.2. Study area

The experimental study area of the present manuscript is consistent with the study area described in Dunham et al. (2014).

### 2.3. Quail trapping

All Northern bobwhites were collected from the same trapping location, in the same manner, and using the same techniques previously described by Dunham et al. (2014).

### 2.4. Histological techniques

After euthanasia, the head was removed from the body of each sample. While holding the head in hand, the lower mandible, neck, and additional tissues were gently removed. Next the skin and feathers were carefully excised leaving only the skull, upper mandible, and eyelids. Heads were fixed in 10% neutral buffered formalin. Each head was fixed for a minimum of 4 days. Skulls were decalcified with 23% w/w hydrochloric acid for 12–16 h. Decalcified fixed heads were then sectioned in 3 mm intervals prior to processing. All tissues subsequently were processed routinely in an automated Shandon Pathcentre® histology processor (Thermo Scientific, Waltham, MA), which dehydrated tissues in progressively increased concentrations of ethanol and cleared in xylene prior to paraffin embedding. Processed tissue was then embedded in Paraplast™ paraffin wax (VWR, Radnor, PA) to create tissue blocks for microtomy. Tissue was sectioned at 4 μ thickness with a microtome and mounted on glass slides for staining. Routine staining with hematoxylin and eosin (VWR Premium Histology Stains) was performed, slides were cover-slipped, and specimens were examined microscopically by a board-certified veterinary pathologist. Imaging was performed with a Nikon Digital Sight DS-SM camera (Nikon Instruments Inc., Melville, NY) connected to an Olympus BX-51 bright field microscope (Olympus America Inc., Center Valley, PA). The Harderian gland, lacrimal gland, cornea, eyelids, nictitating membrane, and other eye-associated tissues were adequately sampled for each eye of each sample.

### 2.5. Pre-preparation for scanning electron microscopy

Eyeworms were removed using techniques described in Dunham et al. (2015). To prepare eyeworms for scanning electron microscopy photographs, each eyeworm was dehydrated. The dehydration started by placing the designated eyeworms in a deionized water bath for 15 min. Next, eyeworms were placed into each ethanol solution (30%, 50%, 80%, 90%, and 100%) for 15 min followed by a 15 min acetone bath. Once finished, each eyeworm was individually stored in a 5 ml tube with 100% ethanol and sent to the Tulane Coordinated Instrumentation Facility (New Orleans, LA), where scanning electron microscopy was performed. Voucher specimens of *O. petrowi* (107282) were deposited in the U.S. National Parasite Collection, Beltsville, Maryland.

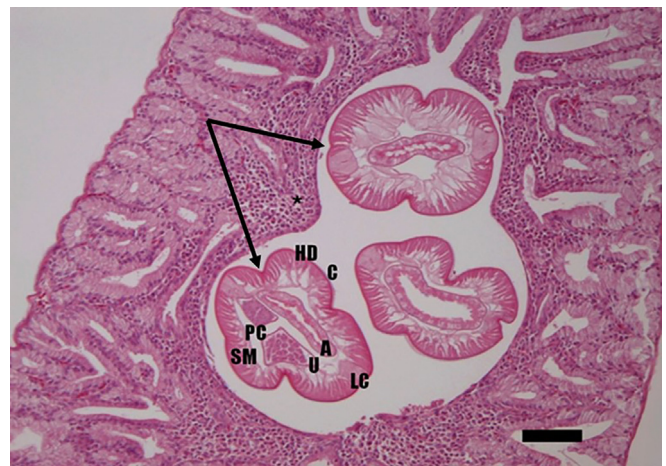### 2.6. Parasite identification

Identification of *O. petrowi* was based on histological and morphological characteristics, such as spicule and esophagus length, as described by Addison and Anderson (1969) and Pence (1972).

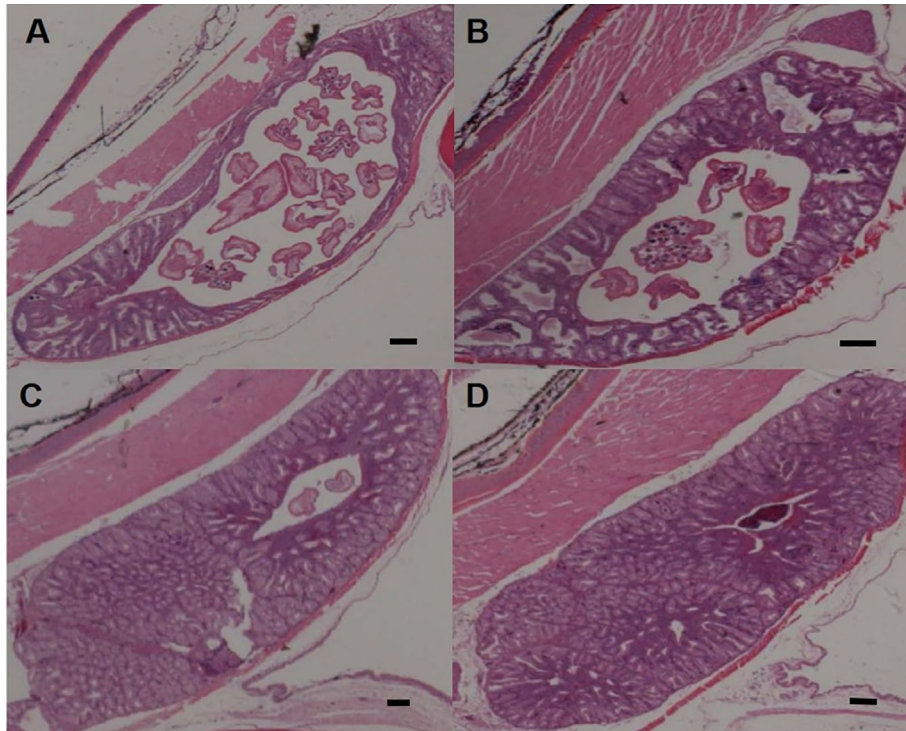
## 3. Results

A total of 25 of the 28 (89.3%) Northern bobwhites were infected with *O. petrowi*. Fourteen of 15 males, 11 of 13 females, 12 of 12 adults, and 13 of 16 juveniles were found to be infected. Eyeworms were found in the lacrimal gland, Harderian gland, nictitating membrane, bulbar conjunctive, fornix of the conjunctiva, and nasolacrimal duct. Histological sections of the Harderian gland demonstrated lesions, with a varying degree of presumed severity, associated with the presence of *O. petrowi* (Figs. 1 and 2). *O. petrowi* presence was associated with lymphoplasmacytic Harderian gland adenitis in all cases. In addition to increasing inflammatory cell infiltration associated with infection, there was also increased atrophy and corresponding duct dilation.

The intraluminal presence of the *O. petrowi* was associated with a moderate to marked Harderian gland adenitis and fibrosis. In this study, several birds had corneal epithelial erosions and edema



**Fig. 1.** Histological section of a Northern bobwhite (*Colinus virginianus*) Harderian gland with intraluminal *Oxyspirura petrowi* parasites in transverse section (indicated by arrows) and marked heterophilic Harderian adenitis. Hematoxylin and eosin staining at 100×, scale = 100 μm \* = marked lymphocyte and heterophilic inflammatory cell infiltrate; C = cuticle; HD = hypodermis; SM = somatic musculature; LC = lateral cords; PC = pseudocoelom; A = alimentary tract; U = uterus containing embryonated eggs.



**Fig. 2.** Histological section of Northern bobwhite (*Colinus virginianus*) Harderian glands with a varying degree of pathological response associated with *Oxyspirura petrowi* infection. Scale bar = 200  $\mu$ m.

causing corneal edema. Corneas of many infected bobwhites appeared to be cloudy and have early ulcerative erosions. Eye tissues from the three uninfected quail lacked gland atrophy when compared to infected birds.

#### 4. Discussion

While many ocular conditions are reported in avian species, the impact that ocular parasites have on their hosts are not fully understood. Our results suggest that eyeworms, such as *O. petrowi*, negatively impact ocular tissues by causing inflammation, fibrosis, and adenitis to the host. Past studies with *Oxyspirura* spp. observed ocular irritation with no signs of damage in other galliforme species, but histological techniques were not implemented (Saunders, 1935; McClure, 1949; Pence, 1972). A closely related eyeworm, *Oxyspirura mansoni*, has been associated with damage to the conjunctiva and lacrimal ducts in poultry (Kobayashi, 1927) and researchers hypothesized that severe infection, coupled with inflammation, would likely lead to blindness (Sanders, 1929). Bruno et al. (2015) first documented eye pathology in bobwhites associated with *O. petrowi* and infection within the Harderian gland. Additionally, Dunham et al. (2014, 2015) revealed significant inflammation and petechial hemorrhaging associated with *O. petrowi* infection. This research, along with the present study, describe a series of detrimental consequences within the Northern bobwhite host when infected with eyeworms.

Visual acuity is not only necessary for finding/securing food but also for identifying mates and escaping predators (Jezler et al., 2010). In the present study, eyeworm infection caused adenitis (glandular inflammation) in both juvenile and adult Northern bobwhite. Inflammation of any kind is commonly associated with pain due to swelling. The inflammation and gland destruction associated with *O. petrowi* infection, if allowed to progress, would lead to gland destruction and functional compromise. Swelling in/


around the eye causes impingement on stretch receptors which releases cytokines followed by the release of stress hormones. Add the irritation caused by oscillating and migrating filarids, these quail would be suspected to be significantly compromised in terms of foraging and escaping predation.

All avian species possess intraorbital gland which consist of the lacrimal and Harderian gland (Dimitrov and Genchev, 2011). The eye requires secretions from the lacrimal and Harderian gland for moistening, nutrition, and controlling orbital and ocular defense (Knop and Knop, 2005; Kozlu and Altunay, 2011). In time, the adenitis would likely result in gland atrophy and fibrosis, a condition that was observed in several of the samples in this study. These conditions cause a deficiency in tear production called keratoconjunctivitis sicca (KCS), which is commonly known as “dry eye”. This KCS condition is likely to lead to corneal ulcerations and a reduction in vision. In addition the inflammatory condition itself would be expected to cause significant morbidity resulting from pressure, swelling, and likely lead to pain associated with inflamed glands. Inflammation was witnessed in all quail samples that were infected.

Several cornea samples appeared cloudy and had signs of early erosions. Corneal damage is often very painful and debilitating when compromised in any manner. The cornea is the most important structure of the ocular surface for the maintenance of visual function (Knop and Knop, 2005) hence, corneal damage may be painful and debilitating. With the Northern bobwhites having an average life span of approximately six months (Hernández and Peterson, 2007) and with the negative impacts of eyeworm infection, it is likely that bobwhites that survive longer harboring these parasites have more inflammation and eye pathology. Additional studies are warranted to determine if pain is associated with inflammation and swelling in bobwhites infected with eyeworms.

Dunham et al. (2015) revealed that eyeworms have a unique mouth structure that we speculate likely enables them to attach





**Fig. 3.** Scanning electron microscope photograph of the head and mouth structure of *Oxyspirura petrowi* removed from a Northern bobwhite (*Colinus virginianus*) captured in the Rolling Plains of Texas, USA.

and potentially feed. The potential implications of attaching eyeworms, along with a high prevalence of infection found within individual quail, would be expected to cause localized tissue trauma and inflammation. To strengthen this hypothesis, Fig. 3 shows the first ever image of an *O. petrowi* mouth structure. If eyeworms do attach to tissues it is likely detrimental to the host; however, determining damage caused by mouth parts was out of the scope of the present study and additional research is needed.

The present study supports the recent data suggesting that *O. petrowi* infection may impact the Northern bobwhite host. Although cause and effect are not proved, we saw a varying degree of lesion severity within the Harderian gland associated with *O. petrowi* infection suggesting a causal relationship, which wasn't previously documented in related studies. While the results of this study cannot determine if *O. petrowi* infection leads to visual impairment, it is likely that the pathological damage associated with infection negatively impacts the eye function and reduces survival. Additional research is needed to determine if *O. petrowi* infections decrease vision and play a role in the fitness, hence survival, of Northern bobwhites.

### Acknowledgments

We thank Park Cities Quail and the Rolling Plains Quail Research Foundation for their continued financial support of our quail research. We thank the Texas A&M Veterinary Medical Diagnostic Laboratory (Amarillo, TX) and Comparative Ocular Pathology Laboratory of Wisconsin (Madison, WI) for performing the pathology evaluation on our quail samples. We thank the owners and employees of our study ranch for allowing access and providing lodging. Lastly we thank members of the Wildlife Toxicology Laboratory for their field and laboratory assistance.

### References

Addison, E.M., Anderson, R.C., 1969. A review of eyeworms of the genus *Oxyspirura*

- (Nematoda: Spiruroidea). *J. Wildl. Dis.* 55, 1–8.
- Bayón, A., Almela, R.M., Talavera, J., 2007. Avian ophthalmology. *Eur. J. Companion Anim. Pract.* 17, 1–13.
- Bruno, A.B., Fedynich, A.M., Smith-Herron, A., Rollins, D., 2015. Pathological response of northern bobwhites to *Oxyspirura petrowi* infections. *J. Parasitol.* 101, 364–368.
- Cram, E.B., 1937. A review of the genus *Oxyspirura*, with a morphological study of *O. petrowi* Skrjabin, 1929, recently discovered in galliform birds of the northern United States. In: *Papers in Helminthology Published in Commemoration of the 30-year Jubilee of K.I. Skrjabin and of 15th Anniversary of the All-Union Institute of Helminthology. All-Union Lenin Academy of Agricultural Sciences, Moscow, Russia*, pp. 89–98.
- Dimitrov, D.S., Genchev, A.G., 2011. Comparative morphometric investigations of intraorbital glands in Japanese quails (*Coturnix coturnix japonica*). *Bulg. J. Vet. Med.* 14, 124–127.
- Dunham, N.R., Bruno, A., Almas, S., Rollins, D., Fedynich, A.M., Presley, S.M., Kendall, R.J., 2016. Eyeworms (*Oxyspirura petrowi*) in Northern bobwhite (*Colinus virginianus*) from the rolling plains of Texas and Oklahoma, 2011–2013. *J. Wildl. Dis.* 52, 562–567.
- Dunham, N.R., Kendall, R.J., 2016. Eyeworm infections of *Oxyspirura petrowi*, Skrjabin, 1929 (Spirurida:Thelaziidae), in species of quail from Texas, New Mexico, and Arizona, USA. *J. Helminthol.* 1–6. <http://dx.doi.org/10.1017/S0022149X16000468>.
- Dunham, N.R., Soliz, L.A., Fedynich, A.M., Rollins, D., Kendall, R.J., 2014. Evidence of an *Oxyspirura petrowi* epizootic in northern bobwhites (*Colinus virginianus*). *J. Wildl. Dis.* 50, 552–558.
- Dunham, N.R., Soliz, L.A., Brightman, A., Rollins, D., Fedynich, A.M., Kendall, R.J., 2015. Live eyeworm (*Oxyspirura petrowi*) extraction, in-vitro culture, and transfer for experimental studies. *J. Parasitol.* 101, 98–101.
- Hernández, F., Peterson, M.J., 2007. Northern bobwhite ecology and life history. In: Brennan, L. (Ed.), *Texas Quails: Ecology and Management*. Texas A&M University Press, College Station, USA, pp. 40–64.
- Jezler, P.C.O.C., Braga, M.B.P., Perlmann, E., Squarzone, R., Borella, M.I., Barros, P.S.M., Milanelo, L., Antunes, A., 2010. Histological analysis of eyeballs of the striped owl *Rhinoptynx clamator*. In: *Microscopy*. In: Mendez-Vilas, A., Diaz, J. (Eds.), *Science, Technology, Applications and Education*. Formatex, Badajoz, Spain, pp. 1047–1054.
- Johnson, J.L., Rollins, D., Reyna, K.S., 2012. What's a quail worth? A longitudinal assessment of quail hunter demographics, attitudes, and spending habits in Texas. *Proc. Nat. Quail Symp.* 7, 294–299.
- Knop, E., Knop, N., 2005. The role of eye-associated lymphoid tissue in corneal immune protection. *J. Anat.* 206, 271–285.
- Kobayashi, H., 1927. On the life history of *Oxyspirura mansoni* and pathological changes in the conjunctiva and the ductus lacrymalis caused by the worm. *Jpn. Pathol. Soc. Trans.* 17, 239–242.
- Korbel, R.T., Habil, M.V., 2011. Avian ophthalmology – Principles and Application. In: *Advancing and Promoting Avian Medicine and Stewardship*, p. 37.
- Kozlu, T., Altunay, H., 2011. Light and electron microscopic studies of the quail (*Coturnix coturnix*) Harderian gland. *J. An. Vet. Adv.* 10, 932–938.
- Lehman, V.W., 1984. *The Bobwhite in the Rio Grande Plain of Texas*. Texas A&M University Press, College Station, USA.
- McClure, H.E., 1949. The eyeworm, *Oxyspirura petrowi*, in Nebraska pheasants. *J. Wildl. Manag.* 13, 303–307.
- Pence, D.B., 1972. The genus *Oxyspirura* (Nematoda:Thelaziidae) from birds in Louisiana. *Proc. Helminthol. Soc. Wash* 39, 23–28.
- Robel, R.J., Walker Jr., T.L., Hagen, C.A., Ridley, R.K., Kemp, K.E., Applegate, R.D., 2003. Helminth parasites of lesser prairie-chicken *Tympanuchus pallidicinctus* in southwestern Kansas: incidence, burdens and effects. *Wildl. Biol.* 9, 341–349.
- Ruff, M.D., Norton, R.A., 1997. Nematodes and acanthocephalans. In: Calnek, B.W., Barnes, H.J., Beard, C.W., McDougald, L.R., Saif, Y.M. (Eds.), *Diseases of Poultry*, tenth ed. Iowa State University Press, Ames, Iowa, pp. 815–850.
- Sanders, D.A., 1929. Manson's eyeworm of poultry. *Fla. Agri Exper. Stn. Bull.* 206, 567–584.
- Saunders, G.B., 1935. Michigan's studies of sharp-tailed grouse. *Trans. Amer. Game Conf.* 21, 342–344.
- Villarreal, S.M., Fedynich, A.M., Brennan, L.A., Rollins, D., 2012. Parasitic eyeworm *Oxyspirura petrowi* in northern bobwhites from the Rolling Plains of Texas, 2007–2011. *Proc. Nat. Quail Symp.* 7, 241–243.
- Xiang, L., Guo, H., Zhang, H., LaCoste, L., Rollins, D., Bruno, A., Fedynich, A., Zhu, G., 2013. Gene discovery, evolutionary affinity and molecular detection of *Oxyspirura petrowi*, an eye worm parasite of game birds. *BMC. Microbiol.* 13, 233.