

# Predictive effects of the intercondylar notch morphology on anterior cruciate ligament injury in males

## A magnetic resonance imaging analysis

Mengquan Huang, MD<sup>a,\*</sup>, Yubiao Li, MD<sup>a</sup>, Hedan Li, MB<sup>b</sup>, Chunlai Liao, MD<sup>a</sup>, Haitao Xu, MD<sup>c</sup>, Xiaowei Luo, MB<sup>a</sup>

### Abstract

The effects of the intercondylar notch morphology on predicting anterior cruciate ligament (ACL) injury in males were unknown. We aimed to determine the risk factors of the intercondylar notch on ACL injury, and evaluate the predictive effects of the morphological parameters on ACL injury in males. Sixty-one patients with ACL injury and seventy-eight patients with intact ACLs were assigned to the case group and control group respectively. The notch width (NW), bicondylar width, notch width index (NWI), notch height (NH), notch cross-sectional area (CSA), notch angle (NA) and notch shape were obtained from the magnetic resonance images of male patients. Comparisons were performed between the case and control groups. Logistic regression model and the receiver operating characteristic curve were used to assess the predictive effects of these parameters on ACL injury. The NW, NWI, NH, CSA and NA in the case group were significantly smaller than those in the control group on the coronal magnetic resonance images. The NW and NWI were significantly smaller, while no significant differences of the NH and CSA were found between the 2 groups on the axial images. There was no significant difference in the notch shape between the 2 groups. The maximum value of area under the curve calculated by combining all relevant morphological parameters was 0.966. The ACL injury in males was associated with NW, NH, NWI, CSA, and NA. These were good indicators for predicting ACL injury in males.

**Abbreviations:** ACL = anterior cruciate ligament, AUC = area under the curve, BW = bicondylar width, CSA = cross-sectional area, ICC = intra-class correlation coefficient, MRI = magnetic resonance imaging, NA = notch angle, NH = notch height, NW = notch width, NWI = notch width index, ROC = receiver operating characteristic.

**Keywords:** anterior cruciate ligament, intercondylar notch, magnetic resonance imaging, risk factor

### 1. Introduction

Anterior cruciate ligament (ACL) injury is the most common ligament injury of the knee joint, accounting for about 50% of knee injuries.<sup>[1]</sup> ACL injury could increase the migration of the

femoral condyle relative to the tibial plateau, and led to secondary meniscus injury and articular cartilage degradation.<sup>[2]</sup> Adolescent patients with ACL injury eventually develop knee osteoarthritis.<sup>[3,4]</sup> However, even ACL reconstruction surgery could not effectively prevent the occurrence of osteoarthritis.<sup>[5]</sup>

The ACL injury was the consequence of multiple factors, such as sports type, anatomical structures, hormones, muscle, and nerve control, and so on.<sup>[6–8]</sup> Anatomical structures were 1 of the risk factors of ACL injury, including the shape of the intercondylar notch and the slope of the tibial plateau. The slope of tibial plateau was identified as a risk factor of ACL injury by biomechanical researches, but the results were controversial on imaging analysis. The ACL collided with the narrow intercondylar notch causing its injury, confirmed by arthroscopic surgery.<sup>[9]</sup> Furthermore, narrow notch have been recognized as an important factor in ACL injury on magnetic resonance imaging (MRI) in many studies.<sup>[10–14]</sup> These studies focused on the correlation between the morphological parameters of the intercondylar notch and ACL injury, but the predictive effects of these parameters on ACL injury have not been reported.

Studies reported women were more prone to suffer ACL rupture.<sup>[15–17]</sup> Several previous studies compared the parameters of intercondylar notch width (NW), notch width index (NWI) and notch shape in female ACL-injured and uninjured patients, or compared the parameters between different genders.<sup>[11,12,14]</sup> The results of these studies were inconsistent. In our department's clinical practice. There were far more men with ACL injuries than women. The main causes of injuries in these patients were sports and military training. It was important for us to guide these male

Editor: Miao Liu.

Disclosure of potential conflicts of interest.

All procedures performed in studies involving human participants were in accordance with the ethical standards of the institutional and/or national research committee.

Orcid id: Available at: <https://orcid.org/0000-0003-4760-0807>

The authors have no funding and no conflicts of interest to disclose.

<sup>a</sup> Department of Orthopaedics, Air Force Hospital of Southern Theater Command of PLA, <sup>b</sup> Department of Orthopaedics and Traumatology, Nanfang Hospital, Southern Medical University, <sup>c</sup> Department of Orthopaedics, Qifu Hospital, Guangzhou, Guangdong Province, China.

\* Correspondence: Mengquan Huang, Department of Orthopaedics, Air Force Hospital of Southern Theater Command of PLA, Guangzhou, 510602, Guangdong Province, China (e-mail: mcquery2019@sina.com).

Copyright © 2020 the Author(s). Published by Wolters Kluwer Health, Inc. This is an open access article distributed under the terms of the Creative Commons Attribution-Non Commercial License 4.0 (CCBY-NC), where it is permissible to download, share, remix, transform, and buildup the work provided it is properly cited. The work cannot be used commercially without permission from the journal.

How to cite this article: Huang M, Li Y, Li H, Liao C, Xu H, Luo X. Predictive effects of the intercondylar notch morphology on anterior cruciate ligament injury in males: a magnetic resonance imaging analysis. *Medicine* 2020;99:10(e19411).

Received: 8 September 2019 / Received in final form: 14 January 2020 /

Accepted: 3 February 2020

<http://dx.doi.org/10.1097/MD.00000000000019411>

populations to avoid ACL injury. It would be meaningful to utilize these intercondylar notch parameters to identify those people at high risk for ACL injury.

In this study, we investigated the morphological parameters including NW, bicondylar width (BW), NWL, notch height (NH), notch cross-sectional area (CSA), notch angle (NA) and notch shape, obtained from the MR images of male patients. We aimed to

- (1) compare those parameters between the patients with and without an ACL injury to determine the risk factors for ACL injury.
- (2) evaluate the predictive effects of the morphological parameters of the intercondylar notch on ACL injury in males.

## 2. Material and methods

This retrospective study included male patients who suffered ACL injury due to non-contact factors, and underwent reconstruction surgery from Jan 2013 to Jan 2018. Those patients were less than 50 years old, and confirmed the diagnosis of ACL injury with arthroscopic surgery and MRI examination. They were allocated as the case group. The subjects in the control group were healthy with intact ACL and without any other ligamentous injuries or meniscus injuries. Patients with history of ACL reconstruction surgery, avulsion fractures of ACL footprint, tibiofibular, and femoral fractures, open ACL injury, hereditary musculoskeletal disorders, osteoarthritis, combined with other knee ligament injuries were excluded. The age, height, weight, and involvement of the knee joint of the patients was recorded. This study was approved by the ethics committee of our hospital (No.SAFH2018082202).

All included cases were examined using a 1.5T MR scanner (AllTech, Chengdu, China). The patient lied supine. The lower extremities were naturally straight and slightly external. The knee flexed about 10°. The coronal, sagittal, and axial scans were performed routinely, and were used to visualize the ligaments and skeletal structures of each knee. The scanning sequences included a spin echo (SE) T1 weighted image (T1WI), a gradient echo (GRE) sequence T2 weighted image (T2WI), a FSE pressure lip sequence. The thickness of each layer was 3 mm, and with a pitch of 0.5 mm. All the MR images of the knee joint were obtained and measured using the pictures archiving and communications system.

On the coronal view of MRI, a slice with the highest tibial spine was chosen. The  $NW_1$  and  $BW_1$  were measured using the method reported by Domzalski et al.<sup>[10]</sup> The  $NW_1$  and  $BW_1$  were measured at the level of the popliteal groove on the lateral condyle of the femur, parallel to the joint line formed by the distal femoral condyles. (Fig. 1 A) The  $NW_{I1}$  was the ratio of  $NW_1$  and  $BW_1$ . The  $NH_1$  was the distance between the tangential line of the top of the intercondylar notch and the distal femoral articular surface. (Fig. 1 C) The notch  $CSA_1$  was the inner area of the closed curve formed along the contour and the entrance of the intercondylar notch. (Fig. 1 E) The NA was formed by the two tangential line of the entrance of the medial and lateral femoral condyle through the highest point of the intercondylar notch. (Fig. 1 G) On the axial view, a slice with the deepest groove of tendon of distal lateral femoral was chosen. The  $NW_2$  and  $BW_2$  were measured using the method reported by Stein et al.<sup>[18]</sup> The  $NW_2$  and the  $BW_2$  were measured parallel to that line at 2/3 of the NH. (Fig. 1 B) The  $NW_{I2}$  was the value of  $NW_2/BW_2$ . The  $NH_2$

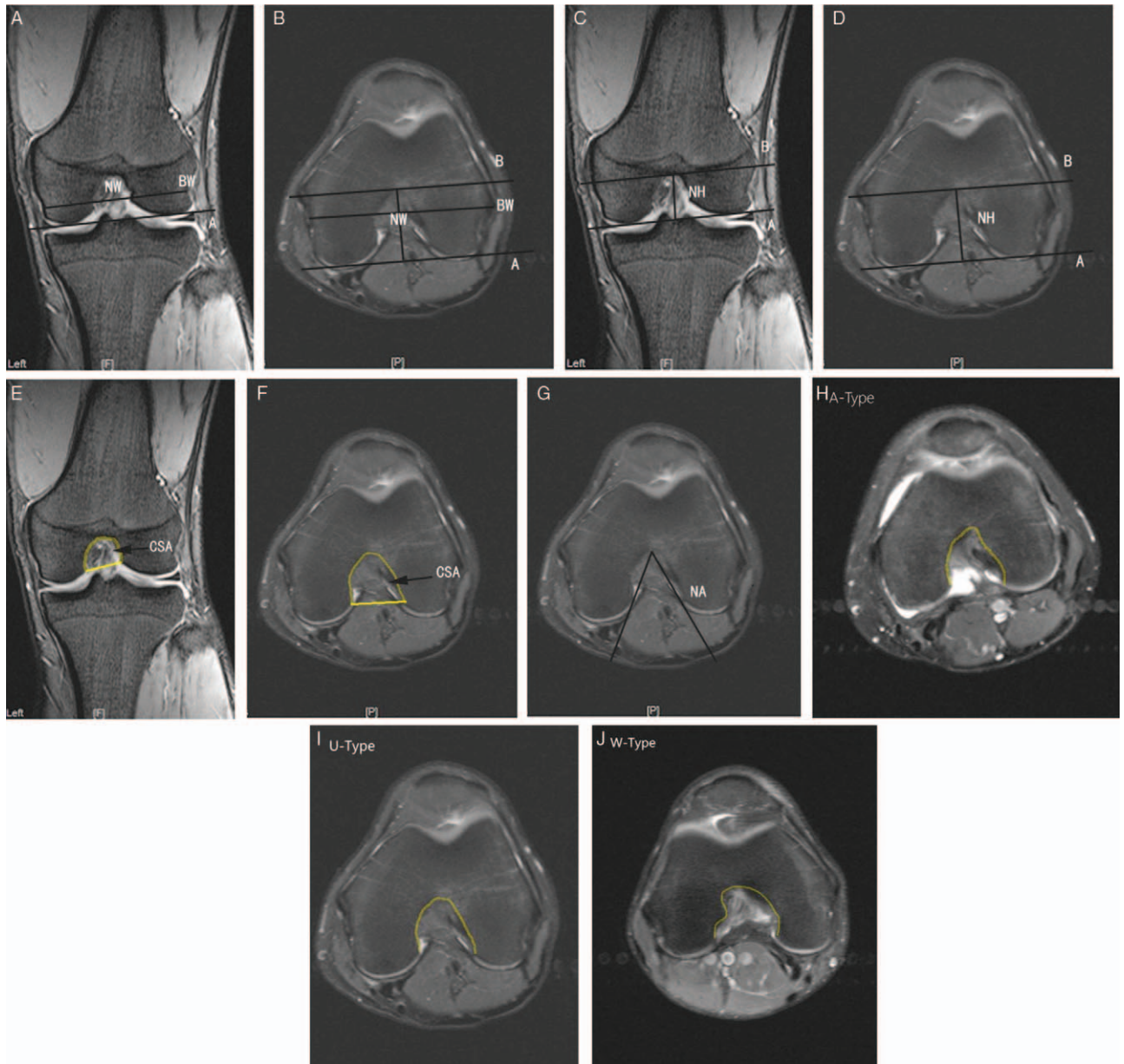
and  $CSA_2$  on axial sequence were measured using the same way as the coronal view. (Fig. 1 D,F) The notch shape was identified using the description reported by van Eck et al.<sup>[19]</sup> A-Type is characterized by a narrow and long intercondylar notch. Its top looks like the apex of an acute triangle. U-Type is more spacious than the A-type and has a smoother top. W-Type has 2 vertices to distinguish it from A-type and U-type. (Fig. 1 H-J) In this study, the U-type and W-type were combined for analysis. Two observers were trained to measure the parameters of 30 samples independently before the study. Then they carried out the measurements without any knowledge of patients characteristics.

Data was analyzed using statistical software SPSS 13.0 (SPSS Inc, Chicago, IL). Measurement data are expressed as mean  $\pm$  standard deviation ( $\bar{x} \pm s$ ). Student *t* test or Chi-square test was utilized to compare the data between different groups. Binary logistic regression analysis was conducted to determine the influence of the parameters on ACL injury. The dependent variable was defined as “ACL status” (0, injured; 1, intact). The receiver operating characteristic (ROC) curve was drawn according to the probability calculated by these morphological parameters respectively. When making a multi-index combined ROC curve, the parameters that needed to be combined and analyzed were used as covariates, the ACL state was used as the dependent variable, and the combined probability was calculated using logistic regression analysis. This probability value was the result obtained by combining each included index in the multi-factor analysis equation. Then it was used as a test variable to make the ROC curve. The area under the curve (AUC) was calculated. The Youden Index was the value of sensitivity + specificity -1. The maximum value of the index was used to determine the cut-off value of the parameters. The intra-class correlation coefficient (ICC) was used to determine the inter-observer and intra-observer reliability. The ICC was 0.92 and 0.93 for inter-observer and intra-observer reliability respectively. A *P*-value < .05 was considered statistically significant.

## 3. Results

A total of 139 male patients were enrolled in the study, with an average age of 25.38 years old (16–44 years). Among them, 61 patients and 78 patients were allocated in the case group and control group respectively. There was no significant difference in the basic characteristics between the case and control groups. (Table 1) On the coronal MR images, the  $NW_1$  and  $NW_{I1}$  in the case group were significantly smaller than those in the control group ( $P < .001$ ,  $P < .001$ ). There was no significant difference in the  $BW_1$  between the 2 groups ( $P = .173$ ). The  $NH_1$  and  $CSA_1$  in the case group were significantly smaller than those in the control group ( $P < .001$ ,  $P < .001$ ). On the axial images, the  $NW_2$  and  $NW_{I2}$  in the case group were significantly smaller than those in the control group ( $P = .035$ ,  $P < .001$ ). The  $BW_2$  in the case group was larger than that in the control group, and the difference was statistically significant ( $P < .001$ ). There were no significant differences in  $NH_2$  and  $CSA_2$  between the case group and the control group ( $P = .458$ ,  $P = .338$ ). The NA was significantly smaller in the case group than that in the control group ( $P = .018$ ). There were 30 cases of A-type and 31 cases of (U+W)-type in the case group, 46 cases of A-type and 32 cases of (U+W)-type in the control group. There was no significant difference in the notch shape between the 2 groups ( $P = .173$ ). (Table 2).

Using binary logistic regression models, the AUC values of  $NW_{I1}$ ,  $NW_1$  and  $CSA_1$  were 0.766, 0.760, and 0.757,



**Figure 1.** Measurement of morphological parameters of the intercondylar notch. A and B: The notch width (NW) and bicondylar width (BW) on coronal and axial images. C and D: the notch height (NH) on coronal and axial images. E and F: The notch cross-sectional area (CSA) on coronal and axial images. G: the notch angle. H: A-type, I: U-type; J: W-type.

respectively, higher than others. The cut-off values were 0.2809, 2.1450, and 3.0950, respectively. The AUC value, cut-off value, sensitivity and specificity of the morphological parameters associated with ACL injury were showed in Table 3. The ROC curves were drawn according to the combined probabilities

calculated from those morphological parameters, and the AUC value was calculated. Among them, the combined AUC value of  $NW_1, NW_{11}, NW_2, BW_2,$  and  $NW_{12}$  could reach 0.914. When all the relevant parameters were combined, the AUC value could reach a maximum of 0.966. (Table 4, Fig. 2).

**Table 1**  
**Basic characterize of the case and control groups.**

	Case group (n=61)	Control group (n=78)	P-value
Knee (Left/right)	36/25	41/37	.494
Age, yr	26.16 ± 5.79	24.77 ± 4.49	.112
Weight (kg)	72.14 ± 4.46	71.58 ± 5.62	.524
Height (cm)	173.67 ± 4.81	173.19 ± 4.85	.562

**4. Discussion**

The most important finding of this study was the combined morphological parameters of the intercondylar notch, which can predict ACL injury with high accuracy. We found the parameters of the notch had different effects on ACL injury. The predictive effect of each parameter on the ACL injury was low to medium accuracy. Among those parameters, the coronal NWI had the highest accuracy, followed by the coronal NW, and again the



**Table 2**  
**comparison of the morphology parameters between the case and control groups.**

	Case group (n=61)	Control group (n=78)	P-value
NW <sub>1</sub>	2.00±0.17	2.20±0.22	<.001*
BW <sub>1</sub>	7.14±0.30	7.22±0.32	.173
NWI <sub>1</sub>	0.28±0.02	0.30±0.03	<.001*
NH <sub>1</sub>	2.37±0.22	2.60±0.34	<.001*
CSA <sub>1</sub>	2.83±0.43	3.93±0.59	<.001*
NW <sub>2</sub>	1.84±0.19	1.92±0.24	.035*
BW <sub>2</sub>	7.78±0.39	7.48±0.40	<.001*
NWI <sub>2</sub>	0.24±0.02	0.26±0.03	<.001*
NH <sub>2</sub>	2.89±0.23	2.92±0.30	.458
CSA <sub>2</sub>	3.88±0.57	3.98±0.66	.338
NA	50.36±5.70	53.75±7.67	.018*

BW=bicondylar width, CSA=cross-sectional area, NA=notch angle, NH=notch height, NW=notch width, NWI=notch width index.

\* P<0.05, statistically significant.

coronal notch CSA. The effect of a single factor predicting the ACL rupture was limited. When combined all relevant morphological parameters, the AUC value was increased to a maximum of 0.966. The accuracy of predicting ACL rupture had been considerably improved. This also suggested that the abnormalities of the intercondylar notch might be the most important cause of ACL injury. Measuring multiple morphological parameters of the notch was valuable to predict ACL damage.

In this study, we found that both on the axial and coronal MR images, the NW, and NWI of the male in the case group were

significantly smaller than the control group, and they were risk factors of ACL injury in male patients. Most studies have confirmed that intercondylar notch stenosis was an independent factor in ACL injury, and patients with intercondylar notch stenosis had smaller NWI than healthy people.<sup>[20-23]</sup> Guermazi et al<sup>[24]</sup> proposed that only NWI was a risk factor for male ACL injury. Another study found that NW was associated with male ACL injury, while NWI was not relevant.<sup>[6]</sup> Domzalski et al<sup>[25]</sup> and van Diek et al<sup>[26]</sup> reported no significant difference in NWI between ACL-injured and non-injured patients in the male or female patients. Although the results were not completely consistent, a meta-analysis study concluded that smaller NWI or NW predicts that ACLs were more susceptible to injury.<sup>[27]</sup> Previous studies had suggested that NWI was lower than 0.269, 0.21, and 0.20 when the intercondylar notch was narrow. Nevertheless, these studies had not proposed the methods to calculate the cut-off value.<sup>[18,20,28]</sup> The Youden Index indicates the total ability of a diagnostic experiment to identify a truly affected or non-affected subject. The greater the value, the better the authenticity of the diagnostic experiment. In this study, the cut-off value was determined based on this quota. When the NWI on the axial MR image was lower than 0.2403, or the value on the coronal image was less than 0.2809, suggesting the ACL with high risk to rupture.

Another finding of this study was that on the coronal MR images, the NH and the CSA in the case group were significantly smaller than those in the control group of male patients. It suggested that NH and CSA were associated with male ACL injury. Previous study reported the ratio of the NH to the medial femoral condyle height had no significant correlation with ACL

**Table 3**  
**The AUC value and cut-off value of the morphology parameters associated with ACL injury.**

	AUC	P-value	95%CI	Cut-off value	Sensitivity, specificity
NW <sub>1</sub>	0.760	<.001*	0.680,0.841	2.1450	0.641,0.836
NWI <sub>1</sub>	0.766	<.001*	0.685,0.846	0.2809	0.833,0.557
NH <sub>1</sub>	0.729	<.001*	0.646,0.812	2.4950	0.654,0.721
CSA <sub>1</sub>	0.757	<.001*	0.678,0.836	3.0950	0.705,0.705
NW <sub>2</sub>	0.611	.025*	0.517,0.705	1.8750	0.628,0.623
BW <sub>2</sub>	0.708	<.001*	0.622,0.794	7.7450	0.769,0.492
NWI <sub>2</sub>	0.693	<.001*	0.606,0.780	0.2403	0.705,0.623
NH <sub>2</sub>	0.538	.449	0.442,0.633	3.1650	0.231,0.902
CSA <sub>2</sub>	0.538	.440	0.442,0.634	4.3100	0.308,0.803
NA	0.616	.018*	0.525,0.710	47.2950	0.795,0.344

AUC=area under the curve, BW=bicondylar width, CSA=cross-sectional area, NA=notch angle, NH=notch height, NW=notch width, NWI=notch width index.

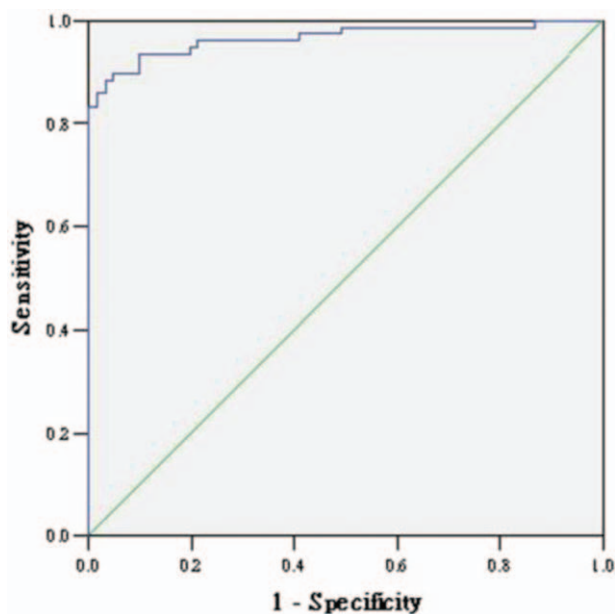
\* P<.05, statistically significant.

**Table 4**  
**Combined the morphology parameters for predicting ACL injury.**

	AUC	P-value	95%CI
NW <sub>1</sub> + NWI <sub>1</sub>	0.769	<.001*	0.689, 0.848
NW <sub>2</sub> + BW <sub>2</sub> + NWI <sub>2</sub>	0.744	<.001*	0.664, 0.825
NH <sub>1</sub> + CSA <sub>1</sub>	0.760	<.001*	0.681, 0.838
NW <sub>1</sub> + NWI <sub>1</sub> + NW <sub>2</sub> + BW <sub>2</sub> + NWI <sub>2</sub>	0.914	<.001*	0.866, 0.961
NW <sub>1</sub> + NWI <sub>1</sub> + NH <sub>1</sub> + CSA <sub>1</sub> + NW <sub>2</sub> + BW <sub>2</sub> + NWI <sub>2</sub>	0.949	<.001*	0.916, 0.983
NW <sub>1</sub> + NWI <sub>1</sub> + NH <sub>1</sub> + CSA <sub>1</sub> + NW <sub>2</sub> + BW <sub>2</sub> + NWI <sub>2</sub> + NA	0.950	<.001*	0.918, 0.982
NW <sub>1</sub> + NWI <sub>1</sub> + NH <sub>1</sub> + CSA <sub>1</sub> + NW <sub>2</sub> + BW <sub>2</sub> + NWI <sub>2</sub> + NH <sub>2</sub> + CSA <sub>2</sub> + NA	0.966	<.001*	0.937, 0.995

AUC=area under the curve, BW=bicondylar width, CSA=cross-sectional area, NA=notch angle, NH=notch height, NW=notch width, NWI=notch width index.

\* P<.05, statistically significant.



**Figure 2.** The ROC curve drawn by combining the morphological parameters of the intercondylar notch was used to predict ACL injury (AUC=0.966). ACL = anterior cruciate ligament, AUC = area under the curve, ACL = anterior cruciate ligament.

injury.<sup>[29]</sup> The NH limited the range of motion of the ACL in the longitudinal direction. When the height of the notch was lower, the ACL was more likely to collide with the notch to cause injury during the motion of the knee joint. The CSA of the notch limited the range of movement of the ACL in a plane. The smaller the CSA, the more observable the limitation of ACL activity, and the greater the possibility of collision with the notch wall, the more liable the injury was. In this study, when the NH and CSA on the coronal images were lower than 2.4950, and 3.0950, respectively, suggesting that ACL was prone to injury.

Whether or not the NA was related to ACL injury continuing to be controversial. In this study, we found the NA of the case group was significantly smaller than the control group, which was a risk factor of ACL injury in male patients. Previous studies reported that if the NA was less than or equal to 50°, it might lead to ACL injury.<sup>[30,31]</sup> However, other studies had suggested that smaller NA did not increase the risk of ACL injury.<sup>[18,28,29]</sup> In this work, the average NA value of male patients in the ACL injury group was 50.36, which was similar to the results of previous studies.<sup>[29,30]</sup> According to logistic regression analysis, when the NA was less than 47.2950, it suggested that the ACL was easy to be injured.

There was still some controversy about the relationship between the shape of the notch and ACL injury. This study showed that the A-type notch was not a relevant factor for male ACL injury. Previous studies found that U-type notch was usually not prone to stenosis, and the width of the A-type notch was smaller than that of the other two types by MRI or arthroscopy.<sup>[19,28,31]</sup> Those patients were more prone to ACL injury. Shen et al<sup>[29]</sup> considered that the proportion of A-type in the ACL injury group was greater than in the control group, but there was no significant correlation with ACL injury. When the notch entrance was small, the U-type notch would have a small

NA, but the NW or NWI was large. Therefore, the effect of the notch shape on ACL injury was uncertain.

There were still some shortcomings in this study. First, The prediction of ACL injury in women was also of great research importance. Because of the small sample size of female patients, the study was conducted only for male patients to avoid errors. Second, included cases were available from the same hospital. There was sample selection bias. Lastly, there might be some deviation in the position of the knee joint during the MR examination, which might influence the results.

In conclusion, ACL injury in males was associated with NW, height, width index, CSA, and NA. Combined analysis of various morphological parameters could identify the people prone to affect ACL rupture more accurately.

## Author contributions

**Conceptualization:** Mengquan Huang.

**Data creation:** Yubiao Li, Hedan Li, Xiaowei Luo.

**Investigation:** Haitao Xu, Chunlai Liao.

**Data analysis:** Mengquan Huang, Haitao Xu.

**Supervision:** Mengquan Huang, Yubiao Li.

**Writing:** Mengquan Huang.

## References

- [1] Lesic A, Bumbasirevic M. The clinical anatomy of cruciate ligament and its relevance in anterior ligament (ACL) reconstruction. *Folia Anat* 1999;27:1–1.
- [2] Cohen M, Amaro JT, Ejnisman B, et al. Anterior cruciate ligament reconstruction after 10 to 15 years: association between meniscectomy and osteoarthritis. *Arthroscopy* 2007;23:629–34.
- [3] Simon D, Mascarenhas R, Auid O, et al. The relationship between anterior cruciate ligament injury and osteoarthritis of the knee. *Adv orthop* 2015;2015:928301.
- [4] Dare D, Rodeo S. Mechanisms of post-traumatic osteoarthritis after ACL injury. *Curr rheumatol rep* 2014;16:448.
- [5] Barenus B, Ponzer S, Shalabi A, et al. Increased risk of osteoarthritis after anterior cruciate ligament reconstruction: a 14-year follow-up study of a randomized controlled trial. *Am J Sports Med* 2014;42:1049–57.
- [6] Park JS, Nam DC, Kim DH, et al. Measurement of knee morphometrics using MRI: a comparative study between ACL-injured and non-injured knees. *Knee Surg Relat Res* 2012;24:180–5.
- [7] Dunning A, Ghoreysy A, Bertuccio M, et al. The tuning of human motor response to risk in a dynamic environment task. *PLoS One* 2015;10:e0125461.
- [8] Romani W, Patrie J, Curl LA, et al. The correlations between estradiol, estrone, estriol, progesterone, and sex hormone-binding globulin and anterior cruciate ligament stiffness in healthy, active females. *J Womens Health* 2003;12:287–98.
- [9] Fu FH, Musahl V. Anatomic ACL reconstruction. *Clin Sports Med* 2013;32:xv–i.
- [10] Domzalski M, Grzelak P, Gabos P. Risk factors for anterior cruciate ligament injury in skeletally immature patients: analysis of intercondylar notch width using magnetic resonance imaging. *Int Orthop* 2010;34:703–7.
- [11] Bouras T, Fennema P, Burk S, et al. Stenotic intercondylar notch type is correlated with anterior cruciate ligament injury in female patients using magnetic resonance imaging. *Knee Surg Sports Traumatol Arthrosc* 2017;26:1252–7.
- [12] Dienst M, Schneider G, Altmeyer K, et al. Correlation of intercondylar notch cross sections to the ACL size: a high resolution MR tomographic in vivo analysis. *Arch orthop trauma surg* 2007;127:253–60.
- [13] Lombardo S, Sethi PM, Starkey C. Intercondylar notch stenosis is not a risk factor for anterior cruciate ligament tears in professional male basketball players: an 11-year prospective study. *Am J Sports Med* 2005;33:29–34.
- [14] Stijak L, Radonji V, Nikoli V, et al. Correlation between the morphometric parameters of the anterior cruciate ligament and the intercondylar width: gender and age differences. *Knee Surg Sports Traumatol Arthrosc* 2009;17:812–7.

- [15] Arendt E, Dick R. Knee injury patterns among men and women in collegiate basketball and soccer. NCAA data and review of literature. *Am J Sports Med* 1995;23:694–701.
- [16] Bjordal JM, Arnly F, Hannestad B, et al. Epidemiology of anterior cruciate ligament injuries in soccer. *Am J Sports Med* 1997;25:341–5.
- [17] Toth AP, Cordasco FA. Anterior cruciate ligament injuries in the female athlete. *J Gend Specific Med* 2001;4:25–34.
- [18] Stein V, Li L, Guerhazi A, et al. The relation of femoral notch stenosis to ACL tears in persons with knee osteoarthritis. *Osteoarthritis Cartilage* 2010;18:192–9.
- [19] van Eck CF, Martins CA, Vyas SM, et al. Femoral intercondylar notch shape and dimensions in ACL-injured patients. *Knee Surg Sports Traumatol Arthrosc* 2010;18:1257–62.
- [20] Sonnery-Cottet B, Archbold P, Cucurulo T, et al. The influence of the tibial slope and the size of the intercondylar notch on rupture of the anterior cruciate ligament. *J Bone Joint Surg Br* 2011;93:1475–8.
- [21] Ireland ML, Ballantyne BT, Little K, et al. A radiographic analysis of the relationship between the size and shape of the intercondylar notch and anterior cruciate ligament injury. *Knee Surg Sports Traumatol Arthrosc* 2001;9:200–5.
- [22] Keays SL, Keays R, Newcombe PA. Femoral intercondylar notch width size: a comparison between siblings with and without anterior cruciate ligament injuries. *Knee Surg Sports Traumatol Arthrosc* 2016;24:672–9.
- [23] Shaw KA, Dunoski B, Mardis N, et al. Knee morphometric risk factors for acute anterior cruciate ligament injury in skeletally immature patients. *J Child Orthop* 2015;9:161–8.
- [24] Guerhazi A, Roemer FW, Haugen IK, et al. MRI-based semiquantitative scoring of joint pathology in osteoarthritis. *Nat Reviews Rheumatol* 2013;9:236–51.
- [25] Domzalski ME, Keller MS, Grzelak P, et al. MRI evaluation of the development of intercondylar notch width in children. *Surg Radio Ana* 2015;37:609–15.
- [26] van Diek FM, Wolf MR, Murawski CD, et al. Knee morphology and risk factors for developing an anterior cruciate ligament rupture: an MRI comparison between ACL-ruptured and non-injured knees. *Knee Surg Sports Traumatol Arthrosc* 2014;22:987–94.
- [27] Zeng C, Gao SG, Wei J, et al. The influence of the intercondylar notch dimensions on injury of the anterior cruciate ligament: a meta-analysis. *Knee Surg Sports Traumatol Arthrosc* 2013;21:804–15.
- [28] Al-Saeed O, Brown M, Athyal R, et al. Association of femoral intercondylar notch morphology, width index and the risk of anterior cruciate ligament injury. *Knee Surg Sports Traumatol Arthrosc* 2013;21:678–82.
- [29] Shen L, Jin ZG, Dong QR, et al. Anatomical risk factors of anterior cruciate ligament injury. *Chin Med* 2018;131:2960–7.
- [30] Alentorn-Geli E, Pelfort X, Mingo F, et al. An evaluation of the association between radiographic intercondylar notch narrowing and anterior cruciate ligament injury in men: the notch angle is a better parameter than notch width. *Arthroscopy* 2015;31:2004–13.
- [31] Anderson AF, Lipscomb AB, Liudahl KJ, et al. Analysis of the intercondylar notch by computed tomography. *Am J Sports Med* 1987;15:547–52.