

Risk Stratification of Oral Potentially Malignant Disorders in Fanconi Anemia Patients Using Autofluorescence Imaging and Cytology-On-A Chip Assay^{1,2}



Timothy J. Abram^{*,†}, Curtis R. Pickering[‡], Alexander K. Lang[§], Nancy E. Bass[§], Rameez Raja^{*,§}, Cynthia Meena[§], Amin M. Alousi[†], Jeffrey N. Myers[‡], John T. McDevitt[†], Ann M. Gillenwater[‡] and Nadarajah Vigneswaran[§]

*Rice University, Department of Bioengineering, Houston, Texas; [†]New York University, Department of Biomaterials, New York, NY, USA; [‡]University of Texas M. D. Anderson Cancer Center, Department of Head and Neck Surgery, Houston, Texas, USA; [§]University of Texas School of Dentistry, Department of Diagnostic and Biomedical Sciences, Houston, Texas, USA; [¶]University of Texas M. D. Anderson Cancer Center, Department of Stem Cell Transplantation, Houston, Texas, USA

Abstract

Fanconi anemia (FA) is a hereditary genomic instability disorder with a predisposition to leukemia and oral squamous cell carcinomas (OSCCs). Hematopoietic stem cell transplantation (HSCT) facilitates cure of bone marrow failure and leukemia and thus extends life expectancy in FA patients; however, survival of hematologic malignancies increases the risk of OSCC in these patients. We developed a “cytology-on-a-chip” (COC)-based brush biopsy assay for monitoring patients with oral potentially malignant disorders (OPMDs). Using this COC assay, we measured and correlated the cellular morphometry and Minichromosome Maintenance Complex Component 2 (MCM2) expression levels in brush biopsy samples of FA patients' OPMD with clinical risk indicators such as loss of autofluorescence (LOF), HSCT status, and mutational profiles identified by next-generation sequencing. Statistically significant differences were found in several cytology measurements based on high-risk indicators such as LOF-positive and HSCT-positive status, including greater variation in cell area and chromatin distribution, higher MCM2 expression levels, and greater numbers of white blood cells and cells with enlarged nuclei. Higher OPMD risk scores were associated with differences in the frequency of nuclear aberrations and differed based on LOF and HSCT statuses. We identified mutation of FAT1 gene in five and NOTCH-2 and TP53 genes in two cases of FA patients' OPMD. The high-risk OPMD of a non-FA patient harbored FAT1, CASP8, and TP63 mutations. Use of COC assay in combination with visualization of LOF holds promise for the early diagnosis of high-risk OPMD. These minimally invasive diagnostic tools are valuable for long-term surveillance of OSCC in FA patients and avoidance of unwarranted scalpel biopsies.

Translational Oncology (2018) 11, 477–486

Address all correspondence to: Dr. Nadarajah Vigneswaran, University of Texas School of Dentistry at Houston, Department of Diagnostic and Biomedical Sciences, 7500 Cambridge Street, Suite 5371, Houston, TX 77054, USA.

E-mail: Nadarajah.Vigneswaran@uth.tmc.edu

¹Disclosure of Potential Conflicts of Interest: John McDevitt is one of the founders of SensoDx and serves as the chief scientific officer for the same. All other authors disclosed no potential conflicts of interest relevant to this publication.

²Financial Support: This work was supported by the National Institutes of Health through the National Institute of Dental and Craniofacial Research (award number R01DE024392) (N.V.), The Cancer Prevention and Research Institute of Texas (award number RP101382) (J.M./N.V.), UTHealth-Center for Clinical and Translational Sciences Pilot Award (N.V./J.M./A.G.), and University of Texas M.D.

Anderson Cancer Center Head and Neck SPORE Developmental Research Program Award (N.V./A.G./A.A.). The COC assay platform described in this work is currently being developed for commercial use through an SBIR Fast Track Phase I/II grant (award number R44DE025798)(J.M.). This content is solely the responsibility of the authors and does not necessarily represent or reflect the official views of the National Institutes of Health or the US government.

Received 15 November 2017; Revised 12 January 2018; Accepted 16 January 2018

© 2018 The Authors. Published by Elsevier Inc. on behalf of Neoplasia Press, Inc. This is an open access article under the CC BY-NC-ND license (<http://creativecommons.org/licenses/by-nc-nd/4.0/>). 1936-5233/18

<https://doi.org/10.1016/j.tranon.2018.01.014>

Introduction

Fanconi anemia (FA; MIM 227650) is an inherited genomic instability disorder clinically characterized by congenital abnormalities, progressive bone marrow failure, and increased cancer susceptibility [1,2]. FA is caused by genetic deficiencies in one of at least 22 FA genes (FANCA-W) critical for DNA repair and maintaining genomic stability during DNA replication and transcription [3–5]. Loss of function mutations in 21 FA genes function in a recessive manner [5] and predispose these patients to acute myeloid leukemia and head and neck squamous cell carcinoma (HNSCC). FA patients' risk for HNSCC is 500 to 1000 times greater than the general population [6–9]. Oral squamous cell carcinoma (OSCC) is the most common type of HNSCC seen in FA patients, which frequently involves the tongue and gingiva and is also associated with extensive premalignant changes [9,10]. OSCC in FA patients occurs at a younger age than the general population (range=15–49-years, median=31 years) without traditional risk factors (e.g., smoking, alcohol, and oncogenic HPV infection) [11]. These tumors have an aggressive biologic behavior characterized by poor survival and high relapse rates [7–11]. Allogeneic hematopoietic stem cells transplantation (HSCT) is the only potential cure available for the hematologic disorders of FA patients; however, HSCT increases the risk for OSCC [8,9,12,13]. The cumulative incidence of OSCC in FA patients who had HSCT is estimated to be almost 100% by 45 years of age, whereas FA patients without HSCT have half of this risk [9,14]. Increased risk for OSCC in FA patients with HSCT is attributed to the conditioning regimen and the occurrence of chronic graft-versus-host disease (cGVHD) in the oral cavity but may also be a function of increased longevity in FA patients, allowing time to develop OSCC [9,15].

Despite improvement of the survival rate and quality of life of FA patients after undergoing HSCT, OSCC and oral potentially malignant disorder (OPMD) remain leading causes of morbidity and mortality [10]. Radiation and chemotherapy are not recommended for FA patients because of side effects and complications related to the defects in DNA damage repair of the normal tissue [10]. Surgical resection is the primary mode of treatment for OSCC in FA patients with an overall 5-year survival rate of 39%, which is significantly lower than the general population [10]. At the time of diagnosis, the majority of the FA patients with OSCC are ineligible for curative surgical treatment, and among those amenable to surgery, the majority will relapse, resulting in the high mortality rate [10]. The best option to improve survival rates of FA patients with OSCC is early detection, preferably at its precursor stage. Most OSCCs in FA patients arise in precursor lesions, called oral potentially malignant disorders [16]. OPMD in FA patients commonly present as a white patch (leukoplakia), a red patch (erythroplakia), or a lichen planus–like (lichenoid) lesion [8,9,16]. Given the increased risk for OSCC, FA patients must undergo at least semiannual oral cancer screenings by an experienced clinician beginning at the age of 10 to 12 years [17–20]. Diagnosis of OPMD in the general population is based on conventional oral examination (COE), with scalpel biopsy of lesions deemed clinically suspicious [21]. COE has poor sensitivity and specificity in discriminating OPMD from other benign lesions, resulting in unnecessary biopsies [22,23]. Decision for an incisional biopsy of OPMD in non-FA patients is based on the clinical characteristics and locations of the lesions [23]. While this approach may be valuable in non-FA patients, it has limitations in OPMD of FA patients; the clinical appearance and sites of OPMD in FA patients are not reliable indicators of malignant transformation risk. OPMDs of FA patients with innocuous clinical presentation

frequently exhibit dysplasia, p53 positivity, and loss of heterozygosity, features that carry the highest risk for transforming into cancer [7,8]. OPMDs are far more prevalent in FA patients and occur at a younger age than the general population. They can be multifocal, involving large areas, often resulting in sampling errors with scalpel biopsy. Hence, close surveillance of OPMD in FA patients requires repeat biopsies. Many physicians and dentists are reluctant to repeat invasive biopsies in FA patients and elect to monitor these lesions by visual examination, which often leads to delay in OSCC diagnosis. There is a desperate need for better and less invasive diagnostic aids for the detection of OSCC and high-risk OPMD in FA patients that can complement COE. Loss of fluorescence (LOF) visualization of the oral cavity using VELscope (Visually Enhanced Lesion Scope; LED Dental Inc., White Rock, BC, Canada) is more sensitive than COE for detection of OPMD, but is not specific, resulting in many false-positive findings [22,24]. In a recent study, we demonstrated the utility of a cytology-on-chip (COC) assay for quantifying cellular and nuclear morphometry for risk assessments of OPMD in non-FA patients [25]. Combination of these approaches may result in reducing diagnostic errors in detecting precancer and cancer in this high-risk population. In this study, we explored the performance of LOF coupled with COC assay for detection and risk assessment of OPMD in FA patients. In addition, we evaluated the feasibility of using brush biopsies of OPMD from a cohort of FA patients to identify HNSCC-related mutations.

Materials and Methods

Study Population

The Institutional Review Board of the University of Texas Health Science Center at Houston reviewed, approved, and monitored this study. Fifty-nine FA patients over the age of 18 years who attended the Meeting for Adults with Fanconi Anemia held in Baltimore in March 2014 and Orlando in February 2016 participated in this study. These patients voluntarily consented to participate in screening and collection of OPMD brush biopsy samples. FA and non-FA patients who participated in this study completed a survey form consisting of patient demographic and known risk factor info for OSCC. Figure 1 illustrates the schematics of the study procedure. Brush biopsy samples of non-FA patients with cGVHD, oral lichen planus (OLP) and proliferative verrucous leukoplakia (PVL) were also used in the next-generation sequencing (NGS) analysis for comparison.

Study Procedure

Clinicians with expertise in oral cancer screening first performed COE of FA patients by visual inspection and palpation to identify OPMD. Following COE, OPMDs were examined using VELscope for LOF, and brush biopsy samples were obtained of these lesions and nonlesional mucosae from the contralateral sites using soft Rovers Orcellex brushes (Rovers Medical Devices B.V., Oss, the Netherlands). These samples were transported in ThinPrep Cytolyt (Hologic, Marlborough, MA) for the COC assay. Brush biopsy samples of FA patients were analyzed using the COC assay platform as described previously [25,26], summarized below.

COC Assay–Based Measurements of the Brush Biopsy Samples

The COC assay platform uses quantitative cytomorphometric and molecular biomarker measurements from single cells to compute a simple, intuitive risk score for OPMD. The system is comprised of a

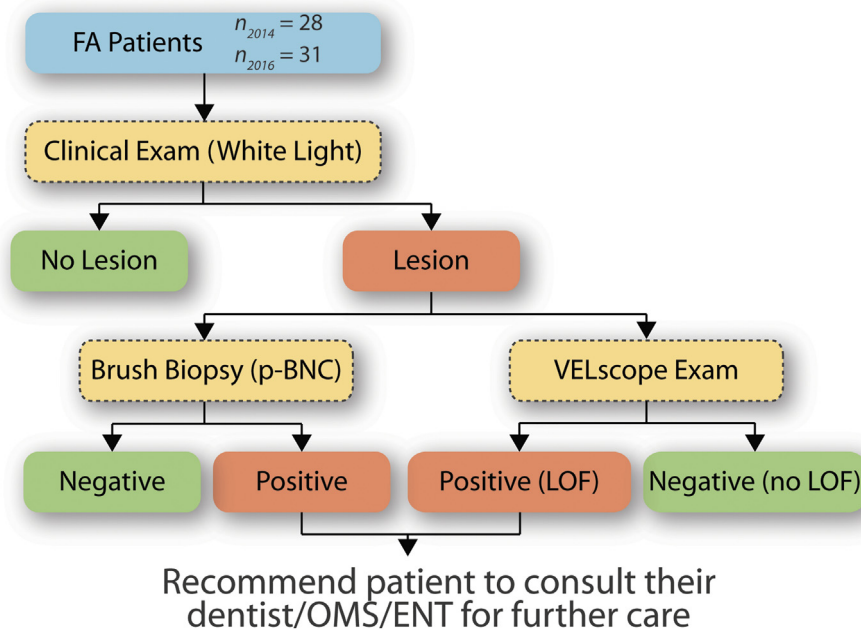


Figure 1. Study design flowchart: FA patients were first subjected to a conventional oral cancer screening by visual inspection and palpation under white light to identify the oral mucosal lesions suspicious of OPMD. If lesions suspicious of OPMD were identified, these were evaluated with autofluorescence visualization using the VELscope and brush biopsy for COC brush biopsy test.

disposable microfluidic cartridge, a high-resolution fluorescence analyzer, and a set of risk assessment algorithms previously validated on non-FA patients with OPMD [25]. Upon arrival, brush biopsy samples from FA patients were vortexed to produce a cell suspension and dispensed onto disposable microfluidic cartridges designed to isolate individual cells and deliver a cocktail of fluorescently labeled reagents. For the COC assays performed in this study, these reagents included DAPI (Life Technologies #D3571) as a nuclear stain, Phalloidin-AlexaFluor-647 (Life Technologies #A22287) as a cytoplasmic stain, and indirect immunostaining reagents for MCM2, a nuclear cell proliferation marker (primary: Abcam #Ab108935, secondary: Life Technologies #A11070). Following assay completion, fluorescent images were recorded of the cytology sample and analyzed through a series of custom software modules, resulting in 310 cytomorphometric measurements (152 nuclear parameters and 158 cytoplasmic parameters) for each identified cell. Parameters of interest used in this study included distributions and average values for cell area; nuclear area; nuclear perimeter; nuclear DAPI displacement, the distance between the fluorescence intensity weighted average and the object centroid and used as a surrogate for chromatin distribution; MCM2 expression derived from nuclear fluorescence intensity; frequency of various nuclear aberrations including binucleated cells, micronucleated cells, and cells with enlarged nuclei; and white blood cell (WBC) count. Nuclear phenotypes automatically identified by the COC assay algorithm were manually confirmed by a trained user using published criteria for identifying nuclear anomalies in buccal mucosa [27,28]. In this study, statistical analyses of quantitative cytology measurements utilized Student's *t* test for independent samples for subgroups of FA OPMD based on either LOF or HSCT status.

COC Assay–Based Risk Score Assignment for the Brush Biopsy Samples FA Patients' OPMD

In addition to quantitative cytology measurements, a quantitative “risk index score” developed from a previous study involving non-FA

OPMD [25] was applied to the present FA patient cohort to translate lesion severity into a continuous numeric scale between 0 and 100. Prior training of the risk index algorithm yielded the following interval definitions and accuracies: 0 to 4: “normal” (97.6%), 4 to 25: “benign” (76.0%), 25 to 75: “dysplastic” (82.4%), and 75 to 100: “malignant” (89.6%) [29].

Targeted NGS of the Brush Samples of OPMD

Thirty-nine DNA samples isolated from OPMD brush biopsies of 19 patients were submitted for targeted NGS. DNA isolated from brush biopsies of the following samples passed DNA quality control and was subjected for targeted NGS: 1) OPMD of FA patients (11 lesions samples from 8 patients) and corresponding normal mucosa (5 samples from 4 patients) and 2) OPMD of non-FA patients with low (OLP and GVHD; $n=4$) and high (PVL, $n=1$) risk for malignant transformation [16]. Ten nanograms of DNA was used as input for target DNA library preparation using the Ion AmpliSeq Library Kit. For amplification of the targeted DNA, a customized pool of primers was designed for amplification of all exon regions of 18 most frequently mutated genes in HNSCC, namely, AJUBA, CASP8, CCND1, CDKN2A, EGFR, FAT1, FBXW7, HLA-A, HRAS, KEAP1, NFE2L2, NOTCH1, NOTCH2, NSD1, PIK3CA, TGFBR2, TP53, and TP63. The target DNA libraries were sequenced in the Ion PGM Sequencer platform. Variant calls were made on the Ion Reporter server v5.0 by using the AmpliSeq tumor-normal pair or single-sample CCP pipeline with customized filters. Filters included removing common single nucleotide polymorphisms, nonimpactful events (synonymous, intron, or UTR), low confidence variants, and variants without at least 10 reads and a 0.1 allele ratio. Filtered variants that were also present in The Cancer Genome Atlas data were manually examined and considered for reinclusion. Although HLA-A is included in the sequencing assay, it is currently excluded from the analysis because of the difficulty in accurately calling mutations in this highly polymorphic gene.

Table 1. Clinical Characteristic FA Patients with OPMD

Characteristics	Value: N (%)
Number of patients	59
Age range	
18-25 y	18 (30%)
26-40 y	33 (56%)
> 40 y	8 (14%)
Mean age	58
Gender	
Male	17 (29%)
Female	42 (71%)
Smoking history	
Current	1 (2%)
Never	51 (86%)
Former	7 (12%)
Alcohol use	
Yes	40 (68%)
No	19 (32%)
HSCT status	
Yes	33 (56%)
No	26 (44%)
Patients with OPMD	
Yes	37 (63%)
No	22 (37%)
OPMD sites	
Tongue	22
Floor of the mouth	6
Buccal mucosa	15
Palate	7
Gingiva	3
OPMD-LOF status	
Yes	31
No	22

Results

Clinical Characteristics of the FA Patients

Fifty-nine FA patients (17 males: 29%; 42 females: 71%; age range: 18-61 years) participated in this study. Twenty-eight FA patients were enrolled for this study in 2014, and another 31 FA patients were enrolled in 2016. Table 1 lists the sociodemographic characteristics of the FA patients and their respective risk factors for OSCC. A majority of FA patients (52%) in this study have had HSCT. OPMD presenting as a white and/or red patch with or without ulceration was noted in 36 (63%) of these patients. The prevalence of OPMD was 65% in FA patients with HSCT and 57% in FA patients without HSCT. These OPMDs occurred in a variety of oral mucosal sites, most often involving more than one intraoral site (Table 1). OPMDs most frequently occurred in the tongue (42%) followed by the buccal mucosa (28%), palate (13%), floor of the mouth (11%), and gingiva (7%). Thirty-six OPMDs in this patient cohort were subjected to LOF imaging and brush biopsy. Twenty-eight of the 36 OPMDs (78%) revealed LOF (Figure 2).

Differences in the Quantitative Cytology of Brush Biopsy Samples of OPMD among Subgroups of FA Patients

To further investigate if these conditions were associated with significant differences in OPMD cytology, quantitative cytology measurements were compared between FA patient subgroups based on their LOF and HSCT status (Figure 3). Average cell area of OPMD brush biopsy samples was not significantly different for different subgroups of FA patients based on LOF or HSCT status. However, the variation of cell area measurements as represented by the coefficient of variation was significantly higher in LOF-positive OPMD than LOF-negative OPMD (73.9% vs 56.9%, respectively;

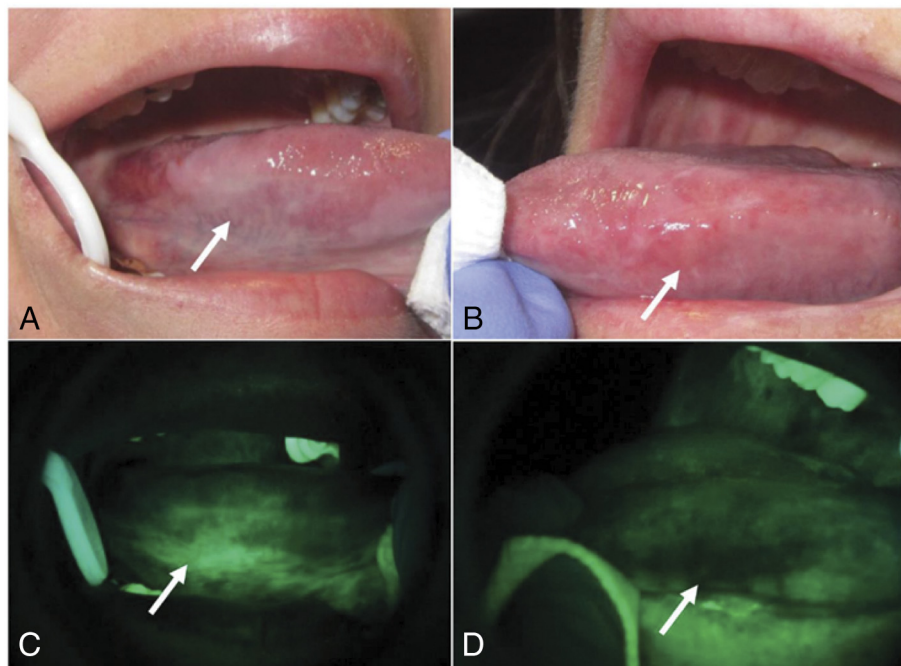


Figure 2. Representative clinical (A & B) and autofluorescence visualization (C & D) images of low- (A) and high-risk (B) OPMD in the lateral surface of the tongue of FA patients. (A) A 39-year old female FA patient without HSCT and tobacco/alcohol use history presented with an OPMD in the lateral surface of the tongue, which was negative for LOF (arrow). The COC assay risk score for this OPMD was 18. (B) A 37-year old female FA patient with HSCT and tobacco/alcohol use history presented with an OPMD in the lateral surface of the tongue, which was positive for LOF. The COC assay risk score for this OPMD was 94.

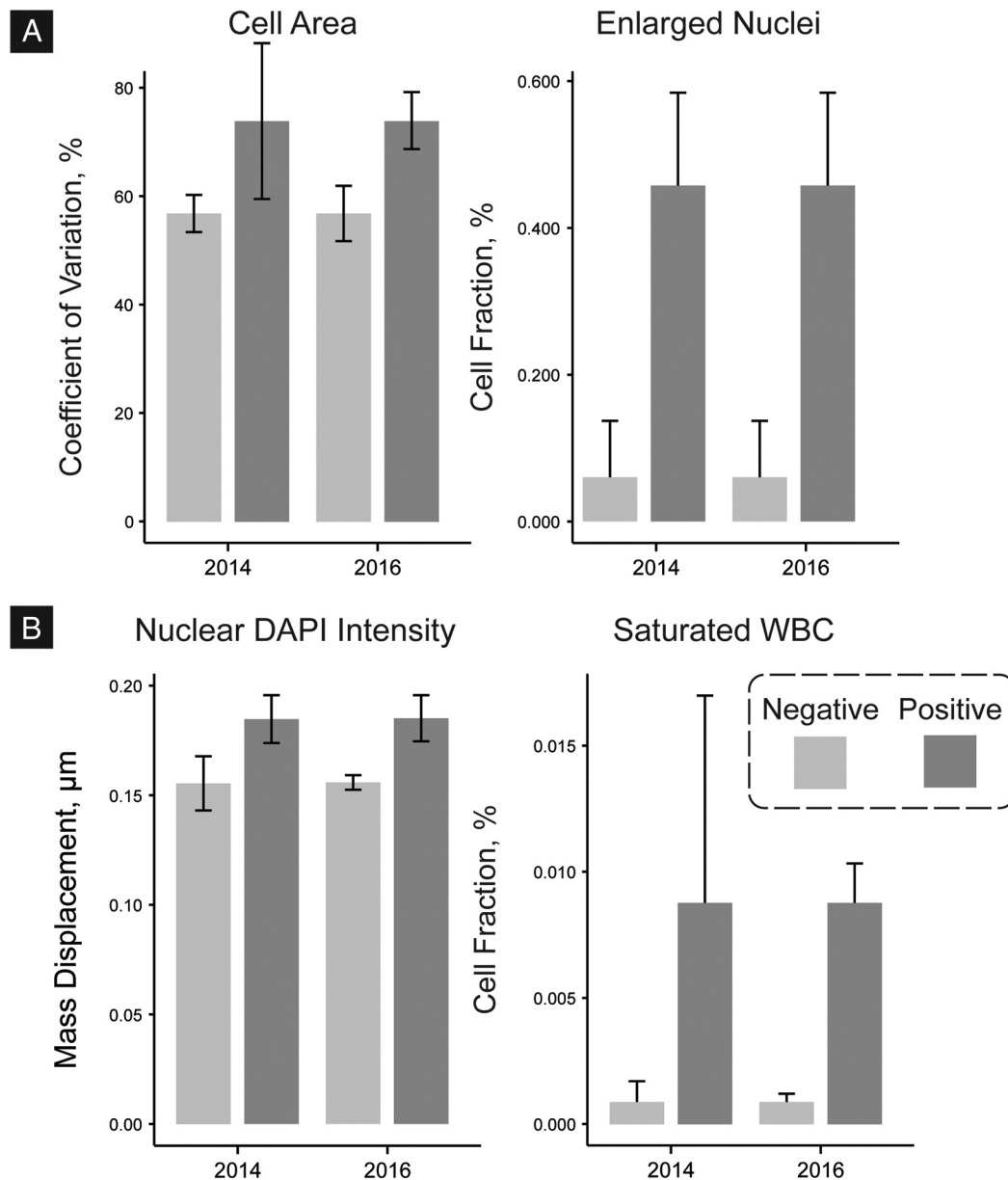


Figure 3. Differences in the quantitative cytology of brush biopsy samples of 2014 and 2016 cohorts of FA patients' OPMD. Quantitative cytology differences exist for FA patients depending on (A) patient LOF status and (B) patient HSCT status.

$P < .05$; Figure 3). Nuclear shape parameters including nuclear perimeter and area were not significantly different among FA patient subgroups. Nuclear chromatin distribution variation, quantified as the nuclear mass displacement of DAPI fluorescent signal, was on average 18% higher for HSCT-positive OPMDs than HSCT-negative OPMDs ($P < .05$; Figure 3). Nuclear MCM2 expression was significantly higher in LOF-positive OPMDs of FA patients regardless of their HSCT status ($P < .05$).

Unique cellular phenotypes were also distributed differently among FA OPMD subgroups. The presence of cells with enlarged nuclei (defined as a cell with nuclear area three times greater than "normal" nuclei) was on average 3.22 times greater in LOF-positive OPMDs than LOF-negative OPMDs ($P < .05$). Additionally, the presence of WBCs was on average 9.89 times greater in HSCT-positive OPMDs than HSCT-negative OPMDs ($P < .05$; Figure 3). Overall, these trends were conserved for both the 2014 and 2016 FA patient cohorts.

Differences in the Nuclear Anomalies of OPMD among Subgroups of FA Patients

Nuclear aberrations within oral epithelial cells are reliable markers for DNA damage, genomic instability, and cellular proliferation, linked to tumorigenesis [27,28]. The most frequently occurring nuclear aberration was the appearance of binucleated cells, which made up 2.79% of identified epithelial cells (Figure 4). Cells characterized by an irregular nuclear membrane, identified as a rough, asymmetrical border, made up an additional 2.23%, and cells with micronuclei made up 1.40% of identified epithelial cells. Frequency of cells with these nuclear anomalies was significantly higher in brush biopsy samples of OPMD compared to the contralateral normal mucosal samples (Figure 4). The distribution of these nuclear aberrations between FA patients with and without HSCT was not significantly different. Significantly more cells with micronuclei were identified in LOF-positive OPMDs compared to LOF-negative OPMDs, irrespective of their HSCT status.

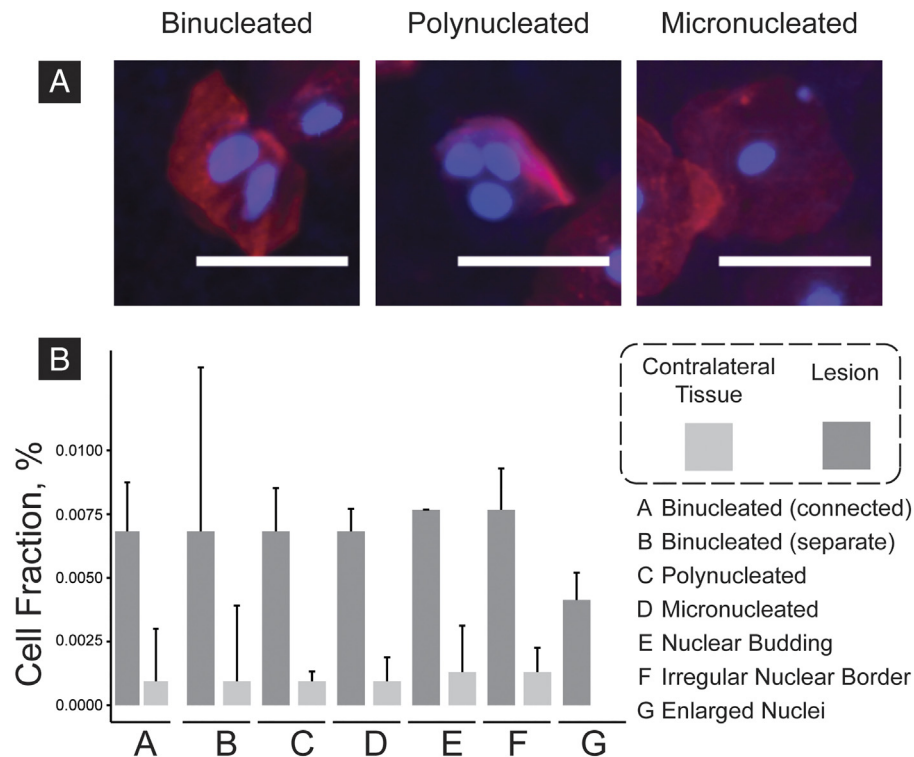


Figure 4. Distribution of nuclear aberrations identified in randomly selected areas of brush biopsy samples of FA patients' OPMD. (A) Photomicrographs with representative images of OPMD cells with binucleation, multinucleation, and micronucleus (scale bar=50 μ m). (B) Nuclear aberrations are more prevalent in brush biopsy samples of OPMD compared to brush biopsy samples of contralateral nonlesional mucosa.

COC Assay Risk Scores of FA Patients' OPMD

Following the collection of data from FA patients on the COC platform, risk index scores were computed for the OPMD samples. Figure 5 illustrates the representative low- and high-grade cytomorphology of two brush biopsy samples with their corresponding risk index scores. As anticipated, risk index scores spanned the full range from 0 to 100 for both recruitment cohorts, demonstrating the dynamic presentation of OPMD in FA. Furthermore, we demonstrated the use of risk index scores for monitoring OPMD progression over time in six FA patients who attended both the 2014 and 2016 screening (Figure 6). From these measurements, we observed the following trends: 1) OPMD risk index score of two patients increased significantly ($>40\%$) during this period, suggesting progression; 2) OPMD risk index score of two patients decreased markedly ($>40\%$), suggesting nonprogression/regression; and 3) OPMD risk index score of other two patients remained mostly unchanged ($\pm 5\%$), indicating nonprogressing stable disease. Of the six follow-up patients, five presented with additional lesions at the second recruitment cycle after 2 years. One patient in particular was associated with a 27-fold increase in risk score for the 2-year period and was notified to seek additional guidance from the patient's head and neck surgeon (subject ID 10849) (Figure 6). Additionally, this patient self-reported a recent diagnosis of pharyngeal cancer within the 2-year period. Although it is not possible to state that the increased risk score of the OPMD is attributable to this event, we considered the that OPMD of this patient has a higher risk for malignant progression and hence needed more close monitoring with more frequent incisional biopsy than the OPMD of other FA patients. Another FA patient with HSCT presented with an OPMD involving the palate, which showed a risk

index score of 99 (subject ID 10851) (Figure 6). The patient's physician was treating this lesion as chronic candidal (yeast) infection. Targeted NGS assay identified mutations of the TP53 and FAT1 genes in the brush biopsy sample of this lesion. Subsequent biopsy of this OPMD after the notification of the risk confirmed the diagnosis of an invasive squamous cell carcinoma.

Prevalence of Somatic OSCC Driver Mutations among FA Patients' OPMD

As a proof-of-concept study, we evaluated the performance of targeted NGS in detecting acquired somatic mutations that drive the development of OSCC using the DNA isolated from the brush biopsy samples of OPMD of FA and non-FA patients. We performed NGS testing on 26 samples of which 25 generated high-quality data for analysis. This included eight FA patients and five non-FA patients (cGVHD=3, OLP=1, PVL =1) with OPMD. Among these 13 patients, 4 patients did not have DNA isolated from brush biopsy samples of normal mucosa, and 3 patients had DNA isolated from brush biopsy samples of multiple lesions. We detected somatic mutations involving the FAT1, NOTCH2, and TP53 genes in 75% (6/8) of OPMDs of FA patients (Table 2). FAT1 gene mutations were noted in 5 of 11 FA OPMDs. Mutations of TP53 and NOTCH2 were seen in 3 of 11 FA OPMDs. The high-risk OPMD (PVL) of a non-FA patient harbored mutations of FAT1, CASP8, and TP63 [16]. The low-risk OPMD (OLP) of non-FA patients harbored mutation of only the CASP8 gene, and the OPMD of non-FA patients with chronic GVHD ($n=3$) harbored none of the OSCC-related somatic driver mutations.

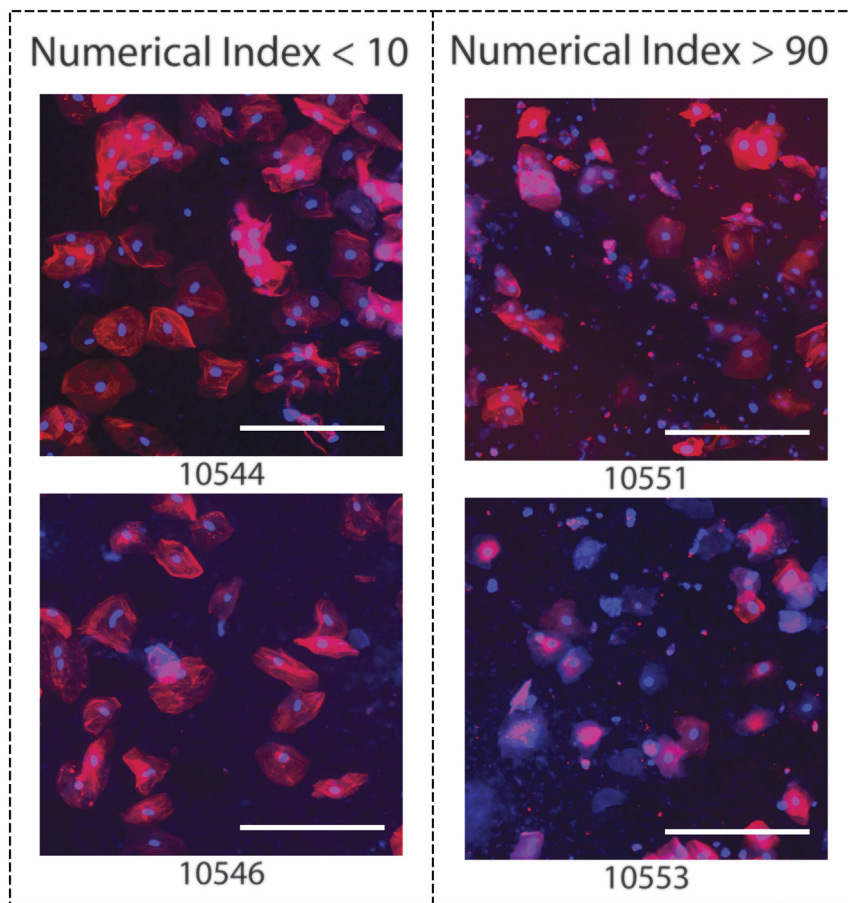


Figure 5. Representative photomicrographs reveal the FA patients' OPMD brush biopsy samples with low- and high-risk scores. Each image is a false-color merged monochrome fluorescent image where the phalloidin dye is seen in red to discern the cytoplasm and DAPI is seen in blue to identify the nuclei (scale bar=100 μ m).

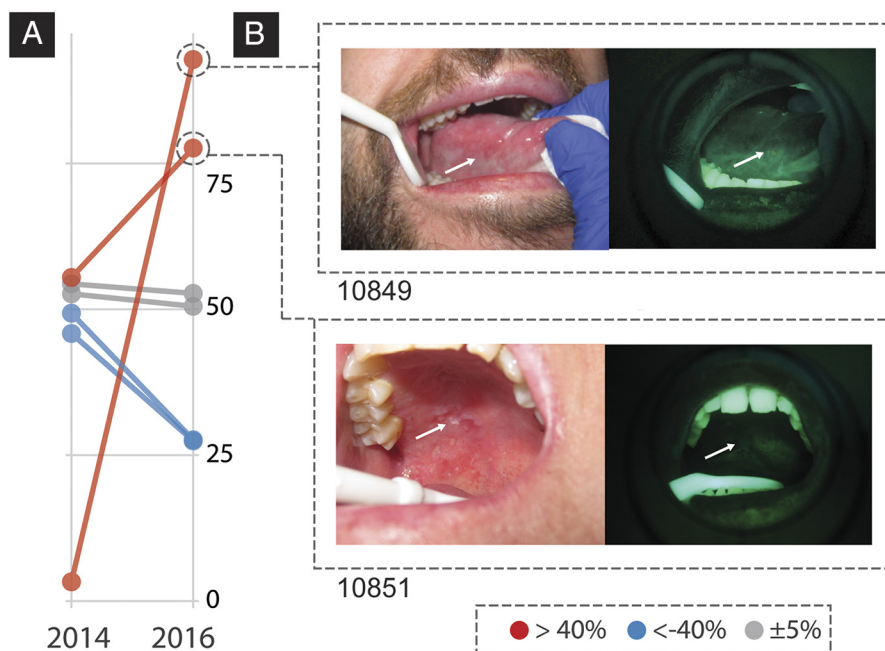


Figure 6. Proof of concept of longitudinal monitoring potential of FA patients' OPMD progression using COC assay risk scores. (Panel I) Slope graphs illustrating changes in risk scores for six FA patients recruited in both 2014 and 2016 cohorts. (Panel II) White light and LOF-positive images of the OPMDs in 2016 with large spike in their risk score over a 2-year period.

Table 2. Correlation of the Frequency of Commonly Mutated OSCC-Related Genes and the Mutation Types with Clinical Features of FA OPMD

Patient ID	Age/Gender	HSCT	Site of the Lesion/Risk Score	FAT1	NOTCH2	TP53
10844	40/F	No	Tongue/18	Yes p.Gln3450Ter*	Yes p.Arg1393Cys*	No
10845	26/F	No	Tongue/26	No	No	No
10846	25/M	Yes	Buccal mucosa/48	Yes p.Asp3242Glu*	No	No
10847	53/F	No	Palate/79	Yes p.Asp1590Asn†	No	No
10848	41/F	No	Buccal mucosa/98	Yes p.Pro1731Ala†	No	No
10849	34/M	No	Tongue/87	No	Yes p.Leu1413 His†	Yes p.Arg342Ter*
10851	36/F	Yes	Palate/99	Yes p.Val2409Met*	No	Yes p.Cys176Ser*
10852	38/M	Yes	Floor of the mouth/22	No	No	No

* The Cancer Genome Atlas mutation.

† Novel mutation.

Discussion

Risk stratification of OPMD in FA patients is greatly important for deciding whether to recommend invasive biopsy; risk of malignancy must be balanced with the biopsy decision given the immunosuppressed status of FA patients, which significantly increases risk of delayed healing and infection. In a previous case report, we demonstrated the use of LOF visualization and COC assay–based quantitative cytology in diagnosing a high-risk OPMD in an FA patient [30]. Abnormal nuclear parameters correlated significantly with high-risk clinical features of OPMD in FA patients such as LOF and the history of HSCT. In a recently published study, Smetsers et al. reported the use of brush biopsy samples for loss of heterozygosity–based genetic screening as a tool for risk prediction of OPMD in FA patients [8]. However, this test is not feasible in FA patients with HSCT because of donor leukocytes' DNA contamination in the brushed samples [8]. In order to overcome this barrier, we used nongenetic cellular and nuclear morphometry–based COC assay for our malignancy risk prediction model [25].

Despite the perceived limitations of quantitative cytology that have prevented its universal adoption as an adjunctive aid for oral epithelial dysplasia grading, the ability to obtain objective cytomorphometric measurements noninvasively poses an opportunity to monitor longitudinally OPMD in patients at high risk of OSCC over time, as in the case of FA patients. Since early signs of genomic instability commonly manifest themselves as nuclear aberrations, cytopathologic grading of brush biopsies represents an excellent opportunity for identification of nuclear abnormalities in squamous epithelial cells. Cytological findings of oral dysplasia include nuclear hyperchromasia, increased nuclear to cytoplasmic area ratio, anisonucleosis, nuclear membrane irregularities, nuclear crowding, and irregular distribution of chromatin. Many of these features, though often identified visually, can be quantified once cellular and nuclear regions are computationally extracted from microscopy images. For example, nuclear and cellular pleomorphism can be identified by quantifying the variability and distribution of specific variables that measure the size, shape, and staining intensity of nuclear and cellular regions, such as the coefficient of variation of cell area and nuclear mass displacement of DAPI intensity.

Using these parameters, we determined the quantitative metrics that differed significantly within subgroups of FA patients' OPMD divided into low and high risks based on their HSCT and LOF status. Previous studies have demonstrated the use of LOF for clinical

surveillance of potentially malignant lesions in multiple organ sites [22]. Degradation of the collagen matrix and angiogenesis occurring during oral carcinogenesis results in a loss of blue-green autofluorescence that is visible as a dark patch [22]. Changes in tissue autofluorescence during malignant progression of OPMD have been used as an optical biomarker for detecting head and neck cancer [22]. VELscope, an FDA-approved oral cancer screening device, is used as an adjunct to COE to enhance the visualization of clinically occult, high-risk OPMDs [22]. We used VELscope to determine the LOF status of OPMD and classified them with and without LOF as high- and low-risk lesions, respectively.

Several cytology measurements were found to differ significantly for high-risk FA patient subgroups with LOF-positive and/or HSCT-positive OPMD, including greater variation in cell area and chromatin distribution, higher MCM2 expression levels, and greater numbers of WBCs and cells with enlarged nuclei. Micronuclei and other nuclear aberrations were more prevalent among high-risk FA patients' OPMD with positive LOF and HSCT status. Micronuclei represent extranuclear segments of chromatin resulting from either DNA double-strand breaks or spindle apparatus dysfunction. Micronuclei can be either acentric chromosomal fragments or whole chromosomes that were not incorporated into the nuclei at the completion of mitosis [31]. Micronuclei are rarely formed during mitosis of healthy cells. In contrast, cells derived from patients with hereditary genome-instability disorders such as FA have a high frequency of micronucleus formation as noted in our study [32]. Micronuclei undergo vastly error-prone DNA replication and DNA breakage and can then be reincorporated into the same nuclear compartment as the main chromosomes during mitosis [33,34]. Elevated levels of micronuclei are indicative of increased risk for tumorigenesis in genetically modified mice [35]. Therefore, prognostic significances of nuclear aberrations in the brush biopsies of FA patients' OPMD are worth investigating as potential biomarkers for disease monitoring as it relates to the risk of developing OSCC. OPMD of FA patients with LOF had significantly higher expression of MCM2 than OPMD without. MCM2 is a nuclear protein overexpressed in proliferating cells, and its overexpression in OPMD correlates with increased risk for malignant transformation [36,37]. Furthermore, the addition of quantitative cytology may aid in identifying inflammation-related false positivity during LOF visualization. In this study, two patients with LOF also had significantly

higher WBC counts compared to all other patients. Though further testing would be required to identify the true biological nature of these lesions, this initial finding can be useful to identify cases of possibly LOF false positivity due to localized inflammatory processes.

Since OPMDs of FA patients require long-term monitoring to assess their risk of developing oral cancer, minimally invasive adjuncts hold great promise for equipping clinicians with information to assist with difficult biopsy referral decisions. We report for the first time the potential of using LOF coupled with transepithelial brush biopsy for detection and risk stratification of OPMD in FA patients at early stages when surgery with curative intent is feasible. These tests offer the ability to perform repeated measurements of OPMD progression and biologic alteration, which can be used for individual patient staging and guiding the optimal treatment option. The COC assay-derived risk index has the potential to serve in clinical decision making in the future as an objective and minimally invasive tool for monitoring lesion severity over time. This pilot, proof-of-concept study demonstrates that the calculated risk score accurately predicted the malignancy risk of OPMD in two patients as confirmed by follow-up scalpel biopsy. Further evaluation is needed to validate this risk index score.

Finally, we demonstrate the feasibility of using DNA isolated from brush biopsy samples of FA and non-FA patients OPMD for NGS testing to profile somatic driver mutations of OSCC. Brush biopsy is ideally suited for mutation analysis of OPMD because it 1) allows broad sampling of OPMD with diffuse and multifocal involvement; 2) does not harbor interfering normal stromal cells; and 3) contains whole cells, yielding higher-quality nuclear DNA. Our pilot proof-concept study reveals that FA OPMDs harbor higher frequency of mutations involving the FAT1, TP53, and NOTCH2 genes that are implicated in oral carcinogenesis. None of these genes was mutated in low-risk OPMD in non-FA patients with OLP and chronic GVHD. In contrast, high-risk OPMD (PVL) revealed six mutations involving three genes (FAT1, caspase 8, and TP53) implicated in oral carcinogenesis. Our NGS-based profiling of cancer-related mutations in the OPMD of FA patients is exploratory in nature with a number of limitations. The OPMD brush biopsy samples were collected under a limited-resource setting yielding low amounts of DNA for NGS. Hence, we used a PCR-based sequencing approach, which can introduce errors due to artifacts. Even though we undertook nearly all reasonable and feasible steps during the data analysis to remove any variants that were suspected of being an artifact, it is not possible to validate these variants using another sequencing platform due to the lack of sufficient DNA samples. Given the exploratory nature of this study, additional studies with adequate quality control measures will be needed to confirm the suitability of using brush biopsy samples of FA patients' OPMD for detection of therapeutically actionable mutations by NGS.

Conclusion

Data from this study suggest that LOF of OPMD, coupled with quantitative cytology of their transepithelial brush biopsy samples, aids in distinguishing high- and low-risk OPMD in FA patients.

Acknowledgements

The authors thank the Fanconi Anemia Research Fund and the FA patients for their participation in this study. The authors acknowledge the former personnel at the University of Texas School of Dentistry at Houston, Rameez Raja, and Cynthia Meena for their assistance in the data collection.

References

- [1] Kutler DI, Singh B, Satagopan J, Batish SD, Berwick M, Giampietro PF, Hanenberg H, and Auerbach AD (2003). A 20-year perspective on the International Fanconi Anemia Registry (IFAR). *Blood* **101**(4), 1249–1256. <http://dx.doi.org/10.1182/blood-2002-07-2170>.
- [2] Levitus M, Joenje H, and de Winter JP (2006). The Fanconi anemia pathway of genomic maintenance. *Cell Oncol* **28**(1-2), 3–29.
- [3] Schneider M, Chandler K, Tischkowitz M, and Meyer S (2015). Fanconi anaemia: genetics, molecular biology, and cancer - implications for clinical management in children and adults. *Clin Genet* **88**(1), 13–24. <http://dx.doi.org/10.1111/cge.12517>.
- [4] Schwab RA, Nieminuszczy J, Shah F, Langton J, Lopez Martinez D, Liang CC, Cohn MA, Gibbons RJ, Deans AJ, and Niedzwiedz W (2015). The Fanconi Anemia Pathway Maintains Genome Stability by Coordinating Replication and Transcription. *Mol Cell* **60** (3), 351–361. <http://dx.doi.org/10.1016/j.molcel.2015.09.012>.
- [5] Palovcak A, Liu W, Yuan F, and Zhang Y (2017). Maintenance of genome stability by Fanconi anemia proteins. *Cell Biosci* **7**, 8. <http://dx.doi.org/10.1186/s13578-016-0134-8>.
- [6] Masserot C, Peffault de Latour R, Rocha V, Leblanc T, Rigolet A, Pascal F, Janin A, Soulier J, Gluckman E, and Socie G (2008). Head and neck squamous cell carcinoma in 13 patients with Fanconi anemia after hematopoietic stem cell transplantation. *Cancer* **113**(12), 3315–3322. <http://dx.doi.org/10.1002/cncr.23954>.
- [7] Kutler DI, Auerbach AD, Satagopan J, Giampietro PF, Batish SD, Huvos AG, Goberdhan A, Shah JP, and Singh B (2003). High incidence of head and neck squamous cell carcinoma in patients with Fanconi anemia. *Arch Otolaryngol Head Neck Surg* **129**(1), 106–112.
- [8] Smetsers SE, Velleuer E, Dietrich R, Wu T, Brink A, Buijze M, Deeg DJ, Soulier J, Leemans CR, and Braakhuis BJ, et al (2015). Noninvasive Molecular Screening for Oral Precancer in Fanconi Anemia Patients. *Cancer Prev Res (Phila)* **8**(11), 1102–1111. <http://dx.doi.org/10.1158/1940-6207.CAPR-15-0220>.
- [9] Velleuer E and Dietrich R (2014). Fanconi anemia: young patients at high risk for squamous cell carcinoma. *Mol Cell Pediatr* **1**(1), 9. <http://dx.doi.org/10.1186/s40348-014-0009-8>.
- [10] Kutler DI, Patel KR, Auerbach AD, Kennedy J, Lach FP, Sanborn E, Cohen MA, Kuhel WI, and Smogorzewska A (2016). Natural history and management of Fanconi anemia patients with head and neck cancer: A 10-year follow-up. *Laryngoscope* **126**(4), 870–879. <http://dx.doi.org/10.1002/lary.25726>.
- [11] Alter BP, Giri N, Savage SA, Quint WG, de Koning MN, and Schiffman M (2013). Squamous cell carcinomas in patients with Fanconi anemia and dyskeratosis congenita: A search for human papillomavirus. *Int J Cancer* **133**(6), 1513–1515. <http://dx.doi.org/10.1002/ijc.28157>.
- [12] Deeg HJ, Socie G, Schoch G, Henry-Amar M, Witherspoon RP, Devergie A, Sullivan KM, Gluckman E, and Storb R (1996). Malignancies after marrow transplantation for aplastic anemia and fanconi anemia: a joint Seattle and Paris analysis of results in 700 patients. *Blood* **87**(1), 386–392.
- [13] Peffault de Latour R, Porcher R, Dalle JH, Aljurf M, Korthof ET, Svahn J, Willemze R, Barrenetxea C, Mialou V, and Soulier J, et al (2013). Allogeneic hematopoietic stem cell transplantation in Fanconi anemia: the European Group for Blood and Marrow Transplantation experience. *Blood* **122**(26), 4279–4286. <http://dx.doi.org/10.1182/blood-2013-01-479733>.
- [14] Rosenberg PS, Socie G, Alter BP, and Gluckman E (2005). Risk of head and neck squamous cell cancer and death in patients with Fanconi anemia who did and did not receive transplants. *Blood* **105**(1), 67–73. <http://dx.doi.org/10.1182/blood-2004-04-1652>.
- [15] Grein Cavalcanti L, Fuentes Araujo RL, Bonfim C, and Torres-Pereira CC (2015). Oral manifestations compatible with chronic graft-versus-host disease in patients with Fanconi anemia. *Biol Blood Marrow Transpl* **21**(2), 275–280. <http://dx.doi.org/10.1016/j.bbmt.2014.10.009>.
- [16] Reibel J, Gale N, Hille J, Hunt JL, Linggen M, Muller S, Sloan P, Tilakaratne WM, Westra WH, and Willams MD, et al (2017). Oral Potentially malignant disorders and oral epithelial dysplasia. In: El-Naggar A, Chan J, Grandis J, Takata T, Sliotweg P, editors. World Health Organization Classification of Tumors: Head and Neck Tumors. 4th edition. Lyon, France: IARC Press; 2017.
- [17] Mawardi H, Elad S, Correa ME, Stevenson K, Woo SB, Almazrooa S, Haddad R, Antin JH, Soiffer R, and Treister N (2011). Oral epithelial dysplasia and squamous cell carcinoma following allogeneic hematopoietic stem cell transplantation: clinical presentation and treatment outcomes. *Bone Marrow Transpl* **46**(6), 884–891. <http://dx.doi.org/10.1038/bmt.2011.77>.

- [18] Shah AT, Wu E, and Wein RO (2013). Oral squamous cell carcinoma in post-transplant patients. *Am J Otolaryngol* **34**(2), 176–179. <http://dx.doi.org/10.1016/j.amjoto.2012.11.004>.
- [19] van der Waal I (2009). Potentially malignant disorders of the oral and oropharyngeal mucosa; terminology, classification and present concepts of management. *Oral Oncol* **45**(4-5), 317–323 S1368-8375(08)00171-1 [pii] <https://doi.org/10.1016/j.oraloncology.2008.05.016>.
- [20] van der Waal I (2009). Oral lichen planus and oral lichenoid lesions; a critical appraisal with emphasis on the diagnostic aspects. *Med Oral Patol Oral Cir Bucal* **14**(7), E310-324 5123658898 [pii].
- [21] Lingen MW, Kalmar JR, Karrison T, and Speight PM (2008). Critical evaluation of diagnostic aids for the detection of oral cancer. *Oral Oncol* **44**(1), 10–22 S1368-8375(07)00176-5 [pii] <https://doi.org/10.1016/j.oraloncology.2007.06.011>.
- [22] Shin D, Vigneswaran N, Gillenwater A, and Richards-Kortum R (2010). Advances in fluorescence imaging techniques to detect oral cancer and its precursors. *Future Oncol* **6**(7), 1143–1154. <http://dx.doi.org/10.2217/fon.10.79>.
- [23] Vigneswaran N and Williams MD (2014). Epidemiologic trends in head and neck cancer and aids in diagnosis. *Oral Maxillofac Surg Clin North Am* **26**(2), 123–141. <http://dx.doi.org/10.1016/j.coms.2014.01.001>.
- [24] Rana M, Zapf A, Kuehle M, Gellrich NC, and Eckardt AM (2012). Clinical evaluation of an autofluorescence diagnostic device for oral cancer detection: a prospective randomized diagnostic study. *Eur J Cancer Prev* **21**(5), 460–466. <http://dx.doi.org/10.1097/CEJ.0b013e32834fdb6d>.
- [25] Abram TJ, Floriano PN, Christodoulides N, James R, Kerr AR, Thornhill MH, Redding SW, Vigneswaran N, Speight PM, and Vick J, et al (2016). 'Cytology-on-a-chip' based sensors for monitoring of potentially malignant oral lesions. *Oral Oncol* **60**, 103–111. <http://dx.doi.org/10.1016/j.oraloncology.2016.07.002>.
- [26] Weigum SE, Floriano PN, Redding SW, Yeh CK, Westbrook SD, McGuff HS, Lin A, Miller FR, Villarreal F, and Rowan SD, et al (2010). Nano-bio-chip sensor platform for examination of oral exfoliative cytology. *Cancer Prev Res (Phila)* **3**(4), 518–528. <http://dx.doi.org/10.1158/1940-6207.CAPR-09-0139>.
- [27] Bolognesi C, Knasmueller S, Nersesyanyan A, Thomas P, and Fenech M (2013). The HUMNxl scoring criteria for different cell types and nuclear anomalies in the buccal micronucleus cytome assay - an update and expanded photogallery. *Mutat Res* **753**(2), 100–113. <http://dx.doi.org/10.1016/j.mrrev.2013.07.002>.
- [28] Sanchez-Siles M, Ros-Llor I, Camacho-Alonso F, and Lopez-Jornet P (2011). A novel application of the buccal micronucleus cytome assay in oral lichen planus: a pilot study. *Arch Oral Biol* **56**(10), 1148–1153. <http://dx.doi.org/10.1016/j.archoralbio.2011.02.019>.
- [29] Speight PM, Abram TJ, Floriano PN, James R, Vick J, Thornhill MH, Murdoch C, Freeman C, Hegarty AM, and D'Apice K, et al (2015). Interobserver agreement in dysplasia grading: toward an enhanced gold standard for clinical pathology trials. *Oral Surg Oral Med Oral Pathol Oral Radiol Endod* . <http://dx.doi.org/10.1016/j.oooo.2015.05.023>.
- [30] Floriano PN, Abram T, Taylor L, Le C, Talavera H, Nguyen M, Raja R, Gillenwater A, McDevitt J, and Vigneswaran N (2015). Programmable bio-nanochip-based cytologic testing of oral potentially malignant disorders in Fanconi anemia. *Oral Dis* **21**(5), 593–601. <http://dx.doi.org/10.1111/odi.12321>.
- [31] Fenech M, Kirsch-Volders M, Natarajan AT, Surrallés J, Crott JW, Parry J, Norppa H, Eastmond DA, Tucker JD, and Thomas P (2011). Molecular mechanisms of micronucleus, nucleoplasmic bridge and nuclear bud formation in mammalian and human cells. *Mutagenesis* **26**(1), 125–132. <http://dx.doi.org/10.1093/mutage/geq052>.
- [32] Maluf SW and Erdtmann B (2001). Genomic instability in Down syndrome and Fanconi anemia assessed by micronucleus analysis and single-cell gel electrophoresis. *Cancer Genet Cytogenet* **124**(1), 71–75.
- [33] Crasta K, Ganem NJ, Dagher R, Lantermann AB, Ivanova EV, Pan Y, Nezi L, Protopopov A, Chowdhury D, and Pellman D (2012). DNA breaks and chromosome pulverization from errors in mitosis. *Nature* **482**(7383), 53–58. <http://dx.doi.org/10.1038/nature10802>.
- [34] Hatch EM, Fischer AH, Deerinck TJ, and Hetzer MW (2013). Catastrophic nuclear envelope collapse in cancer cell micronuclei. *Cell* **154**(1), 47–60. <http://dx.doi.org/10.1016/j.cell.2013.06.007>.
- [35] Crossan GP, van der Weyden L, Rosado IV, Langevin F, Gaillard PH, McIntyre RE, Sanger Mouse Genetics P, Gallagher F, Kettunen MI, and Lewis DY, et al (2011). Disruption of mouse Slx4, a regulator of structure-specific nucleases, phenocopies Fanconi anemia. *Nat Genet* **43**(2), 147–152. <http://dx.doi.org/10.1038/ng.752>.
- [36] Gouvea AF, Santos Silva AR, Speight PM, Hunter K, Carlos R, Vargas PA, de Almeida OP, and Lopes MA (2013). High incidence of DNA ploidy abnormalities and increased Mcm2 expression may predict malignant change in oral proliferative verrucous leukoplakia. *Histopathology* **62**(4), 551–562. <http://dx.doi.org/10.1111/his.12036>.
- [37] Torres-Rendon A, Roy S, Craig GT, and Speight PM (2009). Expression of Mcm2, geminin and Ki67 in normal oral mucosa, oral epithelial dysplasias and their corresponding squamous-cell carcinomas. *Br J Cancer* **100**(7), 1128–1134. <http://dx.doi.org/10.1038/sj.bjc.6604967>.