

Antineutrophil cytoplasmic antibody-associated vasculitis complicated with oral and maxillofacial space infection in a young woman: A case report

ZHU QIAO^{1*}, YUE ZOU^{2*}, SHUANGYAN LIU³, HU ZHAO¹, and XIAODONG LI⁴

¹Department of Stomatology II, Baoding No. 1 Central Hospital of Hebei Medical University, Baoding, Hebei 071000;

²Central Sterile Supply Department, Baoding No. 1 Central Hospital of Hebei Medical University, Baoding, Hebei 071000;

³Department of Internal Medicine, Graduate School of Hebei Medical University, Shijiazhuang, Hebei 050011; ⁴Department of Nephrology, Baoding No. 1 Central Hospital of Hebei Medical University, Baoding, Hebei 071000, P.R. China

Received January 13, 2023; Accepted April 27, 2023

DOI: 10.3892/etm.2023.12043

Abstract. Antibody-associated vasculitis (AAV) is a systemic autoimmune disease, with hormones and immunosuppressants as its main treatment measures. However, during the treatment process, various infections such as lung infections and urinary tract infections are prone to occur, and patients with OMSI are relatively rare. The present case report describes the case of a young woman who received long-term oral glucocorticoids and immunosuppressive agents for the treatment of antineutrophil cytoplasmic (AAV). At hospital admission, the patient with a high fever and painful swelling of the left side of the mouth. The patient was diagnosed with an oral and maxillofacial space infection (OMSI). Therefore, the local incision, drainage and irrigation of abscesses were subsequently performed. Additionally, the immunosuppressive agents were discontinued, the glucocorticoid dose was reduced and intravenous antibiotic therapy was provided. The patient was discharged 1 week later in good condition. Notably, the incidence of AAV is extremely low. Although OMSI is not uncommon, the simultaneous occurrence of AAV in combination with OMSI has not been reported previously. To the best of our knowledge, this is the first reported case of AAV combined with OMSI.

Introduction

Antibody-associated vasculitis (AAV) is a rare autoimmune disease of unknown cause (1). The incidence of AAV among hospitalized patients in China is 0.25%, with the North exhibiting a higher incidence than the South (2). A review of AAV has highlighted that it is associated with combined interaction of infection, genetics and environmental factors, manifests with a variety of non-specific symptoms and usually affects the respiratory and renal systems (3). In addition, AAV is characterized by the inflammation and destruction of small and medium-sized blood vessels and the presence of circulating ANCA (4). It is also distinguished by the pathophysiological production of proteins directed against the neutrophilic protein proteinase 3 (PR3-ANCA) or MPO-ANCA. It is often diagnosed in middle-aged and older adults and is uncommon in young people (5). Dysfunction of the immune system is also speculated to be induced by AAV, for which long-term immunosuppressive therapy is usually administered. Notably, various infections have become the primary cause of death when the disease activity is controlled, particularly during the induction-remission phase of the disease (6). Moreover, infections have been reported to be the main trigger of AAV, the main mechanisms of which include B and T cell activation, direct endothelial injury, immune complex-mediated vascular injury and cell-mediated type IV hypersensitivity-responsive vascular injury (7). Furthermore, patients with AAV may be greatly affected by adverse events associated with its treatment during the first year of diagnosis rather than the active vasculitis itself. Additionally, infections are the most common cause of patient death during follow-up, particularly in individuals undergoing immunosuppressive therapy. Notably, the mortality rate is reported to be higher in China than in Western countries (8,9). OMSI is a general term for potential interstitial septic inflammation of the maxillofacial region, the floor of the mouth and the soft tissues of the neck. The most common causes of OMSI are odontogenic infections, dental caries, periapical periodontitis and pericoronitis (10). However, although the combination of AAV with OMSI is rare in clinical practice, it is important for medical professionals to be aware of.

Correspondence to: Dr Xiaodong Li, Department of Nephrology, Baoding No. 1 Central Hospital of Hebei Medical University, 320 Baoding Great Wall North Street, Baoding, Hebei 071000, P.R. China
E-mail: lxd_765@sina.com

*Contributed equally

Key words: antineutrophil cytoplasmic antibody-associated vasculitis, oral and maxillofacial space infection, infection source

Antineutrophil cytoplasmic antibody (ANCA)-associated vasculitis (AAV) is a group of autoimmune diseases characterized by systemic small vessel inflammation and necrosis. ANCA is an important serum marker for AAV (11). However, the etiology and pathogenesis of AAV remain unclear, and epidemiological studies focusing on AAV are scarce in China. The incidence rate of AAV in other countries is also low (12). Oral and maxillofacial space infection (OMSI) is a bacterial infection in the subfascial space of the oral, maxillofacial and neck regions (13). OMSI can lead to serious and even life-threatening complications if undetected or left untreated. OMSI has a fatality rate of between 10 and 40% (14). In the present case report, a rare case of AAV combined with OMSI is described. To the best of our knowledge, this is the first case of AAV combined with OMSI to be reported.

Case report

A 33-year-old female who presented with swelling and pain in the left side of the mouth that had persisted for 5 days was admitted to Baoding No. 1 Central Hospital of Hebei Medical University (Baoding, China) in June 2022. A year previously, the patient sought medical care due to poor appetite and fatigue, for which the following test results were obtained: Urinary protein (+++), occult blood (++) , blood creatinine (180 $\mu\text{mol/l}$; normal range, 34.2-75.6 $\mu\text{mol/l}$), hemoglobin (89 g/l; normal range, 110-150 g/l) and myeloperoxidase (MPO)-ANCA titer [120 relative units (RU)/ml; normal range, 0-20 RU/ml]. At that time, a renal biopsy was also performed which led to a diagnosis of ANCA-related small vessel renal damage (necrotizing vasculitis). Prednisone acetate tablets (60 mg once daily) and cyclophosphamide (50 mg twice daily) were prescribed. The cumulative dose of cyclophosphamide reached 8 g, after which the oral administration of 0.75 g of mycophenolate mofetil twice daily was initiated. In the following year, 5 days prior to her admission to hospital, the patient developed oral ulcers with swelling and pain in the oral mucosa and swelling in the left cheek. Furthermore, 3 days prior to admission, the patient developed a fever (39.3°C). Subsequently, she was admitted to the Department of Nephrology for treatment. The patient had developed a full and rounded face. This may have been due to Cushing's syndrome induced by treatment with high doses of prednisone. due to the high doses of prednisone received during the previous year for Cushing's syndrome. However, the patient's face was asymmetrical with pronounced swelling of the left cheek, indicating the occurrence of OMSI (Fig. 1). The physical examination results on admission were as follows: Temperature, 38.3°C; blood pressure, 150/80 mmHg; body weight, 58 kg; BMI, 25.7; rounded face; swelling of the left cheek; moderate hardness when palpated without obvious fluid fluctuation; pressure pain (+); maximum mouth opening (MMO) approximately two transverse fingers; intraoral examination suggestive of 38 (Lower left 8th permanent tooth) pericoronal redness and tenderness (+); and buccal mucosal fistula with purulent fluid effusion. The results of the laboratory tests performed after admission are presented in Table I. Additionally, chest computed tomography (CT) revealed no abnormalities. However, CT of the jaws on admission showed swelling of the soft tissues around the mandible with abnormal density on the left side, suggesting infectious lesions



Figure 1. Patient on admission showed her rounded face and swelling of the left cheek.

and abscess formation (Fig. 2). After consultation with the Department of Stomatology, the patient was diagnosed with OMSI combined with abscess formation. Therefore, drainage channels were established at two locations in the buccal mucosa for the treatment of the patient. After repeatedly flushing with saline and diluted hydrogen peroxide solution, yellow pus flowed out of the channels. Thereafter, drainage strips were placed at the drainage sites and changed daily, and the affected locations were adequately flushed locally. On the day of admission, mycophenolate mofetil was discontinued, and the dose of prednisone was reduced to 30 mg once daily. In addition, intravenous antibiotic treatment was administered, comprising oxacillin sodium 2 g twice a day and ornidazole 0.25 g twice a day.

Following these treatments, the left maxillofacial swelling and pain were gradually alleviated and the temperature of the patient returned to normal. One week later, CT imaging of the jaw revealed marked alleviation (Fig. 3). At 1 week later, the general condition of the patient improved and she was discharged from the hospital. The patient was recommended to take antibiotics orally at home for 1 week (cefaclor 0.25 g twice daily). Furthermore, during an outpatient follow-up 2 weeks later, mycophenolate mofetil (0.5 g twice daily) was prescribed. The condition of the patient remained stable during the monthly follow-up examinations for half a year as an outpatient at the Department of Nephrology.

Discussion

The present case report describes a young female patient with a 1-year history of AAV. The pathological findings of the renal biopsy performed 1 year prior to admission revealed AAV-associated glomerular nephritis, which was treated with long-term oral glucocorticoids and immunosuppressive drugs. Laboratory tests on admission suggested a small amount of proteinuria, abnormal renal function and a mildly elevated MPO-ANCA titer. According to the Birmingham vasculitis activity scoring system (15), the active stage of vasculitis is defined as a score of >15 points. The score of the present patient was 10 points, indicating that the patient did not have active AAV. Additionally, the urine output of the patient was

Table I. Laboratory results obtained for the patient.

Investigation	Normal range	Day 1	Day 7
WBC ($\times 10^9/l$)	4.00-10.00	10.90	8.50
Hb (g/l)	110.00-150.00	115.20	117.60
Lymphocyte ($\times 10^9/l$)	1.20-4.80	0.70	1.23
Alb (g/l)	40.00-55.00	38.50	39.20
24-h Upro (g)	0.00-0.15	0.60	0.40
Urea (mmol/l)	2.60-7.50	15.90	12.40
Creatinine ($\mu\text{mol/l}$)	41.00-73.00	240.00	185.20
Potassium (mmol/l)	3.50-5.30	3.80	4.30
CRP (mg/l)	<8.00	129.50	7.20
PCT (ng/ml)	<0.25	3.30	0.30
MPO-ANCA (RU/ml)	<20.00	53.30	28.40
PR3-ANCA (RU/ml)	<20.00	4.60	3.80
C3 (g/l)	0.79-1.52	0.90	1.30
C4 (g/l)	0.16-0.38	0.20	0.30
IgA (g/l)	1.00-4.20	0.45	0.78
IgG (g/l)	8.60-17.40	3.74	6.51
IgM (g/l)	0.50-2.80	0.38	0.46

WBC, white blood cell; Hb, hemoglobin; Alb, albumin; 24-h Upro, 24-h urine proteins; CRP, C-reactive protein; PCT, procalcitonin; MPO, myeloperoxidase; ANCA, anti-neutrophil cytoplasmic antibodies; PR3, proteinase 3; C3, complement 3; C4, complement 4; IgA, immunoglobulin A; IgG, immunoglobulin G; IgM, immunoglobulin M; RU, relative units.

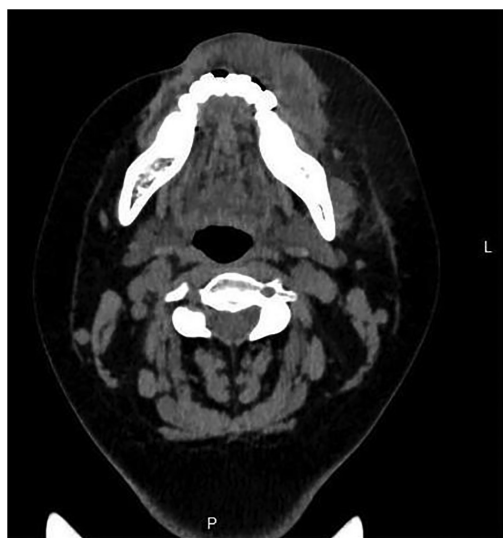

Figure 2. Computed tomography scan of the soft tissue swelling around the mandible before treatment. L, left; P, posterior.

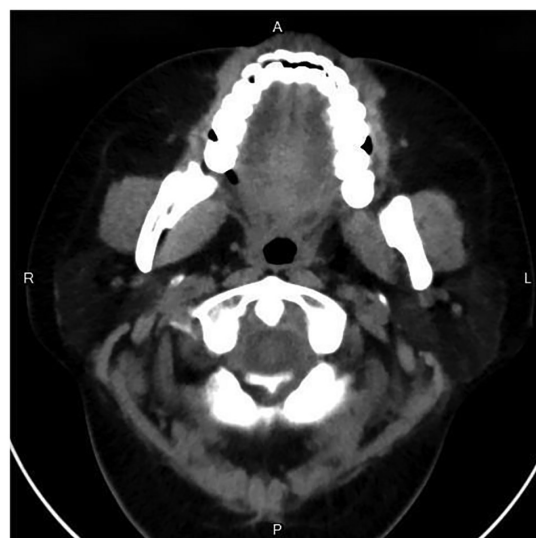


Figure 3. Computed tomography scan showing soft tissue recovery around the mandible after treatment. A, anterior; R, right; L, left; P, posterior.

also normal, suggesting that the AAV was stable. However, the number of lymphocytes was lower than the normal range and the IgA, IgG and IgM levels were also downregulated, indicating a poor immune function.

The clinical pathogenesis of AAV combined with OMSI is relatively complex as it is often challenging to distinguish whether it is caused by active vasculitis and/or the administration of immunosuppressive drugs. Clinicians are required to determine the cause based on the condition of the patient and clinical examination findings (Fig. 4). The patient reported

in the present study presented with fever and soft tissue swelling on the left cheek. Additionally, specialized examination suggested that the left side of the face was more swollen compared with the right side. In addition, the facial skin was red in color with a high temperature, and palpable pressure was evident in the left cheek. No dental caries or periapical infection were observed in the oral cavity, and the bilateral lower wisdom teeth had distal mesial gingival coverage. Moreover, CT of the jaws indicated swelling of the soft tissues around the mandible, mainly in the left side, suggesting infectious lesions

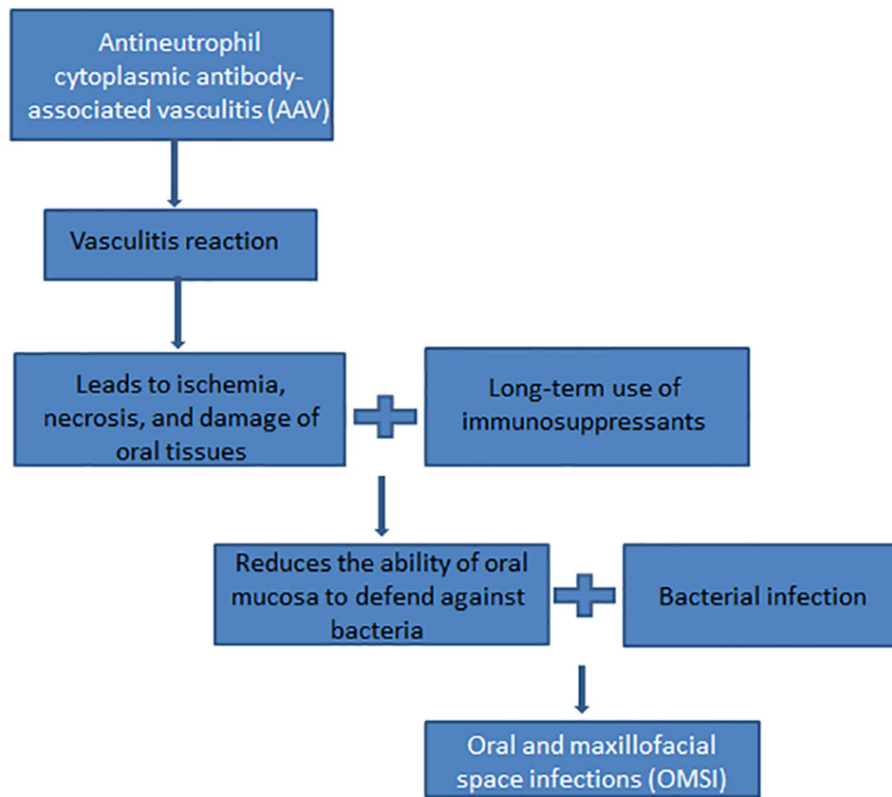


Figure 4. Diagram of the proposed mechanism of antibody-associated vasculitis combined with oral and maxillofacial space infection.

and abscess formation. Iwanaga *et al* (16) injected compressed air into the pterygomandibular space of freshly frozen cadavers to simulate mandibular infection that had spread to the occlusal space. Subsequently, significant air diffusion into the parapharyngeal, parotid, buccal, sublingual and submandibular spaces was observed. These findings suggest that inflammation spreads easily in the maxillofacial region, which has abundant branch-linked spaces and lax connective tissue. The route of infection in the present case was determined to be the acute phase of pericoronitis in the left lower wisdom tooth, which had spread to the occlusal space, invaded the left buccal space, and eventually formed an oral space infection. Moreover, the present patient was young, which is consistent with the finding of a study that young patients are the most affected population (17). Additionally, disease onset in the present case occurred in the summer, which concurs with a previous study that reported a high incidence of AAV in the summer (13).

In addition to the timely surgical management of the local abscess, the discontinuation of immunosuppressive drugs and reduction of glucocorticoids were crucial in restoring the immune functions of the patient. Additionally, the routine intravenous administration of broad-spectrum antibiotics was crucial for the complete control of OMSI in the patient. The patient received regular follow-ups from the hospital, and her conditions have remained stable to date. Patients with AAV are prone to co-infection, which is closely associated with the disease state, individual constitution and the type, dose and duration of immunosuppressive drugs. Immunosuppressive drugs often cause secondary immune deficiency in patients, which can lead to certain rare or uncommon infections and, in

severe cases, death (18). Thus, aggressive infection control can not only ameliorate the activity of AAV but also effectively improve the long-term survival of the patient (19).

There are some limitations in the present case. Firstly, the patient refused to be photographed during the surgery, so photographs that could provide an improved representation of the disease status and the outcome of the surgery are not available. Secondly, no photographs of the pus samples collected for laboratory tests and of the affected area at the time of discharge are available to demonstrate the severity of the infection and the outcome of treatment more visually. However, after timely and precise treatment, the patient recovered and was discharged. Future studies are required to present more evidence to validate the current treatment regimen for AAV combined with OMSI.

In conclusion, glucocorticoids and immunosuppressive drugs are effectively able to control the activity and recurrence of AAV, but secondary infections commonly occur. Infections can impede subsequent treatment of the disease and require careful consideration by clinicians. Therefore, based on the successful treatment experience of the present case, the following recommendations for the prevention and control of AAV infection are proposed. Firstly, the rational use of glucocorticoids and immunosuppressive agents is recommended, with minimal drug doses to control the disease. Current treatment guidelines may be used as a reference in clinical practice, and it is worth noting that personalized treatment regimens are also essential. Secondly, close follow-up is required to regularly monitor the blood and lymphocyte subsets of the patient, allowing early detection and timely intervention. Thirdly, prompt adjustment of

the treatment regimens, particularly medication modifications and the initiation of anti-infective treatment should be performed in a timely manner if the patient shows signs of infection. Therefore, specialized surgical management should be promptly considered for infections that meet the conditions for surgery.

Acknowledgements

Not applicable.

Funding

No funding was received.

Availability of data and materials

The datasets used and/or analyzed during the current study are available from the corresponding author on reasonable request.

Authors' contributions

ZQ contributed to conceptualization and design of the study, analyzed and interpreted the data, and was a major contributor in drafting the manuscript. XL was responsible for study design and manuscript revision. SL and HZ collected clinical information, designed the study and assisted with the drafting of the manuscript. XL and ZQ confirm the authenticity of all the raw data. All authors critically revised the manuscript for important intellectual content. All authors read and approved the final manuscript.

Ethics approval and consent to participate

Not applicable.

Patient consent for publication

Written informed consent was obtained from the patient for publication of the data and images in this case report.

Competing interests

The authors declare that they have no competing interests.

References

- Deng X, Gao J and Zhao F: Identification of differentially expressed genes and pathways in kidney of ANCA-associated vasculitis by integrated bioinformatics analysis. *Ren Fail* 44: 204-216, 2022.
- Li J, Cui Z, Long JY, Huang W, Wang JW, Wang H, Zhang L, Chen M and Zhao MH: The frequency of ANCA-associated vasculitis in a national database of hospitalized patients in China. *Arthritis Res Ther* 20: 226, 2018.
- Salvador F: ANCA associated vasculitis. *Eur J Intern Med* 74: 18-28, 2020.
- Geetha D and Jefferson JA: ANCA-associated vasculitis: Core curriculum 2020. *Am J Kidney Dis* 75: 124-137, 2020.
- Kitching AR, Anders HJ, Basu N, Brouwer E, Gordon J, Jayne DR, Kullman J, Lyons PA, Merkel PA, Savage COS, *et al*: ANCA-associated vasculitis. *Nat Rev Dis Primers* 6: 71, 2020.
- Xiao Y, Guyatt G, Zeng L, Rw Jayne D, A Merkel P, Ac Siemieniuk R, Dookie JE, A Buchan T, Ahmed MM, J Couban R, *et al*: Comparative efficacy and safety of alternative glucocorticoids regimens in patients with ANCA-associated vasculitis: A systematic review. *BMJ Open* 12: e050507, 2022.
- Theofilis P, Vordoni A, Koukoulaki M, Vlachopoulos G and Kalaitzidis RG: Overview of infections as an etiologic factor and complication in patients with vasculitides. *Rheumatol Int* 42: 759-770, 2022.
- King C, Harper L and Little M: The complications of vasculitis and its treatment. *Best Pract Res Clin Rheumatol* 32: 125-136, 2018.
- Lionaki S and Boletis JN: The prevalence and management of pauci-immune glomerulonephritis and vasculitis in Western countries. *Kidney Dis (Basel)* 1: 224-234, 2016.
- Kamat RD, Dhupar V, Akkara F and Shetye O: A comparative analysis of odontogenic maxillofacial infections in diabetic and nondiabetic patients: An institutional study. *J Korean Assoc Oral Maxillofac Surg* 41: 176-180, 2015.
- Nakazawa D, Masuda S, Tomaru U and Ishizu A: Pathogenesis and therapeutic interventions for ANCA-associated vasculitis. *Nat Rev Rheumatol* 15: 91-101, 2019.
- Mohammad AJ: An update on the epidemiology of ANCA-associated vasculitis. *Rheumatology (Oxford)* 59 (Suppl3): iii42-iii50, 2020.
- Han X, An J, Zhang Y, Gong X and He Y: Risk factors for life-threatening complications of maxillofacial space infection. *J Craniofac Surg* 27: 385-390, 2016.
- Al-Sebaei MO and Jan AM: A survey to assess knowledge, practice, and attitude of dentists in the Western region of Saudi Arabia. *Saudi Med J* 37: 440-445, 2016.
- Mukhtyar C, Lee R, Brown D, Carruthers D, Dasgupta B, Dubey S, Flossmann O, Hall C, Hollywood J, Jayne D, *et al*: Modification and validation of the Birmingham vasculitis activity score (version 3). *Ann Rheum Dis* 68: 1827-1832, 2009.
- Iwanaga J, Watanabe K, Anand MK and Tubbs RS: Air dissection of the spaces of the head and neck: A new teaching and dissection method. *Clin Anat* 33: 207-213, 2020.
- Khawaja NA, Khalil H, Parveen K, Al-Mutiri A, Al-Mutiri S and Al-Saawi A: A retrospective radiographic survey of pathology associated with impacted third molars among patients seen in oral & maxillofacial surgery clinic of college of dentistry, riyadh. *J Int Oral Health* 7: 13-17, 2015.
- Arman F, Barsoum M, Selamet U, Shakeri H, Wassef O, Mikhail M, Rastogi A and Hanna RM: Antineutrophil cytoplasmic antibody-associated vasculitis, update on molecular pathogenesis, diagnosis, and treatment. *Int J Nephrol Renovasc Dis* 11: 313-319, 2018.
- Kakoullis L, Parperis K, Papachristodoulou E and Panos G: Infection-induced myeloperoxidase specific antineutrophil cytoplasmic antibody (MPO-ANCA) associated vasculitis: A systematic review. *Clin Immunol* 220: 108595, 2020.



Copyright © 2023 Qiao et al. This work is licensed under a Creative Commons Attribution-NonCommercial-NoDerivatives 4.0 International (CC BY-NC-ND 4.0) License.