

# Metastasis of primary breast angiosarcoma to axillary and supraclavicular lymph nodes: a rare case diagnosed using imaging data

Journal of International Medical Research  
49(3) 1–5

© The Author(s) 2021

Article reuse guidelines:

sagepub.com/journals-permissions

DOI: 10.1177/03000605211002337

journals.sagepub.com/home/imr



Xiaojuan Qin<sup>1,\*</sup>, Yu Wu<sup>1,\*</sup>, Lan Yu<sup>2</sup>, Qing Lv<sup>1</sup>  
and Mingxing Xie<sup>1</sup> 

## Abstract

Primary breast angiosarcoma (PBA) is a rare malignant tumor. PBA usually undergoes hematogenous metastasis; lymph node metastasis is very rare in such patients, and metastasis of PBA to the supraclavicular lymph nodes has not previously been reported. Here, we describe a rare case of PBA manifested by a diffuse enlargement of the left breast, with metastasis to the left axillary and bilateral supraclavicular lymph nodes. Contrast-enhanced ultrasound and positron emission tomography findings indicated a malignant lesion, whereas magnetic resonance imaging suggested a benign lesion. Core needle biopsy identified the lesion as a lymphangioma, and the histological characteristics suggested a high-grade angiosarcoma. Multimodal imaging and perfusion patterns obtained using various contrast agents can thus help to diagnose PBA.

## Keywords

Primary breast angiosarcoma, diagnosis, axillary lymph node metastasis, supraclavicular lymph node metastasis, ultrasound, magnetic resonance imaging, computed tomography

Date received: 27 October 2020; accepted: 22 February 2021

<sup>1</sup>Department of Ultrasound, Union Hospital, Tongji Medical College, Huazhong University of Science and Technology, Wuhan, China

<sup>2</sup>Department of Pathology, Union Hospital, Tongji Medical College, Huazhong University of Science and Technology, Wuhan, China

\*These authors contributed equally to this work.

## Corresponding author:

Mingxing Xie, Department of Ultrasound, Union Hospital, Tongji Medical College, Huazhong University of Science and Technology, No.1277 Jiefang Avenue, Wuhan 430022, China.

Email: xiemx@hust.edu.cn (MX)



## Introduction

Angiosarcomas are rare malignant tumors that originate from endothelial cells lining the vascular and lymphatic channels.<sup>1</sup> Angiosarcoma of the breast usually arises after lymphedema or cancer radiotherapy, whereas primary breast angiosarcoma (PBA) is a rare tumor that accounts for only about 0.05% of all malignant breast tumors.<sup>2</sup> The major clinical manifestations of breast angiosarcomas include a fast-growing painless mass,<sup>3</sup> and approximately 2% of patients with angiosarcoma show diffuse enlargement of the breast.<sup>4</sup> PBA usually undergoes hematogenous metastasis, and lymph node metastasis is very rare. To the best of our knowledge, there have been only six previous reports of PBA with axillary lymph node metastasis,<sup>5-9</sup> for which the imaging descriptions of the lymph nodes only reported swelling. Furthermore, there have been no reports of metastasis of PBA to the supraclavicular lymph nodes.

In this report, we describe a rare case of PBA with diffuse enlargement of the left breast and metastasis to the left axillary and bilateral supraclavicular lymph nodes, and discuss its diagnosis using imaging data.

## Case report

A 22-year-old woman presented with an enlarged left breast after giving birth 4 years earlier, with no local pain, fever, or nipple discharge. She was admitted our hospital with a 1-month history of pericardial and pleural effusions. She had no history of exposure to radiation or other diseases, and had not undergone any surgeries, except for a cesarean section in 2014. On physical examination, her left breast was notably enlarged with telangiectasia. No obvious tumor boundary could be detected. A 4 × 2-cm firm mass was found in the left

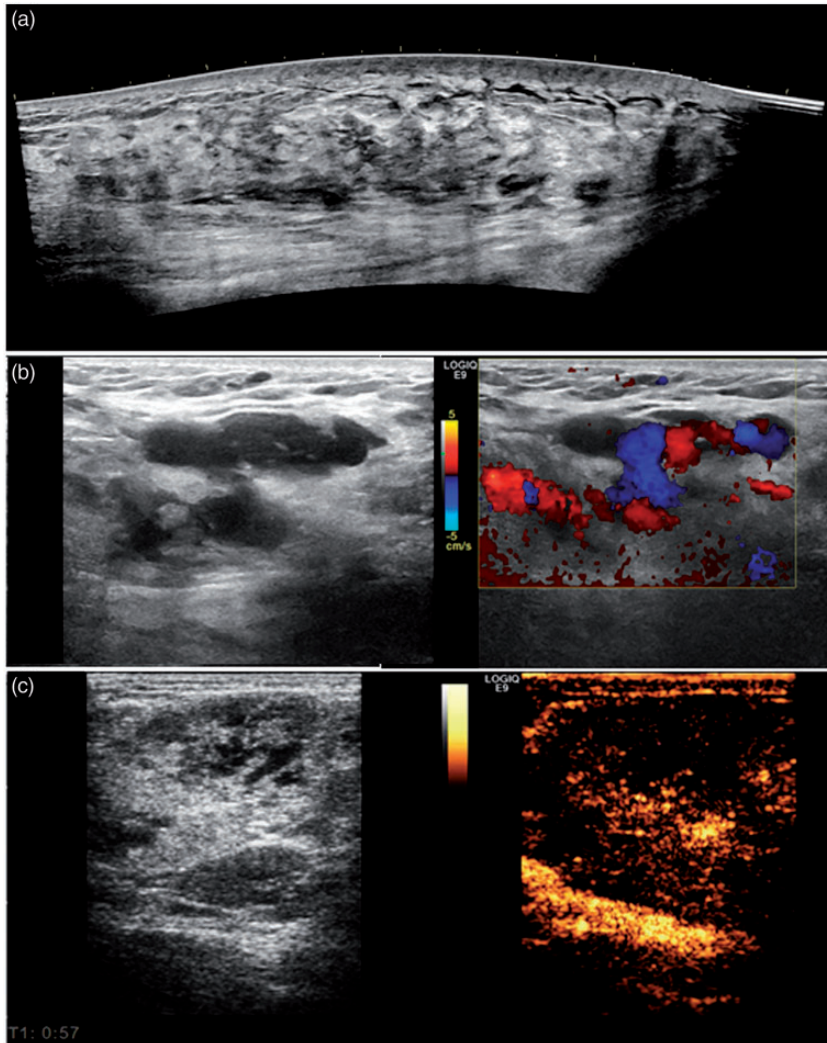
armpit. Examinations of her right breast and armpit were unremarkable.

The entire left breast appeared as a heterogeneous hypoechoic mass with irregular anechoic portions on ultrasonography (Figure 1a). This structure extended outwards and upwards to the left armpit, and hyperechoic masses with tortuous tubular echoes were found in the left lower portion of the neck and bilateral supraclavicular lymph nodes (Figure 1b). Contrast-enhanced ultrasound revealed inhomogeneous enhancement with scattered non-enhanced areas in the mass in the left breast (Figure 1c). The mass was therefore suspected to be a malignant tumor.

Magnetic resonance imaging (MRI) showed no obvious enhanced lesions in the left breast or armpit (Figure 2). The left breast contained tortuous and dilated lymphatics, indicated by earthworm-like tubular shadows. The left axillary lymph node contained a multilocular cystic lesion.

Positron emission tomography showed mild uptake of fluorodeoxyglucose in the left breast, left armpit, and bilateral supraclavicular lesions. The left side of the first and second ribs exhibited partial destruction. Based on these findings, the lesion was diagnosed as malignant.

Core needle biopsy revealed a lymphangioma in the left breast and armpit. Because of persistent pericardial and pleural effusion, multidisciplinary reassessment recommended simple mastectomy and axillary node sampling to confirm the diagnosis. Immunohistochemical staining of D2-40 (+), CD34(-), and ERG(+) confirmed the lymphatic vessels, and histological features suggested a high-grade angiosarcoma (Figures 3 and 4). The left axillary lymph nodes were extensively affected. The patient received chemotherapy. There was no change in the supraclavicular lymph nodes and no clinical evidence of relapse during the 12-month follow-up period.



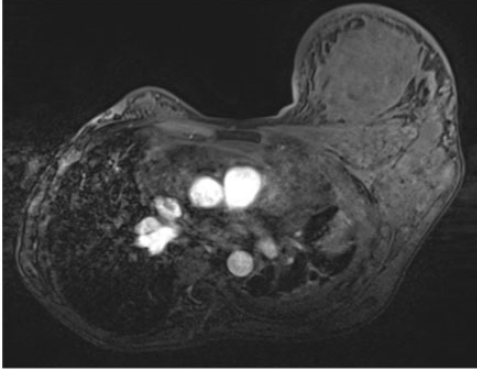
**Figure 1.** Ultrasound findings. a) Grayscale ultrasound showing left breast replaced by heterogeneous hypoechoic structure. b) Grayscale and color Doppler ultrasound showing hyperechoic masses with vessels in the left supraclavicular region. c) Contrast-enhanced ultrasound of structure in left breast showing inhomogeneous enhancement with scattered non-enhancing areas.

## Discussion

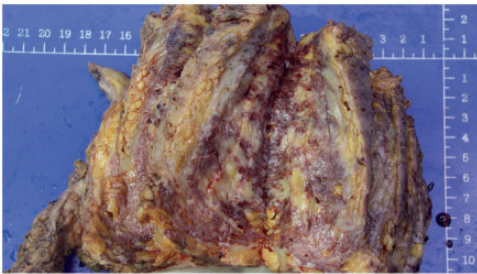
It is usually difficult to diagnose PBA before surgery. Ultrasonography generally fails to reveal any specific characteristics: it can manifest as an independent lesion or multiple lesions, with limited or unclear boundaries, and may be hypoechoic, hyperechoic, or heterogeneous.<sup>7</sup>

Ultrasonography in the current case showed that the entire left breast was replaced by heterogeneous hypoechoic structures with irregular anechoic regions, possibly attributed to a reticular pattern of infiltration of angiosarcoma in the breast. Ultrasonography therefore cannot be used to make an accurate diagnosis. However,

contrast-enhanced ultrasound can be used to differentiate between benign and malignant lesions. This technique shows a small number of sparse microbubbles in normal

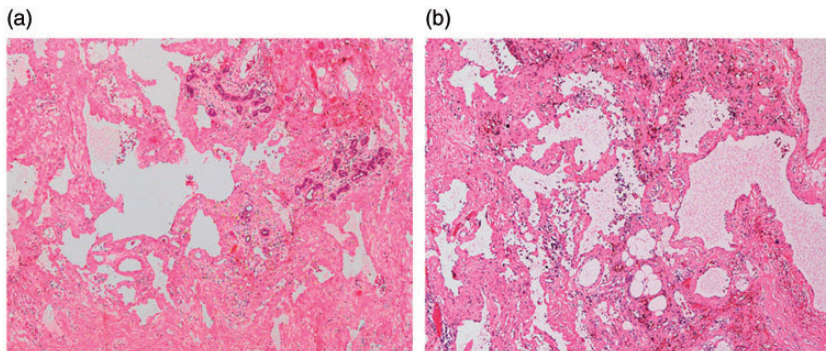


**Figure 2.** Magnetic resonance image showing no obvious enhancement in lesion in left breast and armpit.



**Figure 3.** Gross findings of angiosarcoma of the breast.

breast tissue; however, our patient had a diseased breast with inhomogeneous characteristics visible shortly after injecting the contrast agent, suggesting the occurrence of more blood vessels and increased microvessel bed activity in diseased compared with a normal breast. Malignant lesions release angiogenic factors, thereby increasing local vascular density and permeability,<sup>10</sup> leading to more microbubbles in malignant lesions than in benign ones. Angiosarcoma is often accompanied by a tortuous vascular system and abnormal arteriovenous anastomosis, which can help to determine the malignancy of the tumor. Contrast-enhanced MRI also relies on the pattern of perfusion to differentiate between benign and malignant breast lesions. Wang et al.<sup>7</sup> reported that MRI of PBA was characterized by poorly demarcated lesions with low signal intensity on T1-weighted images, markedly high intensity on T2-weighted images, and prolonged enhancement in dynamic studies. However, MRI scans showed no obvious alterations in the lesions in our patient. The physiological changes following metastasis warrant diagnosis of PBA by imaging. This was especially important in the current patient because she presented with persistent pericardial and pleural effusion and osseous damage, which further supported a malignant diagnosis.



**Figure 4.** Hematoxylin–eosin (H&E) stained section of angiosarcoma of the breast. a)  $\times 40$ ; b)  $\times 100$ .

PBA is difficult to diagnose by core needle biopsy.<sup>8,11</sup> This could be because PBAs comprise vascular endothelial-like structures with an irregular arrangement of papillae. In addition, PBAs are associated with an extensive and abundant blood supply, making it difficult to obtain samples from the parenchymal region by centesis. In the present case, the results of core needle biopsy of the breast and axillary lesions indicated that the lymphangioma was benign. Tumor resection followed by pathological examination is thus currently the most reliable course of action for patients with PBA.

Clinical workups generally fail to detect PBA because of its low incidence and the difficulty in making an accurate diagnosis. However, the timely detection and treatment of PBA is especially important, given its highly malignant nature and poor prognosis. This case highlights the value of multimodal imaging and analysis of perfusion patterns using various contrast agents to aid its diagnosis.

### Ethics Statement

The patient provided written informed consent for treatment and for publication of this report. The study was approved by the Ethics Committee of Union Hospital, Tongji Medical College, Huazhong University of Science and Technology, Wuhan, China (approval number: [2019] Lunshen Zi (S149).

### Funding

The author(s) disclosed receipt of the following financial support for the research, authorship, and/or publication of this article: This study was supported by National Natural Science Foundation of China (Grants: 81901769, 81601540).

### Declaration of Conflicting Interest

The authors declare that there is no conflict of interest.

### ORCID iD

Mingxing Xie  <https://orcid.org/0000-0003-4984-1567>

### References

1. Fraga-Guedes C, Gobbi H, Mastropasqua MG, et al. Primary and secondary angiosarcomas of the breast: a single institution experience. *Breast Cancer Res Treat* 2012; 132: 1081–1088.
2. Abbad F, Idrissi NC, Fatih B, et al. Primary breast angiosarcoma: A rare presentation of rare tumor - Case report. *BMC Clin Pathol* 2017; 17: 17.
3. Masai K, Kinoshita T, Jimbo K, et al. Clinicopathological features of breast angiosarcoma. *Breast Cancer* 2016; 23: 718–723.
4. Bhosale SJ, Kshirsagar AY, Patil MV, et al. Primary angiosarcoma of breast: A case report. *Int J Surg Case Rep* 2013; 4: 362–364.
5. Carter E, Ulusaraç O and Dyess DL. Axillary lymph node involvement in primary epithelioid angiosarcoma of the breast. *Breast J* 2005; 11: 219–220.
6. Sher T, Hennessy BT, Valero V, et al. Primary angiosarcomas of the breast. *Cancer* 2007; 110: 173–178.
7. Wang L, Lao IW, Yu L, et al. Primary breast angiosarcoma: a retrospective study of 36 cases from a single Chinese medical institute with clinicopathologic and radiologic correlations. *Breast J* 2017; 23: 282–291.
8. Kunkiel M, Maczkiewicz M, Jagiełło-Gruszczyńska A, et al. Primary angiosarcoma of the breast—series of 11 consecutive cases—a single-centre experience. *Curr Oncol* 2018; 25: e50–e53.
9. Scow JS, Reynolds CA, Degnim AC, et al. Primary and secondary angiosarcoma of the breast: the Mayo Clinic experience. *J Surg Oncol* 2010; 101: 401–407.
10. Yang WT, Muttarak M and Ho LW. Nonmammary malignancies of the breast: ultrasound, CT, and MRI. *Semin Ultrasound CT MR* 2000; 21: 375–394.
11. Losanoff JE, Jaber S, Esuba M, et al. Primary angiosarcoma of the breast: do enlarged axillary nodes matter? *Breast J* 2006; 12: 371–374.