

# Evidence for Independent Hepatitis E Virus Replication in the Brain

Evert P.M. den Drijver, MD, Annemarie E. Brouwer, MD, PhD, Nathalie E. Synhaeve, MD, PhD, Janneke P. Keijer, MSc, Jaco J. Verweij, PhD, Jean-Luc Murk, MD, PhD, and Suzan D. Pas, PhD

## Correspondence

Dr. den Drijver  
evertendrijver@gmail.com

*Neurol Neuroimmunol Neuroinflamm* 2021;8:e939. doi:10.1212/NXI.0000000000000939

## Case Report

A 46-year-old man presented with a 5-year history of fatigue, frequent painful muscular spasms in the extremities, and tingling sensations in the hands and feet. His medical history consisted of attention-deficit/hyperactivity disorder, a cervical *Mycobacterium avium* lymphadenitis during childhood and lateral ligament reconstruction of both ankles after trauma.

Neurologic examination revealed hyperesthesia of arms and legs and inconsistent motor dysfunction without paresis. No muscle spasms were witnessed. During the examination, the patient showed inconsistent limb weakness without objective paresis as seen in patients with functional neurologic disorder. MRI reports of brain and spinal cord were unremarkable. EMG did not show any sign of polyneuropathy. CSF had 5 white blood cells/mm<sup>3</sup>, no red blood cells, and normal protein (0.36 g/L) and glucose (3.4 mmol/L) levels. Peripheral blood chemistry showed no abnormalities except for elevated gamma-glutamyl and alanine aminotransferases (GGT and ALT of 139 and 58 U/L, respectively). Microbiological examinations provided detectable anti-hepatitis E virus (HEV)-immunoglobulin (Ig) M and IgG antibodies and HEV RNA in serum and CSF. Intrathecal antibody production of anti-HEV IgG was confirmed by calculation of the CSF-serum antibody index, being 7.5. Other hepatitis serology and HIV were negative. The patient did not use immunosuppressive drugs, and a basic immunologic screening did not reveal any immunodeficiencies, with 800/mm<sup>3</sup> CD4 cells and normal IgA, IgM, and IgG subclass analysis. There were no signs of an underlying autoimmune disease and no history of recurrent infections.

Because it was expected that the immunocompetent man would clear the HEV infection, no treatment with ribavirin was started until it became evident at day 205 after the initial presentation that HEV RNA persisted in feces, plasma, and CSF (figure, A). After treatment was started at day 205, HEV RNA became undetectable in serum (day 236) and feces (day 282) and GGT and ALT levels normalized (figure, B). In CSF, however, HEV RNA remained detectable under ribavirin treatment for more than a year, with PCR cycle threshold values between 29.3 and 32.5, without a consistent decrease of viral load. The anti-HEV IgG CSF-serum antibody index increased to 30, which provided evidence for increased intrathecal IgG production (figure, A). Ribavirin plasma concentrations were within therapeutic levels (day 551, >2.00 mg/L). PEG-interferon alpha 2a was added to ribavirin at day 567 because HEV RNA in CSF persisted and the patient showed only very limited signs of (subjective) improvement. Adding PEG-interferon alpha 2a did not result in clinical or virologic improvement, with HEV RNA in CSF still being present after 14 months of combined treatment. At day 991, it was decided to stop further treatment with ribavirin and PEG-interferon alpha 2a. After treatment was discontinued, HEV RNA in feces was tested at day 1,084 and in CSF and serum at day 1,089, with

---

From the Microvida (E.P.M.d.D., J.J.V., J.-L.M.), Department of Internal Medicine (A.E.B.), and Department of Neurology (N.E.S.), Elisabeth-TweeSteden Hospital, Tilburg; and Microvida (J.P.K., S.D.P.), Bravis Hospital, Roosendaal, The Netherlands.

Go to [Neurology.org/NN](https://www.neurology.org/NN) for full disclosures. Funding information is provided at the end of the article.

The Article Processing Charge was funded by the authors.

This is an open access article distributed under the terms of the Creative Commons Attribution-NonCommercial-NoDerivatives License 4.0 (CC BY-NC-ND), which permits downloading and sharing the work provided it is properly cited. The work cannot be changed in any way or used commercially without permission from the journal.

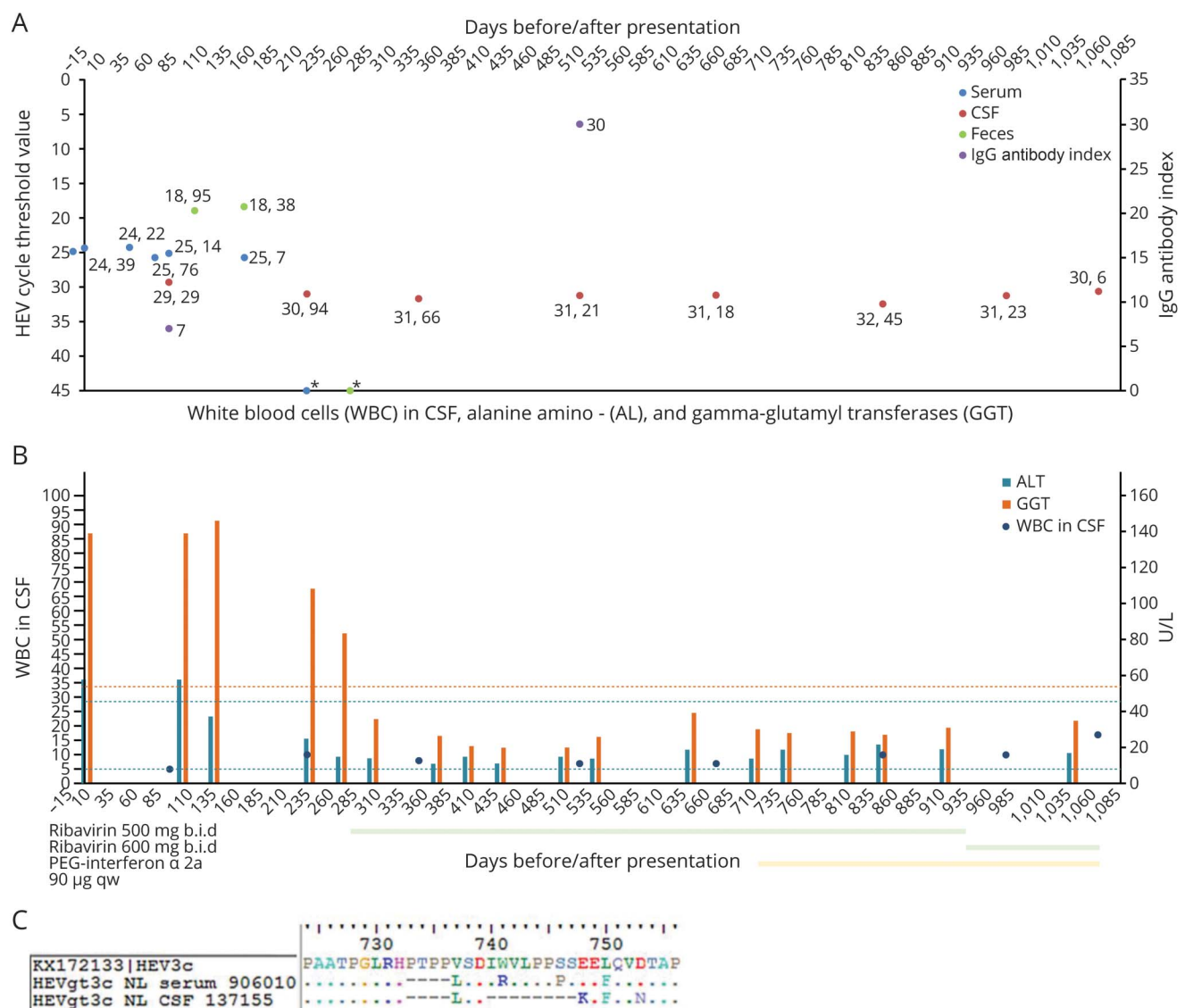
RNA in CSF still being present but no detectable RNA in serum or feces. Nonetheless, a follow-up MRI scan at day 1,109 was unremarkable.

## Virologic Analyses (Methods and Results)

To determine if the CNS contained HEV quaspecies distinct from other bodily compartments, HEV RNA was sequenced from serum and CSF. HEV RNA from serum (day 12) and CSF (day 102) before antiviral treatment was Sanger-sequenced according to Sari et al,<sup>1</sup> with minor adaptations. Near full genome (99.2%) was obtained from serum (GenBank accession number MT362711). From CSF, 66.7% of the

genome could be retrieved due to low viral load (GenBank accession number MT362712). The genomes were genotype 3c, and both showed a deletion in the polyproline-rich region in ORF1, a region known to affect and enhance viral adaptation.<sup>2</sup> Notably, serum and CSF showed a 4 amino acid in-frame deletion (del 733–736, PTPP), and CSF showed an additional 8 amino acid in-frame deletion (del 740–747, IRVLPPPS) compared with reference sequence KX172133 (figure, B and table e-1, [links.lww.com/NXI/A367](https://links.lww.com/NXI/A367)). The presence of a distinct viral population in the CNS in combination with viral persistence in the CSF strongly suggests independent viral replication of HEV in the brain. Ribavirin resistance-associated mutations were not found in samples obtained before treatment.<sup>3</sup> After treatment, viral loads in CSF were below the detection limit for Sanger sequencing.

**Figure** HEV PCR Cycle Threshold Values (Serum, CSF, Faeces) and IgG Antibody Index



(A) Course of infection showing HEV RNA PCR cycle threshold values for serum, CSF, and feces and anti-HEV IgG antibody index values, (B) ALT and GGTs in blood vs WBC values in CSF, and (C) the alignment of reference, serum, and CSF sequence fragment with 4 amino acid in-frame deletion (del 733–736, PTPP) in serum and CSF. An additional 8 amino acid in-frame deletion (del 740–747, IRVLPPPS) in CSF. HEV = hepatitis E virus; IgG = immunoglobulin G.

## Discussion

Apart from hepatitis, HEV infections may also cause neurologic disorders, such as meningoencephalitis, peripheral neuropathies, and polyradiculitis.<sup>4</sup> The etiology of HEV-associated neurologic manifestations is still inconclusive. If the HEV is primarily hepatotropic, the neurologic injury could be the result of postinfectious immune mechanisms. However, previous studies reported evidence for neurotropism of HEV, based on intrathecal anti-HEV antibody synthesis and CNS quasispecies compartmentalization of the HEV.<sup>4</sup> Neurologic symptoms are often accompanied by the transient presence of HEV in CSF; however, it is unknown whether this is the result of a productive or abortive infection of cells in the nervous system. In the first scenario, the nervous system would support HEV replication independent of the rest of the body, whereas in the latter a localized infection cannot be sustained because infected cell types are incapable of completing the full viral replication cycle. The distinction is important because the possibility of a compartmentalized infection could lead to (unrecognized) viral persistence, clinical rebound of infection, treatment failure, and development of antiviral resistance. It also has implications for diagnostic testing and follow-up of patients.

Various human neural cell lines (embryonic stem cell-derived neural lineage cells) have been shown to support *in vitro* HEV replication.<sup>5</sup> In the present case, HEV was cleared from blood and feces on treatment with ribavirin, but HEV RNA persisted in the CSF for 1,089 days. In addition, the patient remained symptomatic and had evidence of CNS inflammation and progressively increasing intrathecal antibody synthesis. Although it could not be determined if HEV in CSF was infectious, this case provides direct evidence that the human CNS supports a persistent HEV infection possibly because of viral adaptation in the polyproline-rich region of ORF1.

The problems typical of compartmentalization are also evident in our case: treatment failure likely because of insufficient penetration of ribavirin in the nervous system.<sup>6</sup> Unfortunately, HEV RNA in CSF could not be tested for mutations associated with failure of ribavirin treatment during therapy because the viral load in CSF was too low.<sup>7</sup> The prognosis of HEV persistence in the CNS is unknown.

In conclusion, we present a first case of chronic HEV RNA persistence and compartmentalization in CSF in an immunocompetent patient, suggestive of viral replication in the CNS. Our case also illustrates that new treatments are needed for persistent HEV infections.

## Acknowledgment

The authors thank the patient for sample contribution and technicians of the Laboratory for Medical Microbiology and Immunology for contributions in diagnostics in the current

case. The patient in this case report provided written informed consent for publication.

## Study Funding

The authors report no targeted funding.

## Disclosure

The authors report no disclosures relevant to the manuscript. Go to [Neurology.org/NN](http://Neurology.org/NN) for full disclosures.

## Publication History

Received by *Neurology: Neuroimmunology & Neuroinflammation* June 23, 2020. Accepted in final form November 9, 2020.

## Appendix Authors

Name	Location	Contribution
<b>Evert P.M. den Drijver, MD</b>	Microvida, Elisabeth-TweeSteden Hospital, Tilburg, the Netherlands	Drafting/revision of the manuscript for content, including medical writing for content; major role in the acquisition of data; study concept or design; and analysis or interpretation of data
<b>Annemarie E. Brouwer, MD, PhD</b>	Department of Internal Medicine, Elisabeth-TweeSteden Hospital, Tilburg, the Netherlands	Drafting/revision of the manuscript for content, including medical writing for content; and major role in the acquisition of data
<b>Nathalie E. Synhaeve, MD, PhD</b>	Department of Neurology, Elisabeth-TweeSteden Hospital, Tilburg, the Netherlands	Drafting/revision of the manuscript for content, including medical writing for content; and major role in the acquisition of data
<b>Janneke P. Keijer, MSc</b>	Microvida, Bravis Hospital, Roosendaal, the Netherlands	Major role in the acquisition of data; and analysis or interpretation of data
<b>Jaco J. Verweij, PhD</b>	Microvida, Elisabeth-TweeSteden Hospital, Tilburg, the Netherlands	Drafting/revision of the manuscript for content, including medical writing for content; and major role in the acquisition of data
<b>Jean-Luc Murk, MD, PhD</b>	Microvida, Elisabeth-TweeSteden Hospital, Tilburg, the Netherlands	Drafting/revision of the manuscript for content, including medical writing for content; major role in the acquisition of data; study concept or design; and analysis or interpretation of data
<b>Suzan D. Pas, PhD</b>	Microvida, Bravis Hospital, Roosendaal, the Netherlands	Drafting/revision of the manuscript for content, including medical writing for content; major role in the acquisition of data; study concept or design; and analysis or interpretation of data

## References

1. Sari G, van de Garde MDB, van Schoonhoven A, et al. Hepatitis E virus shows more genomic alterations in cell culture than in vivo. *Pathogens* 2019;8:255. Available at: [mdpi.com/2076-0817/8/4/255](https://doi.org/10.3390/path8040255). Accessed February 25, 2020.
2. Purdy MA, Lara J, Khudyakov YE. The hepatitis E virus polyproline region is involved in viral adaptation. *PLoS One* 2012;7:e35974. Available at: [dx.plos.org/10.1371/journal.pone.0035974](https://doi.org/10.1371/journal.pone.0035974). Accessed February 25, 2020.
3. Debing Y, Ramière C, Dallmeier K, et al. Hepatitis E virus mutations associated with ribavirin treatment failure result in altered viral fitness and ribavirin sensitivity. *J Hepatol* 2016;65:499–508. Available at: [linkinghub.elsevier.com/retrieve/pii/S0168827816301878](https://doi.org/10.1016/j.jhep.2016.08.018). Accessed February 25, 2020.
4. Dalton HR, Kamar N, van Eijk JJ, et al. Hepatitis E virus and neurological injury. *Nat Rev Neurol* 2016;12:77–85. Available at: [nature.com/articles/nrneuro.2015.234](https://doi.org/10.1038/nrneuro.2015.234). Accessed February 25, 2020.
5. Zhou X, Huang F, Xu L, et al. Hepatitis E virus infects neurons and brains. *J Infect Dis* 2017;215:1197–1206. Available at: [ncbi.nlm.nih.gov/pubmed/28199701](https://pubmed.ncbi.nlm.nih.gov/28199701/). Accessed February 25, 2020.
6. Grayson ML, Cosgrove S, Crowe SM, et al. *Kucers the Use of Antibiotics: A Clinical Review of Antibacterial, Antifungal, Antiparasitic, and Antiviral Drugs* [online]. 7th ed. Boca Raton: CRC Press; 2017. Available at: [taylorfrancis.com/books/9781444147520](https://doi.org/10.1080/9781444147520). Accessed February 25, 2020.
7. Todt D, Walter S, Brown R, Steinmann E. Mutagenic effects of ribavirin on hepatitis E virus—viral extinction versus selection of fitness-enhancing mutations. *Viruses* 2016;8:283. Available at: [mdpi.com/1999-4915/8/10/283](https://doi.org/10.3390/v810283). Accessed February 25, 2020.